

# Severe amnesia following a unilateral temporal lobe stroke

Raji P. Grewal MD

New Jersey Neuroscience Institute, Edison, NJ, USA

**Summary** A 60 year old right-handed man developed severe amnesia following a left medial temporal stroke as documented by cerebral MRI, MRA and SPECT scans. Neuropsychological evaluation 13 weeks after the stroke showed a profound retrograde amnesia characterised by memory loss for public facts and events over the previous four decades. In addition, autobiographical memory showed selective loss of personal episodic memory with relative preservation of personal semantic memory. The development of this degree of amnesia with these features following a unilateral temporal lobe lesion is unusual. The possible neuroanatomical mechanisms underlying the amnesia and how they relate to current theories of memory loss are discussed.

© 2002 Elsevier Science Ltd. All rights reserved.

*Journal of Clinical Neuroscience* (2003) 10(1), 102–104  
© 2002 Elsevier Science Ltd. All rights reserved.  
DOI:10.1016/S0967-5868(02)00278-3

**Keywords:** stroke, unilateral temporal lobe, retrograde amnesia, autobiographical memory

Received 27 June 2002  
Accepted 22 August 2002

Correspondence to: Raji P. Grewal MD, New Jersey Neuroscience Institute, Seton Hall University, 65 James Street, Edison, NJ 08818, USA.  
Tel.: +1-732-321-7000 ext. 68890; Fax: +1-732-632-1584;  
E-mail: rgrewal@solarishs.org

## INTRODUCTION

The central role of the hippocampus in memory and learning in humans has been implicated, in part, on the basis of studies of patients with temporal lobe damage.<sup>1</sup> However, controversies remain regarding the relationship between the extent of damage and the nature of the memory deficit. These include issues of whether or not amnesia can result from unilateral temporal lobe damage and the role of an intact hippocampus in the retrieval of memories that are still preserved.<sup>2–4</sup> I report a patient who developed severe amnesia for facts and events with relative preservation of personal semantic memories following a unilateral temporal lobe stroke.

## CASE REPORT

A 60 year old right-handed man was evaluated 13 weeks after suffering a left hemispheric stroke. He was born in 1938 in Pennsylvania and evaluated in 1998. His native language was English and he had lived his entire life in the United States. He had been employed as a mechanical engineer with expertise in accident analysis and legal testimony. However, following the stroke, he was unable to return to work. His presenting complaint was “I have difficulty remembering things”. He had a 5 year history of non-

insulin dependent diabetes mellitus, hypercholesterolemia and hypertension but no significant past neurological history. A neurological examination revealed normal motor, sensory, and cerebellar systems and a normal gait. Cranial nerve examination disclosed a right superior field hemianopsia with normal pupillary responses and normal visual acuity with correction.

Neuropsychological evaluation was performed. The patient was alert and oriented to the situation. He was cooperative and attentive during the course of the examination. He exhibited a normal level of psychomotor activity. His speech and language were of normal loudness and prosody with no word finding difficulties or paraphasic errors. His affect showed normal range and intensity and he acknowledged concern and insight into his impaired memory and inability to return to work. A Wechsler Individual Achievement Test (WAIT) Screener Set showed that the patient was severely impaired in sight reading which fell at the level of 3rd grade and also impaired in spelling (at the level of 6–7th grade). He had agraphia but no difficulties in color naming or finger agnosia. His performance on tests of mathematical reasoning showed he had retained the basic concepts and operations but made careless errors partly due to inaccurate comprehension of word problems. His scores on the mathematics test were equivalent to the 12th grade, which is below expectation relative to his educational and occupational backgrounds.

A Rey's Auditory-Verbal Learning Test (RVLT) showed that relative to his age range, he was severely impaired including learning over five trials in tests of both short and long term memory.<sup>5</sup> He was asked to read a list of 15 unrelated common words and immediately afterward asked to recall them. After hearing and recalling the list of 15 words 5 times, another list of 15 new words was read to be recalled and to serve as a distraction. Recalling the words from the original list was requested immediately afterwards and again after 30 min of unrelated activities. Furthermore, after the delayed recall, the patient was shown a short story that contains the 15 words and was asked to identify them as a measure of recognition. After the brief distraction, he could not remember any of 15 words. In the recognition test, he correctly identified only 1 out of the 15 words and misidentified 2 words that were not on the list.

His memory for public facts, events and famous names was poor over the preceding four decades. For example, he was able to name the current American president, Bill Clinton but could not provide any details of events during his presidency including political scandals. He could not recall details of major American public events such as the John F. Kennedy or Martin Luther King assassinations from the 1960s and Nixon's impeachment or the end of the Vietnam War from the 1970s. In general, his recall for public events and names prior to 1960 was slightly better. He was able to remember the name of President Truman although he could not recall any other details of his tenure. He also remembered that a retired general became president (Dwight Eisenhower) but could not recall his name. Similarly, his recall of some events associated with American involvement in wars was better for World War II when compared to either the Korean or Vietnam Wars. He was able to recall the month and year of the attack on Pearl Harbor but not D-day or what year the war ended. Overall, his knowledge was still poor. He was able to recall only the opposition country of Germany, and was unable to recall any leaders of the opposing countries. His knowledge of Korean and Vietnam Wars was worse since he could not recall that they had even occurred. His recognition of public faces was similarly poor when tested by direct confrontation with pictures of Presidents and American personalities.

In contrast to his profound deficits in the knowledge of public facts and events, aspects of his autobiographical memory were

well preserved. These were assessed by the autobiographical memory interview.<sup>6</sup> On personal semantic questions, he scored 18, 19 and 19 on the childhood, early adult life and recent life periods (maximum score per life period is 21; his results were within normal limits). His ability to recall autobiographically relevant facts extended from preservation of personally relevant facts from all of the time periods tested from age 6 to 60 years. He was able to recall geography of the area in Pennsylvania where he grew up and the names and locations of all the schools he attended up to the college where he obtained a Bachelor's degree. He was also able to recall without difficulty all of the various places where he had been employed since graduation including the names of the employers and the kind of work he performed. He never married but was able to recall the names and locations of his close relatives. He was familiar with his personal finances and his medical history. In contrast, he scored 4, 5 and 4 on these life periods on the autobiographical incident tests (maximum score per section is 9; his test results were abnormal). All facts were confirmed from a secondary independent source.

### LABORATORY INVESTIGATIONS

A cerebral MRI examination demonstrated lesion consistent with a stroke involving the left medial temporal lobe extending to the occipital lobe (Fig. 1). There is damage to the hippocampus, parahippocampal gyrus and the subcortical white matter extending posteriorly into the occipital lobe. A cerebral MRA examination showed an occlusion of the left posterior cerebral artery corre-

sponding to the distribution of the stroke. A cerebral SPECT scan showed focal decrease in perfusion over the left temporal and occipital lobes.

### DISCUSSION

This patient exhibits several neurobehavioral deficits following the stroke. These include alexia with agraphia, a deficit most likely secondary to damage to the subcortical fibers of the left angular gyrus. However, the presenting symptom was that of memory difficulties which is a consequence of damage to the left temporal lobe.

It has been suggested that the extent of temporal lobe damage correlates with the degree and type of memory loss.<sup>7</sup> In general, those individuals with bilateral hippocampal formation lesions have moderately severe retrograde amnesia for facts and events with a temporal gradient. Those patients with extensive bilateral temporal lobe damage have severe retrograde amnesia for facts and events.<sup>7</sup> This patient's memory deficits for facts and events are severe with memory loss extending for at least 4 decades prior to the stroke and in general, there was better recall for events prior to 1960 suggesting the presence of a temporal gradient. Therefore, his memory deficits appear to be more typical of patients with bilateral than unilateral hippocampal lesions.

Whether or not severe amnesia can occur following unilateral temporal lesions has been a subject of debate.<sup>2</sup> In a recent review of the temporal lobectomy literature, analysis of all those cases initially reported to have become truly amnesic following unilat-

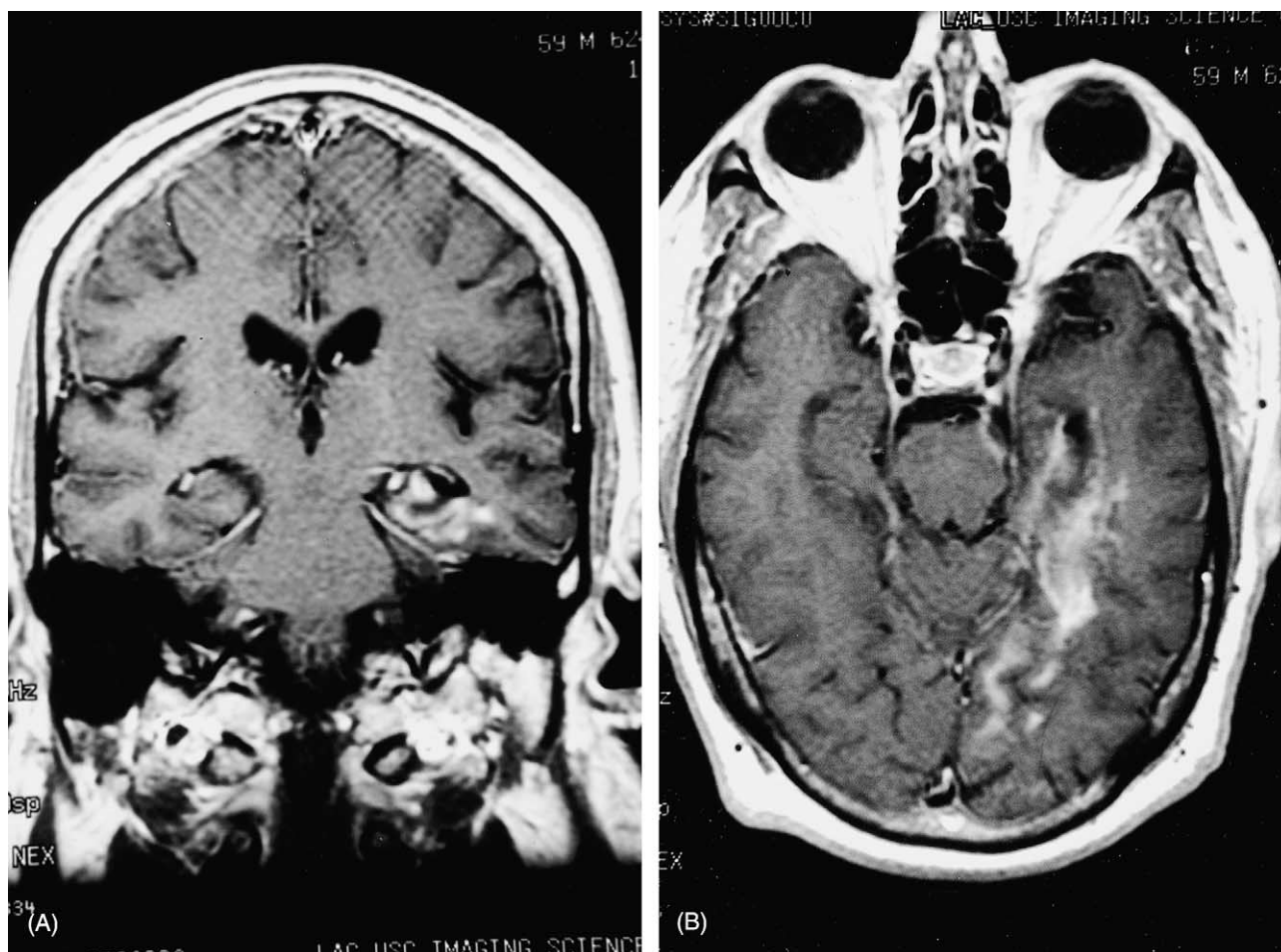


Fig. 1 (A) and (B) Coronal and sagittal cranial MRI images demonstrating an infarct extending from the left temporal lobe including the hippocampal complex to the occipital lobe in the distribution of the left posterior cerebral artery.

eral lobectomy showed that eventually all demonstrated some evidence of a bilateral temporal lobe abnormality.<sup>2</sup> The best available evidence in this patient is that the lesion is unilateral as documented by cerebral MRI, MRA and SPECT scanning.

It has been proposed that there are several types of retrograde amnesia and that this entity can no longer be viewed as a global deficit.<sup>1</sup> Autobiographical memory may be differentiated into episodic and semantic memory with the former referring to an individual's record of events or episodes specifiable in time and space and the latter to an individual's factual knowledge about a person's own past.<sup>6</sup> A recent study of 25 patients with unilateral temporal lobe epilepsy and excisions were studied.<sup>8</sup> Unlike my patient whose memory deficits were profound, they showed only mild memory deficits on standardised tests such as the Wechsler Memory Scale. However, they did demonstrate relative preservation of personal semantic memory with deficits in autobiographical episodic memory regardless of whether the affected temporal lobe was on the right or left. These findings support the "multiple trace theory" (MTT) of memory and hippocampal function where it is proposed that the hippocampal complex is an integral part of an autobiographical memory trace as long as it exists and is also involved in the retrieval process. It was suggested that there is selective loss of personal episodic memory because fewer complete traces have been laid down in comparison to personal semantic memories.<sup>8</sup>

Any attempts at a neuroanatomical explanation of this patient's memory deficits must take into account the status of the contralateral hippocampus. If the contralateral hippocampal formation were normal, as it appears to be by MRI and SPECT scan images, this patient's deficits would support the hypothesis of the MTT about the role of an intact hippocampus in retrieving autobiographical memories. This patient's pattern of autobiographical memory deficits are similar to those reported by Viskontas et al. in that there is loss of personal episodic memory with relative preservation of personal semantic memory. However, the MTT does not account for the severe loss of memory for public facts and events unless one postulates that in this patient, there is cerebral asymmetry for the retrieval or storage of this kind of knowledge.

An alternative explanation is that the contralateral hippocampus is abnormal. In one well-studied patient, severe memory loss with relative preservation of autobiographical knowledge was documented following a right temporal lobectomy.<sup>9</sup> The available technology at that time including an EEG, cerebral angiography and pneumoencephalography failed to disclose evidence of a lesion in the left hemisphere. However, at autopsy, a sclerotic lesion of the left hippocampus was found indicating bilateral damage. In my patient, since the MRI of the contralateral hippocampus appears normal, such an abnormality, if present, would be microscopic. If then, there were bilateral hippocampal damage, it would imply that knowledge and retrieval of semantic autobiographical memory is not dependent upon an intact hippocampal formation and therefore contradicts the MTT of memory.

The study of this patient demonstrates the fractionation of different classes of memoranda within a retrograde time period.<sup>1</sup> However, it also exemplifies the complexities of human memory and the difficulties in trying to reconcile neuropsychological findings with the proposed theories of memory. Studies such as this, even of individual patients are of value and will continue to provide insight into mechanisms of human memory.

#### ACKNOWLEDGEMENTS

I thank the Neuropsychology Services at USC County Hospital, Los Angeles, California, USA for performing some of the psychometric testing on this patient.

#### REFERENCES

1. Warrington EK. Studies of retrograde memory: a long-term view. *Proc. Natl. Acad. Sci.* 1996; 93: 13523–13526.
2. Baxendale S. Amnesia in temporal lobectomy patients: historical perspectives and review. *Seizure* 1998; 7: 15–24.
3. Squire LR. Memory and the hippocampus: a synthesis from findings with rats, monkeys, and humans. *Psychol. Rev.* 1992; 99: 195–231.
4. Nadel L, Moscovitch M. Memory consolidation, retrograde amnesia and the hippocampal complex. *Curr. Opin. Neurobiol.* 1997; 7: 212–227.
5. Lezak M. Memory tests. In: *Neuropsychology Assessment*, third edn. Oxford University Press, New York; 1985: 429–498.
6. Kopelman MD, Wilson BA, Baddeley AD. The autobiographical memory interview: a new assessment of autobiographical and personal semantic memory in amnesic patients. *J. Clin. Exp. Neuropsychol.* 1989; 11: 724–744.
7. Reed JR, Squire LR. Retrograde amnesia for facts and events: findings from four new cases. *J. Neurosci.* 1998; 18: 3943–3954.
8. Viskontas IV, McAndrews MP, Moscovitch M. Remote episodic memory deficits in patients with unilateral temporal lobe epilepsy and excisions. *J. Neurosci.* 2000; 20: 5853–5857.
9. Warrington EK, Duchon LW. A re-appraisal of a case of persistent global amnesia following right temporal lobectomy: a clinico-pathological study. *Neuropsychologica* 1992; 30: 437–450.

## Cerebral lupus in patients whilst on treatment for lupus nephritis with cyclosporine

M. Hussein MB BS (LONDON) FRCP (LONDON),  
J. Mooij MD PHD, H. Roujoleh MD CES

Department of Nephrology, Al Hada Armed Forces Hospital, P.O. Box 1347, Taif, Saudi Arabia

**Summary** Two young female patients who were treated for severe lupus nephritis with cyclosporine, developed, while the renal parameters remained stable, signs of cerebral lupus (bilateral papilloedema and cranial nerve palsy in one patient and grand mal seizures in the second). The first patient responded to plasmapheresis and i.v. cyclophosphamide, and the second to temporary increase in prednisone with anti-convulsant medication.

Both case histories suggest that cyclosporine, whilst controlling lupus nephritis, was not able to prevent serious attacks of cerebral lupus. This discrepancy might be related to relative inability of the drug to reduce antibody production or to the existence of heterogeneous pathogenetic mechanisms of lupus in different organ systems.

© 2002 Published by Elsevier Science Ltd.

*Journal of Clinical Neuroscience* (2003) 10(1), 104–106

© 2002 Published by Elsevier Science Ltd.

DOI:10.1016/S0967-5868(02)00260-6

**Keywords:** cerebral lupus, lupus nephritis, cyclosporine

Received 7 November 2001

Accepted 27 February 2002

Correspondence to: Dr. Magdi. M. Hussein MB, BS (London), FRCP (London), Head, Department of Nephrology and Dialysis, Al Hada Armed Forces Hospital, P.O. Box 1347, Taif, Saudi Arabia. Tel.: +966-2-7541610, ext. 2091/2090; Fax: +966-2-7541218; E-mail: magdihussein@hotmail.com