

while avoiding injury to the normal spinal cord. The tumour in our case included dense fibrous tissue, and use of CUSA did succeed.

REFERENCES

1. Coor P, Benningfield SJ. Magnetic resonance imaging of an intradural spinal lipoma: a case report. *Clin Radiol* 1989; 40: 216–218.
2. Fan CJ, Veerapen RJ, Tan CT. Case report: subdural spinal lipoma with posterior fossa extension. *Clin Radiol* 1989; 40: 91–94.
3. Fujiwara F, Tamaki N, Nagashima T, Nakamura M. Intradural spinal lipomas not associated with spinal dysraphism: a report of four cases. *Neurosurgery* 1995; 6: 1212–1215.
4. Kujas M, Sichez JP, Lalam TF, Poirier J. Intradural spinal lipoma of the conus medullaris without spinal dysraphism. *Clin Neuropathol* 2000; 19: 30–33.
5. Mori K, Kamimura Y, Uchida Y, Kurisaka M, Eguchi S. Large intramedullary lipoma of the cervical cord and posterior fossa. *J Neurosurg* 1986; 64: 974–976.
6. Narazaki O, Hanai T, Kusuhara K, Kawanami T, Nakagaki H. A case of cervical spinal cord lipoma with extension into the posterior fossa. *Rinsho-sinkeigaku* 1984; 11: 1086–1090.
7. Patwardhan V, Patanakar T, Armao D, Mukherji SK. MR imaging findings of intramedullary lipomas. *AJNR* 2000; 174: 1792–1793.
8. Lee M, Rezaei AR, Abbott R, Coelho DH, Epstein FJ. Intramedullary spinal cord lipomas. *J Neurosurg* 1995; 82: 394–400.
9. McGillicuddy GT, Shucart W, Kwan ESK. Intradural spinal lipomas. *Neurosurgery* 1987; 3: 343–346.
10. Rappaport ZH, Tadmor R, Brand N. Spinal intradural lipoma with intracranial extension. *Child's Brain* 1982; 9: 411–418.
11. White WR, Fraser RAR. Cervical spinal cord lipoma with extension into the posterior fossa. *Neurosurgery* 1983; 4: 460–462.

Nocardia brain abscess misinterpreted as cerebral infarction

W. Borm^{1,2} MD, M. Gleixner¹ MD

¹Neurosurgical Department, Klinikum Aschaffenburg, Germany,

²Neurosurgical Department, University of Ulm, BKH Günzburg, Germany

Summary We present the case of a non-immunocompromised man with right-sided hemiparesis and aphasia thought to be caused by cerebral infarction, but which in the later clinical course evolved to be a nocardia brain abscess that needed surgical intervention. Misinterpretation of imaging combined with the absence of clinical signs of infection led to inadequate primary treatment.

© 2002 Elsevier Science Ltd. All rights reserved.

Journal of Clinical Neuroscience (2003) 10(1), 130–132

© 2002 Elsevier Science Ltd. All rights reserved.

DOI:10.1016/S0967-5868(02)00121-2

Keywords: brain abscess, cerebral infarction, nocardia infection

Received 28 December 2001

Accepted 14 February 2002

Correspondence to: Wolfgang Börm MD, Neurosurgical Department, University of Ulm/Günzburg, Ludwig Heilmeyer Strasse 2, 89312 Günzburg, Germany. Tel.: +49-8221-962252; Fax: +49-8221-962110; E-mail: wolfgang.boerm@medizin.uni-ulm.de

INTRODUCTION

Modern imaging techniques and standard laboratory tests combined with the clinical presentation make it possible to establish a correct diagnosis and treatment in most patients referred with an

acute focal neurological deficit. However, misinterpretation does occur in certain circumstances, e.g. if unfamiliarity with neuro-radiological studies is present or if in cases of uncertain findings in computed tomographic (CT) studies the investigators rely on the clinical status of a patient. This may lead to fatal misdiagnosis and subsequently to treatment failure. The differential diagnosis of cerebral ischemia versus early infection of the brain is sometimes not easy to establish, especially in cases with negative laboratory findings, which are not unusual in early brain infection.¹ We present the case of a man with an acute focal neurological deficit and no signs of infection where misinterpretation of initial CT studies of the brain was followed by inadequate treatment of an early brain infection.

CASE REPORT

A 56-year-old non-immunocompromised man experienced acute right-sided hemiparesis and aphasia without any signs of infection. He was treated in a neurological clinic for brain infarction after a CT scan performed at a non-specialised general hospital revealed a hypodense area with slight contrast enhancement thought to be postinfarction luxury perfusion in the left frontotemporal area (Fig. 1). No signs of infection were identified in the laboratory tests including white blood cell count, C-reactive protein, and sedimentation rate.

His clinical course was uneventful with good restitution of neurological function within a few days and he was transferred to a rehabilitation unit after 3 weeks of medical treatment. During his rehabilitation course, 2 months after the initial event, the patient complained of headache, aphasia and intermittent hemiparesis on the right side. He developed focal seizures. CT and magnetic resonance imaging (MRI) scans now showed a $6 \times 3 \times 3$ cm lesion in the left frontotemporal region which enhanced markedly with contrast agents and appeared to be polycystic (Figs. 2 and 3, upper). No signs of infection, either clinically or in laboratory investigations, were present at this time. The diagnosis of brain abscess was now established. The patient was referred to our department for operation.

At operation, after osteoplastic frontotemporal craniotomy and durotomy, a completely encapsulated, firm abscess was found with two lobuli. Total extirpation was performed. Cultures showed *Nocardia asteroides* (Fig. 3, lower). An extensive search for the focus of infection including a thoracic CT scan revealed signs of a clinically silent pneumonia. Postoperative antibiotic treatment with sulfonamides and trimethoprim for 3 weeks was initiated. The postoperative course was excellent with complete recovery of neurological deficits. At follow-up after 24 months, the patient was free of complaints and neurologically intact.

DISCUSSION

This case demonstrates the differential diagnostic problem of cerebral infarction versus infection of the brain. We assume that in our patient the clinically non-apparent pneumonia was the source of brain abscess formation and the early stroke-like symptoms were caused by cerebritis that evolved into a mature brain abscess. Although secondary abscess formation in infarcted brain areas is documented,² we believe that in this case the initial CT scans were misinterpreted. This may have been caused by inexperienced radiologists who were not familiar enough with interpretation of neuroradiological pathology. Assessment by a neuroradiologist or an early MRI may have, in this case, prevented the inadequate treatment course and may have led to a successful conservative

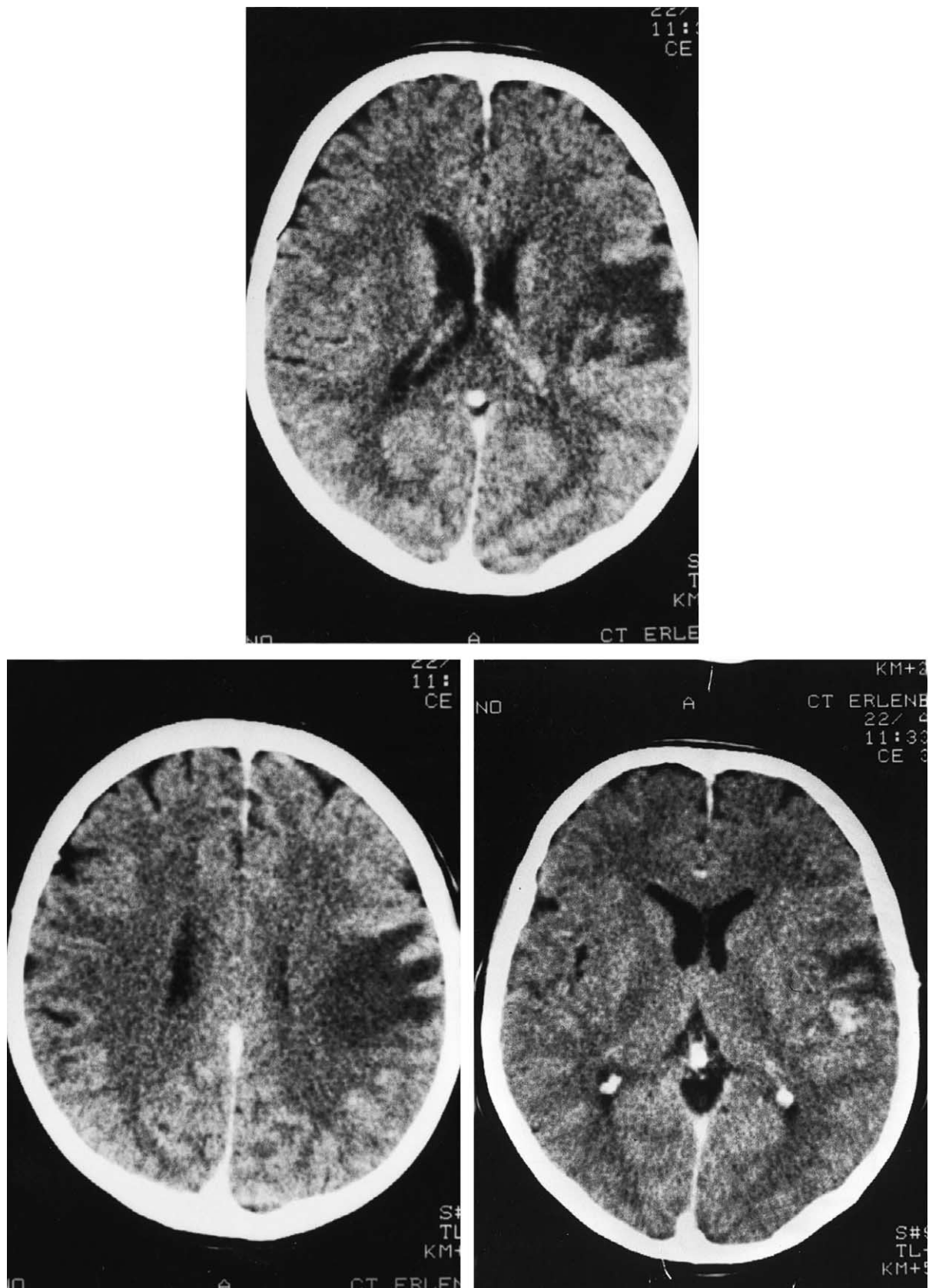


Fig. 1 CT scans after the initial event showing a hypodense area with slight contrast enhancement misinterpreted as infarction with luxury perfusion.

management with antibiotic therapy in this early stage of brain infection.³⁻⁵

Nocardia is known as an opportunistic pathogen that is very likely to metastasise into the central nervous system, with a high

percentage of patients being immunocompromised and with a high mortality ranging between 24 and 50%.^{5,6} According to Mamelak et al. 38% of patients have multiple abscesses leading to a mortality of 66%.⁶ Although in selected cases medical

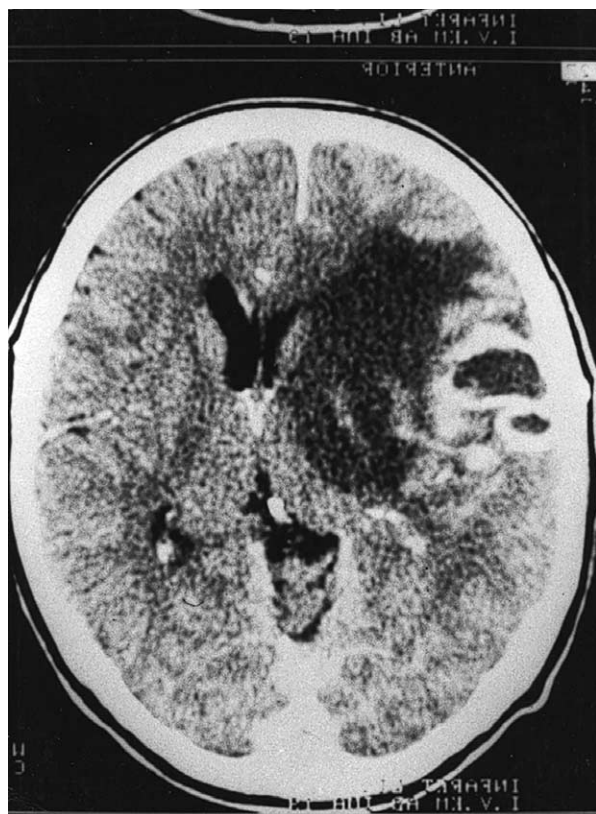

Fig. 2 CT scans obtained 2 months after the initial event showing marked mass effect and ring enhancement consistent with abscess formation. (The figure is mirrored because of the different CT scan orientation.)

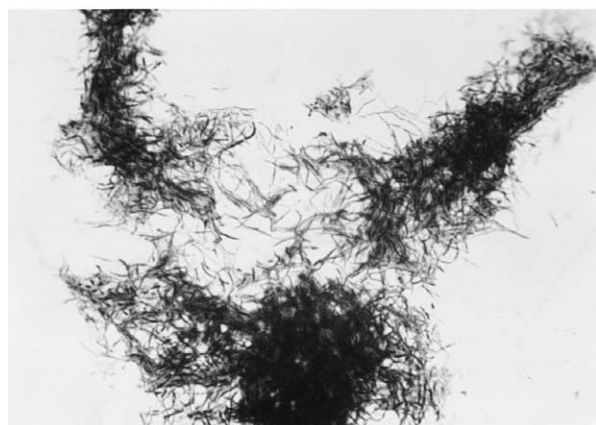
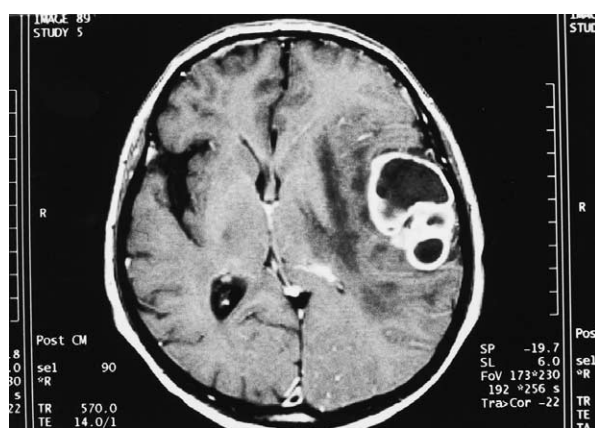

Fig. 3 (Upper) MRI delineating multilobulated abscess; (Lower) photograph of a microscopic specimen of *Nocardia asteroides* (Gram staining, magnification $\times 1000$).

treatment can be successful,^{3,5} surgical extirpation and antibiotic treatment with sulfonamides and trimethoprim, or alternatively minocycline, imipenem or an aminoglycoside in combination with cephalosporins is recommended.^{3,6,7} Whether biopsy and consecutive antibiotic treatment or open abscess extirpation combined with antibiotics is to be preferred depends mainly on the appearance of the lesion and the immune status of the patient. A recent paper by Fleetwood et al. suggested that a more aggressive approach may be more appropriate in the face of a nocardial brain abscess even if an extracranial focus is identified.⁸

In conclusion, early infection of the brain can occur with symptoms of stroke and may be present without laboratory pathology. As misinterpretation of CT imaging in the early infection stages does occur, additional early MRI investigation is recommended, as well as serial imaging at short time intervals in patients with acute stroke-like symptoms and an uncertain diagnosis.

REFERENCES

1. Marchbank ND, Howlett DC, Sallomi DF, Hughes DV. Magnetic resonance imaging is preferred in diagnosing suspected cerebral infections (Letter). *BMJ* 2000; 320: 187.
2. Chen ST, Tang LM, Ro LS. Brain abscess as a complication of stroke. *Stroke* 1995; 26: 696–698.
3. Garlando F, Bodmer T, Lee C, Zimmerli W, Pirovino M. Successful treatment of disseminated nocardiosis complicated by cerebral abscess with ceftriaxone and amikacin: case report. *Clin Infect Dis* 1992; 15: 1039–1040.
4. Schroth G, Kretschmar K, Gawehn J, Voigt K. Advantage of magnetic resonance imaging in the diagnosis of cerebral infections. *Neuroradiology* 1987; 29: 120–126.
5. Peters BR, Saubolle MA, Costantino JM. Disseminated and cerebral infection due to *Nocardia farcinia*: diagnosis by blood culture and cure with antibiotics alone. *Clin Infect Dis* 1996; 23: 1165–1167.
6. Mamelak AN, Obana WG, Flaherty JF, Rosenblum ML. Nocardial brain abscess: treatment strategies and factors influencing outcome. *Neurosurgery* 1994; 35: 622–631.
7. Krone A, Schaal KP, Brawanski A, Schuknecht B. Nocardial abscess cured with imipenem/amikacin and enucleation. *Neurosurg Rev* 1989; 12: 333–340.
8. Fleetwood IG, Embil JM, Ross IB. *Nocardia asteroides* cerebral abscess in immunocompetent hosts: report of three cases and review of surgical recommendations. *Surg Neurol* 2000; 53: 605–610.

Arachnoid granulations in the transverse sinuses of a patient with ocular melanoma

F. Demir Apaydin¹, Orhan Yalçinoğlu¹, Altan Yıldız¹,
Taner Arpacı¹, Meltem Nass Duce¹, Caner Ozer¹,
Celal Bagdatoglu²

¹Department of Radiology, Faculty of Medicine, Mersin University, Mersin, Turkey, ²Department of Neurosurgery, Faculty of Medicine, Mersin University, Mersin, Turkey

Summary Arachnoid granulations show typical imaging features that allow their distinction from dural sinus thrombosis and intrasinus tumor. These features include a mid-lateral transverse sinus location, focality, common adjacent entering superficial veins, origin of attachment, low density on computed tomography (CT), isointensity–hypointensity on T1-weighted magnetic resonance imaging (MRI)