

Arachnoid Cyst Is a Risk Factor for Chronic Subdural Hematoma in Juveniles: Twelve Cases of Chronic Subdural Hematoma Associated with Arachnoid Cyst

KENTARO MORI, TAKUJI YAMAMOTO, NAOAKI HORINAKA, and MINORU MAEDA

ABSTRACT

Chronic subdural hematoma (CSDH) tends to occur in elderly patients with a history of mild head injury at a few months prior to the onset of symptoms. Intracranial arachnoid cyst is believed to be congenital and sometimes becomes symptomatic in pediatric patients. These two distinct clinical entities sporadically occur in the same young patient. Twelve of 541 cases of CSDH surgically treated in our institution had associated arachnoid cyst. The clinical and radiological characteristics of the cases of CSDH associated with arachnoid cyst were retrospectively analyzed and compared with those of CSDH without arachnoid cyst. Arachnoid cysts were located in the middle fossa (eight cases), convexity (two cases), and posterior fossa (two cases). Three cysts were less than 20 mm in diameter. The 12 patients with CSDH and arachnoid cyst (mean age 27.8 ± 19.7 years) were significantly younger ($p < 0.001$) than the patients with CSDH without arachnoid cyst (69.5 ± 13.7 years). Five of the 12 patients were pediatric cases (<15 years old). The clinical symptoms were also significantly different. The most frequent symptom was headache followed by vomiting in the patients with arachnoid cyst, while gait disturbance and hemiparesis predominated in patients without arachnoid cyst. Hematoma evacuation through burr holes improved the symptoms in all patients with arachnoid cyst. We conclude that even a small arachnoid cyst can be a risk factor for CSDH after mild head injury in young patients and symptoms of increased intracranial pressure are common. Hematoma evacuation is adequate at first operation. If the preoperative symptoms persist, additional arachnoid cyst surgery should be considered. The present results also suggest that CSDH formation may be preceded by subdural hygroma caused by the rupture of arachnoid cyst.

Key words: arachnoid cyst; chronic subdural hematoma; head injury

INTRODUCTION

INTRACRANIAL ARACHNOID CYST is one of the most common clinical entities in daily neurosurgical practice. Arachnoid cysts are generally considered to be congenital and tend to occur in children (Shaw and Alford, 1977; Rengachary et al., 1978; Wester, 1992). Arachnoid cyst

most frequently occurs in the middle fossa, followed by the posterior fossa, convexity, and suprasellar regions (Shaw and Alford, 1977; Sato et al., 1983). Headache, convulsion, deformity of the cranium with bulging and thinning of the adjacent bone, focal neurological deficit, and mental retardation are known symptoms of intracranial arachnoid cyst (Rengachary et al., 1978; Sato et al.,

1983). Computed tomography (CT) and magnetic resonance (MR) imaging have increased the detection of incidental asymptomatic arachnoid cyst. Most symptomatic arachnoid cysts indicated for surgical intervention occur in pediatric patients because the cyst manifests as a space occupying lesion in the developing brain (Galassi et al., 1980; Sato et al., 1983; Arai et al., 1996). In addition to cysts manifesting as chronically developing symptoms, subdural or intracystic bleeding from bridging vein or blood vessels sporadically occur around arachnoid cyst after head injury (Galassi et al., 1980; Hara et al., 1984; Page et al., 1987, 1988; Yokoyama et al., 1989; Servadei et al., 1993; Oka et al., 1994; Albuquerque and Giannotta, 1997; Parsch et al., 1997). Middle cranial fossa arachnoid cyst is now recognized as one of the causes of chronic subdural hematoma (CSDH) after head injury, especially in young people. CSDH was generally believed to occur in elderly people at several weeks after head injury (Markwalder, 1981). The association of these two distinct clinical entities in young patients may suggest a possible etiology of CSDH.

This study analyzed the clinical features of 12 cases of CSDH associated with arachnoid cyst among 541 consecutive cases treated surgically from 1987 to 2000, to investigate arachnoid cyst as a risk factor for CSDH in young patients, the etiology of CSDH, and the treatment of such cases.

MATERIALS AND METHODS

Five hundred and forty-one consecutive patients with CSDH were treated by hematoma evacuation and drainage through cranial burr holes in the Department of Neurosurgery, Juntendo University Izunagaoka Hospital from January 1987 to June 2000. Twelve of these 541 patients, six males and six females aged from 5 to 71 years old, had CSDH associated with arachnoid cyst (Table 1). CT and/or MR imaging were performed in all patients to confirm the diagnosis. The arachnoid cysts were located in the middle fossa in eight cases, in the convexity in two cases, and in the posterior fossa in two cases. Eight patients had a definite history of mild head injury and two patients had a history of operation for arachnoid cyst, cystoperitoneal shunting in one case and cyst opening in the other.

All hematomas were evacuated and irrigated with normal saline through two burr holes and closed system subdural drainage was continued for one or two days after the operation. Patient 4 underwent cystoperitoneal shunting surgery after the drainage surgery because the arachnoid cyst caused mass effect to the surrounding brain. The preoperative hematoma thickness and the postoperative

hematoma thickness (1 week after operation) were measured by CT to calculate the re-expansion rate as (preoperative hematoma thickness – postoperative hematoma thickness)/preoperative hematoma thickness \times 100 (%). The clinical and radiological data of the patients of CSDH with arachnoid cyst were compared with the data of the patients of CSDH without arachnoid cyst. Data are given as the mean \pm standard deviation. Results were analyzed for statistical significance using the unpaired Student's *t* test and Pearson's χ^2 -test with $p < 0.05$ considered significant.

RESULTS

Table 2 compares the patients with CSDH with and without arachnoid cyst. The patients with CSDH and arachnoid cyst (mean age 27.8 ± 19.7 years) were significantly younger ($p < 0.001$) than the patients with CSDH without arachnoid cyst (mean age 69.5 ± 13.7 years). Five of the eight pediatric patients (<15 years old) with CSDH had arachnoid cysts. The incidence of association with arachnoid cysts in pediatric patients (62.5%) was significantly higher ($p < 0.001$) than in adult patients (1.3%). Sex, mean interval from trauma to hematoma evacuation, preoperative hematoma thickness, and the locations of CSDH were not statistically different between the patients with and without arachnoid cyst.

The incidence of high CT density hematoma in the patients with arachnoid cyst was significantly higher ($p < 0.01$) than that of the patients without arachnoid cyst. The clinical presentations were quite different between the two groups. The most frequent symptom was headache (83.3%) followed by vomiting (33.3%) and hemiparesis (33.3%) in the patients with arachnoid cyst. The most frequent symptom was gait disturbance (63.5%) followed by hemiparesis (58.0%) in the patients without arachnoid cyst. These symptomatic differences were statistically significant ($p < 0.05$). The reexpansion rate of the brain at one week after burr hole irrigation was $75.3 \pm 13.1\%$ in the patients with arachnoid cyst and was significantly higher ($p < 0.01$) than that in the patients without arachnoid cyst.

All patients with CSDH and arachnoid cyst became symptom-free after the burr hole irrigation. Follow-up CT or MR imaging showed spontaneous disappearance of arachnoid cyst in one patient (patient 11) and decreased size of the arachnoid cyst in two patients (patients 8 and 9).

ILLUSTRATIVE CASES

Patient 3

A 17-year-old man complained of headache and vomiting following mild head injury due to a traffic accident

TABLE 1. CLINICAL CHARACTERISTICS OF 12 PATIENTS WITH CHRONIC SUBDURAL HEMATOMA ASSOCIATED WITH INTRACRANIAL ARACHNOID CYST

Patient no.	Age/sex	Trauma	Interval from trauma to operation of CSDH		Location of CSDH	Symptoms	Location of AC (Galassi classification)	Size of AC	Radiologically demonstrated intracystic hematoma		Treatment	Outcome
			CSDH	CSDH								
1	11/F	—	—	R	Headache, vomiting	R–middle fossa (type I)	32 × 15mm	not clear (CT)	Hematoma irrigation	Good		
2	33/F	AC operation (CP shunt)	4w	L	Headache, hemiparesis	posterior fossa	40 × 35mm	negative (CT)	Hematoma irrigation	Good		
3	17/M	Traffic accident	18w	R	Headache, vomiting	R–middle fossa (type I)	30 × 25mm	positive (MR)	Hematoma irrigation	Good		
4	9/F	Falling	5w	Bilateral	Headache, vomiting	R–middle fossa (type II)	43 × 28mm	positive (MR)	Hematoma irrigation	Good		
5	39/F	Struck by person	9w	L	Hemiparesis	L–convexity	16 × 10mm	positive (MR)	Hematoma irrigation	Good		
6	12/M	AC operation (cyst opening)	11w	R	None	R–middle fossa (type II)	29 × 26mm	negative (MR)	Hematoma irrigation	Good		
7	41/M	Falling	4w	Bilateral	Headache, vomiting	L–middle fossa (type I)	33 × 17mm	negative (MR)	Hematoma irrigation	Good		
8	5/M	Falling	16w	L	Headache	L–middle fossa (type I)	42 × 17mm	positive (MR)	Hematoma irrigation	Good		
9	71/F	—	—	L	Headache, gait disturbance	L–middle fossa (type I)	24 × 20mm	positive (MR)	Hematoma irrigation	Good		
10	43/F	Falling	8w	R	Headache, hemiparesis	L–convexity	16 × 10mm	negative (CT)	Hematoma irrigation	Good		
11	14/M	Falling	4w	L	Headache, hemiparesis	L–middle fossa (type I)	15 × 7mm	positive (MR)	Hematoma irrigation	Good		
12	39/M	Traffic accident	12w	R	Headache	Posterior fossa	27 × 21mm	negative (CT)	Hematoma irrigation	Good		

M, male; F, female; AC, arachnoid cyst; CP, cystoperitoneal; w, week; R, right; L, left; Galassi classification, Galassi et al. (1980); CT, computed tomography; MR, magnetic resonance.

TABLE 2. COMPARISON OF PATIENTS WITH CHRONIC SUBDURAL HEMATOMA WITH OR WITHOUT INTRACRANIAL ARACHNOID CYST

		<i>CSDH with AC</i> (n = 12)	<i>CSDH without AC</i> (n = 529)	p value
Age (years)		27.8 ± 19.7	69.5 ± 13.7	<0.001 (<i>t</i> test)
Sex (male/female)		6:6	376:153	NS (χ^2 test)
Interval from trauma to operation (week)		8.3 ± 4.4	8.5 ± 4.9	NS (<i>t</i> test)
Hematoma thickness (mm)		16.6 ± 6.5	19.5 ± 5.7	NS (<i>t</i> test)
Location of CSDH	Left	41.7%	51.6%	NS (χ^2 test)
	Right	41.7%	30.8%	
	Bilateral	16.6%	17.6%	
CT density of CSDH	High	58.3%	19.5%	<0.01 (χ^2 test)
	Low	16.7%	33.6%	
	Iso	25.0%	27.6%	
	Niveau	0%	19.3%	
Clinical symptoms	Gait disturbance	8.3%	63.5%	<0.001 (χ^2 test)
	Hemiparesis	33.3%	58.0%	NS
	Headache	83.3%	37.4%	<0.05
	Dementia	8.3%	25.1%	NS
	Incontinence	0%	17.6%	NS
	Vomiting	33.3%	2.8%	<0.05
Reexpansion rate of CSDH (%)		75.3 ± 13.1	53.4 ± 19.6	<0.01 (<i>t</i> test)

Data are expressed as mean ± standard deviation.

CSDH, chronic subdural hematoma; AC, arachnoid cyst; CT, computed tomography; *t* test, Student's nonpaired *t* test; χ^2 test, Pearson's chi-square test; NS, not significant.

18 weeks previously. He showed no neurological deficits. CT revealed a high density subdural hematoma in the right frontal convexity but the presence of arachnoid cyst in the right middle fossa (sylvian fissure) was not clear because of the similar density to the CSDH (Fig. 1 upper). MR imaging clearly showed the arachnoid cyst in the right sylvian fissure and the presence of the intracystic hematoma (Fig. 1 lower). The CSDH was irrigated through burr holes and his symptoms disappeared.

Patient 5

A 39-year-old woman was admitted with right mild hemiparesis following mild injury due to being struck by her husband 9 weeks previously. CT showed a low density subdural hematoma and a small (16 × 10 mm) arachnoid cyst with an adjacent bony indentation in the left convexity (Fig. 2 upper). MR imaging showed intracystic

hematoma and continuity to the subdural hematoma (Fig. 2 lower). The CSDH was irrigated through two burr holes and her symptom disappeared immediately afterward. However, 4 years later she suffered headache and left hemiparesis following mild head injury due to falling on the road 8 weeks previously. CSDH had recurred on the right, but the arachnoid cyst in the right convexity had not changed. Her symptoms disappeared after burr hole irrigation. Unfortunately, she did not attend our outpatient clinic after discharge, so we could not follow up the size of the arachnoid cyst after the treatment for CSDH.

Patient 11

A 14-year-old boy was admitted with headache and right hemiparesis following mild head injury due to falling during physical training 4 weeks previously. CT showed a high density subdural hematoma in the left

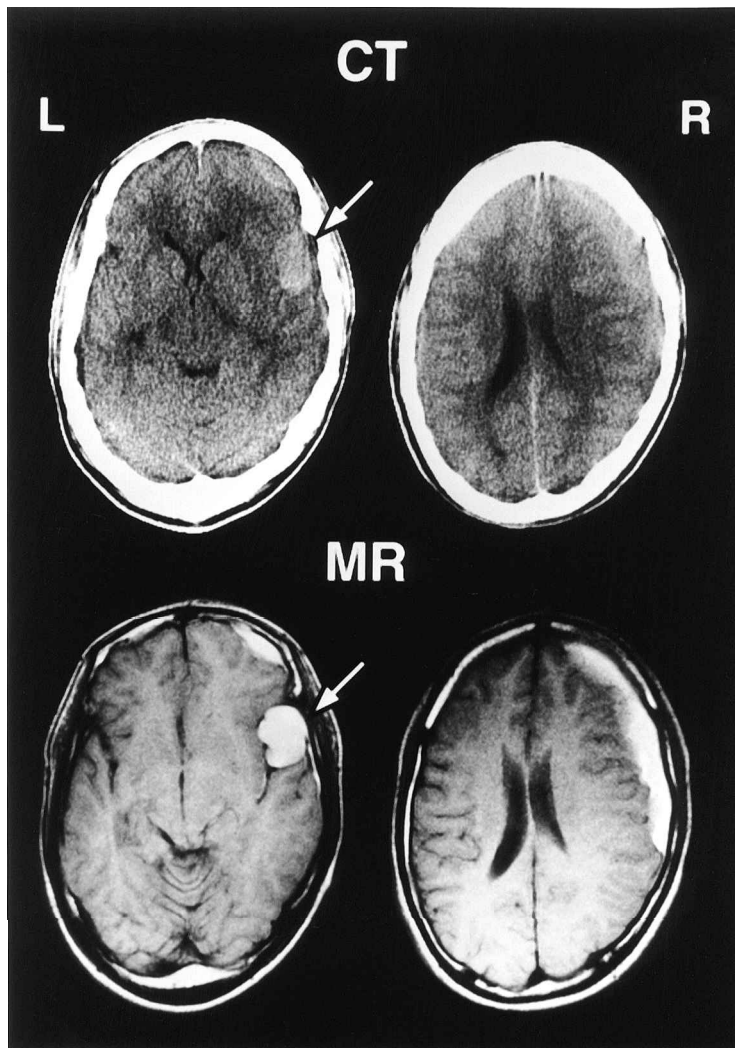


FIG. 1. Patient 3. Upper: CT scans showing a high density subdural hematoma in the right frontal region and a high density round mass lesion in the right sylvian fissure (arrow). Lower: MR images revealing the presence of blood in the arachnoid cyst in the right sylvian fissure (arrow).

frontal and temporal region (Fig. 3 upper). CT also showed a small bony indentation in the tip of the left middle fossa but the presence of arachnoid cyst was not clear because of the intracystic hematoma. His symptoms disappeared immediately after CSDH evacuation through burr holes. Postoperative MR imaging revealed a small (15×7 mm) arachnoid cyst in the tip of the left middle fossa (Fig. 3 lower). Follow-up MR imaging taken 4 months after the irrigation surgery showed that this small arachnoid cyst had disappeared.

Patient 6

A 12-year-old boy was admitted with asymptomatic arachnoid cyst in the right middle fossa. MR imaging

showed a Galassi type II arachnoid cyst in the right middle fossa (Fig. 4 upper). The cyst had caused mass effect to the surrounding brain. The cyst was opened and communication formed between the cyst and the basal cistern through right frontotemporal craniotomy on March 24, 1994. Postoperative MR imaging taken 1 week after the surgery showed formation of bilateral thin subdural effusions (Fig. 4 middle). Follow-up MR imaging taken 11 weeks after the cyst opening revealed the formation of CSDH on the right and compression of the right lateral ventricle (Fig. 4 lower). The patient was symptom-free. The hematoma was irrigated through two burr holes and he was discharged without complications.

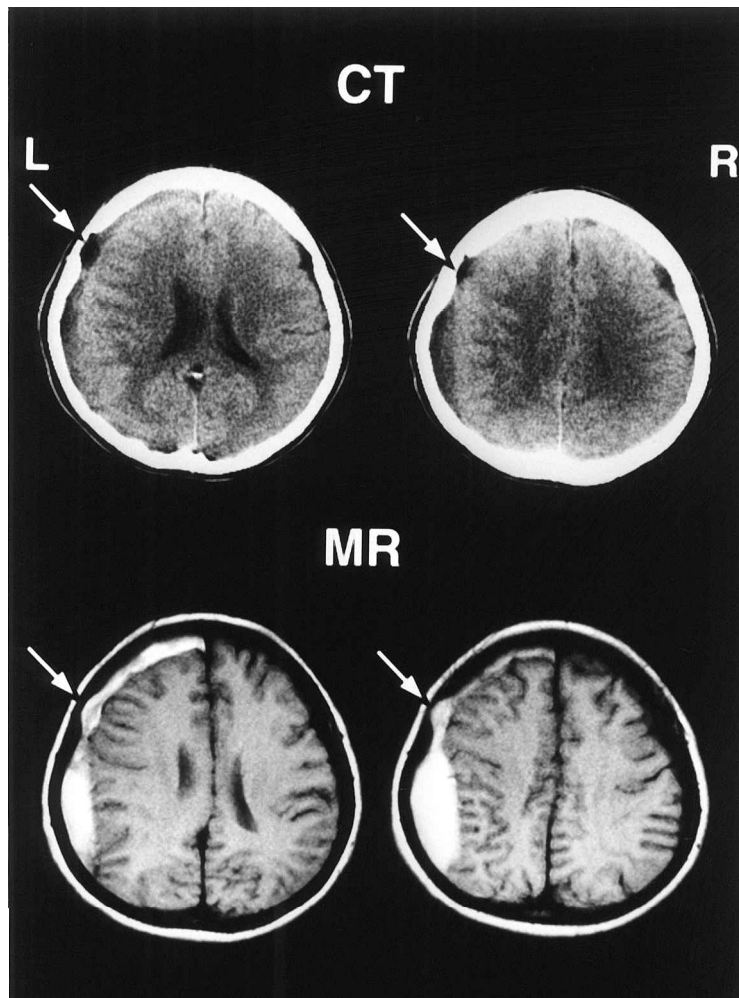


FIG. 2. Patient 5. Upper: CT scans showing a low density subdural hematoma in the left frontoparietal region and a small arachnoid cyst with an adjacent bony indentation in the left frontal convexity (arrow). Lower: MR images revealing the presence of blood in the arachnoid cyst (arrow).

DISCUSSION

The etiology of CSDH is not completely understood. Traumatic subdural effusion is widely accepted as a precursor stage in the formation of CSDH (Ohno et al., 1987; Murata, 1993). Arachnoid tear is also accepted as a causative factor in the development of traumatic subdural effusion (Naffziger, 1924; Stone et al., 1981), supported by the observation that CSDH tends to occur in elderly people because brain atrophy causes enlargement of the subarachnoid space and stretching of the bridging veins, and these preexisting conditions facilitate tearing of the arachnoid membrane and leakage of bloody cerebrospinal fluid (CSF) into the subdural space after mild head in-

jury (Markwalder, 1981). CSF with or without blood leaks into the subdural space then facilitates the formation of the "outer membrane" under the dura mater, which forms internal capillaries or sinusoids (Yamashita and Yamamoto, 1984; Hasegawa et al., 1992). These blood vessels in the outer membrane are fenestrated and allow plasma fluid leakage and resultant enlargement of the subdural effusion (Sato and Suzuki, 1975; Mori et al., 1996, 1998; Mori and Maeda, 2000). Bleeding then occurs repeatedly from the capillaries with degenerating endothelium accompanied by local hyperfibrinolysis, which is one of the causes of the development of effusions into CSDH (Ito et al., 1976, 1978).

Arachnoid cyst is also known to be a predisposing fac-

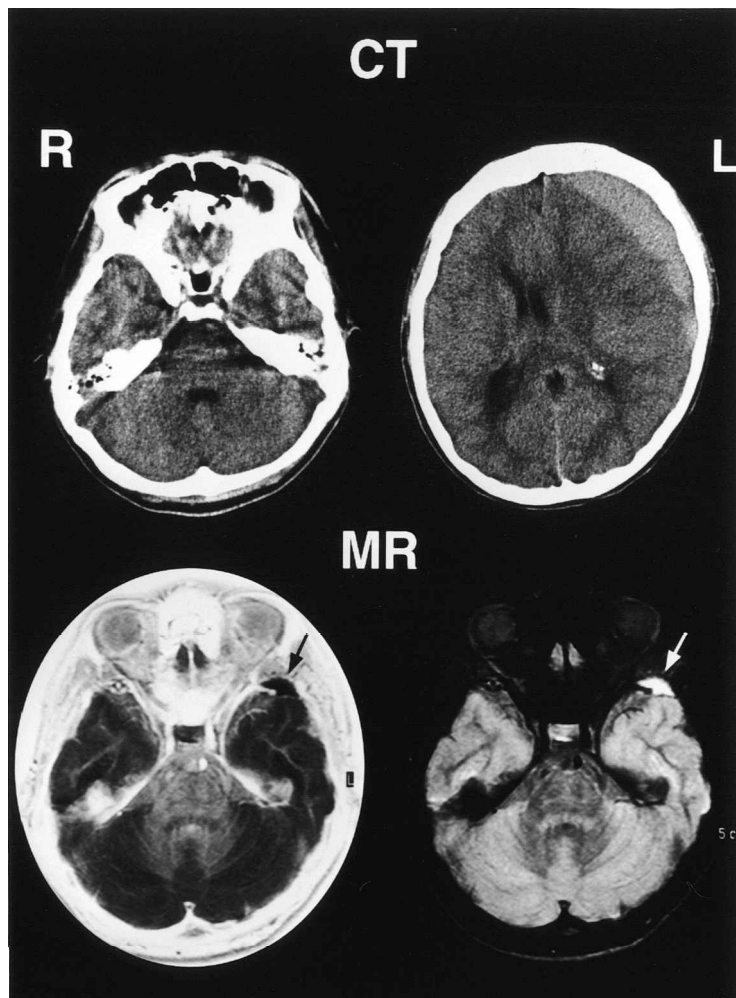


FIG. 3. Patient 11. Upper: CT scans showing a high density subdural hematoma in the left frontal region, and a small bony indentation in the tip of the left middle fossa. Lower: Postoperative MR images revealing the presence of a small arachnoid cyst in the tip of the left middle fossa.

tor for CSDH after mild head injury. Arachnoid cysts are generally believed to be congenital whereas CSDHs tend to occur in elderly people. Association of these two distinct clinical entities indicates involvement in the etiology of CSDH. Arachnoid cyst is occasionally associated with subdural effusion, which is generally thought to result from tearing of the outer wall of the arachnoid cyst after head injury (Albuquerque and Giannotta, 1977; Parsch et al., 1997). The rupture of arachnoid cyst can even occur spontaneously (Rakier and Feinsod, 1995). Tearing of the outer wall of the arachnoid cyst is associated with subdural and/or intracystic hemorrhage caused by rupture of bridging veins, unsupported blood vessels around the cyst wall, and leptomeningeal vessels in the

base of the cyst (Galassi et al., 1980; Aoki and Sakai, 1990). The present study found no neuroimaging evidence of intracystic hematoma in five of the 12 cases, but we cannot exclude the presence of slight intracystic bleeding undetected by CT or MR imaging in these five cases. Communication of the cyst, and CSDH through the tear in the arachnoid cyst wall has been identified by intraoperative findings and technetium-99m scintigraphy (Galassi et al., 1980; Yokoyama et al., 1989). Animal experimental studies have shown that CSF and blood fibrin in the subdural space form an active fibroblastic membrane (premature outer membrane) beneath the dura mater (Watanabe et al., 1972; Apfelbaum et al., 1974). These observations support the importance of arachnoid

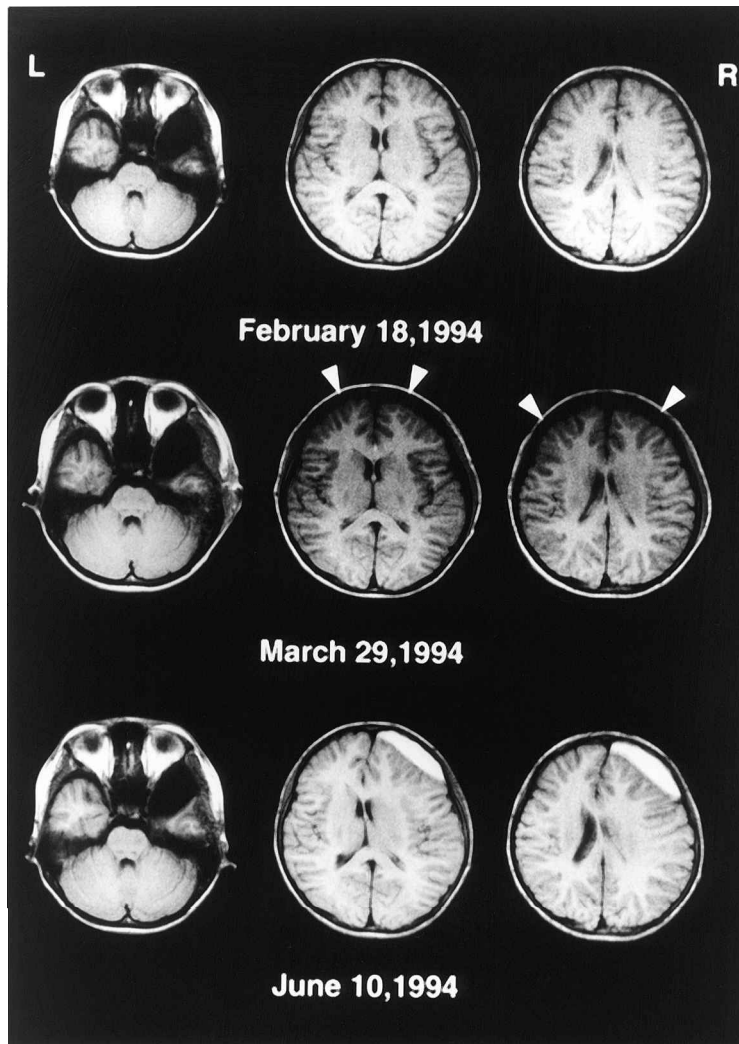


FIG. 4. Patient 6. Upper: MR images showing a Galassi type II arachnoid cyst in the right middle fossa. Middle: Postoperative MR images at 1 week after cyst opening revealing the formation of bilateral thin subdural effusions (arrowheads). Lower: Follow-up MR images at 11 weeks after surgery showing a chronic subdural hematoma in the right frontal region.

tearing as an initial factor in the formation of CSDH. The most common lesion is CSDH ipsilateral to the arachnoid cyst, but CSDH may occur bilaterally or even contralaterally (Page et al., 1987; Parsch et al., 1997). The present study demonstrated the occurrence of CSDH associated with arachnoid cyst, followed by the formation of bilateral subdural effusions after cyst opening in the middle fossa. These bilateral subdural effusions might be the reason why arachnoid cyst is sometimes associated with the formation of bilateral or even contralateral CSDH. The present series included two cases of bilateral CSDHs and one case of contralateral CSDH, as well as cases of CSDH associated with arachnoid cyst in the pos-

terior fossa. Bilateral and contralateral CSDH were found in two of seven cases of arachnoid cyst in the middle fossa. The arachnoid cyst is less compliant than normal brain and so provides reduced intra-calvarial cushioning following minor trauma, and consequently hemorrhage is likely to occur from the ipsilateral or contralateral bridging veins resulting in bilateral or contralateral CSDH (Page et al., 1987). The association of CSDH and arachnoid cyst in the posterior fossa might be a coincidence. This study is not conclusive and the subject needs further investigation.

CSDH is generally believed to occur in elderly patients (Markwalder, 1981). Our series of 541 patients with

CSDH included only eight pediatric patients (1.5%) with CSDH, and five of these pediatric cases (62.5%) had associated arachnoid cyst. The high incidence of association with arachnoid cyst in pediatric cases was statistically significant. This observation clearly shows that arachnoid cyst is a risk factor of CSDH in pediatric or young patients. Indeed, tearing of the arachnoid cyst wall after head injury may be a causative factor of CSDH in children. Physicians should give this information to patients with arachnoid cyst and warn them to avoid sports such as boxing and football that have a high incidence of head injury.

Patients with CSDH associated with arachnoid cyst most frequently present with symptoms of increased intracranial pressure (Arai et al., 1996; Parsch et al., 1997; Albuquerque and Giannotta, 1997). In the present study, the most common symptom of patients with CSDH without arachnoid cyst was gait disturbance followed by hemiparesis. In contrast, the most common symptoms of patients with CSDH and arachnoid cyst were headache and vomiting. Headache is more common in young patients because they tend to suffer increased intracranial pressure caused by CSDH. Conversely, if patients with asymptomatic arachnoid cyst show signs of increased intracranial pressure after head injury, the complication of CSDH should be considered (Albuquerque and Giannotta, 1997; Parsch et al., 1997).

Most cases of arachnoid cyst with CSDH have occurred in the middle fossa. In the present series, eight of 12 cases (67%) were located in the middle fossa (sylvian fissure), six of which were Galassi type I and relatively small. The smallest was 15×7 mm and could be recognized only by MR imaging. Another case of small (16×10 mm) arachnoid cyst in the convexity caused two episodes of CSDH after different head injuries. Even small arachnoid cyst in the middle fossa and also the convexity may be a predisposing factor for CSDH. Repeat CT may be required in young patients with CSDH if CT diagnosis is impaired by an isodense arachnoid cyst due to the presence of intracystic hematoma (Hara et al., 1984; Page et al., 1987; Yokoyama et al., 1989). In the present study, the intracystic hematoma was demonstrated radiologically in 6 cases. Furthermore, we recommend MR imaging to detect the presence of small arachnoid cyst in young patients with CSDH.

The treatment of CSDH associated with arachnoid cyst is still controversial. Immediate removal of the membrane of the arachnoid cyst and evacuation of the subdural fluid by craniotomy is recommended (Galassi et al., 1980). In the present series, we performed only

hematoma evacuation through burr holes, except for one case with cystoperitoneal shunting, and the symptoms disappeared in all cases. Spontaneous disappearance or decreased size of the arachnoid cyst after hematoma evacuation does occur (Mori et al., 1995; Rakier and Feinsod, 1995; Albuquerque and Giannotta, 1997). In our cases, such spontaneous reduction of arachnoid cyst after burr hole irrigation was observed. Cyst removal or fenestration at the time of drainage of CSDH is unnecessary in cases of previously asymptomatic arachnoid cyst (Parsch et al., 1997). Most symptoms of CSDH associated with arachnoid cyst are due to increased intracranial pressure. Therefore, we recommend only burr hole irrigation of CSDH without cyst opening at the first operation (Oka et al., 1994; Arai et al., 1996; Parsch et al., 1997). If the preoperative symptoms persist after the evacuation of the CSDH, additional surgery to treat the arachnoid cyst should be considered.

The number of cases of development of subdural hematoma in patients with arachnoid cysts of the middle fossa has increased since the first report (Robinson, 1971). The real incidence of arachnoid cyst complicated by CSDHs and hygromas is not clear. Sixteen cases (2.4%) of associated arachnoid cysts were found among 658 cases of CSDHs and hygromas (Parsch et al., 1997). The present series included 12 cases with arachnoid cyst among 541 cases of surgically treated CSDHs (2.2%). Therefore, arachnoid cyst can only be recognized in 2% of cases of CSDHs. Conversely, 8–17% of cases of arachnoid cyst are complicated by subdural hematoma or hygroma after head injury (Hayashi et al., 1979; Galassi et al., 1980; Arai et al., 1996). Therefore, the association of subdural hematoma is not uncommon. Most cases of arachnoid cyst with CSDH are located in the middle fossa. Our series also showed that the middle fossa is the most frequent site for arachnoid cyst with CSDH. We think that the middle fossa is the most common site for arachnoid cyst because this location is rich in unsupported veins such as the superficial middle cerebral veins that easily bleed after head injury. However, we also found that small arachnoid cyst in the convexity and even in the posterior fossa could also cause CSDH formation in young patients. We should inform patients with arachnoid cyst and their families of the possibility of complication with CSDH and advise care to avoid head injury in daily life regardless of the size and location of the cyst. However, we do not recommend surgical treatment for arachnoid cyst to prevent CSDH, because the present study included two cases of CSDH formation after arachnoid cyst surgery.

REFERENCES

- ALBUQUERQUE, F.C., and GIANNOTTA, S.L. (1997). Arachnoid cyst rupture producing subdural hygroma and intracranial hypertension: case reports. *Neurosurgery* **41**, 951–956.
- AOKI, N., and SAKAI, T. (1990). Intraoperative subdural hematoma in a patient with arachnoid cyst in the middle cranial fossa. *Childs Nerv. Syst.* **6**, 44–46.
- APFELBAUM, R.I., GUTHKELCH, A.N., and SHULMAN, K. (1974). Experimental production of subdural hematomas. *J. Neurosurg.* **40**, 336–346.
- ARAI, H., SATO, K., WACHI, A., et al. (1996). Arachnoid cysts of the middle cranial fossa: Experience with 77 patients who were treated with cystoperitoneal shunting. *Neurosurgery* **39**, 1108–1113.
- GALASSI, E., PIAZZA, G., GAIST, G., et al. (1980). Arachnoid cysts of the middle cranial fossa: a clinical and radiological study of 25 cases treated surgically. *Surg. Neurol.* **14**, 211–219.
- HARA, H., INOUE, T., MATSUO, K., et al. (1984). Unusual computed tomographic findings in a case of arachnoid cyst in the middle cranial fossa. *Surg. Neurol.* **22**, 79–82.
- HASEGAWA, M., YAMASHIMA, T., YAMASHITA, J., et al. (1992). Traumatic subdural hygroma: Pathology and meningeal enhancement on magnetic resonance imaging. *Neurosurgery* **31**, 580–585.
- HAYASHI, T., ANEGAWA, S., HONDA, E., et al. (1979). Clinical analysis of the arachnoid cysts in the middle fossa. *No To Shinkei* **31**, 205–214.
- ITO, H., YAMAMOTO, S., and KOMAI, T. (1976). Role of local hyperfibrinolysis in the etiology of chronic subdural hematoma. *J. Neurosurg.* **45**, 26–31.
- ITO, H., KOMAI, T., and YAMAMOTO, S. (1978). Fibrinolytic enzyme in the lining wall of chronic subdural hematoma. *J. Neurosurg.* **48**, 197–200.
- MARKWALDER, T.M. (1981). Chronic subdural hematomas: a review. *J. Neurosurg.* **54**, 637–645.
- MORI, K., MITSUOKA, H., CHO, K., et al. (1996). Rate constant of gadolinium (Gd)-DTPA transfer into chronic subdural hematomas. *Neurol. Res.* **18**, 126–134.
- MORI, K., ADACHI, K., CHO, K., et al. (1998). Quantitative kinetic analysis of blood vessels in the outer membranes of chronic subdural hematomas. *Neurol. Med. Chir. (Tokyo)* **38**, 697–703.
- MORI, K., and MAEDA, M. (2000). Delayed magnetic resonance imaging with Gd-DTPA differentiates subdural hygroma and subdural effusion. *Surg. Neurol.* **53**, 303–311.
- MORI, T., FUJIMOTO, M., SAKAE, K., et al. (1995). Disappearance of arachnoid cysts after head injury. *Neurosurgery* **36**, 938–942.
- MURATA, K. (1993). Chronic subdural hematoma may be preceded by persistent traumatic subdural effusion. *Neurol. Med. Chir. (Tokyo)* **33**, 691–696.
- NAFFZIGER, H.C. (1924). Subdural fluid accumulations following head injury. *JAMA* **82**, 1751–1752.
- OHNO, K., SUZUKI, R., MASAOKA, H., et al. (1987). Chronic subdural hematoma preceded by persistent traumatic subdural fluid collection. *J. Neurol. Neurosurg. Psychiatry* **50**, 1694–1697.
- OKA, Y., KUMON, Y., OHTA, S., et al. (1994). Chronic subdural hematoma associated with middle fossa arachnoid cysts: three case reports. *Neurol. Med. Chir. (Tokyo)* **34**, 95–99.
- PAGE, A., MOHAN, R.M., and MOHAN, D. (1987). A reappraisal of the relationship between arachnoid cysts of the middle fossa and chronic subdural haematoma. *J. Neurol. Neurosurg. Psychiatry* **50**, 1001–1007.
- PAGE, A.C., MOHAN, D., and PAXTON, R.M. (1988). Arachnoid cysts of the middle cranial fossa predispose to subdural hematoma formation: Fact or fiction? *Acta. Neurochir. Suppl. (Wien)* **42**, 210–215.
- PARSCH, C.S., KRAUß, J., HOFMANN, E., et al. (1997). Arachnoid cysts associated with subdural hematomas and hygromas: analysis of 16 cases, long-term follow-up, and review of the literature. *Neurosurgery* **40**, 483–490.
- RAKIER, A., and FEINSOD, M. (1995). Gradual resolution of an arachnoid cyst after spontaneous rupture into the subdural space. *J. Neurosurg.* **83**, 1085–1086.
- RENGACHARY, S.S., WATANABE, I., and BRACKETT, C.E. (1978). Pathogenesis of intracranial arachnoid cysts. *Surg. Neurol.* **9**, 139–144.
- ROBINSON, R.G. (1971). Congenital cysts of the brain: arachnoid malformations. *Progr. Neurosurg.* **4**, 133–174.
- SATO, K., SHIMOJI, T., YAGUCHI, K., et al. (1983). Middle fossa arachnoid cyst: clinical, radiological, and surgical features. *Childs Brain* **10**, 301–316.
- SATO, S., and SUZUKI, J. (1975). Ultrastructural observations of the capsule of chronic subdural hematoma in various clinical stages. *J. Neurosurg.* **43**, 569–578.
- SERVADEI, F., VERGONI, G., FRATTARELLI, M., et al. (1993). Arachnoid cyst of middle cranial fossa and ipsilateral subdural hematoma: Diagnostic and therapeutic implications in three cases. *Br. J. Neurosurg.* **7**, 249–254.
- SHAW, C.M., and ALFORD, JR., E.C. (1977). Congenital arachnoid cysts and their differential diagnosis, in: *Handbook of Clinical Neurology*. Vol. 31. P.J. Vinken and G.W. Bruyn (eds), North Holland Publishing Company: Amsterdam, pps. 75–136.
- STONE, J.L., LANG, R.G.R., SUGAR, O., et al. (1981). Traumatic subdural hygroma. *Neurosurgery* **8**, 542–550.

CHRONIC SUBDURAL HEMATOMA ASSOCIATED WITH ARACHNOID CYST

WATANABE, S., SHIMADA, H., and ISHII, S. (1972). Production of clinical form of chronic subdural hematoma in experimental animals. *J. Neurosurg.* **37**, 552–561.

WESTER, K. (1992). Gender distribution and sidedness of middle fossa arachnoid cysts: a review of cases diagnosed with computed imaging. *Neurosurgery* **31**, 940–944.

YAMASHITA, T., and YAMAMOTO, S. (1984). How do vessels proliferate in the capsule of a chronic subdural hematoma? *Neurosurgery* **15**, 672–678.

YOKOYAMA, K., TONAMI, N., KIMURA, M., et al. (1989). Scintigraphic demonstration of intracranial communication

between arachnoid cyst and associated subdural hematoma. *Clin. Nucl. Med.* **5**, b350–353.

Address reprint requests to:

Kentaro Mori, M.D., Ph.D.

Department of Neurosurgery

Juntendo University Izunagaoka Hospital

1129 Nagaoka, Izunagaoka-cho, Tagata-gun

Shizuoka 410-2295, Japan

E-mail: KMORI1919@hkg.odn.ne.jp