

# Left Hemiparesis from Atrial Myxoma Emboli

## Finalist, *Cardiology in Review* Fellowship/Residency Clinical Case Contest

BRIAN D. LE, MD,\* JAMES A. DE LEMOS, MD,† MICHAEL A. WAIT, MD,‡ GARY GOFF, MD,§  
JAMES BOEHRER, MD,¶ and GAIL E. PETERSON, MD†

Atrial Myxomas are benign primary tumors of the heart, arising mainly from the left atrium. Clinical signs and symptoms produced by atrial myxomas may be non-specific or result in mechanical obstruction of cardiac function, arrhythmias, and embolization. The authors present a case of a 60-year-old woman who developed total left hemiparesis resulting from left atrial myxoma embolization causing complete occlusion of the right middle cerebral artery.

**Key Words:** Atrial myxoma, Stroke, Embolization, Cardiac tumors, Benign tumors, Familial tumors.

Primary tumors of the heart are rare entities, occurring in 0.05% of patients at necropsy (1). Myxomas are the most common tumors of the heart, representing 83% of primary cardiac tumors (2). Myxomas overwhelmingly affect adults, whereas rhabdomyomas are most commonly found in children (3). Histologically, cardiac myxomas are benign, but they can be lethal based on their anatomic location. The symptoms depend on size, mobility, and location of the tumor. Most patients present with one or more of the quadrad of embolism, intracardiac obstruction, constitutional symptoms, and arrhythmias (4).

We report a case of a 60-year-old female who presented with a dense left hemiparesis. She was later found to have a left atrial myxoma that embolized to the right middle cerebral artery, resulting in cerebral infarction.

### CASE REPORT

A 60-year-old black woman presented to the emergency room complaining of an inability to

move the left side of her body. The night before admission, she experienced severe left arm pain. On awakening in the morning, she developed paralysis of the left upper and lower limbs. She denied numbness, visual changes, headaches, or dysarthria.

Her medical history was significant for longstanding hypertension. She had no history of tobacco, alcohol, or illicit drug abuse. Family history was notable for a mother who died from a myocardial infarction at the age of 83 and a father with longstanding hypertension.

On admission, the patient has a temperature of 97.4°F, a heart rate of 98 beats/min, a blood pressure of 156/87 mm Hg, and a respiratory rate of 16/min breathing room air. Physical examination revealed an alert and oriented woman. She had no jugular venous distention, and her carotid impulse was normal, without bruits. Lungs were clear to auscultation. Cardiac examination revealed a regular rhythm and rate; a loud, widely split S1; and no murmurs or extra heart sounds. She had no lower extremity edema. Her neurologic exam was significant for a right gaze preference and a left facial droop. She neglected her left side. Otherwise, her cranial nerves were intact. She had 0/5 motor strength on the left and normal strength on the right. Her sensation was intact. Deep tendon reflexes were 2+ bilaterally. Babinski was downgoing on the right and equivocal on

\*Cardiology Fellow, †Assistant Professor, Department of Cardiology, ‡Associate Professor, Department of Cardiothoracic Surgery, University of Texas Southwestern, Dallas, Texas; §Internal Medicine, and ¶Cardiologist, St. Paul University Hospital, Dallas, Texas.

Address reprint requests to: Gail E. Peterson, MD, 5323 Harry Hines Blvd., Dallas, TX 75390-9047. E-mail: gail.peterson@utsouthwestern.edu.

the left. She had no clonus and a negative Hoffman's sign.

Her laboratory evaluation was normal with the exception of a potassium concentration of 3.0 mEq/L. Her lipid panel was normal, with an LDL of 89 mg/dL and an HDL of 67 mg/dL. Electrocardiogram revealed normal sinus rhythm. Chest radiograph showed normal cardiac silhouette without masses or infiltrates. Head CT obtained in the emergency department revealed acute infarction of the right temporal lobe cortex and right cerebellar hemisphere without intracranial hemorrhage.

The patient was started on aspirin and Plavix (Sanofi Winthrop Pharmaceuticals, New York, NY). Low-dose ACE inhibitor was initiated for titration of blood pressure. The following day, an MRI scan of the brain confirmed acute infarction in the right basal ganglia and internal capsule with smaller foci of infarction in the right temporal lobe and right cerebellar hemisphere (Fig. 1). A magnetic resonance angiogram revealed complete occlusion of the right middle cerebral artery at its origin without extracranial cerebrovascular stenosis (Fig. 2). Carotid Doppler studies confirmed normal extracranial vessels. A transthoracic echocardiogram demonstrated a large, 9-cm  $\times$  3-cm left atrial mass arising from the interatrial septum and prolapsing into the left ventricle through the mitral valve, consistent with a myxoma (Fig. 3). The patient was scheduled for surgery in 10 days to allow healing of her cerebral infarcts before undergoing cardiopulmonary bypass. On the fifth hospital day, the patient developed altered mental status with worsened left gaze deviation, worrisome for another cerebral embolus. A repeat head CT and MRI failed to reveal any new cerebral lesions. The patient underwent cardiac catheterization on the same day, which revealed normal coronary anatomy. The next morning, she underwent successful surgical resection of the left atrial mass. Biopsy of the mass confirmed a smooth, gelatinous atrial myxoma (Figs. 4 and 5). She had an uneventful recovery with resolution of her right gaze preference and left-sided neglect. Despite intensive physical rehabilitation, she had no improvement in her left hemiparesis.

## DISCUSSION

Atrial myxomas occur more commonly in women (3:1 ratio) and are usually diagnosed between the ages of 50 and 70 years. Approximately

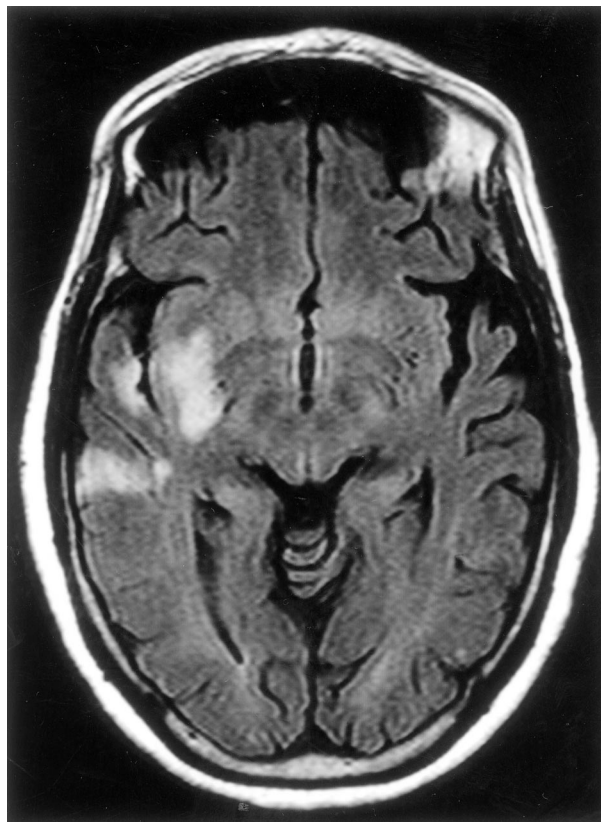


Figure 1. Magnetic resonance imaging showing acute infarctions in the right temporal lobe and internal capsule. Cerebellar and basal ganglia infarctions are not depicted on this image.

75% originate in the left atrium and 15 to 20% in the right atrium. Only 3 to 4% are detected in the left or right ventricle (4,5). The majority are attached to the left atrial septum around the fossa ovalis, occasionally with a component protruding through the atrial septum to the right side. Ninety percent of atrial myxomas are solitary tumors that occur without obvious genetic predisposition. In contrast, multiple atrial myxomas that are associated with facial freckling and endocrine adenoma form a syndrome termed the *Carney complex*. This complex is named for the physician who first described the heritable nature of this disorder (6). Familial myxomas occur in younger patients, and screening of first-degree relatives should be performed.

Myxomas are neoplasms arising from the endocardium. Although not well studied, the rate of growth appears to be relatively rapid compared with other benign neoplasms (7). The majority of myxomas are pedunculated, with a smooth, gelatinous surface. The less common villous or papillary myxomas account for approximately one

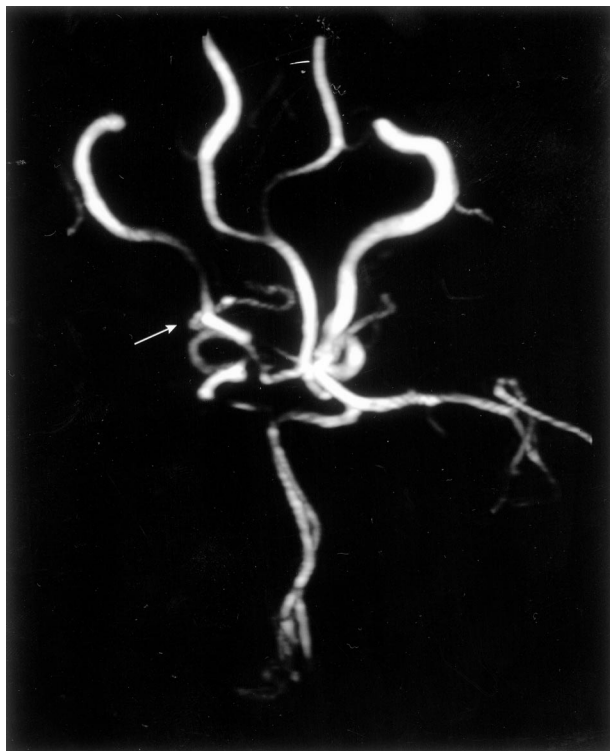

Figure 2. Magnetic resonance angiogram revealing complete occlusion of the right middle cerebral artery at its origin (white arrow).

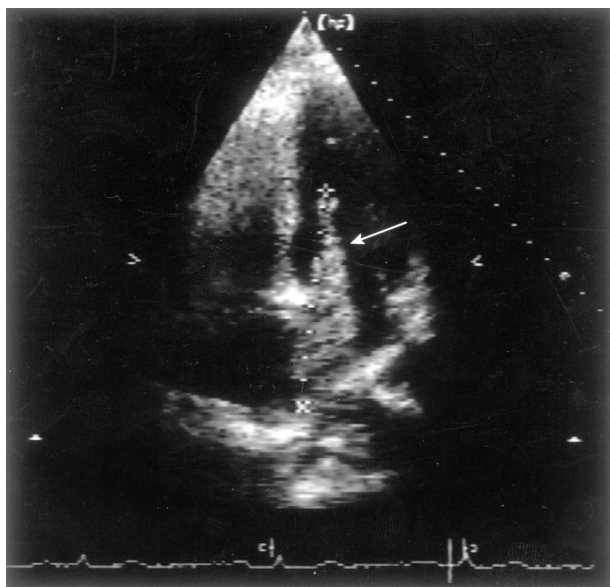


Figure 3. Transthoracic echocardiogram showing 9-cm x 3-cm left atrial myxoma extending from the left atrium into the left ventricle (white arrow).

third of cases and are more friable and fragile, with a tendency to fragment spontaneously (4). Our case was unusual in that the left atrial myxoma was nonvillous with a smooth contour, yet underwent embolization.

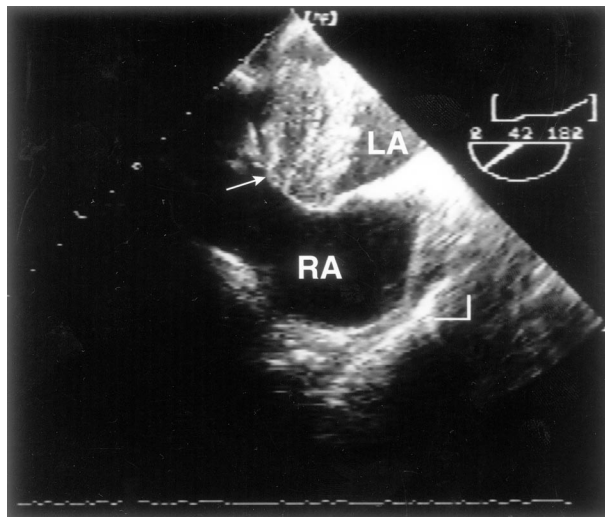


Figure 4. Transesophageal echocardiogram depicting the 0.5-cm stalk of the left atrial myxoma originating from the fossa ovalis (white arrow).

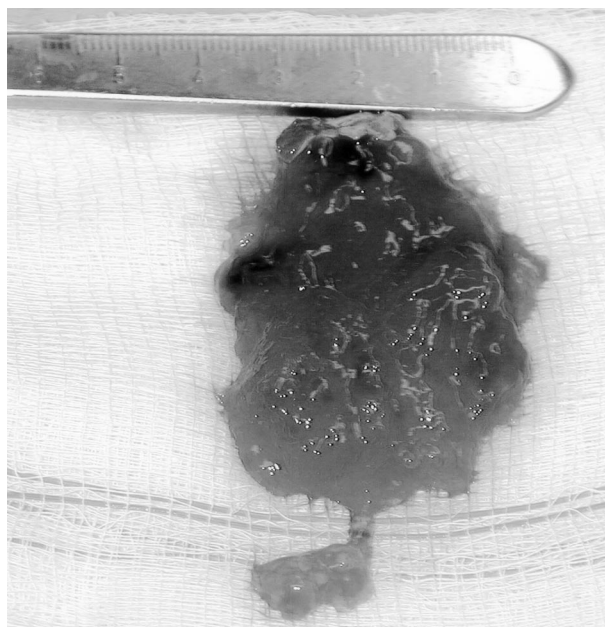


Figure 5. Gross specimen of the excised left atrial myxoma.

Embolism occurs in 10 to 45% of patients with myxomas (2,4,8,9). Since myxomas most commonly arise from the left atrium, systemic embolism is frequent. The majority of cases occur in the cerebral and retinal arteries. Other sites reported include peripheral, aortic, renal, and visceral vessels. In right-sided myxomas, clinically evident embolism is uncommon. However, pulmonary vessel embolism resulting in pulmonary hypertension has been reported (10).

Other clinical presentations include symptoms resulting from obstruction in ventricular inflow, depending on the size of the myxoma. Symptoms include dyspnea, recurrent pulmonary edema, and right heart failure mimicking tricuspid and mitral stenosis. If complete obstruction occurs, syncope and sudden death may ensue. The extent of valvular obstruction may vary with body position (11–13). Atrioventricular block and ventricular tachycardia may be seen from infiltration of the conduction tissue or irritation of the myocardium itself. Lastly, constitutional symptoms of fever, rash, weight loss, fatigue, and myalgia or arthralgia along with anemia and elevated CRP, ESR, and globulin fraction have been noted in many patients, regardless of the size of the tumor.

Systolic and diastolic murmurs are heard in over 50% of patients with myxomas. Murmurs vary according to size, location, mobility of the tumor, and body position. In one third of the patients, a diastolic murmur can be heard 80 to 150 milliseconds after the second heart sound; this sound has been termed the *tumor plop*. In patients with left atrial myxomas, the first heart sound is often loud and widely split due to the delay in mitral valve closure from tumor obstruction (10,14). This finding was noted in our patient.

The diagnosis can be made reliably with transthoracic echocardiography. Echocardiography can determine the location, size, shape, and mobility of the myxoma. Transesophageal echocardiography may be a useful adjunct in detecting the site of insertion and morphologic features of myxomas. The sensitivity of transthoracic echocardiography is 95.2% and TEE 100%, compared to 70% by CT and MRI (15). Unlike ultrasound, CT and MRI may help differentiate tissue composition.

The treatment of choice for atrial myxomas is early surgical resection, which is usually curative. Coronary arteriography in patients over 40 years of age is generally required to rule out concomitant coronary artery disease before undergoing surgery. Surgery is performed to prevent embolic complications and sudden death. The root of the pedicle and the full thickness of the adjacent interatrial septum should be excised, with the resulting atrial defect closed with a pericardial or

Dacron patch if the defect is sufficiently large. Hospital mortality was 3.7% in one series, with a recurrence rate of 4.7% (16,17). The recurrence rate for sporadic myxomas is 1 to 3%; in contrast, the recurrence rate with familial myxomas is at least threefold higher (18). Nevertheless, long-term follow-up with echocardiography is recommended in all cases.

## REFERENCES

1. Reyne K: Frequency of primary tumors of the heart. *Am J Cardiol* 1996;77:107.
2. Blondeau P: Primary cardiac tumors: French studies of 533 cases. *Thorac Cardiovasc Surg* 1990;38(Suppl 2):192–195.
3. Shapiro L: Cardiac tumours: Diagnosis and management. *Heart* 2001;85:218–222.
4. Pinede L, Pierre D, Loire R: Clinical presentation of left atrial cardiac myxoma: A series of 112 consecutive cases. *Medicine* 2001;80:159.
5. Meller J, Teichholz LE, Pichard AD, et al: Left ventricular myxoma: Echocardiographic diagnosis and review of the literature. *Am J Med* 1977;63:816–823.
6. Carney JA: The complex of myxomas, spotty pigmentation, and endocrine overactivity. *Medicine (Baltimore)* 1985;64:270–283.
7. Roudaut R, Gosse P, Dallochio M: Rapid growth of a left atrial myxoma shown by echocardiography. *Br Heart J* 1987;58:413–416.
8. Kneper L: Neurologic manifestations of atrial myxoma: A 12 year experience and review. *Stroke* 1988;19:1435–1440.
9. Sandok BA: CNS embolism due to atrial myxoma: Clinical features and diagnosis. *Arch Neurol* 1980;37:485–488.
10. Reyne K: Cardiac myxomas. *N Engl J Med* 1995;333:1610–1616.
11. Larsson S: Atrial myxomas: Results of 25 years' experience and review of literature. *Surgery* 1989;105:695–698.
12. Markel ML: Cardiac myxoma: A review. *Medicine (Baltimore)* 1987;66:114–125.
13. Sutton MG: Atrial myxomas: A review of clinical experience in 40 patients. *Mayo Clin Proc* 1980;55:371–376.
14. Gershlick AH: The loud first heart sound in left atrial myxoma. *Br Heart J* 1984;52:403–407.
15. Engberding R: Diagnosis of heart tumors by transesophageal echocardiography: A multicentre study in 154 patients. *European Cooperative Study Group. Eur Heart J* 1993;14:1223–1228.
16. Castells E: Cardiac myxomas: Surgical treatment, long-term results and recurrence. *J Cardiovasc Surg (Torino)* 1993;34:49–53.
17. Cooley DA: Surgical treatment of cardiac neoplasms: 32 year experience. *Thorac Cardiovasc Surg* 1990;38(Suppl 2):176–182.
18. McCarthy PM, Piehler JM, Schaff HV, et al: The significance of multiple, recurrent, and "complex" cardiac myxomas. *J Thorac Cardiovasc Surg* 1986;91:389–396.