

K. Karnchanapandh¹
M. Imizu²
Y. Kato²
H. Sano²
M. Hayakawa²
T. Kanno²

Successful Obliteration of a Ruptured Partially Thrombosed Giant M1 Fusiform Aneurysm with Coil Embolization at Distal M1 after Extracranial-Intracranial Bypass

Abstract

Proximal occlusion or trapping combined with EC-IC bypass is usually employed as a definite treatment for a giant fusiform aneurysm in cases where it is impossible to apply clips and do vascular reconstruction. Endovascular treatment is very important as an alternative or combined technique if direct surgery is impossible. The authors report a young male who presented with a 2nd episode of intracranial bleeding in basal ganglion and subarachnoid hemorrhage with mild right hemiparesis. His 3D-CT scan revealed left ruptured partially thrombosed giant M1 fusiform aneurysm and left unruptured C3 saccular aneurysm. He underwent STA-MCA bypass with attempted M1 reconstruction and a week later attempted total occlusion of the M1 aneurysm with coils. But only a ruptured point at the distal M1 was occluded which, however, resulted in temporary mild right hemiparesis and aphasia. A month later when he was supposed to have his 2nd coiling procedure his angiogram demonstrated spontaneous and complete obliteration of both the M1 and C3 aneurysms without any new neurological deficit, so no further endovascular procedure was attempted. The discussion is based on this case and previous reports regarding difficult giant M1 fusiform aneurysms, its treatment and spontaneous thrombosis of aneurysmal sac after bypass and distal occlusion. Conclusions are drawn that 1) spontaneous thrombosis of M1 and C3 aneurysms should be the result of hemodynamic alteration in both aneurysms due to a lower flow velocity induced by distal bypass and distal occlusion of M1, 2) combined distal bypass and endovascular obliteration of the aneurysmal sac with coils is a good alternative if vascular reconstruction is difficult or impossible.

Key words

Giant Fusiform Aneurysm · Spontaneous and Complete Thrombosis · Flow Alteration · Coil Embolization

Introduction

Proximal occlusion or trapping combined with EC-IC bypass is usually used as the definite treatment for a giant fusiform aneurysm where it is difficult or impossible to apply clips and do vascular reconstruction [1–7]. Endovascular treatment is important as an alternative or combined technique if direct surgery is technically impossible [8–13]. We present in this report a patient with a ruptured left partially thrombosed giant M1 fusiform aneurysm and an incidental left C3 saccular aneurysm, who underwent a craniotomy for STA-MCA bypass with attempted M1 reconstruction and later an endovascular treatment resulting in occlusion of the rupture point at the distal part of M1 fusiform aneurysmal sac and a right hemiparesis which recovered uneventful. A month later both his giant M1 fusiform and C3 saccular aneurysms were spontaneously thrombosed and completely obliterated.

Case Report

A 24-year-old, right-handed man was referred to our hospital for a sudden severe headache and mild alteration of consciousness. The CT scan and 4-vessel angiogram which were done in another hospital revealed SAH with a left C3 saccular and a left partially thrombosed giant M1 fusiform aneurysm. 3D-CT done in our hospital demonstrated that the M1 aneurysmal sac was partially thrombosed (Fig. 1d) by which we thought the ruptured site was already obliterated and in some degree was temporarily secured. Together with the high operative risk of the partially thrombosed giant M1 fusiform aneurysm, we decided to follow-up this patient. The mild right hemiparesis, which was the only neurological deficit was completely resolved during the 3-month follow-up period. However, at the end of the 3rd month he had sudden

Affiliation

¹Department of Surgery, Section of Neurosurgery, Rajavithi Hospital, Bangkok, Thailand
²Department of Neurosurgery Fujita Health University, Aichi, Japan

Correspondence

Assoc. Prof. Y. Kato, M. D. · Fujita Health University · 1–98 Dengakugakubo · Kutsukake, Toyoake, Aichi · Japan · Phone: +81–562–93–9253 · Fax: +81–562–93–3118 · E-mail: neuro@fujita-hu.ac.jp

Bibliography

Minim Invas Neurosurg 2002; 45: 245–250 © Georg Thieme Verlag Stuttgart · New York · ISSN 0946-7211

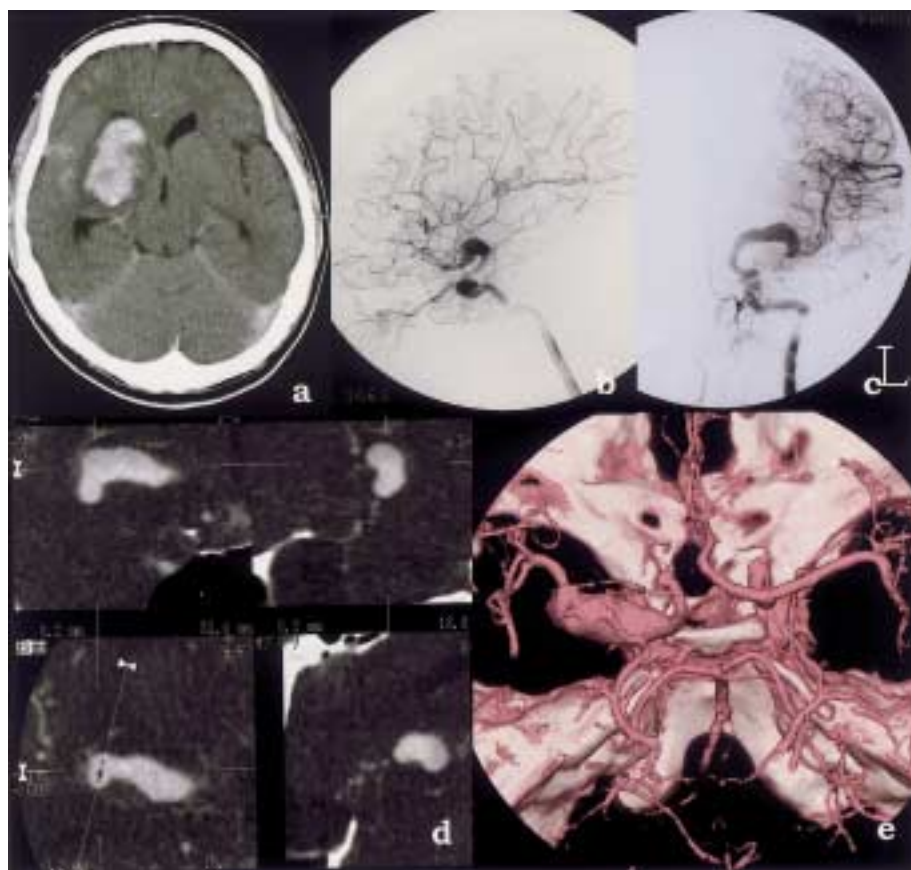


Fig. 1 **a** CT scan, done at 2nd bleeding, shows left basal ganglion hematoma and SAH.

b and **c** Preoperative lateral and A-P view of ICA angiogram show left giant M1 fusiform aneurysm and left C3 saccular aneurysm.

d Multiplanar reconstruction demonstrates thrombus in M1 aneurysm.

e 3D-CT shows left giant M1 fusiform aneurysm and absence of left A1.

right hemiparesis without alteration of consciousness. A CT scan demonstrated LT basal ganglion hematoma with SAH (Fig. 1a). 4-Vessel angiogram and 3D-CT showed a slight change of configuration of the bleb of the M1 giant fusiform aneurysm which was thought to be the site of rupture (Fig. 1b,c,e). Since it was the second bleeding, we decided to give definite treatment for this giant M1 fusiform aneurysm. Our plan was to do an STA-MCA bypass and temporary trapping followed by clot evacuation and M1 reconstruction with much attention to sparing some perforating branches at the proximal M1 if possible while permanent trapping was also an alternative. But as a result of many hard adhesions around the M1 aneurysm, only a few perforating branches could be dissected clearly from the complex adhesion-aneurysm mass. Hence it was impossible without any complication to save enough perforating branches at the proximal M1 for reconstruction or trapping to be employed. Even proximal occlusion at the proximal M1 aneurysmal sac with sparing of some perforating branches was impossible because the M1 aneurysmal sac was so hard that if clip were applied it would have to be slipped over both the more proximal M1 and the spared perforating branches or even over the ICA bifurcation or ICA and its anterior choroidal artery (Fig. 2). Thus, only double anastomosis was done. Although ischemic complication might occur if the sac were totally occluded, the risk of fatal rupture was high in this patient so, a week later, we performed an endovascular surgery aiming at complete obliteration of the M1 fusiform aneurysmal sac. Selective left ECA angiography demonstrated good flow through the STA-MCA anastomosis and good circulation of the recipient MCA branches (Fig. 3a). A balloon occlusion test at C5 was done with Moiyon 5 Fr., 15 minutes after which no new neurological deficit occurred. However no collateral flow from the

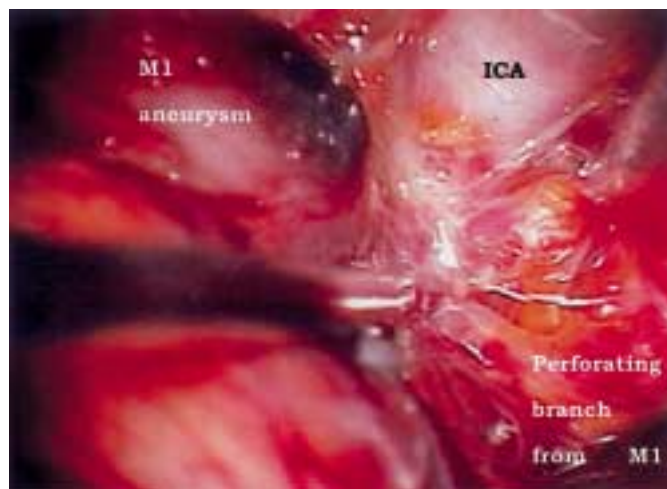


Fig. 2 Intraoperative view show thick adhesion around M1 during meticulous dissection to preserved perforating branches.

anterior cerebral artery and only retrograde flow from EC-IC bypass to the M1 aneurysmal sac were seen (Fig. 3c). An Envoy 5-Fr, 100-cm, guiding catheter, Rapid transit microcatheter, and Terumo GT45-double angle microguide were used.

A 3D-GDC 8 × 25 frame was employed to pack the ruptured site and the distal part of the aneurysm after which flow toward the distal end of the M1 aneurysmal sac was arrested. Then GDC-18 10 × 30 and 8 × 20 were put into the aneurysmal sac but as soon as this was accomplished the patient had right dense hemiplegia and aphasia (Fig. 3d-i). We then stopped coiling and sent him back to the ward and gave him heparinization, dopamine-in-

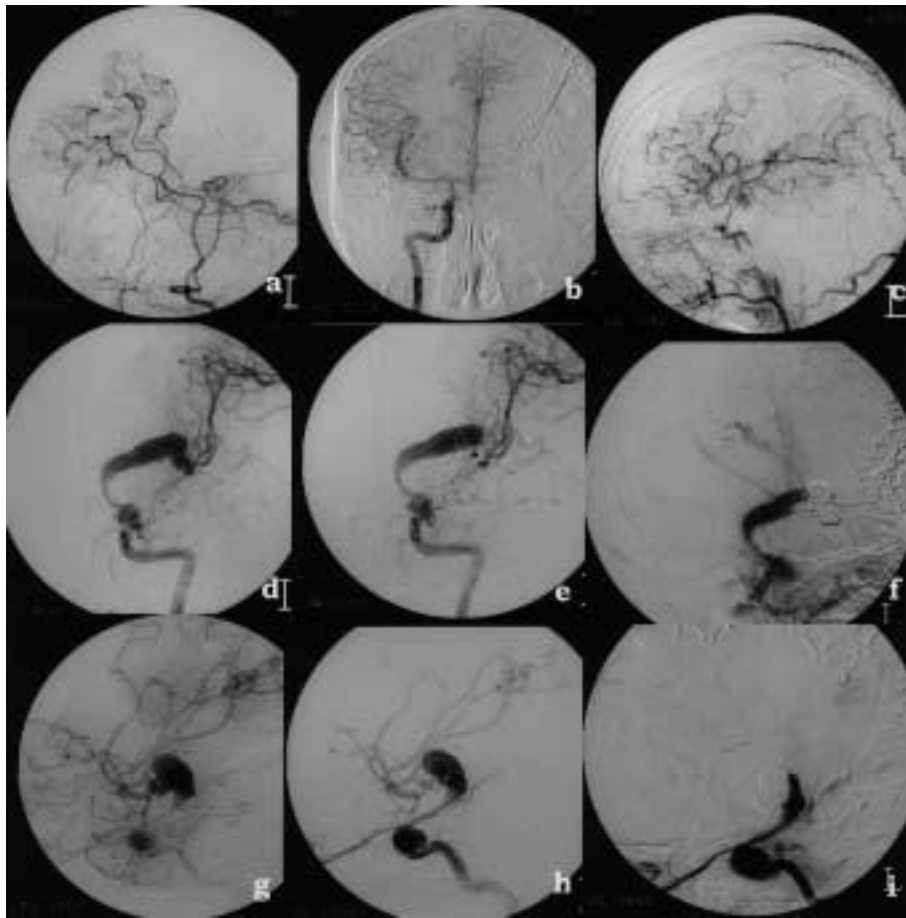


Fig. 3 a Left ECA angiogram demonstrates good flow from anastomosis to peripheral territory of M1. **b** Right ICA angiogram shows no collateral flow to left carotid system through left A1. **c** Left CCA angiogram during balloon occlusion test at left C5 demonstrates collateral flow to peripheral M1 territory via STA-MCA anastomosis and retrograde flow from the anastomosis to M1 aneurysmal sac as faint aneurysmal stain. **d** and **g** A-P and lateral view of left ICA angiogram done just before coiling procedure. **e** and **h** A-P and lateral view of left ICA done during first coiling into the bleb which was suspected to be the ruptured site. **f** and **g** A-P and lateral view of left ICA angiogram done just at the end of coiling procedure which had to be stopped because of acute ischemic deficit during coiling procedure, which however, occlusion of the ruptured site at the distal M1 was accomplished.

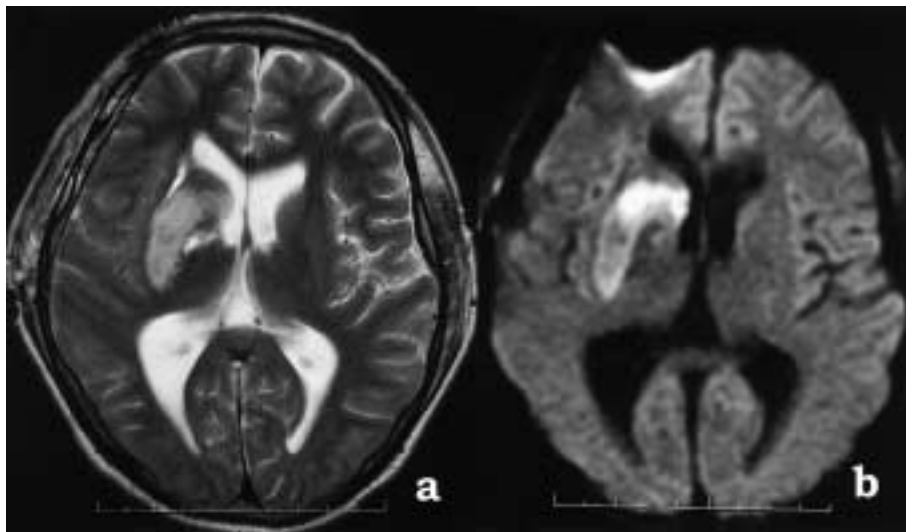


Fig. 4 a MRI done after coiling procedure confirmed left basal ganglion ischemia. **b** Diffusion MRI also shows left basal ganglion ischemia.

duced systolic hypertension above 150 mm Hg, and hyperbaric oxygen therapy. 3 hours later the deficit had disappeared. His angiogram on the next day revealed that the coils were in an original shape and the same site as that of immediate post coiling. T₂-weighted and diffusion MRI at 2 days after coiling showed left basal ganglion ischemia (Fig. 4a, b). SPECT also revealed decreased cerebral blood flow at the left basal ganglion area. Since this patient was afraid of the second coiling procedure and we also wanted to wait until his clinical condition was improved and stable, we delayed the 2nd endovascular surgery. On discharge from our hospital he had only mild difficulty in calculation.

About one month after the 1st coiling procedure, during which no neurological deficits occurred he came back to have the 2nd one. We planned to completely obliterate the sac of the M1 fusiform aneurysm and also the C3 saccular aneurysm but his left ICA angiogram at this time demonstrated only flow into left ICA with its ophthalmic and anterior choroidal artery, no filling of contrast into the C3 and the M1 aneurysms (Fig. 5). Both aneurysms had spontaneously thrombosed and were completely obliterated, hence the patient needed no further treatment to prevent rupture but follow-up. Now he has been on follow-up for 6 months,

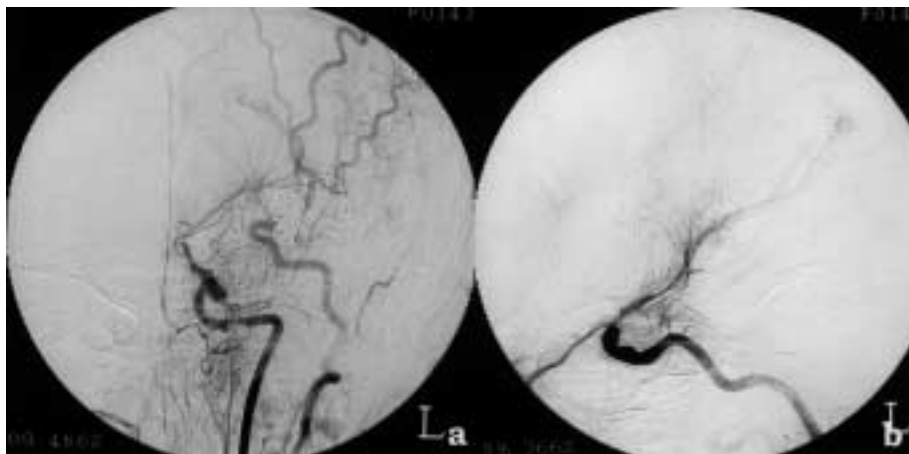


Fig. 5 a and b A.-p. and lateral view of left ICA angiogram done 1 month after coiling, demonstrates complete obliteration of both M1 and C3 aneurysm and also demonstrates a lot of perforating branches to left basal ganglion.

his neurological deficit is completely resolved and he has returned to his normal activity.

Discussion

Steinberg et al. in 1993 reviewed reports in the literature and found that patients with unclippable intracranial aneurysms were dead or severely disabled at the 5-year follow-up period [2]. Our patient presented with SAH and later with basal ganglion hematoma successively within 3 months which was enough to conclude that it was necessary for this particular patient to have definite treatment to prevent any future hemorrhage and/or thromboembolic event in spite of the high operative risk in the partially thrombosed giant aneurysms as described previously by Sano et al. in 1998 [7].

Drake and Peerless in 1997 reviewed their own series of 120 giant fusiform intracranial aneurysms treated surgically of which 25 were located in the anterior circulation and of which 13 were giant fusiform MCA aneurysms. They suggested from their experience that a collateral circulation to the area supplied by perforating vessels arising from the aneurysm sac itself must exist for occlusion of giant fusiform aneurysms and that incorporated perforating branches did not always result in central infarctions. Thus, the majority of giant fusiform aneurysms may be treated safely using parent occlusion or trapping. This even includes the MCA giant fusiform aneurysm in which fear existed for the integrity of lenticulostriate circulation to internal capsule and basal ganglion and where an EC-IC bypass usually satisfies the peripheral MCA territory [5].

In this reported case, an EC-IC bypass to peripheral MCA territory was accomplished successfully but an attempt to trap and do M1 reconstruction failed since there were so many perforating branches arising from aneurysmal sac which could not be preserved and so the risk of infarction of the internal capsule and basal ganglion was too high. We decided not to take such a risk. To obliterate the aneurysmal sac with coils later after the patency of the bypass was confirmed was chosen as an alternative procedure. But during coiling into an aneurysmal sac, an acute ischemic neurological deficit occurred and the procedure had to be stopped. Irrespective of whether the deficit resulted from coil in-

duced occlusion or thromboembolic phenomenon, we speculated that even if a collateral circulation to the central region, as Drake and Peerless mentioned, did already exist, it could not establish sufficient collateral flow in time for the sudden occlusion in our particular case.

However, we succeeded to occlude the ruptured bleb at the distal end of the M1 aneurysm with coils which, we think, might be an important cofactor together with the patent bypass that both created slow flow velocity conditions in the M1 fusiform aneurysmal sac and possibly also in the C1-C2-C3 and C3 saccular aneurysm. We even think that, soon after bypass surgery, the blood flow from the proximal M1 toward the aneurysmal sac had already been reduced to some degree as a result of the anastomosis flow supplying much of the demand of the peripheral M1 territory already and that flow from left ICA somehow decreased in response to this. But, after coiling, this flow must be much more reduced and that this might be sufficient to alter the potential for rupture to less than it would be in its natural course. In another words, by combined distal bypass and distal occlusion of the M1 fusiform aneurysm we may succeed to change the natural course of this particular aneurysm from one with a very high risk of rebleeding to one with a lower risk of rupture while maintaining sufficient flow to perfuse the perforating branches so that no new neurological deficit occurred afterward. Our speculation is based on mechanical concepts of the pathophysiology of initiation-growth-rupture of aneurysms [14–16]. As early as 1930, Forbus emphasized the significance of the flowing blood for aneurysmal initiation and progression [17]. Many investigators suggested a relation of segmental high flow rate and aneurysms that led to the hypothesis of hemodynamic stress as a mechanical factor favoring aneurysm initiation and progression [18–20]. Hashimoto et al. [21,22] could produce cerebral aneurysms in rats by carotid ligation, induced hypertension and administration of a substance causing fragility of connective tissue while later Nagata [23] and Stehbens [24] found that such a substance was not necessary. Futrakis et al. in 1999 computationally investigated hemodynamics and its relation to intracranial aneurysm formation. Their data suggested that, in the absence of any underlying disease process, aneurysm development is a mechanically mediated event or a mechanical deformation to pressure and shear. Their models offered a hypothesis regarding the initiation, growth and rupture of aneurysms as

related to the hemodynamics of cerebral arterial blood flow [25]. Hoh et al. in 2001 suggested flow alteration by combined surgical and endovascular technique as an alternative treatment in their series of 48 aneurysms that could not be clipped or occluded safely, of which 8 were fusiform aneurysms of the M1 segment. They also presented 1 of these 8 cases in which, after EC-IC bypass, an intraoperative angiogram showed complete cessation of flow to the aneurysm at the distal M1 location which they explained as the result of antegrade flow from the ipsilateral ICA that was balanced by an opposing flow from the bypass and the remaining aneurysm segment was later occluded by GDC embolization [13].

Unexpectedly, about 1 month after incomplete coiling of the M1 aneurysmal sac, a cerebral angiogram showed complete occlusion of both the giant M1 fusiform and C3 saccular aneurysms while no new neurological deficit was detected. And again this emphasizes the difference between slow and acute obliteration of the aneurysmal sac and its perforating arteries. Whether this spontaneous intraaneurysmal thrombosis was just incidental or the result of the distal M1 bypass and/or distal occlusion of M1 aneurysmal sac, we could not definitely say. But from the thrombosis point of view, apart from high blood viscosity and endothelial injury, the slow flow velocity is one of the most important factors. In this case we excluded the endothelial injury induced by the endovascular procedure as a cause of thrombosis since both the C3 and M1 had spontaneous and complete thrombosis in the same time period while the coiling procedure was done only into the M1 aneurysmal sac, no attempt into the C3 aneurysmal sac was made. Spontaneous thrombosis of a giant cerebral aneurysms is not uncommon and the finding of thrombus in a giant aneurysmal sac has been reported to vary between 52.4%–83.3% [26–28]. Complete thromboses of giant intracranial aneurysms are not common and the incidence is between 0%–19% [26–28]. Fukuoka et al. reported a completely thrombosed giant aneurysm of the angular artery branch of MCA in a patient who presented with SAH and a large ICH [29]. Marchau et al. reported a completely thrombosed giant basilar artery fusiform aneurysm presenting with ischemic episode without SAH [30]. And even though we suspected from his angiogram and 3D-CT a partial thrombosis in the M1 aneurysmal sac, during the period of at least 3 months before bypass and endovascular surgery, both M1 and C3 aneurysms did not undergo spontaneous and complete thrombosis until bypass and distal M1 aneurysmal sac occlusion were done. So we strongly believe that it is most likely in this case that thrombosis is the result of changing hemodynamic factors in both aneurysmal sacs from high to slow flow velocity. Benashvili et al. reported spontaneous thrombosis of a giant M1 fusiform aneurysm 4 months after EC-IC bypass and before endovascular occlusion was attempted [31]. Yeh and Tomsick also reported a spontaneous and complete thrombosis of a giant saccular aneurysm of the ICA, 1 month after EC-IC bypass and before balloon occlusion of proximal ICA was attempted which, at 2-year follow-up, was still shown to be completely obliterated [32]. However, not only spontaneous and complete thrombosis but also rupture was reported after bypass [33,34]. Hopkins and Grand reported on EC-IC bypass in the treatment of unclippable aneurysms of ICA and MCA in 11 patients, one of which was an unruptured left supraclinoid ICA aneurysm with non-filling of left intracranial circulation distally, which ruptured

1 week after bypass and before ICA ligation was attempted. They then suggested the paramount importance of the need for carotid ligation immediately after the bypass procedure [35]. Scott et al. reported the rupture of a previously unruptured giant MCA aneurysm 13 days after EC-IC bypass. Heros and Ameri also reported the rupture of an unruptured giant basilar aneurysm 36 hours after a saphenous vein interposition graft to the PCA [36]. From these previous reports and our own case, the hemodynamic change after distal bypass in the parent artery and in aneurysmal sac could be due, in either way, to more or less hemodynamic stress, depending on the balance between the retrograde flow from the anastomosis and the antegrade flow from the parent artery. If we cannot accurately predict the change of hemodynamic stress in the aneurysmal sac after bypass, care must be taken for preventing rupture if the aneurysm has not been secured. In our case, occlusion of the bleb which was thought to be the ruptured site at distal M1 was done 1 week after the bypass, which, we think, could have secured the aneurysm to some degree and might also help promote retrograde thrombosis as well. We cannot recommend distal bypass combined with ruptured point occlusion with coils as the treatment protocol for any giant M1 fusiform aneurysm on the basis of one case report. We can only say that combined distal bypass and endovascular technique is helpful in this kind of difficult aneurysm when operative risk is considered. We think that future attention and further studies should aim at a hemodynamic study of flow before and after any endovascular or surgical procedure on the vascular circuit with an unsecured aneurysm and to modify each treatment procedure according to each individual hemodynamic character to achieve the best treatment.

For example, TCD measurement of flow velocity before and after bypass might help make the decision about the time to obliterate the aneurysm, e.g., if after bypass the flow in the aneurysmal sac is higher or more turbulent, the obliteration of the aneurysm should be done as soon as possible but if after bypass flow in the aneurysmal sac is slower or not turbulent we may delay the obliteration and monitor the flow to see if it is possible that flow is going to be slower in some period of time and hence provide the possibility of spontaneous complete obliteration. During this time, we can monitor embolic phenomenon, if there are any, prompt obliteration could be done, etc. Slow obliteration of an aneurysm with perforating branches originating from sac itself might avoid the ischemic complication of the perforating branches territory comparison to that of an acute one. However, successful treatment still depends much upon the collateral circulation to the area supplied by perforating branches originating from aneurysmal sac if they technically could not be spared by treatment.

Conclusion

1. Spontaneous thrombosis of the M1 and C3 aneurysms in this case should be the result of the hemodynamic change, to slow flow in both aneurysms induced by distal bypass and distal occlusion of the M1.
2. Combined distal bypass and endovascular obliteration of the aneurysmal sac with coils is a good alternative if vascular reconstruction is technically difficult or impossible.

3. Further studies should aim at hemodynamic investigation of flow character, e.g., flow velocity before and after any procedure on the vascular circuit to help modify treatment for the individual case.
4. Successful treatment depends much upon collateral circulation to the territory of the perforating branches originating from the aneurysm itself when they are technically impossible to be preserved.

References

- 1 Fujii K, Fukui M, Matsubara T, Nagata S, Fujiwara S, Matsushima T, Haseo K. Microsurgical procedures for management of giant middle cerebral aneurysm causing increased intracranial pressure. *Surg Neurol* 1989; 32: 366–711
- 2 Steiberg GK, Drake CG, Peerless SJ. Deliberate basilar or vertebral artery occlusion in the treatment of intracranial aneurysms – immediate results and long term outcome in 201 patients. *J Neurosurg* 1993; 79: 161–173
- 3 Drake CG, Peerless SJ, Ferguson GG. Hunterion proximal arterial occlusion for giant aneurysms of the carotid circulation. *J Neurosurg* 1994; 81: 656–665
- 4 Anson JA, Lawton MT, Spetzler RF. Characteristic and surgical treatment of dolichoectatic and fusiform aneurysms. *J Neurosurg* 1996; 84: 185–193
- 5 Drake CG, Peerless SJ. Giant fusiform intracranial aneurysms: review of 120 patients treated surgically from 1965 to 1992. *J Neurosurg* 1997; 87: 141–162
- 6 Amin-Hanjani S, Ogilvi CS, Buonanno FS, Choi IS, Metz LN. Treatment of dissecting basilar artery aneurysm by flow reversal. *Acta Neurochir (Wien)* 1997; 139: 44–51
- 7 Sano H, Kato Y, Shankar K, Kanaoka N, Hayakawa M, Katada K, Kanno T. Treatment and result of partially thrombosed giant aneurysms. *Neurol Med Chir Suppl (Tokyo)* 1998; 38: 80–83
- 8 Sinson G, Philips MF, Flamm ES. Intraoperative endovascular surgery for cerebral aneurysms. *J Neurosurgery* 1996; 84: 63–70
- 9 Serbinenko FA, Filatov JM, Spallone A, Tchurilov MV, Lazarev VA. Management of giant intracranial ICA aneurysms with combined extracranial-intracranial anastomosis and endovascular occlusion. *J Neurosurg* 1990; 73: 57–63
- 10 Gobin Y, Vinulla F, Gurian JH, Guglielmi G, Duckwiler GR, Massoud TF, Martin NA. Treatment of large and giant fusiform intracranial aneurysms with Guglielmi detachable coils. *J Neurosurg* 1996; 84: 55–62
- 11 Higashida TR, Smith W, Gress D, Urwin R, Dowd CF, Balousek PA, Halbach VV. Intravascular stent and endovascular coil placement for a ruptured fusiform aneurysm of the basilar artery: case report and review of literature. *J Neurosurg* 1997; 87: 944–949
- 12 Sano H, Kato Y, Singh FB, Abdeen K, Kanaoka K, Katada K, Kanno T. Combined treatment with direct surgery and interventional coil embolization for difficult aneurysms. *Surgery for Cerebral Stroke* 1999; 27: 172–182
- 13 Hoh PL, Putman CM, Budzik RF, Carter BS, Ogilvy CS. Combined surgical and endovascular techniques of flow alteration to treat fusiform and complex wide-necked intracranial aneurysms that are unsuitable for clipping or coil embolization. *J Neurosurg* 2001; 95: 24–35
- 14 Steiger HJ, Poll A, Liepsch D, Reulen HJ. Haemodynamic stress in lateral saccular aneurysms. *Acta Neurochir (Wien)* 1987; 86: 98–105
- 15 Steiger HJ, Poll A, Liepsch D, Reulen HJ. Haemodynamic stress in terminal aneurysms. *Acta Neurochir (Wien)* 1988; 93: 18–23
- 16 Soichiro K, Hashimoto N, Kikuchi H, Fumitada H, Nagata I, Kataoka H. Cerebral aneurysms arising at non branching sites: an experimental study. *Stroke* 1997; 28: 398–404
- 17 Forbus WD. On the origin of military aneurysms of the superficial cerebral arteries. *Bull Johns Hopkins Hosp* 1930; 47: 239–284
- 18 Kayembe KNT, Sasahara M, Hazama F. Cerebral aneurysms and variations of the circle of Willis. *Stroke* 1984; 15: 846–850
- 19 Stehbins WE. Etiology of intracranial berry aneurysms: review article. *J Neurosurg* 1989; 70: 823–831
- 20 Tognetti F, Limoni P, Testa C. Aneurysm growth and hemodynamic stress. *Surg Neurol* 1983; 20: 74–78
- 21 Hashimoto N, Handa H, Nagata I, Hazama F, Hashimoto N, Handa H, Nagata I, Hazama F. Experimental cerebral aneurysms with reference to the experimental condition and to the etiology. *Neuromed Chir* 1979; 19: 999–1003
- 22 Hashimoto N, Handa H, Nagata I, Hazama F. Experimentally induced cerebral aneurysms in rats: part 5, relation of hemodynamics in the circle of Willis to formation of aneurysms. *Surg Neurol* 1980; 13: 41–45
- 23 Nagata I, Handa H, Hashimoto N, Hazama F. Experimentally induced cerebral aneurysms in rats 7, scanning electron microscope study. *Surg Neurol* 1981; 16: 291–296
- 24 Stehbins WE. Hemodynamically induced atrophic lesions of atherosclerosis. In: Liepsch DW (ed). *Proceedings of the 2nd. International symposium on biofluid mechanics and biorheology Basel: Karger, 1989*
- 25 Foutarakis GN, Yonas H, Sclabassi RJ. Saccular aneurysm formation in curved and bifurcating arteries. *AJNR* 1999; 20: 1309–1317
- 26 Lavyne MH, Kleefeld J, Dvis KR. Giant intracranial aneurysms of the anterior circulation: clinical characteristics and diagnosis by computed tomography. *Neurosurgery* 1978; 3: 356–363
- 27 Pinto RS, Kricheff II, Butter AR, Murai R. Correlation of computed tomographic, angiographic and neuropathological changes in giant cerebral aneurysms. *Radiology* 1979; 132: 85–92
- 28 Whittle IR, Dorsch NW, Besser M. Spontaneous thrombosis in giant intracranial aneurysms. *J Neurol Neurosurg Psychiatry* 1982; 45: 1040–1047
- 29 Fukuoka S, Suematsu K, Fujiwara H, Hashimoto I, Nakamura J-I. Completely thrombosed giant aneurysm of angular artery. *Surg Neurol* 1984; 22: 145–148
- 30 Marchau MMB, Vallaeys J, Vanhoonen G. Thrombosis of a giant aneurysm of basilar artery. *Neurosurgery* 1988; 22: 612–613
- 31 Benashvili GM, Alexander LF, Zubkov YN. Thrombosis of giant aneurysm after extracranial-intracranial bypass. *Neurosurgery* 1992; 31: 360–364
- 32 Yeh H-S, Tomsick TA. Obliteration of giant carotid aneurysm after extracranial to intracranial bypass surgery: case report. *Surg Neurol* 1997; 48: 473–476
- 33 Heros RC, Ameri AM. Rupture of a giant basilar aneurysm after saphenous vein interposition graft to the posterior cerebral artery: case report. *J Neurosurg* 1984; 61: 387–390
- 34 Anson JA, Stone LJ, Crowell RM. Rupture of giant carotid aneurysm after extracranial to intracranial bypass surgery. *Neurosurgery* 1991; 28: 142–147
- 35 Hopkins LN, Walter G. Extracranial-intracranial arterial bypass in the treatment of aneurysms of the carotid and middle cerebral arteries. *Neurosurgery* 1979; 5: 21–31
- 36 Scott RM, Liu HC, Yuan R, Adelman L. Rupture of previously unruptured giant middle cerebral artery aneurysm after extracranial-intracranial bypass surgery. *Neurosurgery* 1982; 10: 600–603