


This article was downloaded by: [University of West Florida]

On: 09 October 2014, At: 22:02

Publisher: Routledge

Informa Ltd Registered in England and Wales Registered Number: 1072954 Registered office: Mortimer House, 37-41 Mortimer Street, London W1T 3JH, UK



Neurocase: The Neural Basis of Cognition

Publication details, including instructions for authors and subscription information:

<http://www.tandfonline.com/loi/nncs20>

Recovery of Semantic Word Processing in Transcortical Sensory Aphasia: a Functional Magnetic Resonance Imaging Study

Roland Zahn , Walter Huber , Eva Drews , Karsten Specht , Stefan Kemeny , Wolfgang Reith , Klaus Willmes & Michael Schwarz

Published online: 09 Aug 2010.

To cite this article: Roland Zahn , Walter Huber , Eva Drews , Karsten Specht , Stefan Kemeny , Wolfgang Reith , Klaus Willmes & Michael Schwarz (2010) Recovery of Semantic Word Processing in Transcortical Sensory Aphasia: a Functional Magnetic Resonance Imaging Study, *Neurocase: The Neural Basis of Cognition*, 8:5, 376-386

To link to this article: <http://dx.doi.org/10.1076/neur.8.4.376.16189>

PLEASE SCROLL DOWN FOR ARTICLE

Taylor & Francis makes every effort to ensure the accuracy of all the information (the "Content") contained in the publications on our platform. However, Taylor & Francis, our agents, and our licensors make no representations or warranties whatsoever as to the accuracy, completeness, or suitability for any purpose of the Content. Any opinions and views expressed in this publication are the opinions and views of the authors, and are not the views of or endorsed by Taylor & Francis. The accuracy of the Content should not be relied upon and should be independently verified with primary sources of information. Taylor and Francis shall not be liable for any losses, actions, claims, proceedings, demands, costs, expenses, damages, and other liabilities whatsoever or howsoever caused arising directly or indirectly in connection with, in relation to or arising out of the use of the Content.

This article may be used for research, teaching, and private study purposes. Any substantial or systematic reproduction, redistribution, reselling, loan, sub-licensing, systematic supply, or distribution in any form to anyone is expressly forbidden. Terms & Conditions of access and use can be found at <http://www.tandfonline.com/page/terms-and-conditions>

Recovery of Semantic Word Processing in Transcortical Sensory Aphasia: a Functional Magnetic Resonance Imaging Study

Roland Zahn^{1,2,5}, Walter Huber², Eva Drews^{1,2}, Karsten Specht^{2,3}, Stefan Kemeny³, Wolfgang Reith³, Klaus Willmes⁴ and Michael Schwarz¹

¹Department of Neurology, ²Neurolinguistics Section, ³Department of Neuroradiology, ⁴Neuropsychology Section, University of Technology, RWTH Aachen, Pauwelsstrasse 30, D-52057 Aachen and ⁵Department of Psychiatry, University of Freiburg, Hauptstrasse 5, D-79104 Freiburg, Germany

Abstract

In a previous functional magnetic resonance imaging (fMRI) study with normal subjects, we demonstrated regions related to conceptual-semantic word processing around the first frontal sulcus (BA 9) and the posterior parietal lobe (BA 7/40) in agreement with several previous reports. We had the possibility, using the same fMRI paradigm, to study two consecutive cases with left middle cerebral artery (MCA) infarction (RC and HP) and lesions affecting either solely the pre-frontal (HP) or both the pre-frontal and posterior parietal part of the network activated in normal subjects (RC). Both patients showed transcortical sensory aphasia (TSA) on acute assessment. This contradicts classical disconnection accounts of the syndrome stating intact conceptual representations in TSA. Their recovery of language comprehension was associated with activation of a left hemispheric network. Mainly activations of left perilesional pre-frontal regions (RC), left Wernicke's area (RC and HP) or the left posterior middle and inferior temporal cortex (HP) were demonstrated in the TSA patients. The latter findings suggest that in our cases of TSA functional take-over has occurred in regions with related functions ('redundancy recovery') rather than in previously unrelated areas ('vicarious functioning'). Our data support distributed models of conceptual-semantic word processing and multiple left hemispheric representations of closely related functions.

Introduction

The dissociation of impaired auditory word comprehension and relatively intact repetition termed transcortical sensory aphasia (TSA) has been taken as evidence for an anatomical disconnection of the auditory word-images centre, i.e. Wernicke's area, from a diffuse posterior 'ideational field' (Begriffsfeld) (Lichtheim, 1885). Disconnection mechanisms have been emphasized in neoclassical models of language functions (Geschwind, 1965). Some modern authors view lesions in TSA as representing partial damage to a distributed semantic system itself, rather than a disconnection of intact centres for conceptual and lexical processing (Alexander *et al.*, 1989).

Although functional imaging studies have corroborated the view of a distributed semantic system in posterior extrasylvian areas (Démonet *et al.*, 1992; Warburton *et al.*, 1996; Binder *et al.*, 1997; Vandenberghe *et al.*, 1996), they seem to contradict lesion studies of standard aphasic syndromes, including Wernicke's aphasia, where the most consistent overlap of lesions associated with persistent impairments of

comprehension was to be found in the posterior perisylvian (Wernicke's area), but not the extrasylvian cortex (Willmes and Poeck, 1993). An explanation for this contradiction has been offered by postulating a disconnection of damaged lexical representations in Wernicke's area from spared left extrasylvian conceptual representations (Warburton *et al.*, 1996) or from bilaterally represented conceptual categories (Gainotti *et al.*, 1995) in aphasia. These modern disconnection accounts are compatible with recovery of language functions within a localizationist model. The remarkable ability to recover from functional impairments, however, has been challenging localizationist approaches in general [reviewed by Phillips *et al.* (1984)]. Several alternative theories have been put forward to account for recovery of function after brain injury [reviewed in Marshall (1984) and Finger and Almli (1985)]. Theories of functional compensation (Finger and Almli, 1985) or so-called redundancy recovery (Marshall, 1984) contradict a strict and uniform localization of cognitive functions. These theories presuppose distributed representa-

tions of closely related or identical functions. For language the existence of such multiple representations of functions has been concluded from the equivocal relationship between standard aphasic syndromes and the localization of corresponding lesions (Willmes and Poeck, 1993).

Whereas structure–function relationships have been primarily established by looking for the association of deficit symptoms or recovered functions with certain lesions, functional activation methods offer a means to study more directly the functional anatomy of these recovered or retained functions in neuropsychological patients [for a review of theories of deficit and compensation in aphasia see Springer *et al.* (2000)]. We were interested to test the predictions of theories of recovery applied to recovered semantic word processing in two consecutive cases of TSA after left middle cerebral artery (MCA) infarction, using the Aachen Aphasia Test (AAT). To our knowledge, this is the first functional activation study measuring semantic processing in TSA after a left hemispheric stroke. In a previous functional magnetic resonance imaging (fMRI) study with normal subjects, including elderly persons, we were able to activate left pre-frontal (BA 9) and posterior parietal (BA 7/40) areas in accordance with previous studies [reviewed in Price (1998)] as part of the conceptual-semantic network using a semantic monitoring task on auditory words versus auditory lexical decision with non-word distractors (Zahn *et al.*, 2000). (1) According to the disconnection theory, areas normally involved in lexical or conceptual processing should be spared in TSA and recovery of auditory comprehension should be associated with a re-establishment of the connections between these functionally reactivated areas. (2) Vicarious functioning (Marshall, 1984) can only be assumed when areas are activated after recovery which never show detectable activity in normal subjects during the measured task. (3) Recovery by functional compensation (Finger and Almlí, 1985) or redundancy recovery (Marshall, 1984) within a distributed network of semantic functions is expected to occur through activation of spared parts of a partially damaged semantic system. (4) The left-to-right transfer hypothesis predicts that recovery of auditory comprehension is mediated by activation of right hemisphere homologues of language areas that might have had latent language capabilities prior to disease [reviewed in Kinsbourne (1998)].

Case histories

TSA was diagnosed according to the operational criteria given by the AAT (Huber *et al.*, 1984): fluent speech with no difficulties in articulation, repetition subtest > percentile rank 50 and repetition subtest performance 20 percentile ranks above comprehension subtest, naming subtest and Token Test performance. HP strictly and RC essentially fulfilled these criteria (Table 1).

RC

RC was a 65-year-old right-handed former mechanical engineer who suffered from a cardio-embolic left hemispheric

stroke in January 1998. One day post-onset, a computed tomography (CT) scan revealed two hypodensities in the frontal and parietal MCA territory. On neurological examination a mild right facial paresis and a latent paresis of the right arm were noted. Fluent spontaneous speech with severe language comprehension deficits were apparent. A comparison of two conventional MRI examinations using coronal and axial Fluid Attenuated Inversion Recovery (FLAIR) sequences performed after 10 days and 5 months post-stroke revealed only a slight retraction of the initial hyperintense frontal and parietal lesions. T1-weighted three-dimensional MRI scanning after 5 months indicated an almost complete hypointense demarcation of these areas. Extra- and transcranial Doppler sonography were normal. An arrhythmia absoluta pointed to a cardio-embolic event as the most probable cause.

Aphasia was assessed using the AAT (Huber *et al.*, 1984) on three occasions during the acute and post-acute phases after stroke (Table 1). In the acute phase, spontaneous speech was fluent with no difficulty initiating speech and with normal articulation. Severe word-finding difficulties, semantic paraphasias and many circumlocutions were observed, which were often repeated stereotypically. Syntactic constructions were complex and paragrammatic. Initially there were also many phonemic paraphasias and searching, but these symptoms almost disappeared during the first month, whereas paragrammatic and semantic abnormalities recovered more slowly. The results of the first AAT examination confirmed TSA with repetition being significantly better than all of the other subtests. In the last AAT examination at 5 months, the time of fMRI scanning, the ceiling level had been reached.

HP

HP was a 69-year-old right-handed former high school teacher who suffered from a cardio-embolic left hemispheric stroke in October 1998. One day post-onset a CT scan revealed a left frontal hypodensity within the MCA territory. On neurological examination no focal deficits were noted. Fluent spontaneous speech with severe language comprehension deficits were apparent. A comparison of two conventional MRI examinations using coronal and axial FLAIR sequences performed after 12 days and 6 months post-stroke revealed only a slight retraction of the initial hyperintense frontal lesion. T1-weighted three-dimensional MRI scanning after 6 months indicated an almost complete hypointense demarcation of this area. Extra- and transcranial Doppler sonography was normal. An intermittent arrhythmia absoluta pointed to a cardio-embolic event as the most probable cause.

In the acute phase, spontaneous speech was fluent with no difficulty initiating speech and with normal articulation. Severe word-finding difficulties, semantic paraphasias and many circumlocutions were observed, which were often repeated stereotypically. Syntactic constructions were complex and paragrammatic. From the beginning there were no phonemic paraphasias.

Table 1. Results of the Aachen Aphasia Test examinations

Time post-stroke	Spontaneous speech rating scales						Subtests (percentiles)				
	COM	ART	AUT	SEM	PHO	SYN	TT	REP	WRIT	NAME	COMP
RC											
12th day	3	5	3	3	3	3	31	70	53	52	52
10th week	4	5	4	4	4	4	91**	94**	99**	91**	88(**)
5 months	5	5	4	4	5	4	97	96	99	93	95
HP											
10th day	2	5	2	2	5	3	33	88	–	41	21
12th week	4**	5	5**	4**	5	5**	83**	99	99	88**	59**
6 months	5	5	5	5	5	5	94	97	100	94	70

The Aachen Aphasia Test consists of six six-point spontaneous speech rating scales with 0 = most deviant and 5 = normal, and five subtests. Subtest scores are reported as percentile ranks based on norms for the aphasic population ($n = 376$).

COM, communicative behaviour; ART, articulation and prosody; AUT, automatized and stereotypical speech elements; SEM, semantic structure; PHO, phonological structure; SYN, syntactic structure; TT, Token Test; REP, repetition; WRIT, written language; NAME, confrontation naming; COMP, comprehension, in which different units (phonemes, monosyllabic and polysyllabic nouns, sentences) and linguistic rules are incorporated.

, Significant differences in comparison with the subtest performance in the preceding examination ($\alpha = 10\%$). (), Differences that reach 75% of the critical value for a significant difference.

Severity of impairment in a subtest is operationally defined by Stanine norms (1–9). For repetition, percentile ranks (PR) and corresponding Stanine norms (ST): severe impairment: ST 1–3 = PR 1–25; moderate impairment: ST 4–5 = PR 26–64; mild impairment: ST 6–7 = PR 65–89; residual or no impairment: ST 8–9 = PR 90–100.

In the first AAT examination, 10 days post-stroke, HP performed significantly better in the repetition subtest compared with all of the other subtests (Table 1). In the last AAT examination at 6 months, the time of fMRI scanning, the ceiling level had been reached for all subtests, but comprehension was still impaired.

Materials and methods

Subjects

RC and HP and healthy male subjects ($n = 14$; 23–65 years), strongly right handed, gave informed consent.

fMRI study

The scanning procedure was identical to the normal group study, where we used an additional condition, described elsewhere (Zahn *et al.*, 2000). In this study we focused on two conditions. In the lexical condition [L] an auditory lexical decision task was used, where reversed words served as phonotactically illegal non-word distractors. The use of non-words instead of pseudowords minimizes segmental phonological and automatic lexical-semantic processing. In addition, the target/distracter ratio was kept low at 1/3 across all conditions to reduce further automatic activation of word meaning for targets. The task was expected to engage matching processes involved in lexical access, in addition to pre-lexical processing. In the semantic condition [S] animals had to be discriminated from names of other natural kind, thus requiring a superordinate category decision. Within the chosen model (Hillert, 1999), we expected mainly conceptual-semantic in addition to lexical-semantic and word form processing to be activated. By ‘conceptual-semantic’ we denote an analysis of meaning that goes beyond the meaning

assigned to a lexical entry, by requiring (de-) compositions like superordinate category judgements (Hillert, 1999).

All stimuli were matched for stimulus duration and sound amplitude, word frequency and number of syllables of German. Digital stimuli were auditorily presented (1/3 s) at 85 dB. During the activation periods, the subjects had to monitor for targets according to the criterion given before each session and respond with a button press. Each experimental condition consisted of one session with three 88-s cycles alternating between rest (off) and activation (on). Whole brain fMRI was performed on a 1.5T Philips ACS NT Gyroscan with a standard head coil and echo-planar imaging [repetition time (RT) 4000 ms; echo time (ET) 40 ms; field angle (FA) 40°; matrix 64 × 64; field of view (FOV) 220 × 170 mm; 15 contiguous 7 mm slices parallel to the AC–PC line]. After the functional scans, a high-resolution volumetric anatomic scan was acquired for three-dimensional rendering of the brain (3D FFE sequence with RT 30 ms; ET 4.5 ms; FA 30°; matrix 256 × 256; FOV 220 × 176 mm; 90 contiguous 2 mm thick slices). The data were analysed using SPM96 software (Wellcome Department of Cognitive Neurology, London, UK). The functional images were spatially realigned, normalized into standard stereotaxic space, resliced with a voxel size of 4 × 4 × 7 mm³ and smoothed (8 × 8 × 14 mm³ kernel) (Friston *et al.*, 1995). The first scans from each on and off period were discarded.

In the present study we focused on the following complex contrast (R = rest): interaction between semantic and lexical task indicating areas associated with the processing of word meaning, mainly conceptual-semantic word processing: [S–R]–[L–R], abbreviated [S–L].

We employed conjunction over subjects for the normal group (contrasts of individual subjects separately modelled within one design matrix) showing activation maps of voxels

consistently activated in all subjects (Price and Friston, 1997). Maxima exceeding an individual voxel level of $P = 0.001$ ($z = 3.09$) and a cluster size > 16 voxels ($P < 0.05$ corrected) are displayed in Fig. 1 and Table 2. Because we were interested in the interindividual variability in the normal subjects, we also analysed normal single cases (each subject modelled again within a single design matrix) looking at contrast [S–L] in each subject in five left hemispheric regions of interest (ROIs) defined by Talairach coordinates (see Table 3): (1) posterior middle pre-frontal, (2) inferior pre-frontal cortex, (3) posterior parietal cortex, (4) posterior superior temporal gyrus and (5) posterior middle/inferior temporal gyri. Maxima exceeding $P = 0.01$ ($z > 2.33$) are reported within these regions in Table 3. ROIs (1) and (3) were chosen based on the normal group study and ROIs (2), (4) and (5) for comparison with the main results of the single case analysis in RC and HP (see below).

We performed a single case analysis for RC's and HP's data. Because of spatial distortions occurring during spatial normalization of brains with large lesions, which exceed those tolerable in brains without lesions, we performed a statistical analysis based on the non-normalized but smoothed functional images. Activation maps were then projected on to the individual three-dimensional T1-weighted anatomical image that had been co-registered with the functional images by using the anatomical T1-weighted reference image (Pietrzyk *et al.*, 1994). Localization of activations was determined in axial, coronal and sagittal slices by an experienced neuroradiologist (WR) using anatomical landmarks to identify the activated structures in an anatomical reference atlas (Mai *et al.*, 1998).

Results

Normal subjects' and patients' performances in the fMRI tasks

There were no significant differences (Wilcoxon test, $P = 0.10$) between the tasks in the normal group with respect to d' values (Table 4). Performances of RC and HP in the semantic task were subnormal but significantly above a chance level response (d' around 2). The relative d' difference in performance between tasks was within the normal range.

Structural MRI

RC. The left hemispheric lesion involved the posterior perisylvian inferior parietal lobule, extending into the parieto-occipital junction as well as parts of the inferior and large parts of the left middle frontal gyrus. The pars opercularis of the inferior frontal gyrus (posterior frontal operculum), the superior frontal gyrus and the temporal lobe were spared.

HP. The left hemispheric lesion involved parts of the inferior and large parts of the left middle frontal gyrus. The pars opercularis of the inferior frontal gyrus (posterior frontal

operculum) and the superior frontal gyrus were spared. The lesion was strikingly similar to RC's frontal lesion.

fMRI study

Semantic versus lexical condition [S–L]. Figure 1 shows T1-weighted axial magnetic resonance slices parallel to the AC–PC line through RC's and HP's brains with superimposed activation maps obtained from spatially non-normalized functional images. For comparison, axial slices through a standard brain (Evans *et al.*, 1994) at comparable levels along the z -axis with normalized normal group data are displayed (conjunction over subjects $z > 3.09$, $P < 0.05$ corrected). In Table 2 the results of the normal group (conjunction over subjects) are reported and in Table 3 the results of the ROI single normal subject analysis using normalized data are reported. Table 5 gives statistical information for RC and HP and the anatomical localization of activations. The numbers in the text and in Table 5 refer to the numbered activation peaks in Fig. 1.

Normal subjects

Activations in the contrast semantic versus lexical task were viewed as conceptual-semantic processing areas. For the group (conjunction over subjects) these included parts of the posterior left middle frontal gyrus (BA 9, near BA 45) and posterior parietal lobe (BA 7/40) as seen in Fig. 1 and Table 2. The ROI-based analysis of single normal subjects (Table 3) showed that 12 of 14 single subjects displayed a posterior inferior or middle pre-frontal activation (BA 9, 46/9, 45, 47) at $P = 0.01$. Posterior parietal activations reached significance in eight of 14 single subjects, scattered over BA 7/19, 7/40 and BA 39. Posterior temporal activations, although not significant in the group study, were found in eight subjects; these were located in the posterior inferior or middle temporal gyrus (BA 20/21/37). Only one subject displayed an activation within the posterior superior temporal gyrus (BA 22).

Single subject analysis for RC and HP based on non-normalized data. Inferior and middle frontal activations occurred perilesionally (3, 5, 6, 9). RC showed a perilesional activation in the parietal extension of the superior temporal gyrus (4) as well as left lateralized thalamic (2), left pre-cuneus activations (7) and a left pre-central signal increase (8).

There was a single highly significant cluster of activation within the left posterior superior, middle and inferior temporal gyrus. Thus, both patients activated parts of Wernicke's area, i.e. the posterior superior temporal gyrus. Other activations were not observed, even on a more liberal level of significance ($z > 2.33$, $P = 0.01$ uncorrected).

Discussion

Functional recovery of semantic single word processing in RC and HP

In the present investigation we were interested in the functional anatomy of recovered conceptual-semantic word

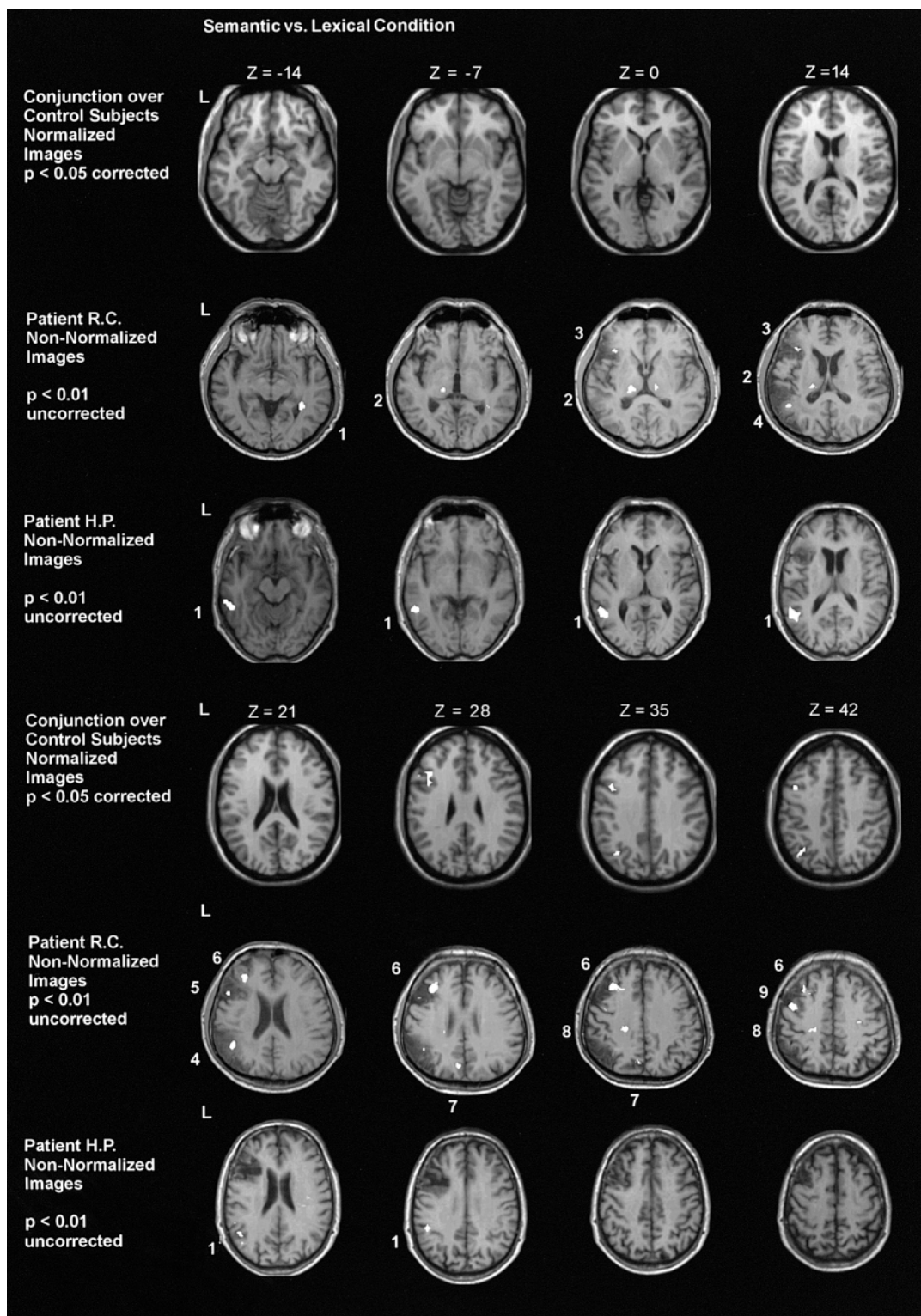


Fig. 1. Spatially non-normalized functional data for RC and HP showing areas of significant activation specific to the semantic relative to the lexical task [S–R]–[L–R] are displayed in the second, third and fifth, sixth rows. The activations are superimposed on eight slices (7 mm interslice interval) parallel to the AC–PC (anterior–posterior commissure) line from the patients’ non-normalized anatomical T1-weighted three-dimensional magnetic resonance image. Probability maps of the conjunction analysis for the normal group at comparable levels along the z-axis with normalized normal group data are shown in the first and fourth rows. The normal group activations (conjunction over subjects) are superimposed on eight slices parallel to the AC–PC line (z-coordinates = –14, –7, 0, 14, 21, 28, 35, 42 mm) from a standard brain (Evans *et al.*, 1994). Activations reaching an individual voxel significance level threshold of $P = 0.001$ and a corrected cluster level < 0.05 for the normal group and a voxel level of $P < 0.01$ uncorrected, 10 voxels, for the patients are displayed.

Table 2. Increases in brain activity, semantic versus lexical task, normal group conjunction analysis ($n = 14$)

Area	Maxima (x, y, z)	BA	z score	Cluster P (corrected)	Talairach ROI for comparison with single subject data	Anatomical description of ROI (x-x), (y-y), (z-z)	N^a
Middle frontal gyrus	-40, 24, 28	9	4.18	0.032	x: (-34 to -60), y: (0 to +45), z: (+9 to +40)	Inferior and middle frontal gyrus (BA 44/45/9)	7
Posterior parietal cortex/ parieto-occipital junction	-32, -60, 49	7/40	4.59	0.028	x: (-30 to -55), y: (-55 to -70), z: (+20 to +50)	Posterior parietal cortex (BA 7/40/39)	8

^a N = number of single subjects with activation within ROI at $P = 0.01$ (uncorrected).

All areas exceeding voxel level: $z > 3.09$ and $P < 0.001$, corrected cluster level $P < 0.05$ (> 16 voxels).

ROI, region of interest.

processing in two cases of TSA after left MCA infarction (RC and HP) using fMRI. By discussing several different mechanisms of recovery we hope to contribute to the debate about localized versus distributed models and the role of the pre-frontal cortex in semantic word processing.

Aphasiological profiles and lesions

In accordance with the disconnection theory of TSA (Lichtheim, 1885), Wernicke's and Broca's areas were largely spared in RC and HP. Their lesions, however, involved parts of the putative conceptual-semantic word processing system proper, as posterior parietal and pre-frontal areas, consistently activated in our normal group as well as in several previous studies (Démonet *et al.*, 1992; Warburton *et al.*, 1996; Binder *et al.*, 1997), were damaged. Consequently, intact conceptual knowledge after a lesion within these areas is incompatible with a simple anatomical disconnection of pathways between intact conceptual knowledge and lexical representations. One could argue that our semantic monitoring task was inadequate to represent conceptual-semantic word processing in general. But even if one admits the limitations of our activation paradigm, that mainly requires superordinate judgement on animate concepts and cannot encompass conceptual processing in general, the recovery of the kind of conceptual-semantic word processing involved in the task was also relevant to the clinically observed recovery of initially impaired auditory single word comprehension (as measured by the AAT). Even if the task can only activate part of the conceptual network, a demonstration of lesions within parts of the network that have led to impairments argues against disconnection theory.

TSA has typically been observed after lesions damaging the temporo-occipital or parieto-occipital junction (Kertesz *et al.*, 1982; Alexander *et al.*, 1989). TSA after frontal lesions were repeatedly discarded as atypical [for a recent review see Berthier (2001)]. Berthier (2001) discussed that primarily atypical language organization (e.g. more bilateral language representation) might contribute to the occurrence of TSA after a left frontal lesion. The results of our functional activation study in both cases make a primarily bilateral organization of language improbable. Our conclusions might

not apply to all cases of TSA with other types of lesions. The finding of an overlap of lesions within the pre-frontal cortex in two cases with TSA taken together with the previously reported cases, however, can be viewed as clinical evidence for a contribution of the pre-frontal cortex to word comprehension. Pre-frontal activations, that were consistently found in a variety of different semantic tasks with functional imaging [discussed and reviewed in Gabrieli *et al.* (1998)], seem to support this conclusion. Because pre-frontal activations in receptive semantic tasks seemed to contradict classical theories of language localization, one was cautious to argue that pre-frontal regions are really involved in word comprehension proper and argued for semantic search, selection or executive demands (Thompson-Schill *et al.*, 1997; Price *et al.*, 1999). But in our view, further clinical evidence for a frontal contribution to word comprehension comes from the fact that the observed preservation of word comprehension in Broca's aphasia (most consistently involving frontal cortex; Willmes and Poeck, 1993) is a result of recovery from initially severe impairments within months or years (Mohr *et al.*, 1978).

Price *et al.* (1999) concluded from their positron emission tomography (PET) study in a patient (SW) with a left inferior pre-frontal lesion without impairment, in a semantic similarity task 4 years post-stroke and showing no perilesional activations, that the inferior frontal activation observed in normal subjects was not a necessary component of the semantic system. Our data are compatible with a modification of this view in showing that independence of the semantic system from the pre-frontal cortex can occur as a result of recovery. One reason for the rarity of reports of pre-frontal lesions leading to TSA might be that most lesion studies have been conducted at a chronic stage.

An objection could be made to our interpretation of comprehension deficits in frontal lesion patients, that it is not the frontal lesion itself in Broca's aphasia or in our TSA cases producing the impairment, but that effects on areas distant to the lesion (diaschisis), for example posterior perisylvian areas, lead to the deficits. Cappa *et al.* (1997) suggested that diaschisis might be the predominant mechanism of recovery in acute aphasia. The classical theory of diaschisis within a localizationist framework states that

Table 3. Increases in brain activity, semantic versus lexical task. Region of interest (ROI) analysis of single normal subject

Case	Posterior pre-frontal <i>x</i> : (-34 to -60) <i>y</i> : (0 to +45) <i>z</i> : (+9 to +40)	Inferior pre-frontal <i>x</i> : (-34 to -60) <i>y</i> : (0 to +45) <i>z</i> : (-14 to +8)	Posterior parietal <i>x</i> : (-30 to -55) <i>y</i> : (-55 to -70) <i>z</i> : (+20 to +50)	Posterior STG <i>x</i> : (-50 to -60) <i>y</i> : (-35 to -55) <i>z</i> : (+10 to +20)	Posterior MTG, posterior ITG <i>x</i> : (-32 to -60) <i>y</i> : (-35 to -68) <i>z</i> : (-21 to +7)
1	No activation	No activation	No activation	No activation	No activation
2		IFG BA 47 -28, 36, -7 <i>z</i> = 3.46	No activation	No activation	ITG BA 37 -60, -68, 7 <i>z</i> = 2.37
3	MFG BA 9 -40, 20, 35 <i>z</i> = 4.53	No activation	G.ang. / LPI BA 39 -44, -68, 28 <i>z</i> = 4.55	No activation	No activation
4	No activation	No activation	No activation	No activation	No activation
5		IFG BA 47 -40, 40, -14 <i>z</i> = 3.82	LPI BA 7 -24, -56, 56 <i>z</i> = 3.76	No activation	No activation
6	MFG BA 46/9 -32, 28, 28 <i>z</i> = 3.81	No activation	GTM/G.ang. BA 39 -32, -72, 14 <i>z</i> = 2.97	No activation	ITG BA 37 -48, -52, -21 <i>z</i> = 4.13 MTG BA 21 -44, -56, 7 <i>z</i> = 3.12
7	MFG BA 9/46 -60, 32, 28 <i>z</i> = 3.30 IFG BA 44 -36, 8, 35 <i>z</i> = 2.99	No activation	No activation	No activation	MTG BA 37 -60, -56, -7 <i>z</i> = 4.30
8		IFG BA 47 -44, 20, -14 <i>z</i> = 3.34	No activation	No activation	ITG BA 20 -68, -40, -7 <i>z</i> = 3.27
9	IFG/MFG BA 45/9 -36, 20, 21 <i>z</i> = 4.05 MFG BA 46/9 -40, 28, 28 <i>z</i> = 3.51	IFG BA 47 -44, 36, -7 <i>z</i> = 3.59	GTM / G. ang. BA 39 -40, -72, 21 <i>z</i> = 3.04	No activation	MTG BA 21 -36, -52, 7 <i>z</i> = 4.07
10		IFG 45 -40, 40, 0 <i>z</i> = 4.18	No activation	STG BA 22 -56, -52, 21 <i>z</i> = 2.35	ITG BA 37 -32, -60, -14 <i>z</i> = 4.38
11		MFG 46/9 -44, 44, 0 <i>z</i> = 4.15	LPI BA 7/19 -36, -72, 42 <i>z</i> = 3.94	No activation	ITG BA 20 -52, -40, -21 <i>z</i> = 4.47
12	MFG 9/46 -28, 36, 28 <i>z</i> = 3.30	No activation	LPI BA 40 -64, -44, 35 <i>z</i> = 3.34	No activation	No activation
13	MFG/IFG BA 9/46 -36, 40, 21 <i>z</i> = 3.17	No activation	LPI BA 7/40 -40, -44, 42 <i>z</i> = 2.44	No activation	No activation
14	IFG/MFG BA 9 -52, 24, 40 <i>z</i> = 3.16	No activation	LPI BA 40 -48, -48, 49 <i>z</i> = 3.12	No activation	MTG/ITG BA 21/37 -56, -48, 0 <i>z</i> = 3.84
<i>N</i> ^a	7	6	8	1	8

^aNumber of subjects with activation at $P = 0.01$.

All areas exceeding a voxel level significance threshold of $z = 2.33$, $P = 0.01$ (uncorrected) within the defined ROI are reported.

ITG, inferior temporal gyrus; MTG, middle temporal gyrus; STG, superior temporal gyrus; IFG, inferior frontal gyrus; MFG, middle frontal gyrus; LPI, inferior parietal lobule; G. ang., angular gyrus.

Coordinates in *italic* = maximum out of ROI range, but activated cluster extends into ROI.

reversible deficits are due to functional deactivation of structurally unaffected areas distant to the lesion (Feeny and Baron, 1986). The areas lesioned in RC and HP, however, were likely to have contributed to their initially impaired semantic word processing prior to stroke, based on the

evidence of our, and previous, functional activation studies. This would contradict the classical concept of diaschisis. A less strict interpretation of diaschisis, however, would be compatible with our data. When multiple representations of closely related functions are assumed, regression of diaschisis

Table 4. d' values for the tasks in each subject

Normal subjects	Age	Sex	d' difference (d' semantic–d' lexical)	Lexical task d'	Semantic task d'
1	23	m	–3.6	6.8	3.2
2	25	m	2.0	4.9	6.8
3	25	m	0	6.8	6.8
4	26	m	0	6.8	6.8
5	25	m	–1.9	4.8	3.0
6	24	m	1.6	5.2	6.8
7	27	m	1.3	3.2	4.6
8	65	m	–1.8	4.3	2.4
9	60	m	–1.5	4.1	2.6
10	58	m	0	2.9	2.9
11	54	m	–1.6	6.8	5.2
12	52	m	0	6.8	6.8
13	53	m	–3.9	6.8	2.9
14	50	m	3.6	3.3	6.8
Mean			–0.4	5.2	4.8
Range			(–3.9–3.6)	(2.9–6.8)	(2.4–6.8)
RC		m	–3.2	5.2	2.0 ^a
HP		m	–0.7	2.6 ^a	1.9 ^a

Wilcoxon sum rank test: no significant differences between the conditions for the normal subjects ($P < 0.10$) for d' .

^aOut of normal range.

could explain the time a partially redundant system needs to compensate for damaged parts by areas left structurally unaffected.

Functional activations associated with recovery of conceptual-semantic word processing in RC and HP

The two most important results of our functional activation study in RC and HP were: (1) that at the time of recovery of auditory comprehension (around 6 months post-stroke), left posterior perisylvian areas were functionally active, furthermore, specifically active during conceptual-semantic versus lexical decision [S–L] and (2) that there was no relevant activation of right hemispheric cortex associated with semantic word processing.

Activation of the posterior superior temporal gyrus (Wernicke's area) in both patients was a surprising finding, as Wernicke's area was not activated in our normal group and even on a single case basis there was an activation only in one subject (Table 3). Although Wernicke's area was not activated in our study, a variety of evidence from other functional activation (Warburton *et al.*, 1996) as well as clinical studies (Naeser *et al.*, 1987; Willmes and Poeck, 1993) leaves little doubt that the posterior superior temporal gyrus is involved in auditory comprehension. The exact role of Wernicke's area, however, is still under debate. In a model proposed by Mesulam (1998) it is suggested to function as a 'transmodal gateway' that mediates between word form and distributed semantic representations. A TSA-like picture has recently been reported after electrocortical stimulation within the left posterior middle temporal gyrus and superior temporal gyrus. The authors suggest disconnection of phono-

Table 5. Increases in brain activity, semantic versus lexical task, in RC and HP, non-normalized data

Number corresponding to Fig. 1	Area	z score	Cluster size at $P = 0.01$
RC			
1	Right periventricular	4.52	19
2	Left thalamus	3.84	26
3	Left anterior inferior frontal gyrus	4.40	12
4	Left posterior superior temporal gyrus, parietal extension	4.32	23
5	Left middle frontal gyrus	4.21	10
6	Left anterior middle frontal gyrus	4.86	98
7	Left pre-cuneus	4.24	13
8	Left pre-central	4.43	24
9	Left posterior middle frontal gyrus	4.17	20
HP			
1	Left posterior superior, middle and inferior temporal gyrus	4.50	54

All areas exceeding a voxel level significance threshold of $z = 3.09$, $P = 0.001$ (uncorrected) and a cluster size ≥ 10 are reported for RC and HP.

logy from lexical-semantic by lesions in Wernicke's area (Boatman *et al.*, 2000) compatible with Mesulam's model. As the posterior superior temporal gyrus probably has related functions to the semantic processing measured in our task and is at least activated in one normal subject, one cannot speak of a vicarious activation. Activation of the spared Wernicke's area in RC and HP demonstrates that it is functionally intact. This points to a compensatory role in the recovery of semantic word processing, either as part of a distributed conceptual system or as a correlate of lexical processes that could partially compensate for damaged conceptual-semantic functions.

The demonstration of a preserved left hemispheric dominance for conceptual-semantic word processing in our patients conflicts with the left-to-right transfer hypothesis of language recovery supported by the studies of Weiller *et al.* (1995), Buckner *et al.* (1996), Ohyama *et al.* (1996), Cao *et al.* (1999), Musso *et al.* (1999) and Thulborn *et al.* (1999) or a primarily bilateral representation of word processing in some individuals (Frackowiak, 1997) as correlates of good recovery. Other functional activation studies have stressed the importance of left hemispheric compensation in the recovery from aphasia (Karbe *et al.*, 1998; Heiss *et al.*, 1999; Miura *et al.*, 1999; Warburton *et al.*, 1999). It is not clear, however, in the cited studies reporting right hemispheric or bilateral activations in aphasic patients, whether these relate to semantic or to lexical or pre-lexical phonological processing, as these levels of processing were not subtracted away in the critical comparisons. In our normal group study we were able to show that hemispheric lateralization within the temporal lobe depended on the level of auditory word processing,

i.e. the control tasks used for subtraction. Left lateralization was observed for semantic word processing, whereas word form processing led to bilateral temporal activations (Zahn *et al.*, 2000) in accordance with evidence from clinical studies [reviewed in Kinsbourne (1998)] as well as a previous functional activation study (Mummery *et al.*, 1999a). Consequently right hemispheric activity in patients is not necessarily the result of a left-to-right hemispheric shift as long as it has not been demonstrated to be specifically related to a highly left lateralized function, such as semantic word processing. In a fMRI study, Calvert *et al.* (2000) actually showed differential lateralization of activations for phonological (to the right) and semantic (to the left) processing after recovery from aphasia.

Thalamic activations in RC could be involved in lexical retrieval processes, as suggested by clinical observations of word-finding difficulties after left thalamic stroke (Sodeyama *et al.*, 1995). Increases in the pre-cuneus have been observed in visual imagery tasks (Kosslyn *et al.*, 1995) and in semantic tasks that were likely to engage visual imagery (Démonet *et al.*, 1992). Visual imagery could partially compensate for conceptual-semantic deficits in RC, as all stimuli in the present task denoted concrete entities.

Finally, methodological limitations of the present and previous functional activation studies in aphasic stroke patients have to be discussed. Most studies have compared patients with groups or subgroups of normals, and do not report single normal subject data. This might be due to the unsolved problem of how to interpret the considerable interindividual variability in single subject data: functional or anatomical variability (Steinmetz and Seitz, 1991), different cognitive strategies or low statistical power in the single case. In our single subject analysis, we found that although posterior parietal activations were highly significant in the conjunction over subjects, on a single case basis activity was detectable in only eight of 14 single subjects at $P = 0.01$. This might be due to the higher type two error in the single case analysis. Therefore, the lack of posterior parietal activation in RC cannot be viewed as abnormal. Our approach of using anatomically non-normalized patient data led to a higher precision in anatomical localization and detection of perilesional activations. It, however, precluded a direct statistical comparison of patient and normal group data as in Price *et al.* (1998, 1999). Another point of criticism could be that our patients performed below the normal range in the semantic tasks. This could have led to abnormal activation patterns due to abnormal performance that are not comparable with activation patterns in normals (Price and Friston, 1999). Our interpretation of deviant functional activations in RC and HP can thus only concern the pathophysiology of recovery from TSA and not the functional anatomy of semantic processing in normals. In our view, as long as patients' performances demonstrate that they are specifically engaged in the task and performing significantly above chance level (in our case two standard deviations above, i.e. d' around 2), one is still measuring a specific response to the

task in question and can thus derive valid conclusions. Looking at our patients' data it is surprising, given their subnormal performance, that their activation patterns are comparable with normal subjects' activations with respect to important aspects: demonstration of (1) left hemispheric lateralization (RC and HP), (2) posterior inferior and middle pre-frontal activations (RC) and (3) posterior middle/inferior temporal activations (HP) (also detectable in eight of 14 normal subjects). Our main conclusions concerning the organization of the normal semantic system are still valid when only these normal aspects of functional activation patterns in RC and HP are considered.

Although our, as well as other, functional activation studies in aphasic patients do have several methodological limitations, a careful interpretation of the data can still lead to valid conclusions, in our view.

General discussion

The functional activation studies showed posterior inferior parietal, parieto-occipital, parieto-temporal and temporo-occipital activations as correlates of semantic processing (Démonet *et al.*, 1992; Vandenberghe *et al.*, 1996; Warburton *et al.*, 1996; Binder *et al.*, 1997). Semantic deficits have been observed in different patients with non-overlapping lesions in the temporolimbic cortex after herpes simplex encephalitis [reviewed in Gainotti *et al.* (1995)], and after left temporo-occipital (Kertesz *et al.*, 1982; Alexander *et al.*, 1989) and parieto-occipital ischaemia (Kertesz *et al.*, 1982). In neurodegenerative dementias, semantic impairment correlated with left inferior temporal (Mummery *et al.*, 1999b) and left parietal (Grossman *et al.*, 1997; Desgranges *et al.*, 1998) and pre-frontal (Desgranges *et al.*, 1998) affection. The anatomical variability of reported lesions associated with semantic impairments could either be explained on the basis of interindividual variability (Steinmetz and Seitz, 1991; Frackowiak, 1997; Berthier, 2001) or attributed to the distributed nature of the system itself (Alexander *et al.*, 1989). Although there is evidence for specific subfunctions of anatomical regions within this system (Gainotti *et al.*, 1995), our study provided evidence for at least limited redundancy, suggesting close relationships between functionally differentiated areas.

Conclusions

The present study showed that damage to only pre-frontal or to pre-frontal and posterior parietal areas activated in normal subjects during conceptual-semantic word processing led to acute TSA in two consecutive cases. The rapid recovery of language comprehension was associated with left hemispheric activations, in both cases parts of Wernicke's area. Wernicke's area, although only activated in one normal subject in this contrast, has been demonstrated as relevant to language comprehension in numerous previous studies. This suggests that a redundancy recovery mechanism rather than a vicari-

ation process was in operation in our cases. Redundancy recovery within the left hemisphere supports distributed models of semantic processes and multiple left hemispheric representations of closely related functions. A lesion confined to only part of such a distributed semantic system seems to be partially compensated for by intact areas of the same system with related functions. Further prospective clinical studies are needed to assess the frequency of auditory comprehension deficits in the acute phase after left prefrontal lesions and their recovery.

Acknowledgements

We thank Professor Dr J. Noth, Dr S. Fellows and two anonymous reviewers for their valuable comments on the manuscript. This study was supported by a grant to MS from the Interdisciplinary Research Centre for the Pathogenesis of Cognitive Disorders at the RWTH Aachen.

References

- Alexander MP, Hiltbrunner B, Fischer RS. Distributed anatomy of transcortical sensory aphasia. *Archives of Neurology* 1989; 46: 885–92.
- Berthier ML. Review. Unexpected brain–language relationships in aphasia: Evidence from transcortical sensory aphasia associated with frontal lobe lesions. *Aphasiology* 2001; 15: 99–130.
- Binder JR, Frost JA, Hammeke TA, Cox RW, Rao SM, Prieto T. Human brain language areas identified by functional magnetic resonance imaging. *Journal of Neuroscience* 1997; 17: 353–62.
- Boatman D, Gordon B, Hart J, Selnes O, Miglioretti D, Lenz F. Transcortical sensory aphasia: revisited and revised. *Brain* 2000; 123: 1634–42.
- Buckner RL, Corbetta M, Schatz J, Raichle ME, Petersen SE. Preserved speech abilities and compensation following prefrontal damage. *Proceedings of the National Academy of Sciences of the USA* 1996; 93: 1249–53.
- Calvert GA, Brammer MJ, Morris RG, Williams SC, King N, Matthews PM. Using fMRI to study recovery from acquired dysphasia. *Brain and Language* 2000; 71: 391–9.
- Cao Y, Vikingstad EM, George KP, Johnson AF, Welch KM. Cortical language activation in stroke patients recovering from aphasia with functional MRI. *Stroke* 1999; 30: 2331–40.
- Cappa SF, Perani D, Grassi F, Bressi S, Alberoni M, Franceschi M *et al.* A PET follow-up study of recovery after stroke in acute aphasics. *Brain and Language* 1997; 56: 55–67.
- Demonet JF, Chollet F, Ramsay S, Cardebat D, Nespoulous JL, Wise R *et al.* The anatomy of phonological and semantic processing in normal subjects. *Brain* 1992; 115: 1753–68.
- Desgranges B, Baron JC, de la Sayette V, Petit Taboue MC, Benali K, Landeau B *et al.* The neural substrates of memory systems impairment in Alzheimer's disease. A PET study of resting brain glucose utilization. *Brain* 1998; 121: 611–31.
- Evans AC, Kamber M, Collins DL, MacDonald D. An MRI-based probabilistic atlas of neuroanatomy. In: Shorvon SD, Fish DK, Andermann F, Wyder GM, Stefan H, editors. *Magnetic resonance scanning and epilepsy*. New York: Plenum Press, 1994: 263–74.
- Feeney DM, Baron J-C. Diaschisis. *Stroke* 1986; 17: 817–30.
- Finger S, Almlí CR. Brain damage and neuroplasticity: mechanisms of recovery or development? *Brain Research* 1985; 357: 177–86.
- Frackowiak RS. The cerebral basis of functional recovery. In: Frackowiak RS, Friston KJ, Frith CD, Dolan RJ, Mazziotta JC, editors. *Human brain function*. San Diego: Academic Press, 1997: 275–300.
- Friston KJ, Ashburner J, Frith CD. Spatial registration and normalization of images. *Human Brain Mapping* 1995; 2: 1–25.
- Gabrieli JD, Poldrack RA, Desmond JE. The role of left prefrontal cortex in language and memory. *Proceedings of the National Academy of Sciences of the USA* 1998; 95: 906–13.
- Gainotti G, Silveri MC, Daniele A, Giustolisi L. Neuroanatomical correlates of category-specific semantic disorders: a critical survey. *Memory* 1995; 3: 247–64.
- Geschwind N. Disconnexion syndromes in animals and man. *Brain* 1965; 88: 237–94.
- Grossman M, Payer F, Onishi K, White-Devine T, Morrison D, D'Esposito M *et al.* Constraints on the cerebral basis for semantic processing from neuroimaging studies of Alzheimer's disease. *Journal of Neurology, Neurosurgery and Psychiatry* 1997; 63: 152–8.
- Heiss WD, Kessler J, Thiel A, Ghaemi M, Karbe H. Differential capacity of left and right hemispheric areas for compensation of aphasia. *Annals of Neurology* 1999; 45: 430–8.
- Hillert D. On processing lexical meanings in aphasia and Alzheimer's disease: some (re)considerations. *Brain and Language* 1999; 69: 95–118.
- Huber W, Poeck K, Willmes K. The Aachen Aphasia Test. *Advances in Neurology* 1984; 42: 291–303.
- Karbe H, Thiel A, Weberluxenburger G, Herholz K, Kessler J, Heiss WD. Brain plasticity in poststroke aphasia: What is the contribution of the right hemisphere? *Brain and Language* 1998; 64: 215–30.
- Kertesz A, Sheppard A, MacKenzie R. Localization in transcortical sensory aphasia. *Archives of Neurology* 1982; 39: 475–8.
- Kinsbourne M. The right hemisphere and recovery from aphasia. In: Stemmer B, Whitaker HA, editors. *Handbook of neurolinguistics*. San Diego: Academic Press, 1998: 386–94.
- Kosslyn SM, Thompson WL, Kim IJ, Alpert NM. Topographical representations of mental images in primary visual cortex. *Nature* 1995; 378: 496–8.
- Lichtheim L. On aphasia. *Brain* 1885; 7: 433–84.
- Mai JK, Assheuer J, Paxinos G. *Atlas of the human brain*. San Diego: Academic Press, 1998.
- Marshall JF. Brain function: neural adaptations and recovery from injury. *Annual Review of Psychology* 1984; 35: 277–308.
- Mesulam MM. From sensation to cognition. *Brain* 1998; 121: 1013–52.
- Miura K, Nakamura Y, Miura F, Yamada I, Takahashi M, Yoshikawa A *et al.* Functional magnetic resonance imaging to word generation task in a patient with Broca's aphasia. *Journal of Neurology* 1999; 246: 939–42.
- Mohr JP, Pessin MS, Finkelshtein S, Funkenstein HH, Duncan GW, Davis KR. Broca aphasia: pathologic and clinical. *Neurology* 1978; 28: 311–24.
- Mummery CJ, Ashburner J, Scott SK, Wise RJ. Functional neuroimaging of speech perception in six normal and two aphasic subjects. *Journal of the Acoustical Society of America* 1999a; 106: 449–57.
- Mummery CJ, Patterson K, Wise RJ, Vandenberg R, Price CJ, Hodges JR. Disrupted temporal lobe connections in semantic dementia. *Brain* 1999b; 122: 61–73.
- Musso M, Weiller C, Kiebel S, Müller SP, Bülow P, Rijntjes M. Training-induced brain plasticity in aphasia. *Brain* 1999; 122: 1781–90.
- Naeser MA, Helm Estabrooks N, Haas G, Auerbach S, Srinivasan M. Relationship between lesion extent in 'Wernicke's Area' on computed tomographic scan and predicting recovery of comprehension in Wernicke's aphasia. *Archives of Neurology* 1987; 44: 73–82.
- Ohyama M, Senda M, Kitamura S, Ishii K, Mishina M, Terashi A. Role of the nondominant hemisphere and undamaged area during word repetition in poststroke aphasics. A PET activation study. *Stroke* 1996; 27: 897–903.
- Phillips CG, Zeki S, Barlow HB. Localization of function in the cerebral cortex: past, present and future. *Brain* 1984; 107: 327–61.
- Pietrzyk U, Herholz K, Fink GR, Jacobs A, Mielke R, Slansky I *et al.* An interactive technique for three-dimensional image registration: Validation for PET, SPECT, MRI and CT brain studies. *Journal of Nuclear Medicine* 1994; 35: 2011–8.
- Price CJ. The functional anatomy of word comprehension and production. *Trends in Cognitive Sciences* 1998; 2: 281–8.
- Price CJ, Friston KJ. Cognitive conjunctions. A new approach to brain activation experiments. *Neuroimage* 1997; 5: 261–70.
- Price CJ, Friston KJ. Scanning patients with tasks they can perform. *Human Brain Mapping* 1999; 8: 102–8.
- Price CJ, Howard D, Patterson K, Warburton EA, Friston KJ, Frackowiak RS. A functional neuroimaging description of two deep dyslexic patients. *Journal of Cognitive Neuroscience* 1998; 10: 303–15.
- Price CJ, Mummery CJ, Moore CJ, Frackowiak RS, Friston KJ. Delineating necessary and sufficient neural systems with functional imaging studies of neuropsychological patients. *Journal of Cognitive Neuroscience* 1999; 11: 371–82.
- Sodeyama N, Tamaki M, Sugishita M. Persistent pure verbal amnesia and transient aphasia after left thalamic infarction. *Journal of Neurology* 1995; 242: 289–94.

- Springer L, Huber W, Schlenck KJ, Schlenck C. Agrammatism: Deficit or compensation? Consequences for aphasia therapy. *Neuropsychological Rehabilitation* 2000; 10: 279–309.
- Steinmetz H, Seitz RJ. Functional anatomy of language processing: neuroimaging and the problem of individual variability. *Neuropsychologia* 1991; 29: 1149–61.
- Thompson-Schill SL, D'Esposito M, Aguirre GK, Farah MJ. Role of left inferior prefrontal cortex in retrieval of semantic knowledge: a reevaluation. *Proceedings of the National Academy of Sciences of the USA* 1997; 94: 14792–7.
- Thulborn KR, Carpenter PA, Just MA. Plasticity of language-related brain function during recovery from stroke. *Stroke* 1999; 30: 749–54.
- Vandenberghe R, Price C, Wise R, Josephs O, Frackowiak RS. Functional anatomy of a common semantic system for words and pictures. *Nature* 1996; 383: 254–6.
- Warburton E, Wise RJ, Price CJ, Weiller C, Hadar U, Ramsay S *et al.* Noun and verb retrieval by normal subjects. *Studies with PET. Brain* 1996; 119: 159–79.
- Warburton E, Price CJ, Swinburn K, Wise RJ. Mechanisms of recovery from aphasia: evidence from positron emission tomography studies. *Journal of Neurology, Neurosurgery and Psychiatry* 1999; 66: 155–61.
- Weiller C, Isensee C, Rijntjes M, Huber W, Müller S, Bier D *et al.* Recovery from Wernicke's aphasia: a positron emission tomographic study. *Annals of Neurology* 1995; 37: 723–32.
- Willmes K, Poeck K. To what extent can aphasic syndromes be localized? *Brain* 1993; 116: 1527–40.
- Zahn R, Huber W, Drews E, Erberich S, Krings T, Willmes K *et al.* Hemispheric lateralization at different levels of human auditory word processing: a functional magnetic resonance imaging study. *Neuroscience Letters* 2000; 287: 195–8.

Recovery of semantic word processing in transcortical sensory aphasia: a functional magnetic resonance imaging study

R. Zahn, W. Huber, E. Drews, K. Specht, S. Kemeny, W. Reith, K. Willmes and M. Schwarz

Abstract

In a previous functional magnetic resonance imaging (fMRI) study with normal subjects, we demonstrated regions related to conceptual-semantic word processing around the first frontal sulcus (BA 9) and the posterior parietal lobe (BA 7/40) in agreement with several previous reports. We had the possibility, using the same fMRI paradigm, to study two consecutive cases with left middle cerebral artery (MCA) infarction (RC and HP) and lesions affecting either solely the pre-frontal (HP) or both the pre-frontal and posterior parietal part of the network activated in normal subjects (RC). Both patients showed transcortical sensory aphasia (TSA) on acute assessment. This contradicts classical disconnection accounts of the syndrome stating intact conceptual representations in TSA. Their recovery of language comprehension was associated with activation of a left hemispheric network. Mainly activations of left perilesional pre-frontal regions (RC), left Wernicke's area (RC and HP) or the left posterior middle and inferior temporal cortex (HP) were demonstrated in the TSA patients. The latter findings suggest that in our cases of TSA functional take-over has occurred in regions with related functions ('redundancy recovery') rather than in previously unrelated areas ('vicarious functioning'). Our data support distributed models of conceptual-semantic word processing and multiple left hemispheric representations of closely related functions.

Journal

Neurocase 2002; 8: 376–86

Neurocase Reference Number:

O271

Primary diagnosis of interest

Transcortical sensory aphasia

Author's designation of case

RC, HP

Key theoretical issue

- Recovery of conceptual-semantic word processing

Key words: functional magnetic resonance imaging; semantics; pre-frontal cortex; Wernicke's area; aphasia physiopathology; aphasia transcortical sensory physiopathology; recovery; stroke

Scan, EEG and related measures

Fluid-attenuated-inversion-recovery-, 3-D MRI, functional MRI

Standardized assessment

Aachen Aphasia Test

Other assessment

Neurological examination, Edinburgh Handedness Inventory

Lesion location

- Left prefrontal (HP, RC) and posterior parietal (RC)

Lesion type

Ischaemic cardio-embolic stroke

Language

English