

Pure Alexia and Hemianopia Related to Dissection of the Internal Carotid Artery

Cynthia Resende Campos, Felipe Fregni,
Ayrton Roberto Massaro, Milberto Scaff

Department of Neurology, School of Medicine of the University of São Paulo, Brazil

Carotid artery dissection is an important cause of stroke and transient ischemic attacks in young and middle-aged patients [1–4]. For hemodynamic and anatomical reasons, it is usually associated with ischemic strokes along the anterior and middle cerebral artery (MCA) territories and in the retinal artery, with most of the patients usually presenting focal deficits related to the involvement of these territories [4]. Posterior cerebral artery (PCA) territory is rarely affected alone in a patient with carotid disease. When it occurs, it is usually associated with the fetal pattern of the circle of Willis which permits access to embolization from the carotid artery causing occipital infarction [5–7]. Few reports of PCA infarctions due to internal carotid artery dissection have been published and the visual field deficit was the main symptom [5, 6].

Differing from previous reports, we describe a patient who presented with pure alexia and mild anomia as the main symptoms of left carotid artery dissection. She is a 49-year-old woman, right-handed, Brazilian, with reading fluency in French and English, having completed university studies and developed commercial activities related to oral and written language. She came to the emergency department because she had noticed difficulty and slowness in reading words for the past 8 days. She had to analyze letter by letter to grasp the meaning. She also developed difficulty in naming objects and people, but she did not complain of any modification in her visual field. On further questioning, the patient referred to severe headaches 2 months earlier, without neck pain, but she had not noticed any modification in her reading skills until 8 days prior to the consultation. She denied transient monocular blindness or hemi-

spheric ischemic attacks. Neurological examination concluded right homonymous hemianopia and a light aphasia with naming disturbances detected in tests with different modalities of stimulus presentation, but no color naming defect. The written language was normal. The patient was only capable of reading by using the grapheme-phoneme conversion, and had difficulty in reading foreign and irregular words which requested global reading and depended on the knowl-

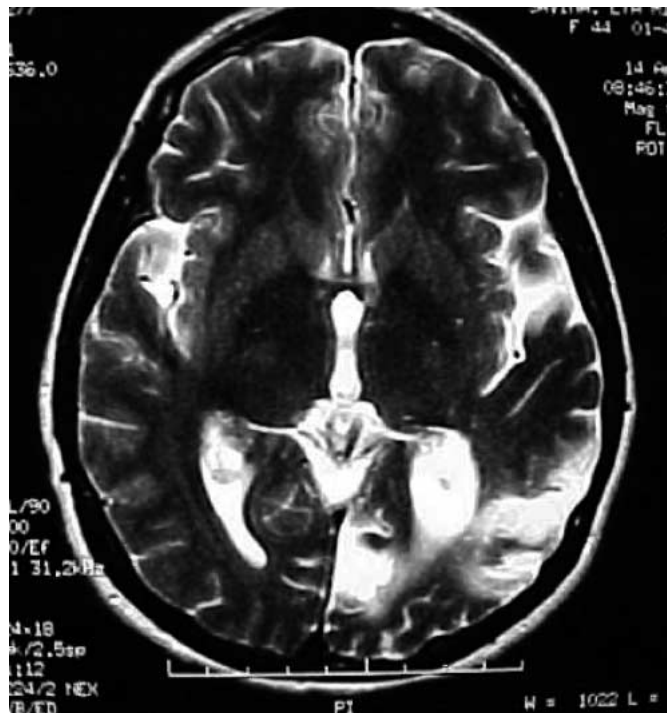


Fig. 1. Axial view of T₂-weighted MRI showing ischemic lesions in the left PCA and posterior MCA temporal territories.

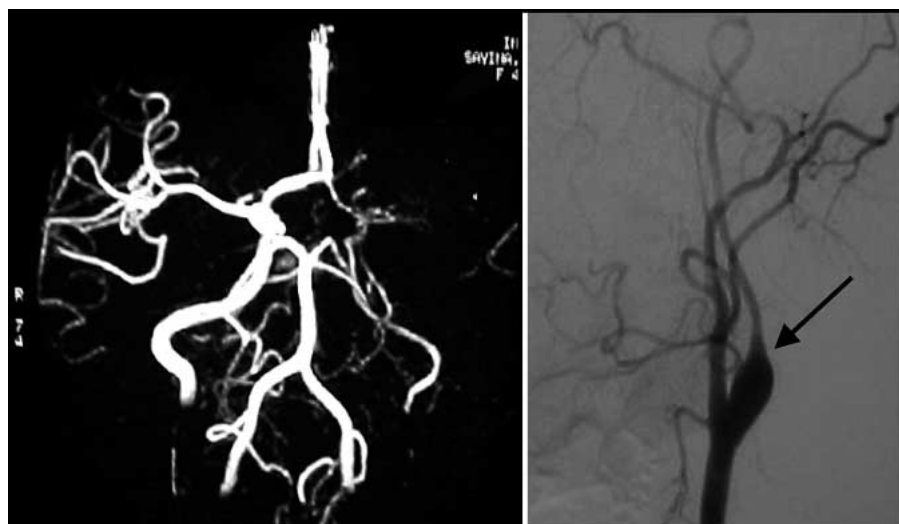

Fig. 2. Left: MRI angiogram of the circle of Willis showing reduced left carotid artery flow and the poor filling of the left PCA through a hypoplastic P₁. Right: digital angiography in the lateral view of the left carotid artery showing gradually tapering stenosis suggestive of arterial dissection (black arrow).

edge of their meaning for the correct production. The rest of the physical examination, her blood pressure and cardiac investigation were normal. Magnetic resonance imaging (MRI) showed ischemic areas in the left PCA and in the posterior MCA temporal territories (fig. 1). The magnetic resonance angiography showed reduced left internal carotid artery (ICA) and left MCA flows and narrowing of the left PCA, especially after the middle portion (P₂) with a poor pattern of distal vessels. There was also asymmetry of the proximal portion (P₁) with a hypoplastic left P₁, suggesting that this area was originally supplied by the left ICA (fetal pattern). Digital subtraction angiography was performed and showed a decreased caliber of the left ICA suggestive of arterial dissection from its beginning until the ophthalmic artery and occlusion of the beginning of the left MCA (segment M₁) (fig. 2). Ischemic lesions related to embolization due to ICA dissection associated with a persistent fetal configuration of the left PCA were diagnosed.

The frequency of PCA territory infarcts in stroke data banks is approximately 10% [8, 9]. Cardiogenic embolism or embolism of undetermined source are the main mechanisms. When arterial thromboembolic is the suspected mechanism of stroke, it is reasonable to assume that posterior circulation is the source. But in almost 2% of these infarcts, PCA is supplied from the carotid artery (fetal pattern) [8], which permits embolization from the carotid artery causing occipital infarction. This means that, even in the presence of suspected isolated posterior circulation based on clinical signs such as visual field disturbance, alexia, amnesic aphasia, we must not exclude the possibility of anterior circulation disease. This becomes most important if we consider that carotid artery dissection is an important cause of stroke in young and middle-aged patients. This is the first case in the literature of alexia after stroke due to internal carotid artery dissection.

References

- 1 Schievink WI, Mokir B, O'Fallon WM: Recurrent spontaneous cervical-artery dissection. *N Engl J Med* 1994;330:393–397.
- 2 Bogousslavsky J, Regli F: Ischemic stroke in adults younger than 30 years of age: Cause and prognosis. *Arch Neurol* 1987;44:479–482.
- 3 Gautier JC, Pradat-Diehl P, Loron P: Accidents vasculaires cérébraux des sujets jeunes: Une étude de 133 patients âgés de 9 à 45 ans. *Rev Neurol* 1989;145:437–442.
- 4 Schievink WI: Spontaneous dissection of the carotid and vertebral arteries. *N Engl J Med* 2001;344:898–906.
- 5 Bourcier-Bareil F, Hommet C, Cottier JP, Arsene S, Rossazza C: Hemianopsia related to dissection of the internal carotid artery. *J Neuroophthalmol* 1999;19:136–139.
- 6 Kuker W, Mull M, Block F, Thron A: Carotid artery dissections presenting as isolated posterior cerebral artery infarctions. *J Neurol* 1997;244:324–327.
- 7 Pessin MS, Kwan ES, Scott RM, Hedges TR 3rd: Occipital infarction with hemianopsia from carotid occlusive disease. *Stroke* 1989;20:409–411.
- 8 Brandt T, Steinke W, Thie A, Pessin MS, Caplan LR: Posterior cerebral artery territory infarcts: Clinical features, infarct topography, causes and outcome. Multicenter results and a review of the literature. *Cerebrovasc Dis* 2000;10:170–182.
- 9 Yamamoto Y, Georgiadis AL, Chang HM, Caplan LR: Posterior cerebral artery territory infarcts in the New England Medical Center Posterior Circulation Registry. *Arch Neurol* 1999;56:824–832.

Dr. Cynthia Resende Campos, MD
Departamento de Neurologia, Hospital das Clínicas da FMUSP
Av. Dr. Enéas de Carvalho Aguiar, 255, 5403-000 São Paulo (Brazil)
Tel./Fax +55 11 30696401, E-Mail Cynthia-98@rocketmail.com