

# Epilepsia Partialis Continua Associated With Widespread Gliomatosis Cerebri

Eli Shahar, MD\*, Uri Kramer, MD†, Dvora Nass, MD‡, and David Savitzki, MD\*

We report an uncommon association of intractable epilepsy partialis continua that was the main presentation of widespread gliomatosis cerebri in two females. Both children had a preceding prolonged secondary generalized seizure 2-4 months before the evolution of epilepsy partialis continua, including recurrent clusters of left-sided myoclonic twitching and sensory impairment. During these events, the children remained fully alert. These seizures were corroborated by prolonged focal epileptic spike/wave discharges evident on the electroencephalograms. Cerebral magnetic resonance imaging in the first patient demonstrated a wide area of increasing signals over the right frontocentral regions, along with diffuse cortical-subcortical infiltration impinging on the left hemisphere. In the second patient a cortical lesion was suspected. Evaluation for Rasmussen's encephalitis, focal cortical dysplasia, or a gliomatous process was conducted; the patients underwent a stereotactic brain biopsy in which the histologic findings were compatible with gliomatosis cerebri with diffuse widespread infiltration of glioma cells with no constitution of a circumscribed tumor mass. The first patient was treated with cranial radiation, chemotherapy, steroids, and combined anti-epileptic therapy. The focal seizures gradually but markedly decreased in frequency, and sensory impairment abated within 18 months after establishment of the diagnosis and ensuing therapy. Cognition remains intact. The second female died 2 years after presentation despite massive chemotherapy and antiepileptic medications. Although rare, gliomatosis cerebri should be taken into account in the differential diagnosis of

epilepsia partialis continua in children to facilitate a rapid diagnosis and initiation of prompt treatment of this rare disorder that may respond to a concurrent effective combination of cranial radiation, chemotherapy, and antiepileptic medications. © 2002 by Elsevier Science Inc. All rights reserved.

Shahar E, Kramer U, Nass D, Savitzki D. Epilepsia partialis continua associated with widespread gliomatosis cerebri. *Pediatr Neurol* 2002;27:392-396.

## Introduction

Epilepsia partialis continua is defined as ongoing relentless clonic muscle twitching, sometimes in rapid succession, that is mainly confined to one side of the body and can last for weeks or months, associated with progressive pyramidal weakness and sensory impairment, although there is no alteration of consciousness, commonly associated with focal epileptic discharges [1-3].

Epilepsia partialis continua in adults has been associated with various underlying etiologies, including infections, cerebrovascular events, and tumors [3]. Epilepsia partialis continua in children has most commonly been associated with Rasmussen's encephalitis [2,4-5], which is a progressive autoimmune unilateral cortical destructive process. Rasmussen encephalitis was the most common underlying etiology of epilepsy partialis continua in children under 16 years of age in a survey of 32 patients reported by Cockerel et al. [2]. Epilepsia partialis continua in children was also associated with congenital structural abnormalities of the cortex secondary to migrational disorders [6-10] however, to a lesser extent, compared with Rasmussen's encephalitis. These abnormalities included focal cortical dysplasia [6-8] and hemimegalencephaly [9-10]. Epilepsia partialis continua in children was also rarely associated with various respiratory chain mitochondrial disorders, including the MELAS syndrome in two young sisters [11], Leigh syndrome and partial deficiency of cytochrome C oxidase [12], NADH-coenzyme Q reductase deficiency [13], and, in a 16-year-old male, it was associated with a homoplasmic mitochondrial tRNA (Ser/UCN) mutation [14].

In this report, we present a unique association of epilepsy partialis continua in two females, which was the main clinical manifestation of gliomatosis cerebri, namely,

From the \*Child Neurology Unit and Epilepsy Service; Meyer Children Hospital; Rambam Medical Center; Haifa; the †Pediatric Neurology Unit; Tel-Aviv Souraski Medical Center; Tel Aviv; and the ‡Department of Pathology; Sheba Medical Center; Tel Aviv, Israel.

Communications should be addressed to: Dr. Shahar; Child Neurology Unit & Epilepsy Service; Meyer Children Hospital; Rambam Medical Center; Haifa 31096, Israel. Received January 16, 2002; accepted May 13, 2002.

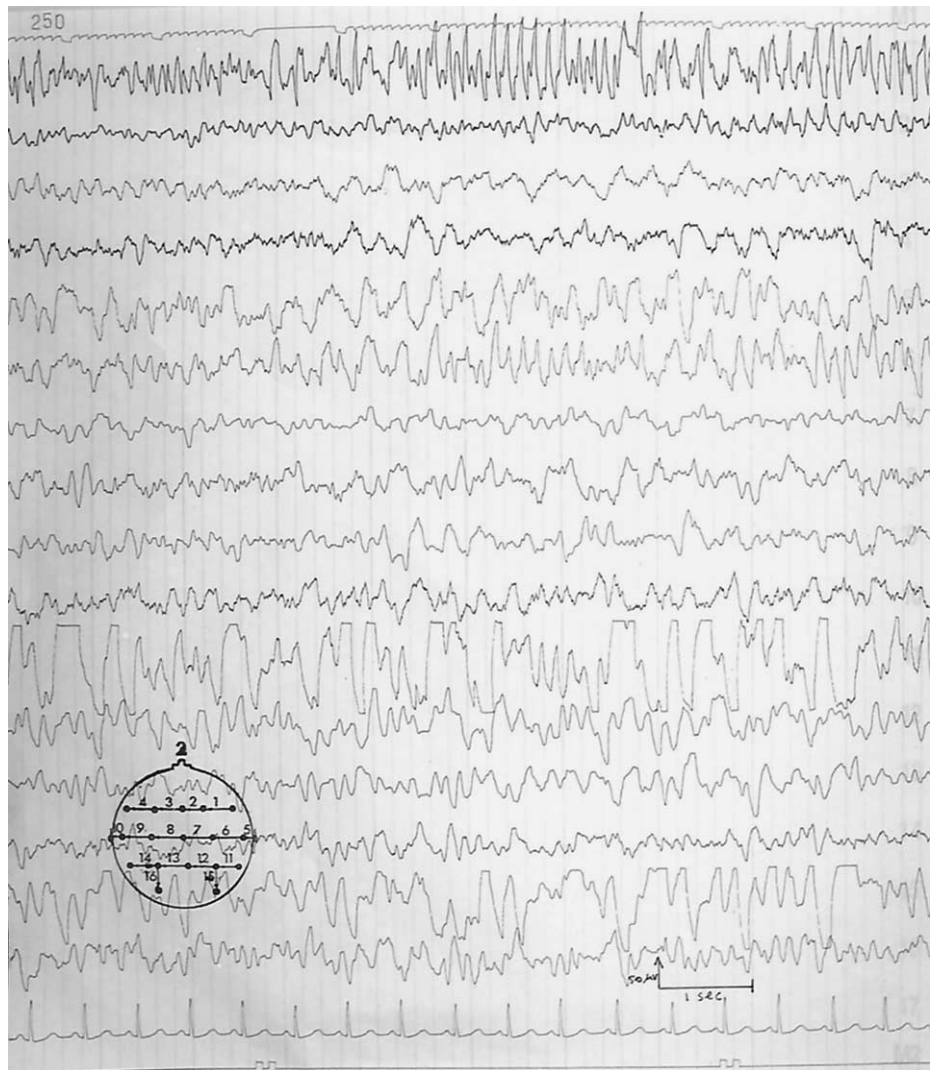


Figure 1. Surface electroencephalogram using a transverse bipolar montage demonstrates a prolonged epileptic discharge over the right frontocentral regions consisting of paroxysmal fast sharp waves, corroborated with left-sided twitching but preserved alertness. This image reveals an underlying moderate disturbance of background activity over the right frontocentral regions.

diffuse infiltration of the normal nervous tissue with glial cells with no concrete formation of a tumor mass [15-18]. Although focal seizures may be the presenting symptoms in gliomatosis cerebri [18], the evolution of epilepsy partialis continua as the main clinical perturbation of gliomatosis cerebri is extremely rare.

## Case Reports

### Patient 1

A 5-year-old previously healthy female presented to a local hospital 10 months before admission to our service with an apparently secondary generalized clonic seizure. The initial electroencephalogram reportedly demonstrated focal epileptic activity over the right hemisphere. She was begun on phenytoin and switched to carbamazepine after 2 months. She remained asymptomatic for a period of 4 months after which she began having recurrent left-sided twitching movements of the face, arm, and leg that lasted for seconds, accompanied by a feeling of numbness over the left upper limb but not associated with any alteration of consciousness. Computed tomography of the brain at that point was unremarkable. Magnetic resonance imaging, on the other hand, demonstrated increased T<sub>2</sub>-weighted signals over the right frontocentral regions. During the next

6 months her focal motor left-sided seizures had markedly increased in frequency to become virtually continuous, along with progressive sensory impairment, mainly of the left upper limb, despite treatment with massive combined antiepileptic therapy, including oral carbamazepine, valproic acid, lamotrigine, and topiramate.

The patient was admitted for evaluation at our institution 6 months after the initiation of her left-sided focal motor seizures, which remarkably increased in frequency; yet she remained fully alert and coherent. Motor-wise a mild-to-moderate left-sided pyramidal weakness was detected along with brisk tendon reflexes and abnormal Babinski and Hoffmann responses, accompanied by mild sensory impairment, namely, tingling and numbness. She had as many as 80-100 clusters of left-sided twitching, which only partially responded to intravenous therapy of phenytoin and midazolam. Repeat electroencephalogram records (Fig 1) demonstrated prolonged and recurrent spike/slow wave epileptic discharges over the right frontocentral regions along with disturbance of background activity, corroborated by the left-sided focal motor seizures verified with video electroencephalogram. Such a combination was compatible with the diagnosis of epilepsy partialis continua. HMPAO single-photon emission computed tomography cerebral scanning demonstrated marked hyperperfusion over the right frontocentral areas, suggestive of prolonged ictal activity. Ophthalmologic examination demonstrated a swollen right optic disc. Magnetic resonance imaging of the brain (Fig 2) demonstrated a large widespread subcortical-cortical

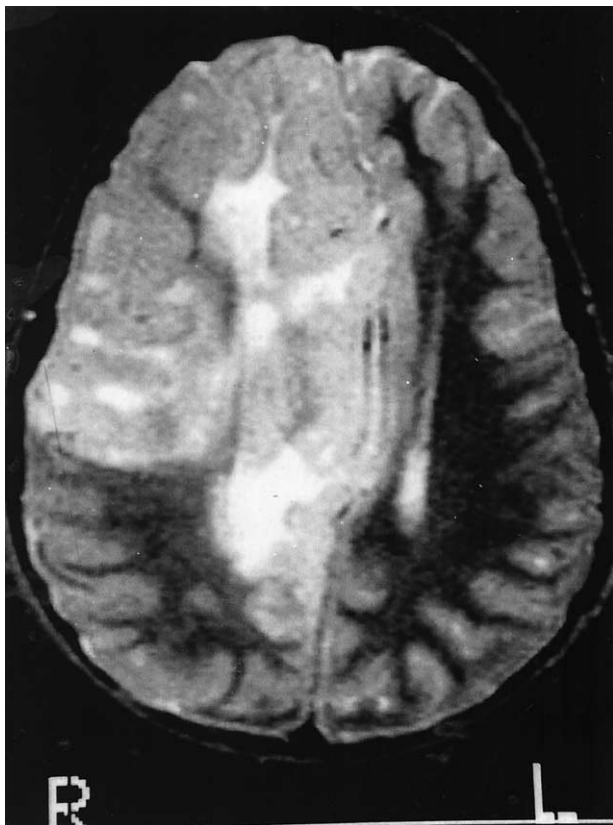


Figure 2. Magnetic resonance imaging of the brain using  $T_2$ -weighted images demonstrates a large widespread cortical-subcortical gadolinium-enhancing ill-defined area encountering the frontocentral areas of the right hemisphere with diffuse swelling, displacing the right midline structures and obstructing the lumen of the right lateral ventricle.

gadolinium-enhancing area encountering the anterior two thirds of the right hemisphere, spreading into the interhemispheric region with diffuse swelling and displacing the right midbrain structures to the left.

Given the progressive and relentless nature of the epilepsy partialis continua, the widespread hemispherical abnormalities depicted on magnetic resonance imaging, and the swelling of the right optic disc, a rapidly expanding destructive cortical mass was suspected.

The differential diagnoses included Rasmussen's encephalitis, cortical dysplasia, or a gliomatous process. A stereotactic cortical biopsy was therefore performed, and the histologic findings were diagnostic of gliomatosis cerebri (Fig 3). This finding demonstrated abundant infiltration of glial cells with irregular hyperchromatic nuclei and minimal cytoplasm, without mitoses or vascular hyperplasia or tissue necrosis. Perineural satellitosis, which is a hallmark of gliomatosis cerebri, was evident and included engulfing of neurons by those glial cells to form a satellite configuration (Fig 3). The overall anatomic structure was not distorted, and there was no outlining of a tumoral mass. Immunohistochemical staining with the Ki-67 marker for cell proliferation was negative. After the ominous diagnosis of gliomatosis cerebri, the patient was treated with cranial radiation, repeat courses of massive combined chemotherapy, high-dose corticosteroids, and combined antiepileptic therapy, including phenytoin, phenobarbital, lamotrigine, and gabapentin. The focal motor clusters gradually decreased in frequency after 5 months of treatment, although she still has intermittent infrequent left-sided twitching with no motor, sensory, or cognitive impairment within a follow-up period of 18 months since the establishment of the histologic diagnosis and initiation of therapy.

### Patient 2

A 10-year-old previously healthy female presented with a prolonged left focal motor seizures that rapidly became generalized and lasted for 2 hours overall. Electroencephalography studies demonstrated epileptiform activity over the right centrotemporal regions, and she was begun on carbamazepine. After 2 months she began having recurrent sensory seizures consisting of a tingling sensation, which began over her left upper limb and spread to the rest of her left side, which were followed by recurrent focal motor seizures. During those events she experienced some decrease of alertness with feeble speech; however, she never lost consciousness and remained aware of her sensory impairment and twitching. Concomitantly she developed a progressive left-sided weakness. Cerebral computed tomography demonstrated a calcified low-density lesion in the right centrotemporal regions. Magnetic resonance imaging demonstrated a cystic mass at the right centrotemporal areas spreading posteriorly, nonenhancing with gadolinium. The differential diagnoses included encephalitis, inflammatory cerebritis, stroke, neurocystercosis, or gliomatosis cerebri, which seemed unlikely. The histology of a stereotactic biopsy of this mass was diagnostic of gliomatosis cerebri. Despite massive chemotherapy and antiepileptic medications, the patient died 2 years after the initial presentation.

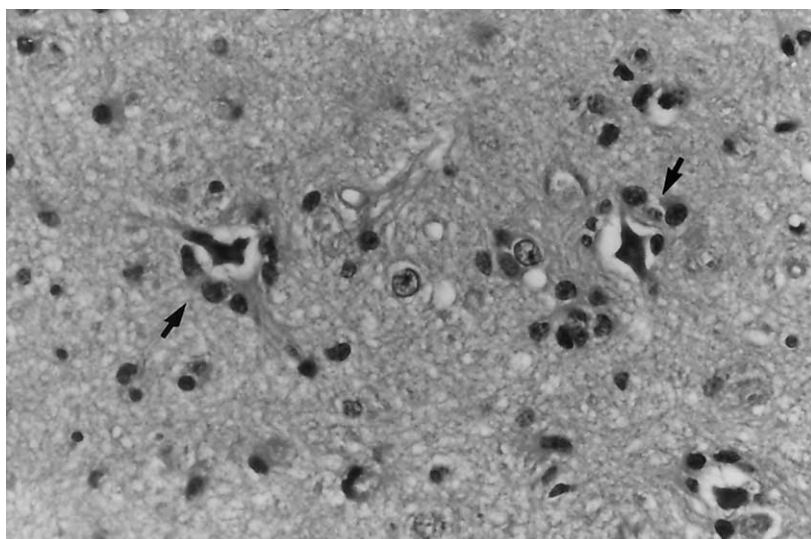


Figure 3. Hematoxylin and eosin staining of a stereotactic cortical biopsy is diagnostic of gliomatosis cerebri. Abundant infiltration of astrocytic cells with irregular hyperchromatic nuclei and minimal cytoplasm are illustrated, without mitoses or vascular hyperplasia or tissue necrosis. Notice a striking satellitosis (arrows) revealing three neurons engulfed by glial cells forming a satellite configuration. Overall the anatomic structure was not distorted with no outlining of a tumor mass.

## Discussion

New-onset epilepsy partialis continua in a previously healthy child implies an ominous progressive neurologic disorder and requires prompt diagnosis and treatment because of the possibility of developing an infiltrative cortical lesion. Regardless of the underlying etiology of epilepsy partialis continua, a lack of response to antiepileptic medications using high doses in various combinations, as occurred in both patients presented in this report, usually constitutes an alarming prognostic sign, necessitating early intervention. When conducting a search of the literature, we could not find a collective series of epilepsy partialis continua in the pediatric age group but found a small number of reports depicting a variety of underlying diagnoses, mainly including Rasmussen's encephalitis [4,5], congenital neuronal migration disorders [6-10], or rare metabolic or enzymatic disorders [11-14]. Rasmussen's encephalitis has been most commonly associated with intractable and relentless epilepsy partialis continua in the pediatric age group [2,4,5], consisting of progressive cortical destruction mainly confined to one hemisphere. After histologic diagnosis, of which the hallmark is perivascular lymphocytic cuffing, early surgical intervention may be required to halt the progressive cortical destruction and suppress the ongoing epilepsy partialis continua. Relatively fewer reports describe the possible association of neuronal migration disorders in infants and children developing epilepsy partialis continua [6-10]. The radiologic abnormalities demonstrated by magnetic resonance imaging may be similar in either Rasmussen's encephalitis or cortical dysplasia. However, the structural abnormalities found in Rasmussen's encephalitis are commonly unilateral and circumscribed compared with multifocal and sometimes bihemispherical parenchymal distortion and ventricular abnormalities observed in disorders of neuronal migration.

A brain biopsy is therefore necessary to delineate the ultimate diagnosis, either demonstrating an inflammatory response with perivascular lymphocytic cuffing in Rasmussen's encephalitis [4,5] or distorted cortical architecture in congenital structural anomalies of the cortex [6-10]. Fusco et al. [6] report that in a series of 50 children with neuronal migration disorders, two children with unilateral migrational abnormalities had developed epilepsy partialis continua, which was subtle and almost overlooked. The same authors [8] also reported on a child with hemimegacephaly who developed an opercular syndrome associated with persistent focal spikes, similar to that reported by Ishii et al. [9]. Debiens et al. [10] reported on a child with occult cortical dysplasia who developed epilepsy partialis continua. In his review, Andermann [19] noted that a high rate of patients with either Rasmussen's syndrome or neuronal migration disorders may develop epilepsy partialis continua or other epileptic discharges arising from the precentral gyrus. In addition, a few rare metabolic and enzymatic disorders in children were also

associated with epilepsy partialis continua [11-14]. However, children affected by such disorders usually suffer from associated cognitive, verbal, and motor handicaps, even before the emergence of the epilepsy partialis continua and, therefore, could be fairly easily differentiated from those with structural anomalies, such as Rasmussen's encephalitis, inducing epilepsy partialis continua.

Gliomatosis cerebri is a rare and unique neoplastic disorder characterized by diffuse widespread proliferation of neoplastic glial cells within the cortex, with no constitution of a discrete tumoral mass, mostly involving the gray matter but may also spread to the white matter [15-18]. Histologic evaluation reveals neoplastic astrocytes with varying degrees of differentiation, of which many cells display elongated twisted nuclei reminiscent of microglia, stained intensely for glial fibrillary acidic protein, with relative preservation of the underlying cytoarchitecture [16].

Concerning the underlying pathogenesis of gliomatosis cerebri that to date has not been fully clarified, Artigas et al. [16] postulated on the basis of the two-stage theory of carcinogenesis that gliomatosis cerebri may be the result of the propagation of primitive glial elements that have not undergone the process of tumor conversion, after analyzing the histology of 58 patients with gliomatosis cerebri. Gliomatosis cerebri rarely has been reported in the pediatric age group, including in neonates, and mainly presents with seizures [18,20]. Other reports include gliomatosis cerebri in a 7-year-old child masquerading as pontine glioma with involvement of the entire neuroaxis [21], gliomatosis cerebri in a 10-year-old female masquerading as diffuse encephalomyelitis and a spinal cord tumor [22], gliomatosis cerebri in a 14-year-old female with progressive dementia [23], and gliomatosis cerebri in a 16-year-old adolescent presenting with unilateral third nerve palsy [24].

The clinical presentations associated with gliomatosis cerebri are variable, depending on the extent and the region affected by the neoplastic glial cells, and may also be age related. Adults, more commonly the elderly, may present with progressive dementia, affective and mental changes, and corticospinal tract perturbations [15-17], whereas children may more readily present with seizures and cranial neuropathies [18]. Couch and Weiss [15] reviewed 36 cases with gliomatosis cerebri, which mainly included adults, and report that the most common presentation included alterations in mental status and personality followed by pyramidal hemiparesis, cerebellar impairment, papilledema, headaches, seizures, and brainstem signs, in decreasing order. The most comprehensive review on gliomatosis cerebri was published by Jennings et al. [18] who reported on 160 cases of gliomatosis cerebri retrieved from the literature. The most common abnormalities in 139 patients at all ages included corticospinal tract deficits in 58%, dementia or mental retardation in 44%, headaches in 39%, seizures (mainly focal) in 38%, cranial

neuropathies in 37%, benign increased intracranial pressure in 34%, and spinocerebellar deficits in 33%. The cerebrum, including the centrum semiovale, was infiltrated in 76% of patients with gliomatosis cerebri, as was the case in the first child presented here with massive infiltration. Jennings et al. [18] also reported on three children in whom a diagnosis of gliomatosis cerebri was established at the ages of 6 days, 8 months, and 6 years, respectively. The neonate presented with right focal seizures that rapidly became generalized, having had repeat nonresponsive episodes of status epilepticus leading to his death. The 8-month-old infant initially had generalized extensor spasms and recurrent myoclonic jerks of upper extremities, representing infantile spasms, that effectively responded to oral steroids. After control of these seizures was established, he developed a right-sided epilepsy partialis continua. The third child also had generalized myoclonic seizures associated with gliomatosis cerebri. All patients had focal electroencephalogram discharges corroborating with unilateral parenchymal changes, implying secondary generalization of the focal epileptic discharges from the regions of the gliomatous spread, similar to the patients presented in this report.

The patients presented herein developed epilepsy partialis continua, intractable to antiepileptic medications, lasting for months before the clinical and electroencephalogram diagnosis of epilepsy partialis continua was established, subsequently undergoing a cortical biopsy in an attempt to identify the underlying etiology. The differential diagnoses in a previously healthy child who develops epilepsy partialis continua, corroborated by hypersignal lesions on magnetic resonance imaging suspecting a structural cortical lesion, includes Rasmussen's encephalitis, disorders of neuronal migration, and, rarely, a gliomatous process such as gliomatosis cerebri, as occurred in both patients presented in this study. Epilepsy partialis continua, which was the single clinical presentation of gliomatosis cerebri in both patients, with no other neurologic abnormalities is unusual and intriguing considering the other various and mixed presentations of gliomatosis cerebri. The outcome of children with diffuse widespread gliomatosis cerebri is currently unpredictable because of the possible beneficial effects of the current potent chemotherapeutic drug combinations after cranial radiotherapy and the effectiveness of antiepileptic medications, as occurred in the first female presented herein. Therefore, gliomatosis cerebri should be taken into account in any previously healthy child presenting with new-onset epilepsy partialis continua corroborating with unilateral spreading lesions visible on magnetic resonance imaging, and hence the importance of readily performing a cortical biopsy to rapidly establish the accurate diagnosis and enable prompt treatment.

## References

- [1] Thomas JE, Reagan TG, Klass DW. Epilepsia partialis continua. A review of 32 cases. *Arch Neurol* 1977;34:266-75.
- [2] Cockerel OC, Rothwell J, Thompson PD, Marsden CD, Shovron SD. Clinical and physiological features of epilepsy partialis continua. Cases ascertained in the UK. *Brain* 1996;119(Pt 2):393-407.
- [3] Gurer G, Saygi S, Ciger A. Epilepsia partialis continua: Clinical and electrophysiological features in adult patients. *Clin Electroencephalogr* 2001;32:1-9.
- [4] Topcu M, Turanli G, Aynaci FM, et al. Rasmussen encephalitis in childhood. *Childs Nerv Syst* 1999;15:395-402.
- [5] Dulac O. Rasmussen's syndrome. *Curr Opin Neurol* 1996;9:75-7.
- [6] Fusco L, Bertini E, Vigeveno F. Epilepsia partialis continua and neuronal migration anomalies. *Brain Dev* 1992;14:323-8.
- [7] Verhagen WIM, Renier WO, ter Laak H, Jaspard HHJ, Gabreels FJM. Anomalies of the cerebral cortex in a case of epilepsy partialis continua. *Epilepsia* 1988;29:57-62.
- [8] Fusco L, Vigeveno F. Reversible operculum syndrome caused by progressive epilepsy partialis continua in a child with left hemimegalencephaly. *J Neuro Neurosurg Psychiatry* 1991;54:556-8.
- [9] Ishii M, Sugita K, Niimi H. A case of epilepsy partialis continua associated with hemimegalencephaly. *Psychiatry Clin Neurosci* 1995;49: S302-3.
- [10] Desbiens R, Berkovic SF, Dubeau F, et al. Life-threatening focal status epilepticus due to occult cortical dysplasia. *Arch Neurol* 1993;50:695-700.
- [11] Balestri P, Grosso S. Endocrine disorders in two sisters affected by MELAS syndrome. *J Child Neurol* 2000;15:755-78.
- [12] Elia M, Musumeci SA, Ferri R, et al. Leigh syndrome and partial deficit of cytochrome c oxidase deficiency associated with epilepsy partialis continua. *Brain Dev* 1996;18:207-11.
- [13] Antizzi C, Franceschetti S, Filippini G, et al. Epilepsia partialis continua associated with NADH-coenzyme Q reductase deficiency. *J Neurol Sci* 1995;129:152-61.
- [14] Schulke M, Bakker M, Stoltenburg G, Sperner J, von Moers A. Epilepsia partialis continua associated with a homoplasmic mitochondrial tRNA(Ser(UCN) mutation. *Ann Neurol* 1998;44:700-4.
- [15] Couch JR, Weiss SA. Gliomatosis cerebri. Report of four cases and review of the literature. *Neurology* 1974;24:504-11.
- [16] Artigas J, Cervos-Navarro J, Iglesias JR, Ebhardt G. Gliomatosis cerebri: Clinical and histologic findings. *Clin Neuropathol* 1985;4: 135-48.
- [17] Kim DG, Yang HJ, Park IA, et al. Gliomatosis cerebri: Clinical features, treatment and prognosis. *Acta Neurochir (Wien)* 1998;140:755-62.
- [18] Jennings MT, Frenchman M, Shehab T, et al. Gliomatosis cerebri presenting as intractable epilepsy during early childhood. *J Child Neurol* 1995;10:37-45.
- [19] Andermann F. Epilepsia partialis continua and other seizures arising from the precentral gyrus: High incidence in patients with Rasmussen's syndrome and neuronal migration disorders. *Brain Dev* 1992;14:338-9.
- [20] Barth PG, Stam FC, Hack W, Delemarre-van de Vaal HA. Gliomatosis cerebri in a newborn. *Neuropediatrics* 1988;19:197-200.
- [21] Cummings TJ, Hulette CM, Longee DC, Bottom KS, McLendon RE, Chu CT. Gliomatosis cerebri: cytologic and autopsy findings in a case involving the entire neuroaxis. *Clin Neuropathol* 1999;18:190-7.
- [22] Jayawant S, Neale J, Stoodley N, Wallace S. Gliomatosis cerebri in a 10-year-old girl masquerading as diffuse encephalomyelitis and spinal cord tumor. *Dev Med Child Neurol* 2001;43:124-16.
- [23] Keen DI, Jimenez C, Hsu E. MRI diagnosis of gliomatosis cerebri. *Pediatr Neurol* 1999;20:148-51.
- [24] Dexter MA, Parker GD, Besser M, Ell J, Fulham MJ. MR and positron emission tomography with fludeoxyglucose F18 in gliomatosis cerebri. *Am J Neuroradiol* 1995;16:1507-10.