


This article was downloaded by: [Eastern Michigan University]

On: 10 October 2014, At: 15:23

Publisher: Routledge

Informa Ltd Registered in England and Wales Registered Number: 1072954 Registered office: Mortimer House, 37-41 Mortimer Street, London W1T 3JH, UK



Neurocase: The Neural Basis of Cognition

Publication details, including instructions for authors and subscription information:

<http://www.tandfonline.com/loi/nncs20>

A New Sign of Callosal Disconnection Syndrome: Agonistic Dyspraxia. A Case Study

Manuel Lavados , Ximena Carrasco , Marcela Peña , Eran Zaidel , Dahlia Zaidel & Francisco Aboitiz

Published online: 09 Aug 2010.

To cite this article: Manuel Lavados , Ximena Carrasco , Marcela Peña , Eran Zaidel , Dahlia Zaidel & Francisco Aboitiz (2002) A New Sign of Callosal Disconnection Syndrome: Agonistic Dyspraxia. A Case Study, *Neurocase: The Neural Basis of Cognition*, 8:6, 480-483

To link to this article: <http://dx.doi.org/10.1076/neur.8.5.480.16178>

PLEASE SCROLL DOWN FOR ARTICLE

Taylor & Francis makes every effort to ensure the accuracy of all the information (the "Content") contained in the publications on our platform. However, Taylor & Francis, our agents, and our licensors make no representations or warranties whatsoever as to the accuracy, completeness, or suitability for any purpose of the Content. Any opinions and views expressed in this publication are the opinions and views of the authors, and are not the views of or endorsed by Taylor & Francis. The accuracy of the Content should not be relied upon and should be independently verified with primary sources of information. Taylor and Francis shall not be liable for any losses, actions, claims, proceedings, demands, costs, expenses, damages, and other liabilities whatsoever or howsoever caused arising directly or indirectly in connection with, in relation to or arising out of the use of the Content.

This article may be used for research, teaching, and private study purposes. Any substantial or systematic reproduction, redistribution, reselling, loan, sub-licensing, systematic supply, or distribution in any form to anyone is expressly forbidden. Terms & Conditions of access and use can be found at <http://www.tandfonline.com/page/terms-and-conditions>

Short Report

A New Sign of Callosal Disconnection Syndrome: Agonistic Dyspraxia. A Case Study

Manuel Lavados, Ximena Carrasco¹, Marcela Peña², Eran Zaidel³, Dahlia Zaidel³ and Francisco Aboitiz¹

Departamento de Ciencias Neurológicas, ¹Programa de Morfología, Instituto de Ciencias Biomédicas, Facultad de Medicina, Universidad de Chile, Santiago, Chile, ²Laboratoire de Sciences Cognitives et Psycholinguistique, EHESS, Paris, France and ³Department of Psychology, University of California, Los Angeles, California, USA

Abstract

We report a patient with callosal haemorrhage and no extracallosal involvement who developed a unique form of intermanual conflict. In the acute phase the patient showed a mild speech disturbance and right hemiparesis, and in her right hand, a grasp reflex and compulsive manipulation of tools, all attributable to transient frontal involvement. In the chronic phase there was intermanual conflict occasionally associated with the sensation of a second left hand. The patient also presented a sign consisting of compulsive, automatic execution of orders by one hand (the left or the right) when the patient was specifically asked to perform the movement with the other hand (the right or the left, respectively). There was no left–right confusion in this patient. We call this condition agonistic dyspraxia. In contrast with diagonistic dyspraxia, this consists of the agonistic behaviour of the other hand under conditions in which the hand that has been instructed to respond cannot execute the request.

Introduction

A variety of abnormal involuntary motor behaviours has been described following callosal lesions which may or may not be accompanied by hemispheric damage. One example of this is the group of syndromes labelled as alien hand (Brion and Jedyak, 1972), anarchic hand (Della Salla *et al.*, 1994), wayward hand (Goldberg, 1987), intermanual conflict (Bogen, 1979) and diagonistic dyspraxia (Akelaitis, 1945). Here we report a patient with callosal haemorrhage who showed, in addition to familiar signs of callosal interruption, an abnormal behaviour not previously described. When instructed to perform a command with either the right or the left forelimb, the patient used the forelimb on the opposite side.

evaluated as Glasgow 12. There was a minimal right crural hemiparesis, more pronounced in the lower limb, with Babinski sign. Examination of the cranial nerves, sensory and cerebellar function was normal. A computerized tomography examination revealed a haemorrhage spanning the whole length of the corpus callosum. On 13 June a bilateral carotid and left vertebral angiography indicated vasospasm in both the pericallosal and the callosomarginal arteries without evidence of aneurysm or arterovenous malformations. After 1 month the bilateral carotid and vertebral angiography was normal. Magnetic resonance imaging performed 5 months later revealed three distinct callosal lesions, without extra-callosal involvement (see Fig. 1).

Case description

The patient, EB, was a 40-year-old, right-handed woman with an eighth grade education, with a history of chronic arterial hypertension. On 1 June 1997, she presented a sudden episode of intense cephalgia and loss of consciousness. On admission she was evaluated as Glasgow 3, but after a few hours the patient had recovered consciousness and was

Hospitalization period (1 June to 1 August)

During the first 2 weeks, EB showed a slight right hemiparesis, a language deficit similar to a transcortical motor aphasia and a preserved ability to repeat words and two-word utterances. These early language impairments rapidly changed to fluent speech with normal grammar. Even though the patient's right arm was mildly paretic, she had signs of a

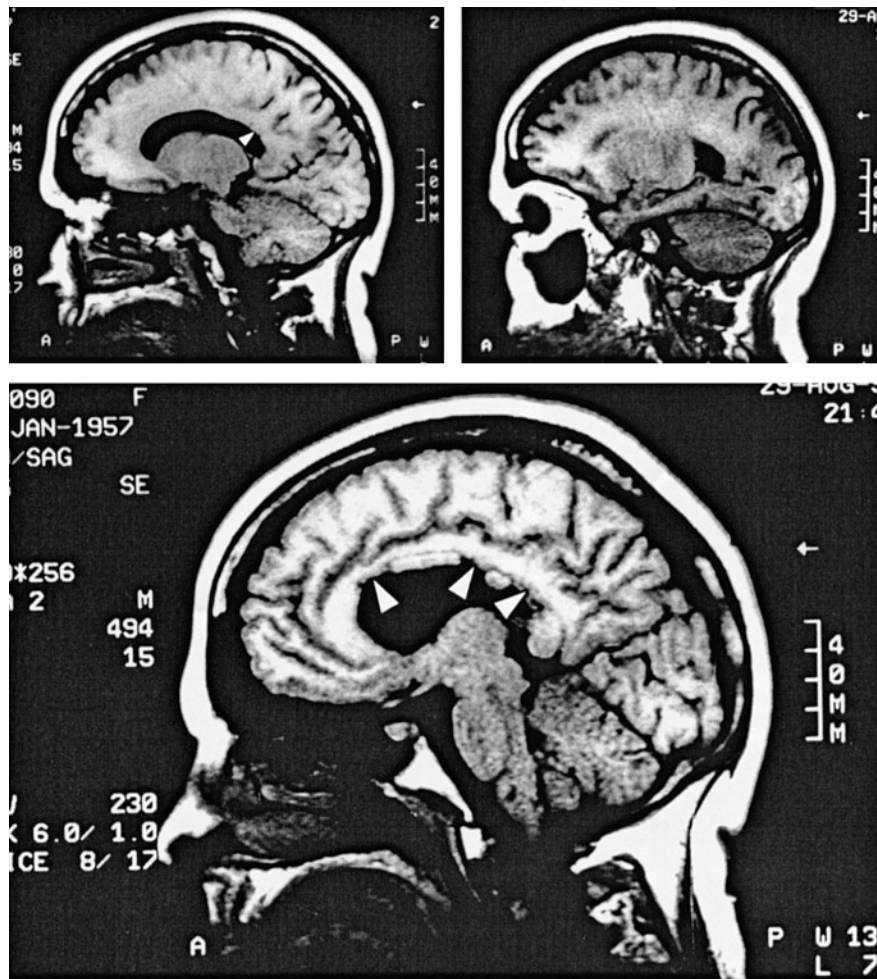


Fig. 1. Midsagittal magnetic resonance image indicating the lesioned regions (arrowheads) along the patient's corpus callosum (TR, 494 ms; TE, 15 ms). Above, two parasagittal images leftward (left) and rightward (right) from the midline, showing absence of extracallosal damage. In the picture on the left, two vestiges of the posterior lesion can still be observed in the posterior body of the callosum (arrowhead), which disappeared in the subsequent sections.

mild and transient left motor neglect. If the patient sat in front of the examiner, she normally responded with her right arm to movements produced by the right arm of the examiner; however, sometimes she did not respond with her left arm or if she did, her movements were slow. She had no problem reporting tactile stimuli applied bilaterally and simultaneously, and had no visual neglect according to the Barcelona Test (Peña-Casanova, 1990). In addition, occasionally the patient's right hand moved purposelessly and exhibited an uncontrollable tendency to reach for objects nearby and an inability to release them, as well as a strong grasp reflex. All the signs described completely disappeared within the first 2 weeks. The patient was discharged in July, after her second angiography.

Neuropsychological assessment (September)

The patient performed normally in the Mini-mental Test, in the mnesic BEM 144 Test for short- and long-term memory (Signoret, 1991), in the tasks for loud reading and comprehension of the Barcelona Test, and in the Boston Naming Test.

Visual object naming as well as colour or body part naming were all normal in both visual fields. In both lexical and semantic verbal fluency she scored normally. Right-hand writing was normal as evaluated by the written language subtest of a Spanish adaptation of the Aachen Aphasia Test (Huber *et al.*, 1983). Visuoconstructive function was well preserved in both hands. Similarly, scores in ideomotor praxis commands (Alexander *et al.*, 1992) were normal, except the upper limbs, which will be discussed below. In frontal tests, she performed normally. A dichotic listening study with consonant–vowel monosyllables revealed a strong pattern of right ear advantage for speech sounds (73% of the responses had a right ear advantage), suggesting auditory disconnection. In tests of blind somesthetic transfer between the hands, she consistently failed in cross-replication of hand postures (0/20), in cross-recognition of small objects (0/20) and in cross-localization of finger tips (4/16), indicating manual callosal disconnection. While evaluating unimanual tactile naming in the same blind conditions, the patient was unable to name objects in either hand. However, she was able to identify them by touch (with the same hand) among other objects. In the unimanual naming task, the hand

Table 1. (A) Instances in which the automatic hand (contralateral to the instructed or voluntary hand) performed the order instead of the voluntary hand (contralateral interference). (B) Mean delays in response of the automatic and voluntary hands in each case. The patient was videotaped while performing the different gestures and the reaction times were calculated with a chronometer while watching the tape

| (A) Contralateral interference | | | (B) Delay in response (s) | | | |
|--------------------------------|----------------|--------------|---------------------------|-----------|--------------|-----------|
| | | | September 1997 | | January 1998 | |
| Instructed hand | September 1997 | January 1998 | Automatic | Voluntary | Automatic | Voluntary |
| Right | 8/17 | 5/17 | 2.7 | 11.2 | 4 | 5.1 |
| Left | 17/17 | 4/17 | 11.5 | – | 2 | 3.8 |

that was not holding the object (sometimes the right hand, sometimes the left, depending on which hand was being tested) compulsively tended to grasp the object. Interestingly, when this hand (either right or left) was successful in touching the object, the patient was sometimes able to name it correctly.

Another unusual motor response pattern was observed during praxic evaluation, which to our knowledge has not been described previously. The patient was asked to perform various meaningful acts, either by command or by imitation. Praxis was normal for imitation. However, when specifically instructed to perform some symbolic movement (say, a military salute, the cross sign or a threatening gesture) with either the right or the left hand (hereafter the voluntary hand), typically the other hand (the left or the right, respectively; hereafter called the automatic hand) rapidly responded instead, executing the correct movement (Table 1). When the automatic hand was kept immobilized by the examiner or by the patient herself (by sitting on her hand), it compulsively tended to perform the movement anyway. The patient knew which hand was supposed to perform the action because she looked intently at that hand when it was unable to execute the task. During the session, when the patient was finally able to perform the movement with the voluntary hand, the movement began after a long delay, was apraxic and emerged with great slowness. Although this phenomenon was bilateral, the apraxic-like behaviour was more evident when the voluntary hand was the left than when it was the right. In tests of limb ideomotor praxis (Alexander *et al.*, 1992), EB's performance with the voluntary hand was worse than with the automatic hand, consistent with callosal damage. If the examiner's instruction did not explicitly specify the hand to be moved, the patient correctly engaged either hand to execute the requested command. In such situations, the right hand always performed the movement correctly, while the left was slightly apraxic.

The patient was examined again 7 months following the accident. The frequency of automatic, involuntary movements was significantly reduced (Table 1), but these were still faster than the voluntary movements. The patient also mentioned that her left arm and leg tended to interfere with or oppose a voluntary act, and described a sensation of strangeness, as if her left hand was 'not part of her'. In addition, she reported the occasional experience of having two left hands, where one was external to and smaller than the real one. Sometimes she also

felt that her left foot became distorted and much larger than normal.

Discussion

Our patient presented several symptoms at different stages of her clinical evolution which have been described in association with callosal lesions and/or frontal damage. Crural paresis, transcortical motor aphasia, grasp reflex and compulsive manipulation of tools were all indicative of transient left frontal dysfunction, associated with the haematoma (Tanaka *et al.*, 1996). The anatomical and clinical evidence renders persistent frontal damage unlikely, although it does not eliminate the possibility of laminar necrosis in the frontal cortex. Longer lasting motor disturbances were the traditional callosal signs of the condition that we now describe as agonistic dyspraxia. In contrast to diagonistic dyspraxia, the condition described here consists of the agonistic movements of the contralateral hand to perform those movements for which the specified hand is apraxic. This was still observed several months after the callosal haemorrhage, when the signs attributable to frontal damage had long disappeared.

References

Akelaitis AJ. Studies of the corpus callosum. IV. Diagonistic dyspraxia in epileptics following partial and complete section of the corpus callosum. *American Journal of Psychiatry* 1945; 101: 594–9.

Alexander MP, Baker E, Naeser A, Kaplan E, Palumbo C. Neuropsychological and neuroanatomical dimensions of ideomotor apraxia. *Brain* 1992; 115: 87–107.

Bogen J. The callosal syndromes. In: Heiman K, Valenstein E, editors. *Clinical neuropsychology*. Oxford: Oxford University Press, 1979: 337–407.

Brion S, Jedynak CP. Troubles du transfert interhémisphérique (callosal disconnection) à propos de trois observations de tumeurs du corps calleux. *Le signe de la main étrangère. Revue Neurologique* 1972; 126: 257–66.

Della Salla S, Marchetti C, Spinnler H. The anarchic hand: a fronto-mesial sign. In: Boller G, Grafman J, editors. *Handbook of neuropsychology*, Vol. 9. Amsterdam: Elsevier, 1994: 233–55.

Goldberg G. From intent to action: evolution and function of the premotor systems in the frontal lobe. In: Perecman E, editor. *The frontal lobes revisited*. New York: IRBN Press, 1987: 273–306.

Huber W, Poek K, Weninger D, Willmes K. *Aechner Aphasia Test*. Goottingen: Hogrefe, 1983.

Peña-Casanova J. Programa Integrado de Exploración Neuropsicológica. Test de Barcelona. Barcelona: Masson, 1990.

Signoret JL. Batterie d'efficacité mnésique BEM 144. Paris: Elsevier, 1991.

Tanaka Y, Yoshida A, Kawahata N, Hashimoto R, Obayashi T. Diagonistic dyspraxia. Clinical characteristics, responsible lesion and possible underlying mechanism. *Brain* 1996; 119: 859–73.

Received on 24 November, 2000; resubmitted on 8 December, 2001; accepted on 23 April, 2002

A new sign of callosal disconnection syndrome: agonistic dyspraxia. A case study

M. Lavados, X. Carrasco, M. Peña, E. Zaidel, D. Zaidel and F. Aboitiz

Abstract

We report a patient with callosal haemorrhage and no extracallosal involvement who developed a unique form of intermanual conflict. In the acute phase the patient showed a mild speech disturbance and right hemiparesis, and in her right hand, a grasp reflex and compulsive manipulation of tools, all attributable to transient frontal involvement. In the chronic phase there was intermanual conflict occasionally associated with the sensation of a second left hand. The patient also presented a sign consisting of compulsive, automatic execution of orders by one hand (the left or the right) when the patient was specifically asked to perform the movement with the other hand (the right or the left, respectively). There was no left–right confusion in this patient. We call this condition agonistic dyspraxia. In contrast with diagonistic dyspraxia, this consists of the agonistic behaviour of the other hand under conditions in which the hand that has been instructed to respond cannot execute the request.

Journal

Neurocase 2002; 8: 480–3

Neurocase Reference Number:

O281

Primary diagnosis of interest

Agonistic apraxia

Author's designation of case

EB

Key theoretical issue

- The patient, suffering from a callosal lesion, was unable to execute voluntary movements with the hand specified by the examiner, while the other hand compulsively tended to perform the action

Key words: alien hand; corpus callosum; diagonistic dyspraxia; intermanual conflict

Scan, EEG and related measures

Computed tomography, magnetic resonance imaging

Standardized assessment

Glasgow, Mini-mental Test, BEM 144, Barcelona Test, tests of somesthetic transfer between hands and tactile naming, visual naming in both visual hemifields, dichotic listening

Lesion location

- Three callosal lesions: in the posterior third, in the mid-third and in the anterior body of the callosum

Lesion type

Callosal haematoma

Language

English