

## CASE REPORT

# Subacute encephalopathy with seizures in alcoholism

JAYANTHI MANI, S. SITAJAYALAKSHMI, RUPAM BORGOHAIN & S. MOHANDAS

*Department of Neurology, Nizam's Institute of Medical Sciences, Somajiguda, Hyderabad, India*

Correspondence to: Dr Jayanthi Mani, Panch Mahal, 3rd floor, 546 Renuka Enclave, RajBhavan Road, Somajiguda, Hyderabad 500082, India. *E-mail:* jmani@satyam.net.in

Generalised seizures are a common manifestation of acute alcohol intoxication. Alcohol is known to precipitate generalised seizures in patients with focal brain pathology. A rare case of secondarily generalised seizures precipitated by alcohol in a patient without an underlying focal brain lesion is reported. Electroencephalography (EEG) showed periodic lateralised epileptiform discharges (PLEDs) on the side contralateral to the focal motor fits.

© 2002 BEA Trading Ltd. Published by Elsevier Science Ltd. All rights reserved.

*Key words:* periodic lateralised epileptiform discharges (PLEDs); alcohol withdrawal.

## INTRODUCTION

Alcohol withdrawal states have been known to activate underlying focal structural brain lesions to produce periodic lateralised epileptiform discharges (PLEDs). Here we report a rare case of PLEDs in acute alcoholic intoxication without an obvious structural brain pathology.

A 55-year-old male, a chronic alcoholic was found talking irrelevantly at his workplace in the afternoon. He had consumed a heavy bout of alcohol the previous evening. He was brought home by colleagues and left unattended at home. When his son returned that evening the patient was found muttering irrelevantly and did not obey commands. A couple of hours later, he developed paucity of right sided limb movements. There was no history of seizure, fall, head injury, headache, vomiting, fever or previous history of seizures. He was brought to hospital the same night.

On admission, the patient was afebrile, pulse 104 per minute, blood pressure in the right upper limb was 108/84 mmHg. There were no external injuries.

The patient was conscious, made eye contact and localised pain. His attention was poor, he did not follow any verbal commands and spoke incoherently. There

was occasional motor perseveration. Pupils were equal and reacting to light, fundi were normal, there was right gaze preference and right hemiparesis, power 3/5. Tendon reflexes were brisk and right plantar was extensor. There were no meningeal signs.

On admission the random blood sugar was 161 mg%, blood urea 15 mg% (15–40 mg%), creatinine 0.8 mg/dl (0.6–1.5 mg/dl), serum electrolytes were normal (Na, 144 meq/l; K, 3.5 meq/l). Computed tomography of the brain showed cerebral atrophy without any focal structural abnormalities. Liver function tests showed mild hyperbilirubinemia with total bilirubin 2.2 mg/dl, (normal upto 0.8 mg/dl) conjugated bilirubin 0.8 mg/dl (normal upto 0.3 mg/dl) and slightly elevated liver enzymes SGOT 158 (5–40 U/l), SGPT 131 (5–40 U/l), alkaline phosphatase 65 (upto 130 U/l), GGT 381 (10–45 U/l).

The patient was administered intravenous thiamine and intravenous fluids. The next morning he was more responsive and obeyed commands occasionally. There was no motor deficit, but he had two focal seizures involving the face and the right sided limbs. This was followed by persistent arrhythmic jerky movements especially of the right sided limbs. Antiepileptic drug carbamazepine was instituted.

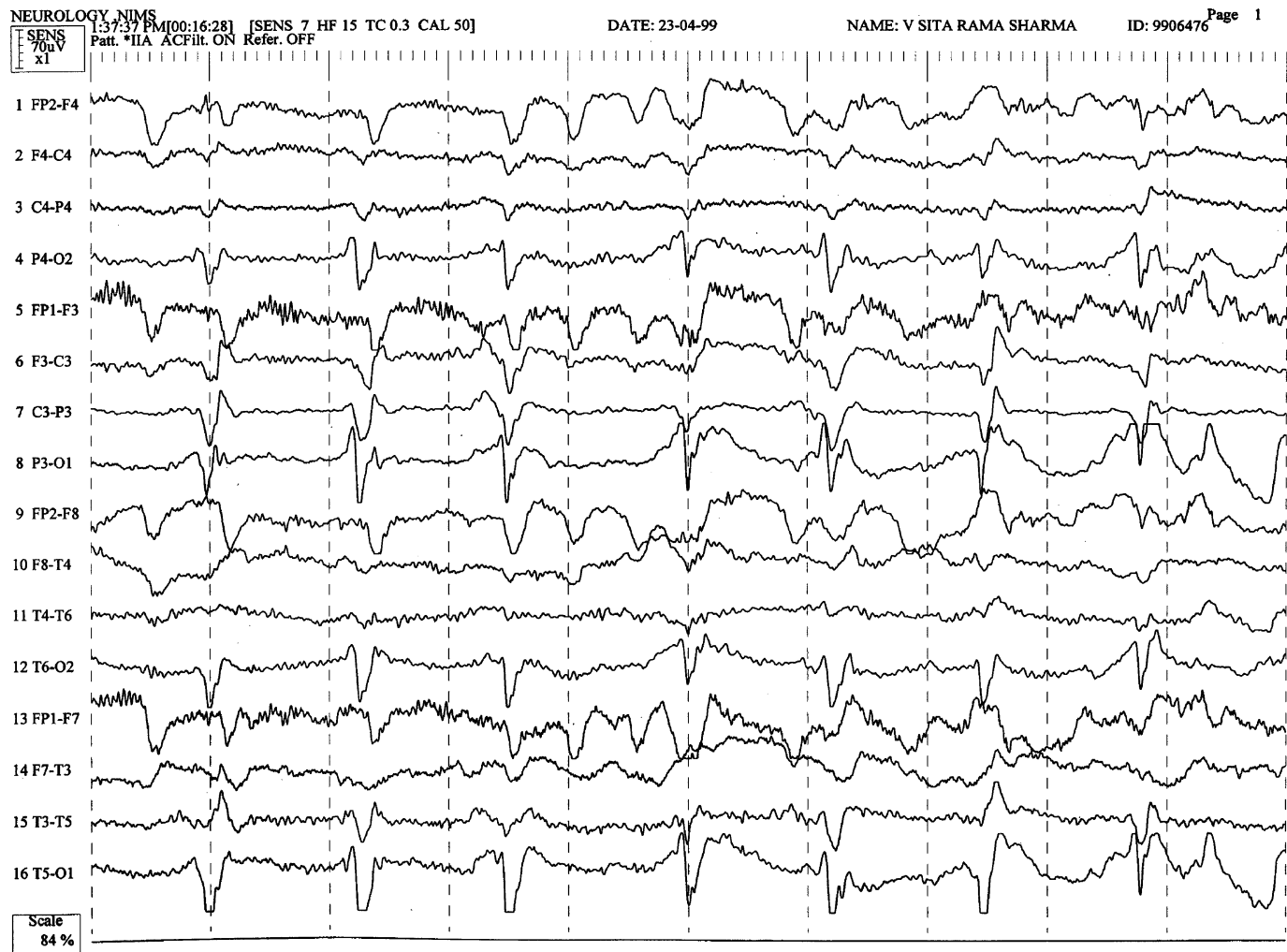


Fig. 1: Six channel EEG record of the patient showing periodic lateralised sharp wave discharges more prominent over the left hemisphere.

EEG showed low voltage background with periodic sharp wave discharges 125–150  $\mu$ V, 0.75–1 Hz, lateralised to the left hemisphere. They were especially prominent in the left parieto-occipital region, with some spread of discharges to the right occipital area (Fig. 1).

MRI brain showed sulcal prominence with ventricular enlargement without any other parenchymal abnormalities (Fig. 2a and b).

The dose of carbamazepine was rapidly built up to 600 mg/day over the next 2 days. The serum carba-

mazepine level at discharge was 6.0  $\mu$ g/ml (normal range 4–12  $\mu$ g/ml).

During his hospital stay the patient became more responsive and oriented but attention span remained reduced. He was able to name and read but unable to write. Recent memory was impaired and he confabulated occasionally. Remote memory was good. The jerks reduced in intensity and were absent at discharge after 5 days of hospital stay. An EEG repeated at discharge showed a better modulated background alpha rhythm at 8–9 Hz, without PLEDs.

A diagnosis of subacute encephalopathy with seizures in alcoholism (SESA) was considered in view of the confusional state with focal seizures, jerks and transient hemiparesis, a normal brain imaging and the classical EEG pattern in the background of alcoholism.

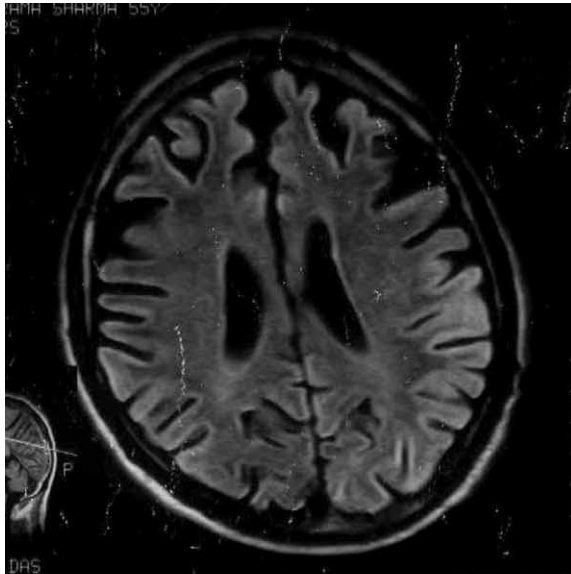
## DISCUSSION

Seizures occur in about 46% of acute alcohol related syndromes<sup>1</sup>. Most seizures are generalised, majority of patients with structural lesions also have generalised seizures<sup>2</sup>. Contrary to this, patients with SESA may have focal seizures without associated focal structural brain abnormality.

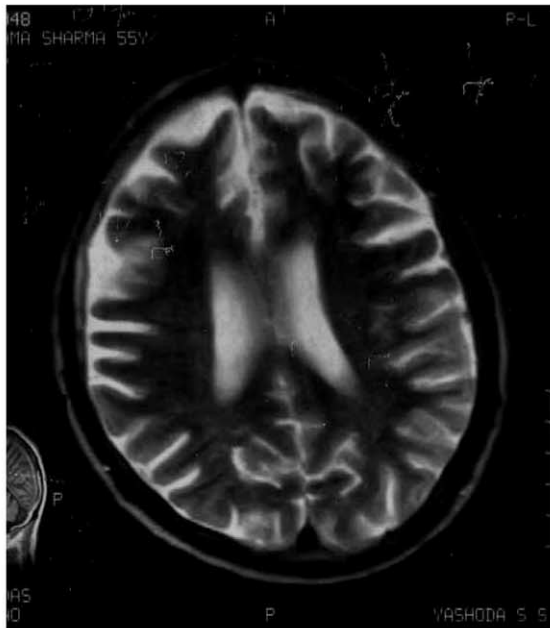Subacute encephalopathy with seizures in alcoholism is a rare entity. Niedermeyer *et al.* first proposed it in 1981 based on typical clinical and EEG features in the setting of chronic alcoholism<sup>3</sup>. A medline search identified only three more cases<sup>4–6</sup> in addition to the seven described by Niedermeyer in 1981.

The condition is distinct from other alcohol-related syndromes. It is clinically characterised by lethargy, confusion, recurrent focal and/or generalised seizures with focal neurological deficits like hemianopia, hemiparesis, or aphasia and distinct EEG features. The presence of focal neurological deficits, EEG features and normal neuroimaging differentiates this condition from other alcohol-related syndromes. The EEG picture in other acute alcohol related syndromes, may show a normal or an uncharacteristic low voltage pattern<sup>2, 7</sup>. The EEG in SESA shows marked slowing with periodic lateralised epileptiform discharges (PLEDs).

Periodic lateralised epileptiform discharges (PLEDs) were first described by Chatrian *et al.*<sup>8</sup>. They are associated with a variety of neurological conditions like cerebrovascular accidents, tumours, chronic seizure disorders, CNS infections<sup>8–10</sup>. The exact mechanism of generation of PLEDs is still a matter for debate. One view is that PLEDs occur due to white matter lesions that disconnect the cortex from subcortical influences<sup>11</sup>. Chatrian *et al.* postulated metabolic



(a)



(b)

Fig. 2: (a and b) T1 and T2 weighted MR images of the brain showing marked cortical atrophy.

derangements, head trauma, alcohol withdrawal or a pre-existing convulsive disorder or a focal brain lesion may contribute to the development of PLEDs by lowering the seizure threshold. They could not demonstrate isolation of the cortical structures in autopsy material. However, the neurological and pathological findings in their series of 12 patients are not clear. Pohlmann Eden *et al.* emphasised the dominant etiological role of strokes in the generation of PLEDs and suggest that the PLEDs reflect a key pattern for focal neuronal hyperexcitability in the penumbra of the ischemic area. They consider PLEDs as 'an EEG signature of a dynamic pathophysiological state in which unstable neurobiological processes create an ictal-interictal continuum, with the nature of the underlying injury, the patients pre-existing propensity to have seizures, and the co-existence of acute metabolic derangements all contributing to whether seizures occur or not'<sup>12</sup>.

Alcohol is known to precipitate PLEDs in patients with underlying focal brain pathology. In the pathological series by Chu *et al.* all the four patients described showed small chronic cortical brain infarcts ipsilateral to the PLEDs<sup>13</sup>. In a recent neuroimaging study of patients with PLEDs, eight patients underwent MR scans of the brain, all of which showed cortical abnormalities<sup>14</sup>. On the contrary, brain imaging in all reported cases of SESA shows no focal structural pathology and this matches with the CT and MRI findings in our patient. The diffuse brain atrophy seen in these patients has been reported in many patients with chronic alcoholism<sup>1, 13</sup>.

The pathogenesis of this rare syndrome is obscure. Niedermeyer postulated a vascular etiology but no evidence is yet available<sup>3</sup>. Functional neuroimaging studies may provide some evidence for the same. The role of metabolic derangements in the setting of chronic alcoholism cannot be overlooked. Our patient had evidence of hepatic disease with raised serum bilirubin and liver enzymes. The other possibility is an effect of altered neurotransmitter dynamics in the setting of acute alcohol withdrawal. However the focal nature of the discharges in the absence of an underlying structural pathology is still obscure.

It is interesting to note that Terzano *et al.* have reported a confusional state with neurological manifestations in seven elderly patients with PLEDs on the EEG and normal brain imaging in all but one of the patients. However no focal or generalised convulsions were noted<sup>15</sup>.

The seizures in SESA respond partially to anticonvulsant medication, but the resolution of the condition is gradual and recurrences have been reported<sup>3</sup>. The underlying medical illnesses associated with chronic alcoholism like infections and poor nutrition may prove fatal.

## REFERENCES

1. Essardas, D. H., Santolaria, F. J., Gonzales, R. E. *et al.* Alcohol withdrawal syndrome and seizures. *Alcohol and Alcoholism* 1994; **29** (3): 323.
2. Krause, G. L. and Niedermeyer, E. EEG and seizures in chronic alcoholism EEG. *Clinical Neurophysiology* 1991; **78** (2): 97–104.
3. Niedermeyer, E., Freund, G. *et al.* Subacute encephalopathy with seizures in alcoholics: a clinical electroencephalographic study. *Clinical Electroencephalography* 1981; **12**: 113–129.
4. Borojerd, B., Hungs, M., Binick, R. and Noth, J. Subacute encephalopathy with seizures syndrome. *Nervenarzt* 1998; **69** (2): 162–165.
5. Homma, G. and Niedermeyer, E. Subacute encephalopathy and seizures in chronic alcoholism. *Nervenarzt* 1993; **64** (6): 390–393.
6. Yoshino, A., Yoshimasu, H., Masaki, K. and Hara, T. Subacute encephalopathy with seizures in alcoholics. *Nippon Rinsho* 1997; **55** (Suppl.): 383–387; Yoshino, A., Yoshimasu, H., Masaki, K. and Hara, T. Subacute encephalopathy with seizures in alcoholics. *Nervenarzt* 1997; **64** (6): 390–434.
7. Deisenhammer, E., Klinger, D. and Tragner, H. Epileptic seizures in alcoholism and diagnostic value of EEG after sleep deprivation. *Epilepsia* 1998; **25** (4): 526–530.
8. Chatrian, G. F., Shaw, C. M. and Leffman, H. The significance of periodic lateralised epileptiform discharges in EEG: an electrographic, clinical and pathological study. *Electroencephalography and Clinical Neurophysiology* 1964; **17**: 177–193.
9. Bauer, G., Aichner, F. and Hengl, W. Diagnostic value of periodic lateralised complexes in the EEG. *Elektroenzephalography, Elektromyography Verwandte Geb* 1981; **12** (3): 135–141.
10. Schraeder, P. L. and Singh, N. Seizure disorders following periodic lateralising epileptiform discharges. *Epilepsia* 1980; **21** (6): 647–653.
11. Cobb, W. and Hill, D. Electroencephalogram in subacute progressive encephalitis. *Brain* 1950; **73**: 392–404.
12. Pohlmann Eden, B., Hoch, D. B., Cochins, J. I. and Chiappa, K. H. Periodic lateralising epileptiform discharges: a critical review. *Journal of Clinical Neurophysiology* 1996; **13**: 519–530.
13. Chu, N. S. PLEDs with preexisting focal brain lesions: role of alcohol withdrawal and anoxic encephalopathy. *Archives of Neurology* 1980; **37** (9): 551–554.
14. Raroque Jr, H. G. and Purdy, P. Lesion localization in periodic lateralised epileptiform discharges: gray or white matter. *Epilepsia* 1995; **36**: 58–62.
15. Terzano, M. G., Parrino, L., Mazzuchi, A. and Morretti, G. Confusional state with PLEDs: a peculiar epileptic syndrome in elderly. *Epilepsia* 1986; **27** (4): 446–457.