

CASE REPORT

Intestinal pseudo-obstruction and urinary retention: cardinal features of a mitochondrial DNA-related disease

A. GARCÍA-VELASCO¹, C. GÓMEZ-ESCALONILLA², J. M. GUERRA-VALES¹, A. CABELLO³, Y. CAMPOS⁴ & J. ARENAS⁴

From the Departments of ¹Internal Medicine, ²Neurology, ³Pathology, and ⁴Investigational Centre, University Hospital 12 de Octubre, Madrid, Spain

Abstract. García-Velasco A, Gómez-Escalonilla C, Guerra-Vales JM, Cabello A, Campos Y, Arenas J (University Hospital 12 de Octubre, Madrid, Spain). Intestinal pseudo-obstruction and urinary retention: cardinal features of a mitochondrial DNA-related disease (Case report). *J Intern Med* 2003; **253**: 381–385.

The syndrome of mitochondrial myopathy, encephalopathy, lactic acidosis and stroke-like episodes (MELAS) is a multisystemic disorder associated in most of the patients with an A to G transition at nucleotide position 3243 in the transfer RNA (tRNA)^{Leu(UUR)} (A3243G) of the mitochondrial DNA. This syndrome is characterized by the preponderant

involvement of skeletal muscle and central nervous system, but urinary or gastrointestinal symptoms are seldom documented. Here we report an unusual case of a 52-year-old woman with a clinical phenotype characterized by encephalopathy, left hemiparesis, urinary retention and gastrointestinal pseudo-obstruction. She had the classical A3243G mitochondrial DNA point mutation of MELAS syndrome. We also present a clinically heterogeneous multigenerational pedigree with several affected members in the maternal lineage.

Keywords: A3243G mitochondrial DNA (mtDNA) mutation, intestinal pseudo-obstruction, MELAS, mitochondrial encephalomyopathy.

Introduction

In 1977, Shapira *et al.* [1] proposed a concept of mitochondrial encephalomyopathy for a group of diseases with combined involvement of skeletal muscle and the central nervous system. The syndrome of mitochondrial myopathy, encephalopathy, lactic acidosis and stroke-like episodes (MELAS), which was first introduced by Pavlakis *et al.* [2] in 1984, is a multisystemic disorder associated with point mutations in mitochondrial DNA (mtDNA) particularly with an A to G transition at nucleotide 3243 (A3243G 85–90% of cases). MELAS syndrome is characterized by the presence of normal early development, short stature, seizures, progressive dementia, 'stroke-like' episodes, lactic acidosis and 'ragged-red' fibres on muscle biopsy. Urinary or gastrointestinal symptoms are rarely found. On the other hand, gastrointestinal dysmotility is the most

prominent manifestation of the mitochondrial neurogastrointestinal encephalomyopathy (MNGIE), an autosomal recessive disorder caused by nuclear DNA mutations in the thymidine phosphorylase (TP) gene. In this issue we report a multigenerational pedigree harbouring the point mutation A3243G, and an unusual phenotype with prominent gastrointestinal involvement.

Patients

Index case (II:1)

A 52-year-old woman without cardiovascular risk factors arrived to the emergency room with the following symptoms: an acute confusional syndrome, migraine, and left hemiparesis. She had sensorineural hearing loss since childhood and frequent constipation. In the previous 4 months, the patient had

suffered occasional abdominal pain and vomiting. She had a family history of normal early development, short stature, sensorineural hearing loss, exercise intolerance and frequent constipation, in several members of the maternal lineage.

On physical examination, slight dysarthria, left hemiparesis and short stature (1.42 m) were found. Chest X-ray, electrocardiogram, complete blood count and coagulation studies were normal. Lactate dehydrogenase (LD) was 1251 IU L^{-1} (313–618 normal range), and creatine kinase (CK) 2369 IU L^{-1} (35–230 normal range).

Cranial computed tomographic (CT) scan showed calcification of the basal ganglia and a hypodense temporoparietal image with an important component of vasogenic oedema. Oral anti-aggregation treatment was started.

The following additional tests were performed and showed normal values: serological search for virus (human immunodeficiency virus, hepatitis B and C and herpes virus) Brucella, Borrelia, Lues, immunological determinations for antiphospholipid antibodies, rheumatoid factor, antinuclear antibodies (ANA), extractable nuclear antigens (ENA), antineutrophil cytoplasmic antibodies (ANCAs) and the complement factors 3 and 4.

During admission, the patient's clinical condition improved, focal neurological deficits disappeared and her speech became more coherent, although some disorders in the cortical functions remained (inattention and euphoria) and hearing loss worsened.

After 4 days she developed paralytic ileus and urinary retention. An abdominal X-ray showed an increased jejunoileal gas with air-fluid levels (Fig. 1). The abdomino-pelvic ecography and CT revealed an important urinary retention with uretero-hydronephrosis and signs of intestinal pseudo-obstruction without a definite obstructive level. A barium meal showed the duodenum–ileum to be akinetic, and radiological contrast was seen in the duodenum in an abdominal X-ray taken 27 h after its administration. Parenteral nutrition was begun, being followed by the slow resolution of the pseudo-obstruction.

Serum lactate was 4.1 mmol L^{-1} (normal $<2.09 \text{ mmol L}^{-1}$), pyruvate was 0.3 mmol L^{-1} (normal $<0.03 \text{ mmol L}^{-1}$), and blood muscle enzymes were also elevated. A cranial magnetic resonance (MR) confirmed the lesions already visualized in CT and revealed changes on signal intensity

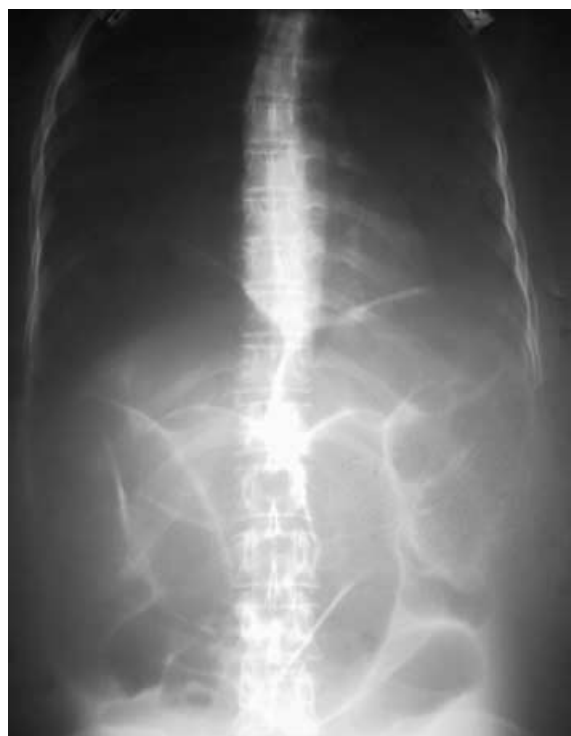

Fig. 1 Simple abdominal radiograph of the proband's intestinal pseudo-obstruction.

in the right cerebral hemisphere. The electromyogram demonstrated myopathic changes.

A muscle biopsy of the brachial biceps revealed abundant ragged-red fibres (RRF) strongly positive to succinate dehydrogenase staining, that stained positive for cytochrome c-oxidase (COX) activity in most fibres, although there were some RRF-COX negative fibres.

Genetic analysis of mtDNA revealed the presence of the A3243G mutation in muscle and blood from the patient, which confirmed the diagnosis of MELAS syndrome.

She was treated with L-carnitine ($1 \text{ g } 24 \text{ h}^{-1}$), Co-enzyme Q ($100 \text{ mg } 12 \text{ h}^{-1}$), and B-complex vitamins (B1, B6, B12).

One month after this first episode, she presented with seizures, lactic acidosis, intestinal pseudo-obstruction and urinary retention. Two months later the patient had an acute severe paralytic ileus. She is currently treated with L-carnitine, erythromycin and B-complex vitamins and is relatively doing well, having a regular intestinal rhythm, and recovered oral nutrition. The only remaining sequelae are a sensorineural hearing loss and a mild disorder of the cortical function consisting of euphoria.

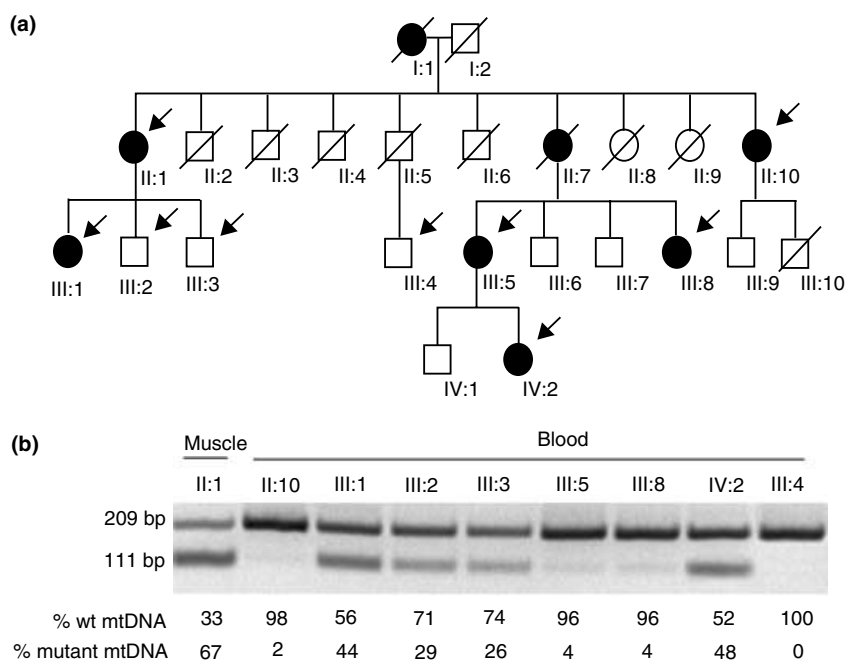


Fig. 2 Family pedigree (a) and molecular analysis, (b) in family members, with the A3243G mutation. In the presence of the mutation, the 209 bp fragment is cleaved by the endonuclease Apa I into two fragments of 111 and 98 bp (not shown), whilst the wild-type mtDNA remains uncut. Arrows indicate individuals tested for the mutation and solid symbols denote symptomatic members. Percentages of mutation are shown for blood and muscle.

Other individuals

I:1. The proband's mother, died at 81 years of age because of cardiopathy. She was likely to have been affected because she was short in stature and deaf since adolescence.

II:7. The proband's sister, was also short in stature and deaf, and who developed, late in life, a psychiatric-like disease (characterized by lost of inhibition) and a stroke. A cranial CT showed a hypodense area, apparently ischaemic, and massive calcification of the basal ganglia. She died at 72 years of age, because of congestive cardiopathy.

II:10. The 67-year-old sister of case II:1, the only proband's sibling still alive, was short in stature, diabetic and deaf.

III:1, III:5, III:8, and IV:2. The daughter, cousins and a cousin's daughter of the case II:1 share a similar phenotype of short stature and thin muscles, and they refer easy tiredness and frequent constipation.

III:2, III:3, III:4. The proband's sons and a male cousin are asymptomatic.

Methods

Exercise tests

Serum determinations of lactate and pyruvate before and after an isometric aerobic exercise of 20 min were performed in six family members.

Mitochondrial genetic analysis

Total DNA was extracted from skeletal muscle and blood of each patient, using an established procedure [3]. The mtDNA tRNA^{Leu(UUR)} region spanning between 3145 and 3354 mtDNA positions, was PCR-amplified, with suitable primers as described [4]. The 209 bp PCR product was then digested by Apa I and the fragments separated by electrophoresis. The A3243G mutation creates a restriction site for Apa I, yielding fragments of 111 and 98 bp, whereas the wild-type sequence remains uncut. Percentages of mutant mtDNA were estimated densitometrically. To confirm the presence of the mutation the mtDNA fragment was sequenced in an ABI 310 (PE Biosystems, Foster City, CA, USA), using the same set of primers.

Results

Family pedigree and proportion of mutant genomes are shown in Fig. 2. The A3243G point mutation was heteroplasmic in all patients studied, except in case III:4, a nephew of the proband, son of the proband's brother. The percentage of mutant mtDNA in muscle fibres of the proband was 67% and varied between 2 and 48% in family members (blood samples).

The case IV:2, the 23-year-old second-cousin of case II:1 had the highest percentage of mutated DNA (48%); the proband's 19-year-old daughter (case III:1) had 44% mutant genomes. Both of them have short stature and easy tiredness, with no further symptoms.

Exercise tests revealed an elevation of serum lactate and piruvate after isometric aerobic exercise in those family members with the highest proportion of mutant blood mtDNA (cases III:1 and IV:2).

Discussion

Mitochondrial DNA disorders are a heterogeneous group of diseases that affect mitochondrial energy metabolism and result in decreased aerobic adenosine triphosphate (ATP) production and impairment of energy-requiring functions. Individuals affected with disorders of mitochondrial energy production can have a wide range of multisystemic symptoms [5]. MELAS syndrome, first described by Pavlakis *et al.* in 1984 [2], is associated with mtDNA point mutations; particularly with the A3243G substitution [4]. Our patient showed the following cardinal features of MELAS syndrome: RRF, stroke-like episodes, lactic acidosis, seizures and progressive dementia. In addition, she had gastrointestinal dysmotility and urinary retention, which are unusual findings in patients with MELAS. The evidence of maternal transmission of the trait, together with the histochemical findings, prompted us to look for the A3243G mutation in mtDNA. Molecular analysis revealed the presence of the mutation in varying levels of heteroplasmy in the different tissues of several individuals related to maternal lineage. Cases III-4 and III-2 illustrate the concept of maternal transmission of the mutation: III-4 was the son of the proband's brother and harboured 100% of normal mtDNA (no transmission via males), whereas III-2 was the son of the proband and harboured 29% mutant mtDNA. MELAS has mater-

nal inheritance, but the onset, severity and course of the disease, cannot be accurately predicted by different levels of heteroplasmy in tissues and differing threshold values in different organs and individuals, as demonstrated by the lack of relationship between proportion of mutant genomes and severity of clinical phenotype in our family.

Gastrointestinal dysmotility, including diarrhoea and pseudo-obstruction syndrome, is a cardinal feature of MNGIE, which is often associated with multiple deletions in mtDNA but, in contrast to MELAS syndrome, MNGIE is an autosomal recessive disorder because of mutations in the nuclear-encoded TP gene [6]. In addition, intestinal pseudo-obstruction has also been documented in a patient with encephalopathy and cardiomyopathy, harbouring a large-scale mtDNA deletion [7]. The case we describe here raises a special interest because of the main gastrointestinal involvement and the urinary retention associated with the A3243G mutation. Although the combination of MELAS and gastrointestinal dysmotility has been reported before [8], it is rather unusual, particularly if associated with urinary retention. The symptoms of urinary tract may suggest a more generalized involvement of smooth muscle cells caused by the A3243G mutation. The aetiology of the intestinal pseudo-obstruction is unclear, whether they result from defective energy output in enteric neurones [6], smooth muscle [7], or both, will require further research.

These data extend and confirm the wide clinical spectrum of mitochondrial disorders associated with the A3243G mutation [9].

In conclusion, for a clinician, the MELAS syndrome should not be considered any longer as an encapsulated group of definite symptoms, but a multisystemic disorder that should be suspected in young and middle-aged people [10] with symptoms and signs of muscular and visceral myopathy and/or pathological family history. Also, genetic counselling in those family members at high risk of developing or transmitting this mutation is recommended, as it is the introduction of adequate treatments [11].

References

- 1 Shapira Y, Harel S, Russel A. A group of neuromuscular disorders with defects in oxidative metabolism. *Israel J Med Sci* 1977; 13: 161–4.

- 2 Pavlakis SG, Phillips PC, DiMauro S, De Vito DC, Rowland LP. Mitochondrial myopathy, encephalopathy, lactic acidosis and stroke-like episodes: a distinctive clinical syndrome. *Ann Neurol* 1984; **16**: 481–8.
- 3 Sue CM, Crimmins DS, Presgrave CM *et al.* Neuroradiological features of six kindreds with MELAS tRNA^{Leu} A3243G point mutation: implications of pathogenesis. *Neurol Neurosurg Psych* 1998; **65**: 233–40.
- 4 Goto Y, Nnaka I, Horai S. A mutation in the tRNA-Leu (UUR) gene associated with the MELAS subgroup of mitochondrial encephalomyopathies. *Nature* 1990; **348**: 651–3.
- 5 Munnich A, Rustin P, Rotig A, Chretien D, Bonnefont JP, Nutton C. Clinical aspects of mitochondrial disorders. *J Inherit Metab Dis* 1992; **15**: 448–55.
- 6 Hirano M, Silvestri G, Blake DM *et al.* Mitochondrial neurogastrointestinal encephalomyopathy (MNGIE): clinical, biochemical, and genetic features of an autosomal recessive disorder. *Neurology* 1994; **44**: 721–7.
- 7 Campos Y, Martin MA, Caballero C *et al.* Single large-scale mitochondrial DNA deletion in a patient with encephalopathy, cardiomyopathy, and prominent intestinal pseudo-obstruction. *Neuromusc Dis* 2000; **10**: 56–8.
- 8 Shimotake T, Furukawa T, Katsuhiro I, Iwai N, Takeuchi Y. Familial occurrence of intestinal obstruction in children with the syndrome of mitochondrial encephalomyopathy, lactic acidosis and stroke-like episodes (MELAS). *J Pediatr Surg* 1998; **33**: 1837–9.
- 9 Leonard JV, Schapira AHV. Mitochondrial respiratory chain disorders I. mitochondrial DNA. *Lancet* 2000; **355**: 299–304.
- 10 Kimata KG, Gordan L, Ajax ET, Davis PH, Grabowski T. A case of late-onset MELAS. *Arch Neurol* 1998; **55**: 722–5.
- 11 Dougherty FE, Ernst SG, Aprille JR. Familial recurrence of atypical symptoms in an extended pedigree with the syndrome of mitochondrial encephalomyopathy, lactic acidosis and stroke-like episodes (MELAS). *J Pediatr* 1994; **5**: 758–61.

Received 23 September 2002; revision received 24 October 2002; accepted 19 November 2002.

Correspondence: Dr Adelaida Garcia-Velasco, Department of Medical Oncology, University Hospital 12 de Octubre, Avda. de Córdoba Km. 5, 4. 28041, Madrid, Spain (fax: 34-91-4603310; e-mail: adelaidaoncomed@yahoo.es).