

# Sudden Death in a 35-Year-Old Man with Occult Malformation of the Brain and Aseptic Meningitis

Jakob Matschke, M.D., Maria Makrigeorgi-Butera, M.D., and Dimitrios Stavrou, M.D.

A 35-year-old man was found dead by his wife. He was reported to have had symptoms of a common cold the week preceding his death. The medicolegal autopsy yielded signs of central dysregulation (ectasia of the urinary bladder and rectum, dystelectasis of the lungs) together with marked brain edema and fresh bite marks on the tongue. The cause of death was presumed to be lethal epileptic seizure. Neuropathologic examination revealed neuronal nodular heterotopia as well as discrete lymphocytic meningitis (aseptic meningitis). The death was most probably caused by the combination of the meningitis with the occult malformation, leading to a lowered seizure threshold and subsequent lethal seizure. The morphologic findings of this case are presented, and the probable mechanisms of death are discussed.

**Key Words:** Sudden death—Brain malformation—Meningitis—Aseptic—Neuronal heterotopia.

Sudden unexpected death has been defined as death occurring in a very short interval beginning from the onset of symptoms, making it impossible for any physician familiar with the patient to certify the cause of death with reasonable accuracy. The length of the interval has been given as long as 24 hours by some authors and as short as 1 hour by others (1,2).

Intracranial pathologic conditions as a cause of sudden unexpected death are all too familiar to the forensic practitioner. Intracranial bleeding (intracerebral hemorrhage or spontaneous subarachnoid hemorrhage), infections (bacterial meningitis), sudden unexpected death in patients with epilepsy (SUDEP), and tumors are among the most frequent (3).

Neuronal nodular heterotopia, defined as nodules of gray matter in an inappropriate location (4), are a frequent finding both in patients with intractable epilepsy and in normal subjects after careful neuropathologic examination.

We present the case of a 35-year-old man with clinically silent and occult nodular heterotopia, in whom an additional benign lymphocytic meningitis led to death resulting from epileptic seizure.

## CASE REPORT

The 35-year-old man worked as a physician in a hospital. He was reportedly in complete good health, apart from stress at the job and being a heavy smoker. During the week preceding his death he experienced a common cold (fever, headaches, malaise, coughing, sneezing). On the day of his death, he went to bed at about 11 P.M. and suddenly sat up in bed, leading to his wife's "impression of something being wrong." She went to another room to call an ambulance. When she came back, the man had fallen out of bed and was lying on the floor, pulseless and breathless. Despite cardiopulmonary resuscitation attempts by the emergency physician who arrived some 5 minutes later at the scene, the man died. A legal autopsy

Manuscript received August 28, 2002; accepted November 14, 2002. From the Institute of Neuropathology (J.M., M.M.-B., D.S.) and the Institute of Legal Medicine (J.M.), University Hospital of Hamburg-Eppendorf, Hamburg, Germany.

Address correspondence and reprint requests to Dr. J. Matschke, Institute of Neuropathology, Martinistrasse 52, D-20246 Hamburg, Germany; e-mail: matschke@uke.uni-hamburg.de

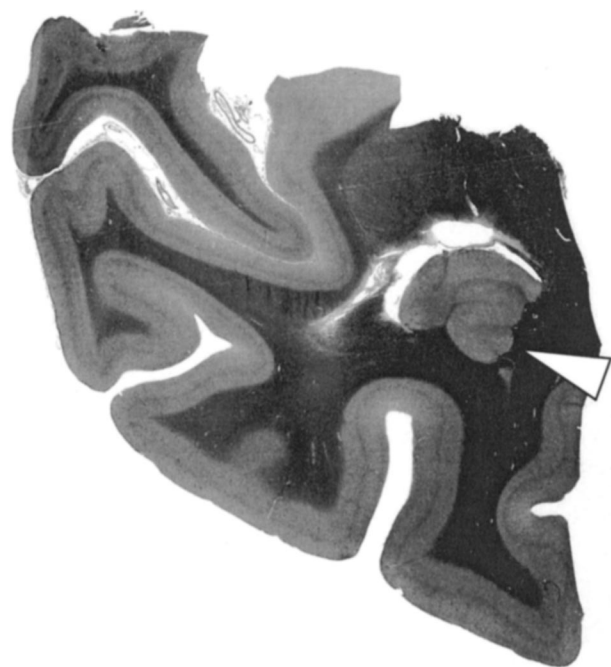was initiated by the local authorities and was performed 36 hours after the death.

### Autopsy Findings

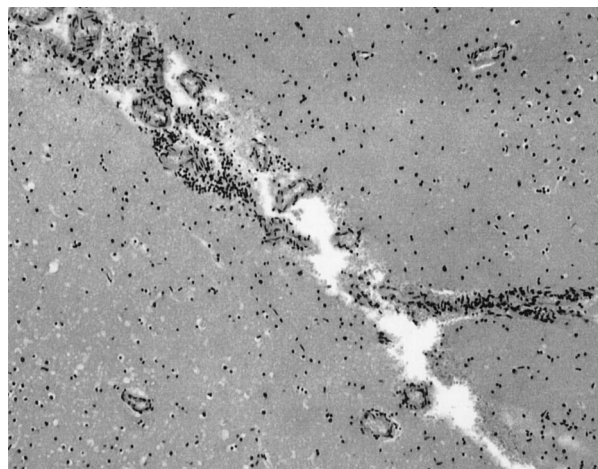
The body was that of a 35-year-old obese man (body weight 102 kg, body length 181 cm). Apart from signs of cardiopulmonary resuscitation (electrodes, vein cannulas) no external abnormalities could be seen. Signs of central dysregulation were present, with ectasia of bladder and rectum, pulmonary dystelektasis and edema, and marked brain edema (fresh brain weight 1720 g). Fresh bite marks appeared on the tongue. Slight general and coronary atherosclerosis was seen. Acute infection of the upper airways was seen, with edema and congestion of the bronchial mucosa and moderate amount of mucus. The remaining morphologic findings were completely unremarkable. Intoxication was ruled out: the blood alcohol concentration was 0.00 mg/ml, and toxicologic analysis failed to detect any drugs or unusual substances. Histologic analysis of the internal organs yielded no pathologic findings, especially no signs of myocarditis or pneumonia. Death was attributed to epileptic seizure, and the unsliced brain was fixed in formalin for 3 weeks.

### Neuropathologic Findings

Macroscopically, signs of marked brain edema with flattened gyri, compression of the ventricular system, and prominent temporal and tonsillar herniation were seen. Around the occipital horns of the lateral ventricles, nodules of gray matter were seen bilaterally, bulging into



**FIG. 1.** Occipitomedial right with nodular mass of ectopic grey substance (white arrowhead) bulging into the ventricular lumen (Elastica-van-Gieson).



**FIG. 2.** Subarachnoid space between two adjacent gyri showing moderate lymphocytic infiltrates H & E; original magnification 10 $\times$ .

the ventricular lumen, raising the suspicion of subependymal nodular heterotopia (Fig. 1).

Microscopically, the heterotopia consisted of clusters of disorderly arranged neurons and glia lining the ventricular wall. The overlying cerebral cortex appeared normal. Furthermore, there were scanty to moderate lymphocytic infiltrates in the subarachnoid space and in the perivascular spaces surrounding some of the superficial cortical blood vessels (Fig. 2). Immunohistochemically, these infiltrates consisted mainly of T lymphocytes intermingled with some B lymphocytes. Further immunohistochemical studies failed to reveal antigens of herpes simplex virus type I and II, cytomegalovirus, Epstein-Barr virus, varicella zoster virus, mumps virus, or human immunodeficiency virus. No other abnormalities could be found, in particular no indications of epileptic scars (hippocampal sclerosis) or other malformations.

### DISCUSSION

According to most recent advances in the research of cerebral cortical development, this extremely complex process can be subdivided into three general and overlapping steps: (1) cell proliferation, which includes neuronal and glial proliferation and apoptosis, (2) neuronal migration, and (3) cortical organization (5). These milestones of cerebral cortical development provide a framework of both known and yet undescribed malformations, given that each of the steps has its own unique set of characteristic malformations.

Disorders of neuronal migration, for example, may interrupt any of the many complex and interacting processes that lead the immature neuron through the developing hemisphere until it reaches the proper layer of the mature cerebral cortex (5).

Neuronal heterotopias are malformations that result from disorders of neuronal migration, allowing multiplication of neuroblasts but preventing or arresting their migration from the periventricular region into the later cerebral cortex (6). They consist of aggregates of neurons and glia that form a nodular, bandlike or ribbonlike mass of gray matter in an appropriate location (4–6). Heterotopias may be single or multiple, unilateral or bilateral. They can be located just beneath the ventricular lumen (subependymal), in the deep white matter (subcortical), or even in the arachnoid (marginal glioneuronal) (5). They can be associated with accompanying malformations of the overlying, corresponding cortex. The genetic basis of some rare familial forms of heterotopias have been elucidated (7–9); however, most cases appear to be sporadic (6). In animal models of heterotopia, orthodromic and antidromic neuronal connections between the heterotopia and overlying neocortex and hippocampus can be found. Furthermore, both the heterotopia and the overlying cortex show altered excitatory and inhibitory neurotransmitter receptor units, an increase in intrinsically bursting neurons, and prolonged depolarization potentials (10), findings that help explain the fact that heterotopias can produce epilepsy in animal models and in humans.

The term “aseptic meningitis” was coined long ago to describe a clinical syndrome of meningeal inflammation, in which common bacterial agents could not be identified in the cerebrospinal fluid (11). With newer and more sophisticated techniques, many pathogens, mostly viral, have been associated with this syndrome. Nowadays, the term is used to describe a syndrome of fever, headache, and meningeal irritation together with moderate lymphocytic pleocytosis in the cerebrospinal fluid. Implicit in the definition is the absence of signs of involvement of the brain (encephalitis) or spinal cord (myelitis), which in turn underlies the benignity of the illness in the overwhelming number of cases (11). Depending on the amount and sophistication of diagnostic methods used, members of the family of enteroviruses can be detected in 75% to 90% of all cases with aseptic meningitis (12,13).

According to the morphologic findings in our case, this 35-year-old man had both bilateral subependymal nodular heterotopia and benign lymphocytic (aseptic) meningitis. The cause of the meningitis could not be elucidated, but because most of the rarer forms of aseptic meningitis (herpes simplex virus type I and II, cytomegalovirus, Epstein-Barr virus, varicella zoster virus, mumps virus, and human immunodeficiency virus (11)) could be ruled out by immunohistochemistry, the infectious agent in our case could well have been a member of the family of enteroviruses (for which no antibody exists).

Seizures are not considered as part of the clinical spectrum in lymphocytic meningitis without involve-

ment of the brain proper (no encephalitis). As for the necessary lowering of seizure thresholds, the gray matter has to be affected by the inflammatory process (14,15). Heterotopias are a relatively frequent finding in unselected patients with epilepsy, e.g. 10% in the series of Meencke and Veith (16), and epilepsy is a rather common symptom in patients with symptomatic heterotopias, e.g. 82% in the series of Dubeau et al. (6)). Therefore, it seems justified to conclude that the clinically silent heterotopias in our case might very well have lowered the seizure threshold to a point at which any other disturbance in the dynamics of the neuronal network (14) led to the terminal lowering of the threshold that did indeed cause the lethal seizure. All findings in this case strongly suggest the meningitis as being this additional disturbance.

In our opinion, the patient in this case could not be classified as a SUDEP case, because in all definitions the diagnosis of epilepsy, meaning recurrent unprovoked seizures, is mandatory (17,18). In the history of this man there were no indications of recurrent seizures, and it seems reasonable to assume that he himself, as a doctor, would have easily recognized the symptoms of a seizure.

Retrospectively, we believe that the man in our case experienced a provoked or acute symptomatic seizure because it occurred in close temporal relationship with an acute meningitis. Judging from the history given by the wife, a registered nurse, who witnessed the man sitting up in bed and giving her the impression of “something being wrong,” the seizure could at least initially have been a partial one (given that no tonic and/or clonic movements were noted by her). Finally, the partial seizure obviously generalized secondarily, with the fresh tongue bites as the strongest indicator for this event.

The issue concerning the actual terminal cause of death resulting from seizure has not yet been solved. Central apnea is known to occur in seizures (19,20), and this would very well explain the signs of central dysregulation in our case. Other theories draw attention to the arrhythmogenic epileptic death, because seizures are known to potentially induce malignant cardiac arrhythmias (21,22).

Our case cannot contribute further to this debate, but it underlines once more the importance of meticulous investigation and analysis of unexplained deaths. This is especially true for neuropathologic studies, which we recommend be done in all cases of unexplained death with a suspected intracranial cause, because only the analysis of the formalin-fixed brain by an experienced neuropathologist is capable of detecting even the slightest morphologic cause of sudden unexplained death (23,24).

## REFERENCES

1. DiMaio VJ, DiMaio D. Sudden, unexpected natural death. In DiMaio VJ, DiMaio D. *Forensic pathology*. 2nd ed. Boca Raton, FL: CRC Press, 2001:6–9.

2. Knight B. The pathology of sudden death. In Knight B. *Forensic pathology*. 2nd ed. London: Arnold, 1996:487–515.
3. Black M, Graham DI. Sudden unexplained death in adults caused by intracranial pathology. *J Clin Pathol* 2002;55:44–50.
4. Porter BE, Brooks-Kayal A, Golden JA. Disorders of cortical development and epilepsy. *Arch Neurol* 2002;59:361–5.
5. Barkovich AJ, Kuzniecky RI, Jackson GD, Guerrini R, Dobyns WB. Classification system for malformations of cortical development. Update 2001. *Neurology* 2001;57:2168–78.
6. Dubeau F, Tampieri D, Lee N, et al. Periventricular and subcortical nodular heterotopia: a study of 33 patients. *Brain* 1995;118:1273–87.
7. Gleeson JG, Allen KM, Fox JW, et al. Doublecortin, a brain-specific gene mutated in human X-linked lissencephaly and double cortex syndrome, encodes a putative signaling protein. *Cell* 1998;92:63–72.
8. Des Portes V, Pinard JM, Billuart P, et al. A novel CNS gene required for neuronal migration and involved in X-linked subcortical laminar heterotopia and lissencephaly syndrome. *Cell* 1998;92:51–61.
9. Fox JW, Lamperti ED, Eksioglu YZ, et al. Mutations in filamin 1 prevent migration of cerebral cortical neurons in human periventricular heterotopia. *Neuron* 1998;21:1315–25.
10. Sancini G, Franceschetti S, Battaglia G, et al. Dysplastic neocortex and subcortical heterotopias in methylazoxymethanol-treated rats: an intracellular study of identified pyramidal neurons. *Neurosci Lett* 1998;246:181–5.
11. Rotbart HA. Viral meningitis and the aseptic meningitis syndrome. In Scheld WR, Whitley RJ, Durack DT, eds. *Infections of the central nervous system*. 2nd ed. Philadelphia: Lippincott-Raven, 1997:23–46.
12. Rotbart HA. Diagnosis of enteroviral meningitis with the polymerase chain reaction. *J Pediatr* 1990;117:85–9.
13. Sawyer MH, Holland D, Aintablian N. Diagnosis of enteroviral central nervous infection by polymerase chain reaction during a large community outbreak. *Pediatr Infect Dis J* 1994;13:177–82.
14. Lopes da Silva FH, Wadman WJ. Pathophysiology of epilepsy. In Meinardi H, ed. *Handbook of clinical neurology*. Vol. 72. *The epilepsies*. Part 1. Amsterdam: Elsevier, 1999:39–81.
15. De Bittencourt PRM, Sander JW, Mazer S. Viral, bacterial, fungal and parasitic infections associated with seizure disorders. In Meinardi H, ed. *Handbook of clinical neurology*. Vol. 72. *The epilepsies*. Part 1. Amsterdam: Elsevier, 1999:145–74.
16. Meencke HJ, Veith G. Migration disturbances in epilepsy. *Epilepsy Res* 1992;(Suppl)9:31–40.
17. Nashef L. Sudden unexpected death in epilepsy: terminology and definitions. *Epilepsia* 1997;38(Suppl 11):S6–S8.
18. Annegers JF. United States perspective on definitions and classifications. *Epilepsia* 1997;38(Suppl 11):S9–S12.
19. Nashef L, Walker F, Allen P, Sander JW, Shorvon SD, Fish DR. Apnoea and bradycardia during epileptic seizures: relation to sudden death in epilepsy. *J Neurol Neurosurg Psychiatry* 1996;60:297–300.
20. So EL, Sam MC, Lagerlund TL. Postictal apnea as a cause of SUDEP: evidence from near-SUDEP incident. *Epilepsia* 2000;41:1494–7.
21. Reeves AL, Nollet KE, Klass DW, Sharbrough FW, So EL. The ictal bradycardia syndrome. *Epilepsia* 1996;37:983–7.
22. Jallon P. Arrhythmogenic seizures. *Epilepsia* 1997;38(Suppl 11):S43–S47.
23. Rossi L. Bulbo-spinal pathology in neurocardiac sudden death of adults: a pragmatic approach to a neglected problem. *Int J Legal Med* 1999;112:93–0.
24. Sperhake JP, Matschke J, Orth U, Gal A, Püschel K. Sudden death due to cerebrotendinous xanthomatosis confirmed by mutation analysis. *Int J Legal Med* 2000;113:110–3.