

Vocal Cord Palsy Resulting From Spontaneous Carotid Dissection

Tiemo Wessels, MD; R. Sparing, MD; C. Neuschaefer-Rube, MD, PhD; C. Klötzsch, MD, PhD

Objectives/Hypothesis: Vocal cord palsy has a variety of causes, such as malignant tumors of the thyroid, lung, or upper mediastinum, aortic aneurysm, surgery of the thyroid, and infectious diseases. **Study Design:** Case report. **Methods:** A 43-year-old biologist had a holocephalic headache and right-sided neck pain for 1 day. Five days later, he developed paralysis of the right-side vocal cord. In addition, an angiotensin converting enzyme (ACE) inhibitor was administered because the patient had high systolic and diastolic blood pressures, which were formerly not known to the patient. Five days after admission, a temporary sensorimotor hemiparesis occurred. **Results:** Neurological examination revealed, in addition to the known paralysis of the right-side vocal cord, right-side palatoplegia, right-side hypoglossal nerve palsy, and mild dysphagia. Duplex sonography showed evidence of lumen narrowing of the right-side internal carotid artery caused by an hypoechogenic mural hematoma. Magnetic resonance imaging (0.5 T, Philips Gyroscan) revealed a circumscribed dissection of the right-side internal carotid artery from the carotid bifurcation to the petrosal segment. The diffusion-weighted magnetic resonance imaging scan of the brain also demonstrated multiple embolic ischemic lesions in the right hemisphere. **Conclusion:** Internal carotid artery dissection must be included in the differential diagnosis of lower cranial nerve palsy and should be assessed by duplex ultrasonography and magnetic resonance imaging. **Key Words:** Vagus nerve palsy, carotid artery dissection, lower cranial nerve palsies, tenth cranial nerve, magnetic resonance imaging, vocal cord palsy.

Laryngoscope, 113:537–540, 2003

INTRODUCTION

Paralysis of the vocal cord has a variety of causes, such as malignant tumors of the thyroid, lung, or upper mediastinum, aortic aneurysm, surgery of the thyroid,

and infectious diseases.^{1–5} In some cases, no cause is found despite extensive investigations. These cases are categorized as idiopathic palsies. Patients present with a persistent hoarseness and weakness of the voice. Additional symptoms might improve the diagnostic process. We present the unusual case of a unilateral paralysis of the vocal cord resulting from a spontaneous internal carotid artery (ICA) dissection. Although rare, this differential diagnosis, if dismissed and untreated, might prove fatal because of the risk of cerebral embolism.

Typical presentation of spontaneous ICA dissection is an ipsilateral pain in neck and face with Horner syndrome and contralateral neurological deficits (e.g., hemiparesis or aphasia). A number of isolated lower cranial nerve palsies have been reported to be associated with ipsilateral ICA dissection.^{6–8} Cranial nerve palsy occurs in 3% to 12% of all patients with ICA dissection. However, in 3% of these patients a syndrome of occurrences of hemicrania and ipsilateral cranial nerve palsy is the sole outcome of ICA dissection, and in 0.5% of cases there is only cranial nerve palsy without headache.^{9–11}

CASE REPORT

A 43-year-old biologist had a holocephalic headache and a right-sided neck pain for 1 day. The general practitioner noticed a slight swelling of the cervical lymph nodes and made the diagnosis of sore throat caused by acute angina. Body temperature was normal. Blood samples were not taken, and the patient was given antibiotic treatment (Roxithromycin). The following day, the patient noted the beginning of a slowly progressive hoarseness. Five days later, he was admitted to the hospital. He was examined primarily by an otorhinolaryngological surgeon, who diagnosed a bilateral tonsillitis-pharyngitis inflammation of the salpingopalatine fold (history of tonsillectomy in 1972), a modest case of laryngitis, and uncompensated paralysis of the right-side vocal cord, which was considered to be due to a (para-) infectious paralysis of the right-side nervus vagus. Although body temperature was normal and blood values revealed no signs of inflammatory processes, the antibiotic treatment was continued by administration of intravenous cefotiam. Furthermore, topical and intravenous cortisone and Emalaptile were given. In addition, an angiotensin converting enzyme inhibitor was administered to reduce the high systolic and diastolic blood pressures (which were formerly not known to the patient). Five days after admission, a temporary sensorimotor hemiparesis occurred, lasting 5 to 10 minutes. The neurological and phoniatic examination revealed, in addition to the known paralysis of the right-side vocal cord

From the Departments of Neurology (T.W., R.S.) and Phoniatics, Pediatric Audiology, and Communication Disorders (C.N.-R.), Aachen University Medical School, Aachen, Germany; and the Department of Neurology (C.K.), Kliniken Schmieder Allensbach/Hegau-Klinikum, Singen, Germany.

Editor's Note: This Manuscript was accepted for publication October 15, 2002.

Send Correspondence to Tiemo Wessels, MD, Department of Neurology, Aachen University Medical School, Pauwelsstrasse 30, 52057 Aachen, Germany. E-mail: tiemo.wessels@gmx.net

(Fig. 1), a right-side palatoplegia, a right-side hypoglossal nerve palsy (Fig. 2), and mild dysphagia.

Duplex sonography of the carotid arteries showed a reduced diastolic flow in the right-side common and internal carotid artery, indicating a significant carotid lumen narrowing as a result of an intramural hematoma. Magnetic resonance imaging (MRI) (0.5 T, Philips Gyroscan) revealed a circumscribed dissection of the right-side ICA, extending from the carotid bifurcation to the petrosal segment (Fig. 3). The hyperintense signal in the T2-weighted images and in the T1-weighted images with fat suppression clearly indicated an intramural hematoma surrounding the artery with a semilunar shape. Its maximum extension was on the dorsolateral surface. A significant narrowing of the arterial lumen could be derived from a decreased flow void signal in the magnetic resonance angiography.

The diffusion-weighted MRI scan of the brain also demonstrated multiple embolic ischemic lesions in the right hemisphere. The possibility of performing intra-arterial angiography was rejected because the patient was allergic to iodine. Results of blood analyses for vasculitis and infectious diseases (e.g., borreliosis) were normal. The duplex sonography showed no evidence for a mycotic aneurysm. The patient had no recollection of any trauma that might have initiated the ICA dissection. He was treated with intravenous heparin and, subsequently, after discharge, with warfarin. A follow-up examination was recommended in 3 months.

DISCUSSION

In recent years, it has been recognized that isolated or combined lower-nerve palsy can be caused by spontaneous ICA dissection.^{7,9,10,12} Several distinct syndromes of cranial nerve palsies have been recognized to be associated with ICA dissection. These include syndromes of lower cranial, trigeminal or ischemic optic neuropathy and ocular motor palsies.¹⁰ The latter commonly is associated with ipsilateral Horner syndrome.

Our patient represents a rare case of combined ninth-, tenth-, and twelfth-nerve palsy caused by dissec-

tion of the ipsilateral ICA.⁸ Moreover, the palsy of the tenth nerve preceded the other nerve palsies by more than 5 days. Thus, the correct diagnosis might have been dismissed because of the wide variety and more common causes of a tenth-nerve palsy. However, analyzing the case retrospectively, there were at least some aspects which could have led to doubts. First, the patient reported a right-sided neck pain, which was initially mistaken for a sore throat. However, the symptom is typical for a carotid dissection. Second, the normal results from blood samples and the normal body temperature suggested a lack of infection. Third, the incidence of high blood pressure probably resulted from a consecutive increase attributable to a relevant carotid stenosis. A more detailed diagnostic investigation should have been performed before initiating antihypertensive therapy. Furthermore, in our case, the initial lack of additional neurological deficits made the diagnosis more difficult.

Carotid dissection can be caused by trauma and spontaneously. In some cases, congenital tissue defects such as fibromuscular dysplasia, Ehlers-Danlos syndrome, Marfan syndrome, or α 1-antitrypsin deficiency can be identified. However, in most cases, no cause could be found.^{9,10} The pathophysiological characteristics of lower cranial nerve palsies associated with a carotid dissection are still a matter of debate. A common hypothesis is that the mural hematoma of the dissected artery causes compression of the lower cranial nerves in the upper cervical parapharyngeal space where it is located laterally. To cause significant nerve compression, a substantial expansion of the vessel diameter would seem to be necessary. However, unlike the present case report, ICA dissections presenting with lower cranial nerve palsies rarely show symptoms of cerebral ischemia, and patients presenting

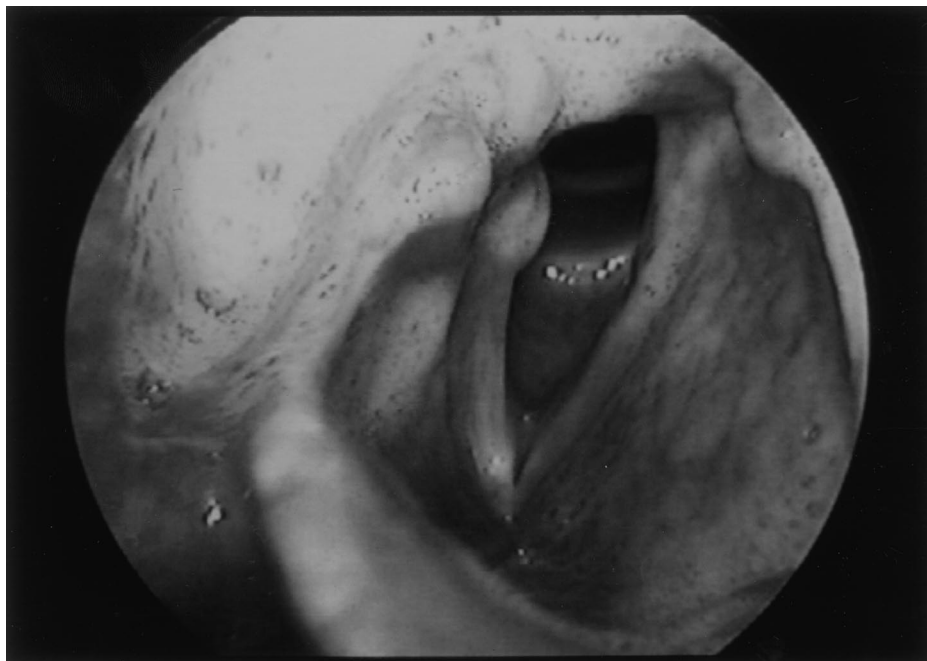


Fig. 1. Right-side vocal cord palsy with vocal cord excavation, incomplete glottal closure, and highly reduced phase-different vocal cord vibration. Laryngostroboscopy was carried by 90° optic convection to the computer-assisted media stroboscope system.

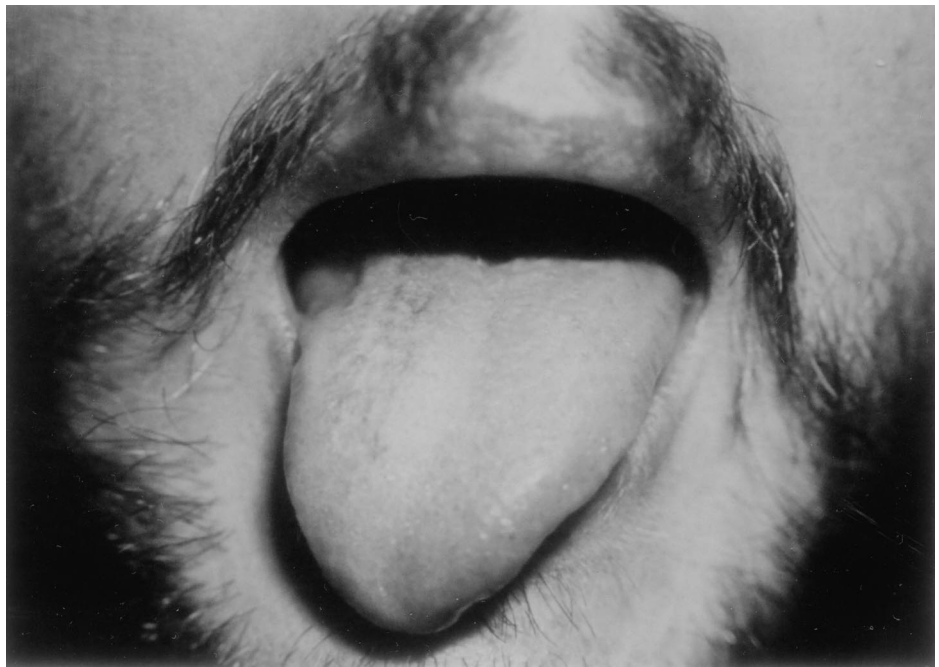


Fig. 2. Right-side hypoglossal palsy (tongue deviation to the right, reduced muscular force, and impaired tongue motion).

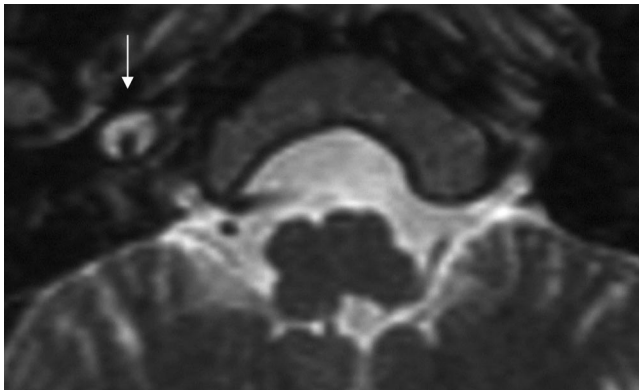


Fig. 3. T1-weighted image with fat suppression clearly indicated an intramural hematoma surrounding the right-side internal carotid artery with a semilunar shape (arrow); the normal left-side carotid artery shows no lumen narrowing.

with symptoms of cerebral ischemia rarely show lower cranial nerve palsies.

Baumgartner et al.¹³ discussed the theory of two different hematoma localizations within the arterial wall. The subintimal localized hematoma is likely to narrow or occlude the lumen of the artery and may cause cerebral

ischemia. If the hematoma is predominantly positioned in the subadventitial layer, the lumen might be only slightly affected, but it may lead to a considerable eccentric expansion of the vessel wall and thereby may compress lower cranial nerves. A less likely possibility is either a transient or permanent interruption of the blood supply of the cranial nerves by compression of the ascending pharyngeal artery. This seems to be unlikely because the ascending pharyngeal artery originates from the external carotid artery and only the rare variant of an origin from the ICA can explain an ischemic pathological mechanism (Table I).

In our case, the patient developed lower cranial nerve palsies and cerebral ischemia. Therefore, a combination of local compression of the cranial nerves below the jugular foramen and narrowing of the arterial lumen of the ICA with cerebral embolism resulting from endothelial dysfunction seems to be the most likely explanation.

Duplex sonography is considered to be a reliable technique for the detection of ICA dissection.^{9,11,12,14,15} Limitations such as the following must be considered: If the vessel lumen does not narrow and no changes in blood flow velocity occur at the site of lesion or proximal to it, the dissection might not be detected by Doppler sonography.⁶

The present case exemplifies the following: Although ICA dissection only rarely causes lower cranial nerve palsy, it should always be included in the differential

TABLE I.
Mechanisms for Neurologic Deficits in Carotid Dissection.

Subintimal hematoma	Cerebral ischemia (due to stenosis and embolism) (13)
Subadventitial hematoma	Compression of lower cranial nerves: cranial nerve palsy (13)
Interruption of the blood supply of the cranial nerves	Compression of the ascending pharyngeal artery: cranial nerve palsy (10)

diagnosis and should be assessed carefully by duplex ultrasonography and MRI.

Acknowledgments

The authors thank Gary Brook, PhD, Department of Neurology, Aachen University Medical School, for assistance in preparing the manuscript.

BIBLIOGRAPHY

1. Titche LL. Causes of recurrent laryngeal nerve paralysis. *Arch Otolaryngol* 1976;102:259–261.
2. Yumoto E, Minoda R, Hyodo M, Yamagata T. Causes of recurrent laryngeal nerve paralysis. *Auris Nasus Larynx* 2002;29:41–45.
3. Neuschaefer-Rube C, Haase G, Angerstein W, Kremer B. Unilateral recurrent nerve paralysis in suspected Lyme borreliosis [in German]. *HNO* 1995;43:188–190.
4. Taillibert S, Bazin B, Pierrot-Deseilligny C. Dysgeusia resulting from internal carotid dissection: a limited glossopharyngeal nerve palsy. *J Neurol Neurosurg Psychiatry* 1998; 64:691–692.
5. Teixido MT, Leonetti JP. Recurrent laryngeal nerve paralysis associated with thoracic aortic aneurysm. *Otolaryngol Head Neck Surg* 1990;102:140–144.
6. Spitzer C, Mull M, Topper R. Isolated hypoglossal nerve palsy caused by carotid artery dissection: the necessity of MRI for diagnosis. *J Neurol* 2001;248:909–910.
7. Guidetti D, Pisanello A, Giovanardi F, Morandi C, Zuccoli G, Troiso A. Spontaneous carotid dissection presenting lower cranial nerve palsies. *J Neurol Sci* 2001;184:203–207.
8. Guy N, Deffond D, Gabrillargues J, Carriere N, Dordain G, Clavelou P. Spontaneous internal carotid artery dissection with lower cranial nerve palsy. *Can J Neurol Sci* 2001;28: 265–269.
9. Leys D, Lucas C, Gobert M, Deklunder G, Pruvo JP. Cervical artery dissections. *Eur Neurol* 1997;37:3–12.
10. Mokri B, Silbert PL, Schievink WI, Piepgras DG. Cranial nerve palsy in spontaneous dissection of the extracranial internal carotid artery. *Neurology* 1996;46:356–359.
11. Sturzenegger M. Spontaneous internal carotid artery dissection: early diagnosis and management in 44 patients. *J Neurol* 1995;242:231–238.
12. Sturzenegger M, Huber P. Cranial nerve palsies in spontaneous carotid artery dissection. *J Neurol Neurosurg Psychiatry* 1993;56:1191–1199.
13. Baumgartner RW, Arnold M, Baumgartner I, et al. Carotid dissection with and without ischemic events: local symptoms and cerebral artery findings. *Neurology* 2001;57: 827–832.
14. Steinke W, Rautenberg W, Schwartz A, Hennerici M. Noninvasive monitoring of internal carotid artery dissection. *Stroke* 1994;25:998–1005.
15. Ozdoba C, Sturzenegger M, Schroth G. Internal carotid artery dissection: MR imaging features and clinical–radiologic correlation. *Radiology* 1996;199: 191–198.