

## CASE REPORT

B. Paghera • P. Mariën • L.A. Vignolo

**Crossed aphasia with left spatial neglect and visual imperception: a case report**

Received: 12 May 2002 / Accepted in revised form: 18 November 2002

**Abstract** A 64-year-old right-handed woman with no left-handers in the family developed aphasia associated with moderate left hemiparesis and dense left homonymous hemianopia following rupture of a right middle cerebral artery aneurysm and subsequent selective surgery confined to the right hemisphere. Severe left spatial neglect and constructional apraxia were also present. The patient was an achondroplastic dwarf whose previous medical and neurological history was otherwise unremarkable. Computed tomography of the brain showed a large right temporo-insulofrontoparietal lesion. Language and non-verbal cognitive functions were assessed after 2 and 6 months, and then four years later. A reportedly overall language disruption in the acute period evolved into Wernicke's aphasia and then into a mild form of conduction aphasia. The associated left spatial neglect eventually shrank to a minimum. The patient never had clinically detectable visual agnosia, but on specific tests of visual recognition and perception some impairment was found four years after onset. The left hemiparesis disappeared in time while the left hemianopia persisted. This case is a convincing example of an entirely right-handed person in whom both linguistic and visuospatial functions are represented in the right hemisphere.

**Key words** Crossed aphasia • Visual spatial disorders • Language

B. Paghera • L.A. Vignolo (✉)  
Neurological Clinic  
University of Brescia  
Spedali Civili, I-25125 Brescia, Italy

P. Mariën  
Department of Neurology  
General Hospital Middelheim  
Antwerp, Belgium

**Case report**

A 64-year-old right-handed woman with five years of schooling was admitted to hospital a few hours after the sudden onset of a severe headache which rapidly worsened in association with vomiting. Computed tomography (CT) of the brain revealed right subarachnoid hemorrhage with integrity of the left hemisphere. Angiography showed a saccular aneurysm of the right middle cerebral artery. The patient was alert but agitated and uncooperative. Clinical records indicated that her speech was scarce and incoherent, but gave no information as to fluency or nonfluency. There was a moderate left hemiparesis predominantly in the lower limb and a dense left homonymous hemianopia. Two days later she underwent right frontotemporal craniotomy and clipping of the aneurysm. After a brief period of clear consciousness the neurological situation worsened. A repeat CT scan showed an intracerebral hematoma in the site of surgery. The hematoma was urgently removed and the neurological situation gradually improved.

The patient was an achondroplastic dwarf who lived on a disability pension and the knitting she did at home. Her previous medical and neurological history was unremarkable. No sinistrality in the family was reported. The Edinburgh inventory [1] collected from relatives and, later, from the patient herself yielded a total score of 20/20 (laterality quotient = 100), stressing the patient's clear-cut dextrality, in spite of the fact that the right upper limb was somewhat shorter than the left due to a skeletal asymmetry related to achondroplasia.

Language and non-verbal cognitive functions were first assessed 2 and 6 months after onset, and then more extensively in our department four years afterwards (Table 1).

**Assessment at 2 months**

Language was assessed on the Aachener aphasia test (AAT) [2, 3]. Spontaneous language output was fluent though not overflowing and consisted of phonemic paraphasias, several

**Table 1** Neuropsychological assessment of the patient during follow-up. All scores are performance scores (number of correct responses) unless explicitly stated. Scores of some tests are adjusted for age or for age and years of schooling

Test	Patient's scores			Cut-off score	Maximum score
	2 months	6 months	4 years		
<b>Language</b>					
Aachener Aphasia Test, n (percentiles) of correct responses					
Token test	11 (50)	NP	44 (91)	NA	50
Repetition	73 (25)	NP	112 (52)	NA	150
Written language	36 (39)	NP	63 (70)	NA	90
Naming	39 (21)	NP	98 (80)	NA	120
Comprehension	76 (40)	NP	98 (77)	NA	120
Speech production	Fluent, many hesitations, phonemic errors and groping, anomias	Fluent, some hesitations, phonemic errors and groping, anomias	Fluent, a few hesitations, phonemic errors and groping, anomias	-	-
Aphasia diagnosis	Wernicke, severe	Wernicke, moderate	Conduction, mild	-	-
<b>Gestures</b>					
Oral	18	20	20	16	20
Ideomotor	71	72	71	62	72
<b>Visuospatial abilities</b>					
Attention					
Crossing-out lines					
Right	18	18	18	NA	18
Left	0	18 (very slow)	18	NA	18
Toulouse-Piéron test					
Right	3	3	5	NA	5
Left	0	0	2	NA	5
Line bisection, mm of offset	<b>71 (to the right)</b>	NP	<b>3.5 (to the right)</b>	0	-
Orientation					
Line orientation	NP	NP	2	21	30
Construction					
Copying drawings	0	3	4	4	4
Rey's figures copy, immediate	Left part neglected	Left part neglected	NP	-	-
Bender-Gestalt test	Left part neglected, severe	Left part neglected, moderate	NP	-	-
Drawing to command	0	1	3	3	3
Visual recognition					
Real objects	10	10	10	10	10
Faces	NP	NP	39	40	54
Overlapping figures	NP	NP	<b>38.34</b>	51.25	-
VOSP					
Screening test	NP	NP	19	NA	20
Incomplete letters	NP	NP	12	NA	20
Silhouettes	NP	NP	9	15	20
Object decision	NP	NP	12	14	20
Progressive silhouettes	NP	NP	16	<15	20
Dot counting	NP	NP	10	8	10

Cont. →

Table 1 cont.

Test	Patient's scores			normative score cut-off	Maximun score
	2 months	6 months	4 years		
<b>VOSP</b>					
Position Discrimination	-	-	<b>12</b>	NA	20
Number location	NP	NP	7	7	10
Cube analysis	NP	NP	<b>4</b>	6	10
<b>Auditory recognition</b>					
ESRT score	NP	NP	22	22	25
Errors, n					
Acoustic	NP	NP	2	3	-
Semantic	NP	NP	1	1	-
Unrelated	NP	NP	0	0	-
<b>Calculation</b>	Very poor	Very poor	Very poor	-	-
<b>Nonverbal intelligence</b>					
WAIS performance scale, raw score (adjusted score)					
Digit-symbol association	NP	NP	2 (6)	NA	-
Picture completion	NP	NP	5 (6)	NA	-
Block design	NP	NP	4 (6)	NA	-
Picture arrangement	NP	NP	2 (3)	NA	-
Object assembly	NP	NP	2 (4)	NA	-
Total scale	NP	NP	2 (5)	NA	-
Performance IQ	NP	NP	71	-	-
Raven's Progressive Matrices	<b>11</b>	NP	19	17.5	36
<b>Memory</b>					
Digit span	<b>3</b>	NP	4.5	3.75	-
Spatial span	NP	NP	4.25	3.50	-
Short story recall	NP	NP	11	7.5	28
Rey's figure copy, delayed	NP	NP	<b>2</b>	15	36

ESRT, Environmental Sound Recognition Test; VOSP, Visual Object and Space Perception Battery; WAIS, Wechsler Adult Intelligence Scale; NA, not available; NP, not performed. Abnormal scores are in bold

neologisms and anomias, with frequent hesitations, self-corrections, *conduites d'approche* and phonemic groping behavior. Intentional repetition was limited to phonemes and bisyllabic words. Picture naming was virtually impossible. Verbal description of a visual scene was made even more difficult by the associated severe left spatial neglect and by lack of synthesis in visuospatial perception: the patient not only ignored the left half of the scene but seemed compelled to inspect the details analytically. Auditory verbal comprehension in a conversational setting was variable but mostly poor. On testing, it was sometimes preserved for simple commands but not for the token test section of the AAT. Reading comprehension was also hampered by left inattention: only the last two words of the written sentence were read, and the rest was neglected. Reading aloud was, in addition, aprosodic, syllabic, with phonemic substitutions and omissions. Writing attempts were confined to the right half of the page and showed phonological errors and perseverations sometimes leading to short jargonographic sequences. The signature was sufficiently correct.

The overall diagnosis at this post-acute stage was severe Wernicke's aphasia. Language rehabilitation was started.

Nonverbal cognitive tests disclosed neither oral apraxia nor ideomotor apraxia. By contrast, left spatial neglect was severe on a number of ad hoc tests. On the lines crossing-out test [4], the patient crossed out only the lines drawn on the right half of the page. On the Toulouse-Piéron test, the patient correctly crossed out only three items located in the right lower corner, exploring merely the right half of the page from bottom to top. She was at a loss when trying to compare each item with the sample item drawn on top of the page. On the Bender-Gestalt test [5], the left sides of the drawings were incomplete and their spatial orientation was often wrong. On the drawing to command test (a house, a man, a tree), the patient failed to complete the left side of the house and the man. There was a marked constructional apraxia. The copy of Rey's figures [6] was very poor. Calculation was impossible except for the simplest additions, subtractions and multiplications (e.g. 16+4, 19-8, 11x3).

Since the standard tests could not be administered at this stage because of severe aphasia and left spatial neglect, memory was tentatively evaluated through touch and found not to be grossly impaired. The patient could easily remember three objects previously explored by touch.

### Assessment at 6 months

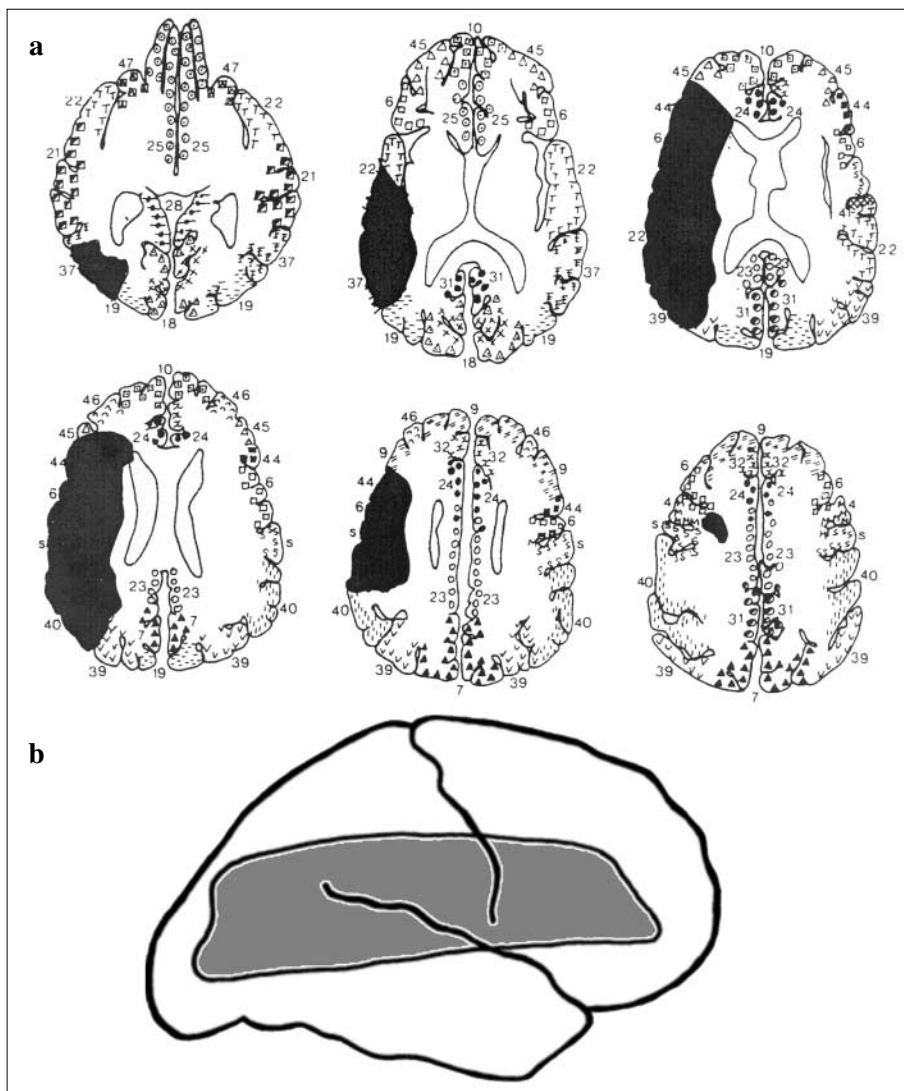
Six months after the onset of aphasia, language was informally re-assessed and the diagnosis was modified to moderate Wernicke's aphasia. The left spatial neglect was diminished on re-testing. On the lines crossing-out test, the patient crossed out all lines meticulously, starting with those drawn on the right side and proceeding with extreme slowness. On the more challenging Toulouse-Piéron test, only nine items located on the extreme right were crossed out. On the Bender-Gestalt test, she began all drawings from the right side, but then successfully completed them. The three drawings to command (a house, a man, a tree) were correct and symmetric. On verbally describing a complex scene, the patient now seemed to explore the whole picture. On writing lengthy phrases, both under dictation and in copy, she sometimes omitted the first word.

The patient continued rehabilitation on an outpatient basis for about one year, after which she applied for admission to a resting home, where she currently lives.

### Assessment at 4 years

Four years after onset of aphasia, the patient underwent extensive re-evaluation in our department. The neurological examination showed mild residual left hemiparesis with neither hemihyposesthesia nor extinction on double simultaneous tactile stimulation. Homonymous hemianopia involving the entire left visual field was still dense both on confrontation and on Goldmann's perimeter. The CT scan of the brain showed, in addition to signs of the old right frontotemporal craniotomy, a single large hypodense lesion involving the right corticosubcortical temporo-insulo-frontoparietal region, with slight widening of the right lateral ventricle. There were no other areas of ischemia. Neither midline shift nor damage to the left hemisphere was detected (Fig. 1). A metallic clip along the course of the right medial cerebral artery did not allow us to perform magnetic resonance imaging.

The neuropsychological examination (Table 1) investigated language, gestures, visuospatial attention, orientation and construction, visual and auditory recognition, calculation, non-verbal intelligence, and memory.



**Fig. 1** a CT scan of the lesion (*black*) mapped onto axial templates of brain sections, according to Damasio and Damasio [7]. The right hemisphere is represented in the left half of each section. Numbers indicate Brodmann's areas. **b** Lateral view of the lesion

The AAT showed unequal improvement in the various language modalities. Spontaneous speech was fluent with some hesitations, a few anomias and several phonemic paraphasias. Anomias and circumlocutions were present in over one-half of the naming tasks. Auditory-verbal comprehension was greatly improved (only six errors on the token test section), while repetition was still poor, mainly due to several phonemic paraphasias and phonemic groping behavior with unsuccessful attempts at self-correction. Repetition of compound words, foreign words and syntagms was virtually nil. Reading aloud was prosodically correct and sufficiently fluent, in spite of some phonemic paraphasias and *conduites d'approche*. Reading comprehension and all modalities of writing also improved. The overall diagnosis at this late stage was mild conduction aphasia.

The patient showed neither oral nor limb apraxia. The left spatial neglect was minimal, though not altogether absent. The patient made no errors on the line crossing-out test. On the Toulouse-Piéron test, two items on the left half of the page were missed. On line bisection, the mid-point was still shifted to the right by 3.5 mm in average. Copying pictures and drawing to command (a clock, a man, a butterfly) were correct. Constructional apraxia was still evident in the copy of Rey's figure, mainly due to awkwardness and mistakes in drawing the left half.

The patient, though not clinically agnostic, performed poorly on a number of visual perceptual tests administered for the first time at this late stage, such as the judgment of line orientation test [8] and most subtests of the visual object and space perception battery (VOSP) [9]. Borderline performance was observed in facial recognition [8] and Poppelreuter's overlapping figures test [10]. By contrast, nonverbal auditory recognition, assessed by the environmental sounds recognition test [11] was normal.

Calculation was confined to simple additions, subtractions and multiplications. The WAIS performance scale and Raven's coloured progressive matrices [12, 13] were performed at low-to-normal level. Among the standard memory tests, i.e. digit span, Corsi's spatial span, short story recall and the delayed copy (after 15 minutes) of Rey's figure, only the delayed copy was defective.

---

## Discussion

Our patient satisfies the basic criteria required for the diagnosis of crossed aphasia in a dextral (CAD), i.e. right-handedness assessed by a formal test, absence of familial sinistrality or previous brain damage, right hemisphere lesion and integrity of the left hemisphere [14, 15].

The patient underwent neuropsychological evaluation both in the post-acute phase and in different stages of the late phase (6 months and 4 years after onset). Two months after onset, fluent though halting paraphasic speech with poor comprehension and poor repetition indicated severe Wernicke's aphasia with predominantly phonemic disorders.

This clinical picture eventually evolved into a milder form suggesting conduction aphasia, characterized by fluent though slightly hesitant speech with phonemic paraphasias and *conduites d'approche*, some anomias, and minimal comprehension deficits, in contrast with poor repetition.

Whether these features of aphasia and the type of outcome were "mirror-like" or "anomalous" in Alexander et al.'s sense [16] is debatable. On the one hand, the clear-cut involvement of the premotor area and subjacent white matter would predict a nonfluent, rather than a fluent, type of aphasia, and our case should then be considered anomalous. On the other hand, the occurrence of a fluent aphasia following a lesion to the anterior language area of the left (dominant) hemisphere, though unusual, has also been observed in a small number of dextrals [17], and this would then allow us to consider our case as mirror-like. Whatever label one wants to use, it is noteworthy that the disorder in our patient disrupted mainly the phonological level of language processing, leaving the articulatory speech mechanisms intact and allowing a good recovery of comprehension. The shift in time from Wernicke's aphasia with predominantly phonemic errors in oral expression to conduction aphasia is the rule in this type of disorder.

The fact that aphasia was still remarkable after 6 months and that some language difficulties were left as late as four years later does not support the generalization that CAD is transient and has a particularly good prognosis, due to possibly incomplete language lateralization. On the contrary, the evidence indicates that in our patient language was deeply entrenched in the right hemisphere, particularly in the perisylvian areas homologous to the classic language areas subserving the phonological processes, and suffered in consequence. By contrast, motor planning presumably was still represented in the undamaged left hemisphere, as indicated by the absence of both ideomotor and oral apraxia. The preservation of oral gestures is particularly remarkable if one considers that the right sylvian opercula were destroyed – an event that, when occurring in the left hemisphere, is typically associated with oral apraxia [18].

What about the functions that are usually subserved by the right hemisphere in dextrals? Left spatial neglect was prominent and visual recognition, though unimpaired clinically, was found to be defective on some specific tests as late as four years after onset, indicating that control of left visual attention and other visual perceptual abilities remained in the right hemisphere, in cohabitation with language, and were disrupted by the lesion. Laiacona et al. [19] maintained that such overcrowding could make language more vulnerable to purely deep lesions. In our case, however, the damage did not destroy the deep gray nuclei, being confined to the cortex and the underlying white matter – a distribution that these authors found in no more than 39% of crossed aphasics with unilateral neglect vs. over 66% of those without neglect.

Constructional apraxia was not surprising, being reported in about three-quarters of patients with CAD [20] following a lesion in either hemisphere. Its presence in CAD tells us little about the lateralization of visuomotor functions. As to non-verbal auditory recognition, neither the perceptual dis-

crimination of similar sounds nor their semantic identification (which may be impaired in dextrals following, respectively, right and left hemisphere damage [11, 21]) were affected.

In conclusion, the main interest of our patient resides in the fact that a cortico-subcortical focal brain lesion in an adult disclosed an unusual hemispheric organization of the cognitive functions, consisting of the representation of both language and the visuospatial abilities in the right hemisphere.

---

**Sommario** Viene descritto il caso di una paziente di 64 anni, destrimane e senza mancini in famiglia, che ha presentato un'afasia con modesta emiparesi sinistra ed emianopsia laterale omonima sinistra in seguito alla rottura di un aneurisma dell'arteria cerebrale media destra e successivo intervento strettamente limitato all'emisfero destro. Il quadro clinico comprendeva anche una grave emi-inattenzione spaziale sinistra e un'aprassia costruttiva. La paziente era una nana acondroplastica con anamnesi medica e neurologica altrimenti negativa. Alla TC cerebrale si osservava un'ampia lesione temporo-insulo-fronto-parietale destra. Il linguaggio e diverse funzioni cognitive non verbali sono state valutate a distanza di due mesi, sei mesi e quattro anni dal danno cerebrale. A un disturbo globale del linguaggio nel periodo acuto è seguita un'afasia di Wernicke che, migliorando, ha assunto le caratteristiche di un'afasia di conduzione. Col tempo sono residuati soltanto minimi segni dell'emi-inattenzione spaziale sinistra. La paziente non ha mai presentato un'agnosia visiva clinicamente evidente, ma a test mirati di percezione e riconoscimento visivo si è notato un certo deficit ancora quattro anni dopo l'esordio dei disturbi. Col tempo l'emiparesi sinistra è scomparsa, mentre l'emianopsia è rimasta immutata. In questo caso il danno cerebrale ha rivelato che, in un individuo assolutamente destrimane, sia il linguaggio sia le funzioni visuospatiali erano rappresentate nell'emisfero destro.

**Acknowledgments** We thank Antonio Miozzo for contributing to the neuropsychological assessment of the patient.

---

## References

1. Oldfield RC (1971) The assessment and analysis of handedness: the Edinburgh inventory. *Neuropsychologia* 9:97–113
2. Huber W, Poeck K, Weniger D, Willmes K (1983) Der Aachener Aphasia Test (AAT). Hogrefe, Goettingen
3. Luzzatti C, Willmes K, Bisiacchi P, De Bleser R., Mazzucchi A, Posteraro C, Taricco M, Faglia L (1987) L'Aachener aphasia test (AAT): proprietà psicometriche della versione italiana. *Arch Psicol Neurol Psichiatria* 4:167–184
4. Albert M (1973) A simple test of visual neglect. *Neurology* 23:658–664
5. Hutt ML (1977) The Hutt Adaptation of the Bender-Gestalt Test, 3<sup>rd</sup> edn. Grune and Stratton, New York
6. Osterrieth PA (1944) Le test de copie d'une figure complexe. *Arch Psychol* 30:205–353
7. Damasio H, Damasio AR (1989) *Lesion Analysis in Neuropsychology*. Oxford University, New York
8. Benton AL, Hamsher KD, Varney NR, Spreen O (1983) *Contributions to Neuropsychological Assessment: a Clinical Manual*. Oxford University, New York
9. Warrington EK, James M (1991) *The Visual Object and Space Perception Battery*. Thames Valley Test, Bury St. Edmunds
10. Della Sala S, Laiacona M, Trivelli C, Spinnler H (1995) Poppelreuter-Ghent overlapping figures test: its sensitivity to age, and its clinical use. *Arch Clin Neuropsychol* 10:511–534
11. Schnider A, Benson DF, Alexander DN, Schnider-Klaus A (1994) Non-verbal environmental sound recognition after unilateral hemispheric stroke. *Brain* 117: 281–287
12. Raven JC (1938) *Standard Progressive Matrices*. Lewis, London
13. Basso A, Capitani E, Laiacona M (1987) Raven's coloured progressive matrices: normative values on 305 normal controls. *Funct Neurol* 2:189–194
14. Faglia L, Rottoli MR, Vignolo LA (1990) Aphasia due to lesions confined to the right hemisphere in right-handed patients: a review of the literature including the Italian cases. *Ital J Neurol Sci* 11:131–144
15. Mariën P, Engelborghs S, Vignolo LA, De Deyn PP (2001) The many faces of crossed aphasia in dextrals: report of nine cases and review of the literature. *Eur J Neurol* 8:643–658
16. Alexander MP, Fischette MR, Fischer RS (1989) Crossed aphasias can be mirror image or anomalous. *Brain* 112:953–973
17. Basso A, Capitani E, Laiacona M, Zanobio ME (1985) Crossed aphasia: one or more syndromes? *Cortex* 21:25–45
18. Tognola G, Vignolo LA (1980). Brain lesions associated with oral apraxia in stroke patients. *Neuropsychologia* 18: 257–272
19. Laiacona M, Capitani E, Stangalino C, Lorenzi L (1996) Crossed aphasia. II: Why are deep lesions overrepresented with respect to standard aphasia? *Behav Neurol* 9:163-170
20. Castro-Caldas A, Confraria A, Poppe P (1987) Non-verbal disturbances in crossed aphasia. *Aphasiology* 1:403–413
21. Vignolo LA (1982) Auditory agnosia. In: Broadbent DE, Weiskrantz L (eds) *The Neuropsychology of Cognitive Functions*. Philosophical Transactions of the Royal Society of London, B 298, pp 49–87