

SHORT REPORT

Sudden bilateral simultaneous deafness with vertigo as a sole manifestation of vertebrobasilar insufficiency

H Lee, H A Yi, R W Baloh

J Neurol Neurosurg Psychiatry 2003;**74**:539–541

A 68 year old woman presented with bilateral sudden simultaneous hearing loss and transient spontaneous vertigo as a sole manifestation of vertebrobasilar insufficiency. Extensive investigation to exclude other causes was unremarkable. Magnetic resonance imaging of the brain, including diffusion images, showed no abnormalities. A magnetic resonance angiogram showed severe stenosis of the middle third of the basilar artery. A pure tone audiogram showed moderate sensorineural-type hearing loss bilaterally. The localisation and mechanism of an isolated cochleovestibular dysfunction are discussed.

Vertebrobasilar insufficiency (VBI) can cause sudden bilateral deafness because the vertebrobasilar system supplies most of the auditory system including the inner ears.^{1–7} Characteristically, sudden bilateral deafness due to VBI is associated with multiple brain stem or cerebellar signs.^{1–6} To our knowledge, sudden bilateral simultaneous deafness with vertigo has not been reported as a sole manifestation of VBI.

We report on a patient who presented purely with sudden bilateral deafness and vertigo. This unusual presentation was due to a selective involvement of the inner ears supplied by the internal auditory arteries, ordinarily branches of the anterior inferior cerebellar artery (AICA).

CASE REPORT

A 68 year old woman with long standing non-insulin dependent diabetes mellitus and hypertension suddenly developed vertigo, vomiting, and bilateral tinnitus. Five minutes later, she noticed bilateral hearing loss. She had difficulty hearing her husband speak. She did not have dysarthria, numbness, weakness, visual distortion, or incoordination. The hearing loss persisted, but vertigo resolved over a few hours. Two days previously, she had had two episodes of transient vertigo and hearing loss involving the left ear that lasted no more than a few minutes without any accompanying neurological symptoms. The patient had no previous history of hearing difficulty. There was no prior history of temporal bone fracture, meningitis, autoimmune disease, or exposure to ototoxic drugs.

On admission, she had persistent bilateral hearing loss and non-specific dizziness with lightheadedness. The results of her general and neurological examinations were normal except for the bilateral hearing loss. Extensive blood tests including liver function tests, complete blood count, urea nitrogen, creatinine, erythrocyte sedimentation rate, circulating immune complex, and serum electrolytes were all normal. Antinuclear antibody, rheumatoid factor, C reactive protein, HIV serology, and

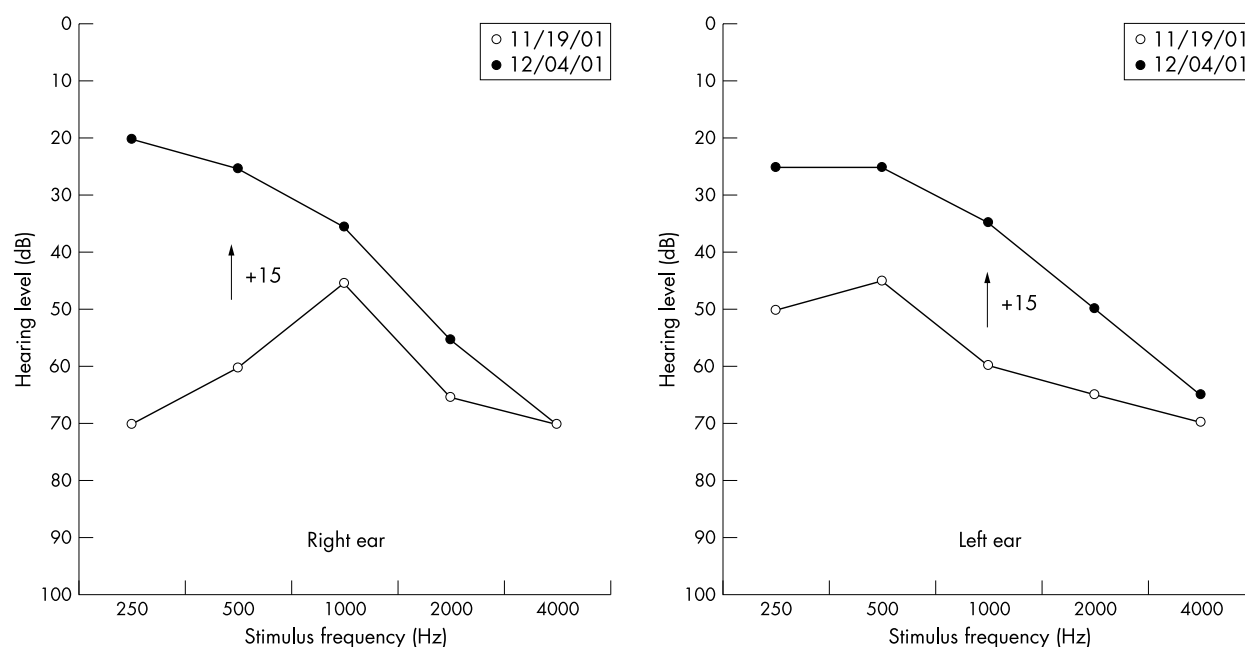


Figure 1 Pure-tone air conduction audiograms obtained on two different dates, 15 days apart (+15). The patient's hearing levels are plotted against stimulus frequency on a logarithmic scale. The decibels were measured according to the American National Standards Institute, 1989.

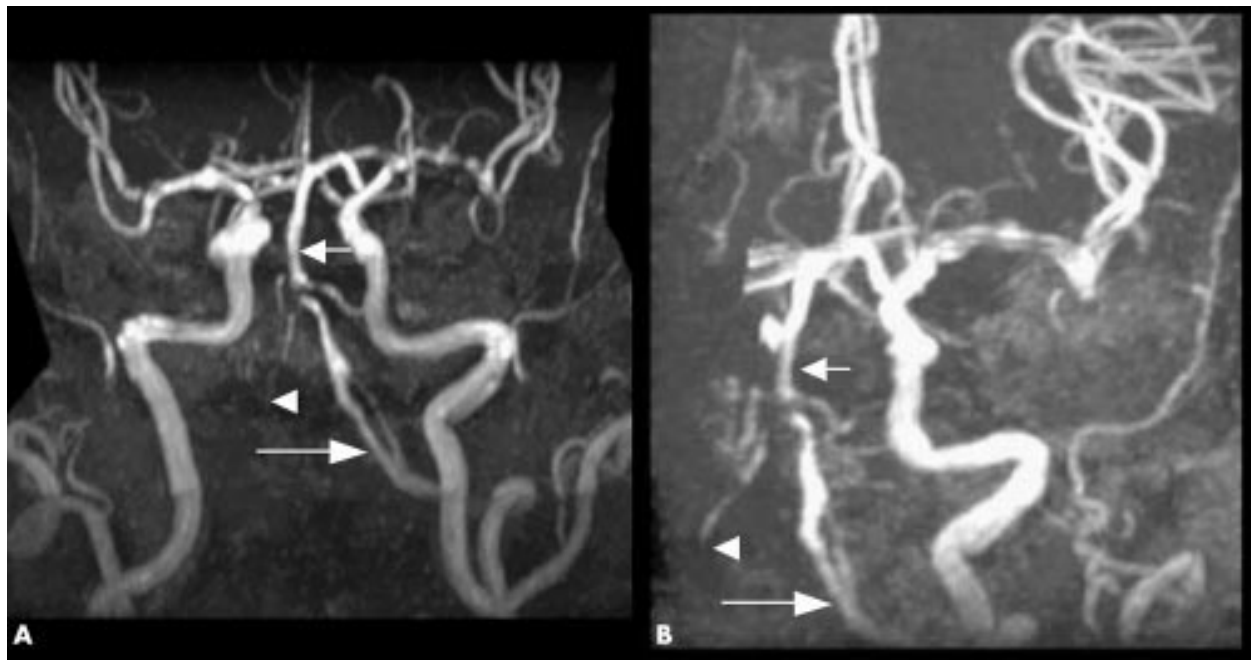


Figure 2 Frontal (A) and lateral (B) views of cerebral magnetic resonance angiogram show a severe stenosis at the junction of the left vertebral artery (long arrow) and the basilar artery (short arrow). The right distal vertebral artery is also occluded (arrowhead).

treponemal serology (Venereal Disease Research Laboratory test) were unremarkable. Audiometric testing, performed on admission, showed moderate sensorineural hearing loss of 55 dB with 90% speech discrimination on the left side and 45 dB with 95% speech discrimination on the right (fig 1). Stapedial reflex thresholds at multiple frequencies were normal on both sides. Normal waveform responses were evoked bilaterally on brain stem auditory evoked potentials. Electronystagmography showed hypoexcitability (more than 22% asymmetry in our laboratory) to caloric stimulation on the left side. There were no abnormalities in saccades, pursuit, or optokinetic nystagmus. Magnetic resonance imaging of the brain, including diffusion images, was normal. Magnetic resonance angiography showed severe stenosis of the middle third of the basilar artery and blockage of the right distal vertebral artery (fig 2). A transthoracic echocardiogram and an electrocardiogram showed no abnormalities. The patient was treated acutely with a platelet aggregation inhibitor. Fifteen days later, a follow up pure tone audiogram documented notable improvement on both sides to 35 dB pure tone average (fig 1). At last follow up, the patient had no specific complaints and has had no further neurological attacks.

DISCUSSION

The differential diagnosis of bilateral sudden sensorineural hearing loss includes trauma, autoimmune inner ear disease, meningitis, syphilis, HIV, and ototoxic drugs.⁸ Sudden bilateral deafness is also associated with VBI.¹⁻⁷ Our patient developed sudden onset of symptoms and had definite vascular risk factors with longstanding hypertension and diabetes mellitus. Furthermore, the magnetic resonance angiogram showed severe stenosis of the middle third of the basilar artery close to the origin of the AICA. She also had two episodes of transient cochleovestibular symptoms typical of transient ischaemic attack before the major bilateral sudden deafness. Extensive blood tests with erythrocyte sedimentation rate, antinuclear antibody, Venereal Disease Research Laboratory test, HIV, and C reactive protein were normal.

Sudden bilateral deafness and VBI

There have been several reports of bilateral deafness due to VBI.¹⁻⁷ However, most previous reports¹⁻⁶ of bilateral deafness due to VBI have also described associated neurological

symptoms such as mental change, motor weakness, sensory loss, or cranial nerve palsy. Brain magnetic resonance images characteristically showed hyperintensities involving the brain stem, cerebellum, or both. In 1981, Stephan *et al*¹ described a patient with sudden bilateral deafness caused by basilar artery occlusion who later developed bilateral weakness and died 10 hours after the onset. In 1993, Huang *et al*² described seven patients with sudden bilateral deafness caused by VBI, all of whom had brain stem signs including facial palsy, diplopia, swallowing difficulty, and bilateral weakness. Brain computed tomography in six patients showed multiple hypodense lesions in brain stem and cerebellum. The report did not mention audiometric data, limiting localisation. In 1995, Buttner *et al*⁷ reported on a patient who had a bilateral vestibulocochlear loss due to VBI without any other neurological symptoms or sign, as in our case. In comparison with our patient, however, the patient described by Buttner *et al* had continuous prolonged vertigo and bilateral canal paresis on caloric stimulation. They did not conduct specialised auditory testing to localise the site of hearing loss. In 1998, Deplanque *et al*³ reported on a patient with unilateral lateral inferior pontine infarction who presented with bilateral deafness, facial palsy, Horner syndrome, and ataxia. In 2000, Sunose *et al*⁴ described a patient with bilateral cerebellar infarction who had acute onset of hearing impairment bilaterally, dizziness, oculomotor abnormalities, and numbness in the right extremity. In 2001, Lee *et al*⁵ described a patient who had a bilateral sudden deafness as a prodrome of pontocerebellar infarction in the territory of the AICA. In 2002, Toyoda *et al*⁶ reported on two patients with basilar artery occlusion who had bilateral deafness as a warning sign of impending stroke. Both patients died of extensive infarction in the brain stem and cerebellum. All of these patients except one⁷ had multiple neurological signs in addition to bilateral hearing loss.

Localisation of sudden bilateral deafness

Without pathological confirmation, it is impossible to determine precisely the locus of injury responsible for hearing loss in our patient. However, in our patient, speech discrimination and stapedial reflex testing were normal, as were brain stem auditory evoked potentials, indicating a cochlear site of lesion.⁹

Predominantly low frequency hearing loss on the pure tone audiogram suggests that the vascular insufficiency involved small arterioles within the apex of the cochlea, which is considered to be a particularly vulnerable site to ischaemia.¹⁰

Mechanism of sudden bilateral deafness

Strokes in the territory of the AICA are usually associated with basilar occlusive disease.¹¹ Because the brain magnetic resonance angiogram in our patient documented a severe stenosis of the basilar artery close to the origin the AICA, it is possible that an atheromatous plaque within the basilar artery extended into the AICA ostia. By this mechanism, decreased blood flow in both AICA may selectively damage the inner ear because of its high energy requirements and the lack of collaterals.^{5, 12} It is also possible that the hearing loss resulted from emboli originating in the basilar or vertebral arteries, but the bilateral simultaneous onset would be atypical. Previous reports^{10, 13} of experimental transient occlusion of the internal auditory artery have shown that the cochlea is more sensitive to ischaemia than the vestibular labyrinth. We speculate that the prominence of hearing symptoms and the absence of the other neurological symptoms or signs are best explained by the selective vulnerability of the cochlea to ischaemia.

Clinical relevance

We have previously reported hearing loss as a prodrome of AICA infarction. Together, these reports highlight the importance of hearing loss as either a sole manifestation or a warning⁵ of impending brain stem infarction. Clinicians should be aware of the possibility of VBI in patients with bilateral sudden deafness, even when brain stem or cerebellar signs are absent.

Authors' affiliations

*H Lee, H A Yi, Department of Neurology, Keimyung University School of Medicine, Daegu, South Korea

R W Baloh, Department of Neurology, Division of Surgery (Head and Neck), UCLA School of Medicine, Los Angeles, California, USA

*Also the Brain Research Institute, Keimyung University School of Medicine, Daegu, South Korea

Correspondence to: Dr H Lee, Department of Neurology, School of Medicine, Keimyung University, 194 Dongsan dong, Daegu, 700-712 South Korea; hlee@dsmc.or.kr

Received 5 August 2002
In revised form 25 October 2002
Accepted 25 October 2002

REFERENCES

- 1 **Stephan H**, Wappenschmidt J, Kiefer H. Occlusion of the basilar artery. *Neurosurg Rev* 1981;**4**:41-52.
- 2 **Huang MH**, Huang CC, Ryu SJ, *et al*. Sudden bilateral hearing impairment in vertebrobasilar occlusive disease. *Stroke* 1993;**24**:132-7.
- 3 **Deplanque D**, Godefroy D, Guerouaou D, *et al*. Sudden bilateral deafness: lateral inferior pontine infarction. *J Neural Neurosurg Psychiatry* 1998;**64**:817-8.
- 4 **Sunose H**, Toshima M, Mitani S, *et al*. Sudden bilateral hearing loss and dizziness occurred with cerebellar infarction. *Otolaryngol Head Neck Surg* 2000;**122**:146-7.
- 5 **Lee H**, Whitman GT, Lim JG, *et al*. Bilateral sudden deafness as a prodrome of anterior inferior cerebellar artery infarction. *Arch Neurol* 2001;**58**:1287-9.
- 6 **Toyoda K**, Hirano T, Kumai Y, *et al*. Bilateral deafness as a prodromal symptom of basilar artery occlusion. *J Neural Sci* 2002;**193**:147-50.
- 7 **Buttner U**, Ott M, Helmchen CH, *et al*. Bilateral loss of eighth nerve function as the only clinical sign of vertebrobasilar dolichoectasia. *J Vestib Res* 1995;**5**:47-51.
- 8 **Fetterman BL**, Luxford WM, Saunders JE. Sudden bilateral sensorineural hearing loss. *Laryngoscope* 1996;**106**:1347-50.
- 9 **Baloh RW**. *Dizziness, hearing loss, and tinnitus*. New York: Oxford, 1988:89-105.
- 10 **Perman HB**, Kimura RS, Fernandez C. Experiments on temporal obstruction of the internal auditory artery. *Laryngoscope* 1959;**69**:591-613.
- 11 **Amarenco P**, Rosengart A, DeWitt LD, *et al*. Anterior inferior cerebellar artery infarcts. Mechanisms and clinical features. *Arch Neurol* 1993;**50**:154-61.
- 12 **Grad A**, Baloh RW. Vertigo of vascular origin: clinical and electronystagmographic features in 84 cases. *Arch Neurol* 1989;**46**:281-4.
- 13 **Levine RA**, Bu-Saba N, Brown MC. Laser-Doppler measurements and electrocochleography during ischaemia of the guinea pig cochlea: implication for hearing preservation acoustic neuroma surgery. *Ann Otol Rhinol Laryngol* 1993;**102**:127-36.