
RUPTURE OF MIDDLE CEREBRAL ARTERY ANEURYSM IN A NEONATE

CASE REPORT AND REVIEW OF THE LITERATURE

Falah Maroun, M.D.,* Keyna Squarey, M.D.,* Jacob Jacob, M.D.,* Gerald Murray, M.D.,* Benvon Cramer, M.D.,* Jane Barron, M.D.,* and Bryce Weir, M.D.**

*Departments of Neurosurgery, Neurology, Pathology and Radiology, Health Sciences Centre, St. John's, NF, Canada; and **Section of Neurosurgery, University of Chicago, Chicago, Illinois.

Maroun F, Squarey K, Jacob J, Murray G, Cramer B, Barron J, Weir B. Rupture of middle cerebral artery aneurysm in a neonate: case report and review of the literature. *Surg Neurol* 2003;59:114-9.

BACKGROUND

Intracranial hemorrhage because of rupture of a cerebral aneurysm is extremely rare in the neonatal period. Delayed diagnosis contributes to high mortality and morbidity.

CASE DESCRIPTION

The authors report an extremely rare case of a middle cerebral artery aneurysm diagnosed and treated shortly after birth. Extensive review of the literature is presented. The patient died 4 years after surgery. © 2003 Elsevier Science Inc.

KEY WORDS

Cerebral aneurysm, neonate.

Intracranial arterial aneurysms in the pediatric age group are rare, comprising 0.5 to 4.6% of all aneurysms [26]. They are extremely uncommon in early childhood [3], and even more infrequent in the neonatal period [3,10]. Morbidity and mortality are high because of delayed diagnosis and treatment.

In addition to clinical relevance, the study of cerebral aneurysms identified in early childhood may help our understanding of pathogenesis of cerebral aneurysms in all age groups, as the etiopathogenesis of these lesions remains unclear.

Defining the neonatal period as the first 4 weeks of postnatal life, we identified 14 cases of intracranial aneurysm in the literature. We review the liter-

ature and describe a ruptured aneurysm of the distal middle cerebral artery (MCA) in a neonate.

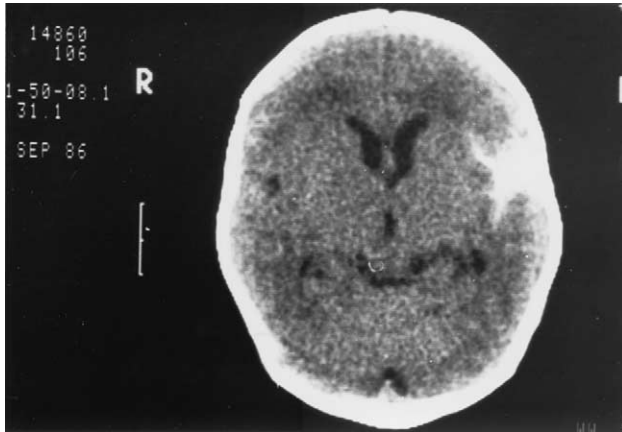
CASE REPORT

A 3-day-old newborn male presented with repeated bouts of focal seizures of the right face, arm, and leg. He was born spontaneously, at term (birth weight 3030 g) after an uneventful gestation. The second stage of delivery was short, but there was well controlled delivery of the head. He had a triple-twisted cord, but cried within 30 seconds and appeared well, with Apgars of 7¹ and 9⁵, respectively. There was no evidence of sepsis during gestation or delivery. Postnatal course was normal until the second day of life, when the infant was noted to be irritable, cyanotic, and had clonic seizures of his right hand.

He was transferred to a regional hospital, where partial motor seizures involving the right arm progressing to a generalized convulsion lasting 10 minutes occurred. The seizure was successfully treated with IV phenobarbital. A septic work-up was undertaken and the patient was treated prophylactically with antibiotics. Lumbar puncture revealed blood-stained cerebrospinal fluid (CSF).

The infant was transferred to the Provincial tertiary care pediatric center. He appeared irritable but was otherwise well; head circumference was 35.25 cm and the anterior fontanel was not bulging; weight was 3240 g. Neurologic examination revealed normal motor function in all extremities; reflexes were normal and symmetrical. General physical examination was within normal limits. Pe-

Address reprint requests to: F.B. Maroun, Room 5202, Health Sciences Centre, 300 Prince Philip Drive, St. John's, NF, Canada, A1B 3V6
Received December 3, 2001; accepted October 3, 2002.



1 CT scan (3rd day of life) showing subarachnoid hemorrhage predominantly in the left Sylvian fissure.

ripheral blood hemoglobin concentration was 200 g/liter, and white blood cell count was 95000/mm³.

Cranial sonography, followed by computed tomography (CT), on the third day of life, showed early ischemia in the left cerebral hemisphere, in the territory of the MCA. There was also evidence of subarachnoid hemorrhage (SAH), with predominance of blood in the left Sylvian fissure (Figure 1). Ultrasound examination revealed a rounded hypodense (relative to the hemorrhage) lesion, highly suggestive of an aneurysm.

During the patient's 3-week hospital stay, seizures were well controlled with anticonvulsants and he was seizure free after the first 2 days of admission. He was discharged home without any medication.

A week later, the infant presented with recurrent convulsive seizures and apneic episodes. Skin was pale, gray, and mottled. Theophylline, anticonvulsants and antibiotics were administered after blood cultures were obtained. He required endotracheal intubation, and continuous positive pressure ventilation.

On examination, the infant's weight and head circumference were 3980 g and 37.5 cm, respectively. The anterior fontanel was full, but not bulging. Suck reflex was weak; the left pupil was dilated and non-reactive to light. Hypertonia, particularly in the upper extremities, and opisthotonic posturing of the trunk were noted. Reflexes were brisk bilaterally. The remainder of the general and neurologic examination was negative.

Cranial ultrasound examination showed extension of the hemorrhage in the left cerebral hemisphere with mass effect and enlargement of the aneurysm. Cranial CT confirmed the extension of

hemorrhage and infarction in the left MCA territory (Figure 2). Cerebral angiography showed a large aneurysm of the left distal middle cerebral artery (Figures 3 and 4). Vasospasm was evident.

At surgery, it was necessary to remove most of the left cerebral hemisphere, as it was swollen, hemorrhagic, and necrotic. During the process of removal, a branch of the MCA had to be clipped. The MCA and distal branches were in marked spasm.

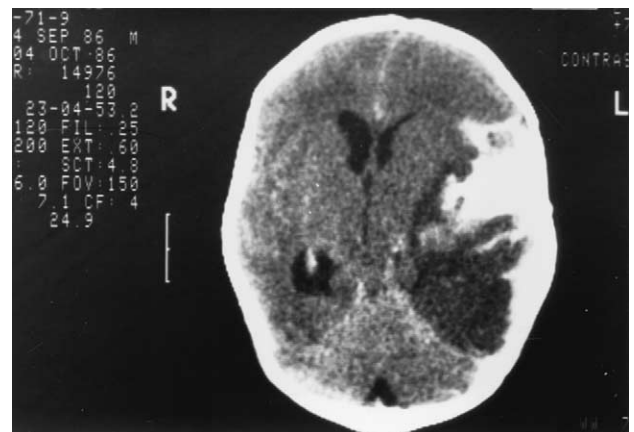
The aneurysm was successfully clipped and excised. The aneurysm measured 1 cm in length and had a narrow base, measuring 3 to 4 mm.

The wall was thin, similar to that of an aneurysm in an adult. There was vigorous blood loss during the procedure and the patient suffered an episode of electromechanical myocardial dissociation; cardiac resuscitation was successful. Postoperative recovery was uneventful.

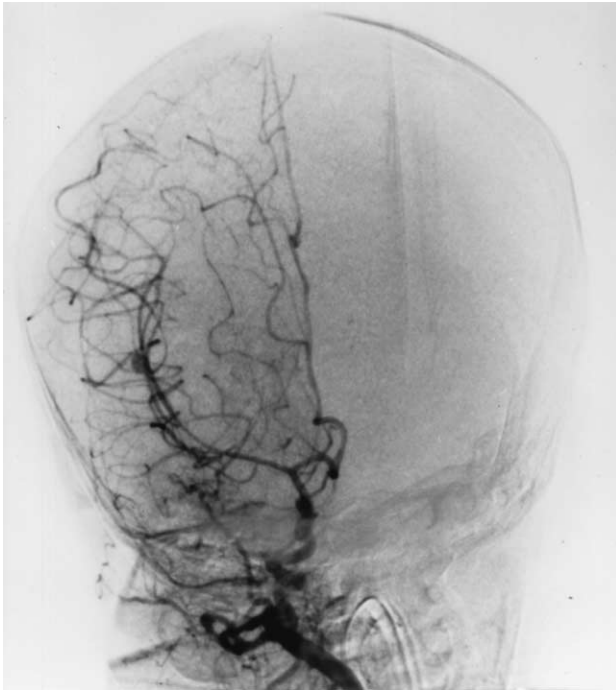
Bilateral third nerve paresis and spastic tetraparesis persisted after surgery; the infant remained severely disabled with marked spasticity of all 4 limbs, and was in a vegetative state until he died 4 years later.

PATHOLOGY

The surgical specimen consisted of blood clot and temporal lobe fragments, and one abnormal vessel. Representative pieces were embedded in paraffin and serial sections were made. H & E stains were done. The sections taken from the aneurysm, that is, the cap portion, showed a thin-walled vessel consisting mostly of adventitial type connective tissue. In some sections, the wall was extremely disrupted. Most of the aneurysm was filled with old and new clot with obvious laminations in one portion. The other specimens were either blood clot and/or pieces of cortical tissue that showed the



2 CT scan (7th day of life) extension of hemorrhage with infarction of the MCA territory.



3 Anteroposterior cerebral angiogram: distal MCA aneurysm.

presence of numerous hemosiderin laden macrophages.

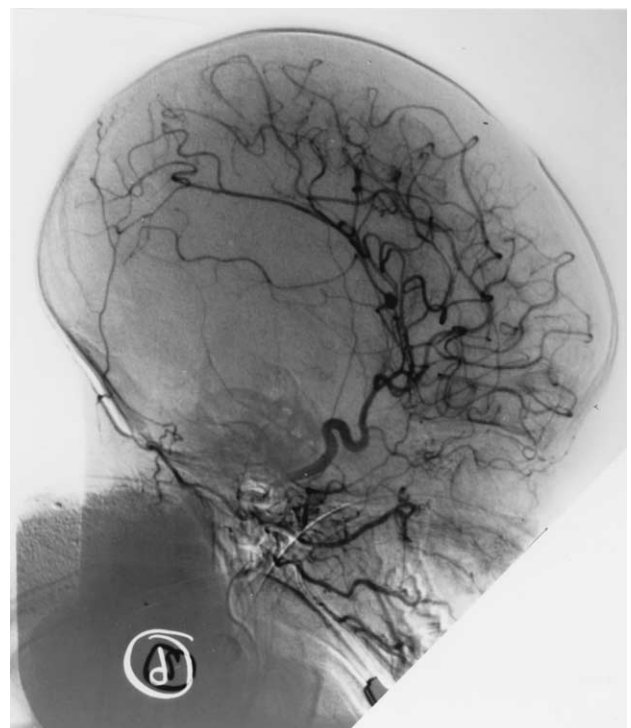DISCUSSION

Intracranial aneurysms in the pediatric population account for only 0.5 to 4.6% of all aneurysms [26]. McDonald and Korb [17] reviewed 1125 cases of saccular cerebral aneurysms; 17 (1.5%) occurred in children, only one of whom was younger than 18 months. Laitinen [13] reported a similar childhood incidence of 1.3% in 688 patients. Patel and Richardson [22] reviewed 3000 cases of SAH including 58 cases in patients under 19 years of age, the youngest was 8 years old. In the Cooperative Study [16], only one of 2627 cases reviewed was in the 0 to 4 year age group. Nishio et al [21] reviewed 66 cases of cerebral aneurysms in children under 2 years of age.

Aneurysms in the neonate are even rarer. Ferrante et al [3] found only 8 cases in the first 4 weeks of life. In our review of the literature, we found 15 cases, including our own, of cerebral aneurysms in the neonatal period (Table 1). Two other cases were reported in a 42 and 45 mm embryo [1]. Also, not included in the neonatal data, is a case reported by Thompson and Pridham [30] of an infant female who developed ophthalmoplegia and quadriplegia at 2 weeks of age. Initial LP was clear. However,

diagnosis of an internal carotid artery aneurysm was made when the child was 9 months old. Grode et al [7] reported a case of a young female whose symptoms were lethargy, vomiting, and pallor on the eighth day of life. SAH was not identified until the child was about 5 weeks old. Angiography, at 8 weeks of age, demonstrated a left MCA aneurysm. They concluded it was a congenital saccular aneurysm.

Differences between intracranial aneurysms in children as compared with adults have been extensively discussed. In early childhood aneurysms differ in their sex predominance, location, and size at presentation. Of the 15 cases included in this review, 8 were male, 6 were female, and the sex of 1 case was unknown; thus there is a male predominance, with a ratio of 4:3. The aneurysm site was the middle cerebral artery (6/15 or 40%) or the vertebrobasilar system (5/15 or 33%). Three aneurysms were found on the internal carotid artery, anterior communicating artery, and anterior cerebral artery. The incidence of large (1.0-2.5 cm) or giant (>2.5 cm) aneurysms was 10/15 or 67%. Presenting symptoms included irritability, vomiting, seizures, SAH, and coma. Subarachnoid hemorrhage is the most common presentation. These findings are consistent with previous studies on early childhood aneurysms.



4 Lateral cerebral angiogram: diffuse cerebral spasm with aneurysm.

1 Clinical Features of Neonatal Cerebral Aneurysms

REFERENCE	AGE	SEX	SITE (SIZE)	PRESENTATION	OUTCOME
Newcomb and Munns (1949)	23 days	M	Circle of Willis (dna)*	SAH after minor head trauma	No surgery. Died.
Jones and Shearburn (1961)	64 hr.	M	PCAPComma (2 mm)	Cyanotic at birth, SAH.	No surgery. Died.
Wierdlis et al (1965)	4 wk.	F	MCA (large)	Irritable, SZ, SAH coma	Neck clipped. Did well.
Pickering et al (1970)	Newborn	dna	MCA (dna)*	SAH	No surgery. Did well.
Lee et al (1978)	1 month	M	d-PICA (2.5 cm)	Apnea, cyanosis, SAH, SZ	No surgery. Died.
Lipper et al (1978)	13 days	F	BA (3 cm)	SZ, SAH	No surgery. Died.
Hungerford et al (1981)	10 days	F	ICA (dna)*	SAH	No surgery. Died.
Shimauchi et al (1989)	1 month	F	d-MCA (1.5 cm)	Irritable, vomiting, SAH	Excision. Did well.
Kuchelmeister et al (1993)	19 days	F	MCA (10 mm) Fusiform	SAH, hematoma	Parent artery clipped. Did well.
Hosotani et al (1995)	4 days	M	AComma (10 mm)	SZ, SAH	No Surgery. Did well.
Thrush and Mirano (1988)	24 days	M	d-PICA (large)	SAH	Parent artery clipped. Did well.
Tan et al (1998)	1 month	F	d-MCA (6 mm)	Hematoma on CT	Clipped. Did well.
Present Case	11 days	M	ACA (10 mm) Fusiform	SAH, IVH	Unsuccessfully clipped. Did well.
	3 days	M	d-MCA (1 cm)	Irritable, cyanotic, SZ, SAH	Clipped & excised.

*dna = data not available.

One of the striking findings from Table 1 is the low operative mortality. An exception was the case presented by Tan et al [29]. They described an 11-day-old infant with an anterior cerebral artery aneurysm, who died 2 weeks after an unsuccessful attempt at clipping the aneurysm. Further, with the exception of one case, mortality in patients who were not treated surgically was high. Piatt and Clunie [23] reported a male neonate with a superior cerebellar artery aneurysm who was managed conservatively and did well. In our case, the patient was initially managed conservatively. However, he presented again a week later, at which time cranial ultrasound and CT showed extension of hemorrhage and infarction in the left cerebral hemisphere. This might have been prevented if the clot had been evacuated and the aneurysm clipped earlier.

The prognosis for ruptured aneurysms in the early neonatal period is poor, despite the greater capacity of the infantile nervous system for recovery. Early diagnosis enhances favorable prognosis. Therefore, surgeons should have a high index of suspicion and perform appropriate investigations when an infant presents with symptoms of increasing irritability, vomiting, and/or seizures, and an LP yields bloody CSF. The most important first step in diagnosis is a cranial ultrasound. In our case, initial ultrasound investigation at 3 days of age revealed hemorrhage in the left Sylvian fissure and a rounded area suggestive of an aneurysm. Repeat examination carried out at 2½ weeks of age showed extension of the hemorrhage and enlargement of the aneurysm. Our delay in the management of this particular patient was multifactorial. He was being treated in the Neonatal Unit and we were only asked to see him a week later. Because of the fact that there was early ischemia indicating cerebrovascular spasm, we elected to wait before doing the angiogram and surgical clipping. However, we feel now that the treatment should have been much quicker and clipping should have been conducted earlier. Cranial sonography is a noninvasive technique that can be repeated without sedation or risk of radiation. Ismail et al [10] report that it is an invaluable diagnostic tool that can demonstrate the location and size of an intracranial hemorrhage and delineate the size or distortion of the ventricular system, as well as suggest the presence of an aneurysm. However, it may miss superficial AVMs or small aneurysms around the circle of Willis.

CT, magnetic resonance imaging (MRI), and magnetic resonance angiography (MRA) are also useful in the diagnosis of intracranial aneurysms in the neonate. CT is very sensitive for acute hemorrhage,

but is not specific enough to identify the cause of the hemorrhage. It may show a focal hyperdense mass with or without enhancement in addition to the hemorrhage. MRI demonstrates the hemorrhage and may show a focal mass with a different signal than the surrounding hemorrhage, with or without flow-void or enhancement. MRA correlates well with conventional angiograms and may eventually replace it. MRA can demonstrate aneurysms as small as 3 mm [29]. A major role of MRA in the future may be in screening patients at high risk for developing aneurysms (e.g., those with a family history of aneurysms). Cerebral angiography carries significant risk in the neonate, but remains the gold standard for preoperative imaging.

A major controversy concerning etiopathogenesis is whether cerebral aneurysms are congenital or acquired. In 1930, Forbus [4] proposed that aneurysms are acquired lesions, arising from a combination of a congenital medial defect of the arterial wall and degeneration of the internal elastic lamina. He suggested this theory when he observed a medial defect at the apex of cerebral artery bifurcations and found that an aneurysm appeared to arise as a bulging through the medial defect. Since then, much conflicting evidence has been presented. Glynn [6] has shown that arteries can withstand intraluminal pressures of 400 to 600 mm Hg without showing any local bulging of the intima into the space lacking the media. Furthermore, medial defects are very common in comparison to the relatively small number of cerebral aneurysms in the general population [2,6,26]. Medial defects also increase with age.

The site of medial defects and aneurysms differ. Medial defects are also found in species that do not develop aneurysms. Thus, medial defects may not be congenital in origin nor represent Forbus' proposed "locus minoris resistentiae."

A recent study carried out by Futami et al [5] in rats showed a disparity between the location of the aneurysm and medial defects. They proposed that the intimal pad is the primary cause of aneurysms, with the medial defect a factor contributing to the degeneration of the internal elastic lamina. The authors postulate that the presence of the intimal pad may cause aneurysmal development by causing stresses in the wall at that point secondary to muscle cells in the pad and media acting in different directions, by producing stagnation of blood flow behind the intimal pad affecting nutrition of the wall, or by causing turbulence and shear stress in that area with the production of endothelial substances that cause degeneration of the vessel wall. Further work on the role of intimal pads in aneu-

rysm formation will likely be a topic of future research.

Other authors postulate that cerebral aneurysms are congenital in nature. Bremer [1] suggested that aneurysms may be remnants of fetal cerebral plexuses. He thought that during development, the proximal portion of such plexuses enlarges, while the distal segments degenerate and thus produce aneurysmal sacs. Further support for congenital formation of aneurysms arises from the occurrence in young persons with a higher frequency occurring in the first 2 years of life [3], familial occurrence [11], association with other cerebral and vascular congenital anomalies, and variations in the Circle of Willis. Furthermore, limited data from light microscopy studies, including our case, has shown fragmentation or absence of both the internal elastic lamina and smooth muscle within the aneurysmal sac. These features are similar to those seen in saccular aneurysms of the adult.

Stehbens [26,27] has refuted the evidence suggesting a primary congenital mechanism as the cause of pediatric aneurysms. He stated that true saccular aneurysms in childhood are rare, and that the presence of a few cases does not negate the acquired degenerative nature of most cases. He further stated that the presence of so-called vestigial vessels has not been demonstrated, and that the presence of a few familial cases is to be expected given the frequency of aneurysms in the population. Also, variations in the Circle of Willis are frequently seen in other animals, whereas aneurysms are not [32].

Nishio et al [21] emphasized the role of hemodynamic factors in the development of aneurysms in adults and infants. In adults, hemodynamic stress against a background of degenerative arterial wall changes is proposed to be the underlying cause of aneurysms. In infants, they postulate that the embryonic development of cerebral vessels in association with hemodynamic factors influences the development of aneurysms. The MCA appears earlier than other vessels, supplies more blood flow to the developing cerebral hemispheres, and is exposed to the hemodynamic stress of direct blood flow for a longer period of time than other vessels. This may be an explanation for the common occurrence of MCA aneurysms in neonates. Piatt and Clunie [23] have suggested that the more common occurrence of posterior circulation aneurysms in neonates is attributable to trauma, with compression of vessels against the free edge of the tentorium during the birth process. Vascular damage later gives rise to aneurysm formation.

In our patient, the aneurysm was considered to

be congenital because of the occurrence of a single large distal MCA aneurysm that by history, had been present since birth. This would make an acquired pathogenesis extremely unlikely. We recommend the routine use of cranial ultrasonography if a cerebral aneurysm is suspected in a neonate, with early clot evacuation and clipping of the aneurysm.

REFERENCES

- Bremer JL. Congenital aneurysms of cerebral arteries: embryologic study. *Arch Neurol Psychiatry* 1943;35:819.
- Carmichael R. Gross defects in the muscular and elastic coats of the larger cerebral arteries. *J Pathol Bact* 1945;57:345-51.
- Ferrante L, Fortuna A, Celli P, Santoro A, Fraioli B. Intracranial arterial aneurysms in early childhood. *Surg Neurol* 1988;29:39-56.
- Forbus WD. On the origin of miliary aneurysms of the superficial cerebral arteries. *Bull John Hopkins Hosp* 1930;47:239-84.
- Futami K, Yamashita J, Higashi S. Do cerebral aneurysms originate at the site of medial defects? Microscopic examinations of experimental aneurysms at the fenestration of the anterior cerebral artery in rats. *Surg Neurol* 1998;50:141-6.
- Glynn LE. Medial defects in the circle of Willis and their relation to aneurysm formation. *J Pathol Bact* 1940;51:213-22.
- Grode ML, Saunders M, Carton C. Subarachnoid hemorrhage secondary to ruptured aneurysms in infants: report of two cases. *J Neurosurg* 1975;49:898-902.
- Hosotani K, Tokuriki Y, Takebe Y, Kawaguchi K, Tsuji A, Kubota T. Ruptured aneurysm of the distal posterior inferior cerebellar artery in a neonate. *Neurol Med China (Tokyo)* 1995;35:892-95.
- Hungerford GD, Marzluff JM, Kempe LG. Cerebral arterial aneurysm in a neonate. *Neuroradiology* 1981;21:107-19.
- Ismail H, Tekko K, Enrique CG, Venture YRA. Spontaneous intracranial hemorrhage of structural origin during the first year of life. *Child Nerv Syst* 1997;13:154-65.
- Jones RK, Shearburn EW. Intracranial aneurysm in a four week old infant: diagnosis by angiography and successful operation. *J Neurosurg* 1961;18:122-4.
- Kuchelmeister K, Schulz R, Bergmann M, Schwuchow R, Vollmer E. A probably familial saccular aneurysm of the anterior communicating artery in a neonate. *Child Nerv Syst* 1993;9:302-305.
- Laitinen L. Arteriella aneurysm med. Subarachnoidal blodming Hosdam. *Nord Med* 1964;71:329-33.
- Lee YJ, Kandall SR, Gahli VS. Intracerebral arterial aneurysm in a newborn. *Arch Neurol* 1978;35:171-2.
- Lippers S, Morgan D, Krigman MR, Staabe V. Congenital saccular aneurysm in a 19 day old neonate: case report and review of the literature. *Surg Neurol* 1978;10:161-5.
- Locksley HB. Report on the cooperative study of intracranial aneurysms and subarachnoid hemorrhage. Section V, Part 7. Natural history of subarachnoid hemorrhage, intracranial aneurysms and arteriovenous malformations. Based on 6368 cases in the cooperative study. *J Neurosurg* 1966;25:219-39.
- McDonald CA, Korb M. Intracranial aneurysms. *Arch Neurol Psych* 1939;42:298-328.
- Meyer FB, Thoralf M, Sundt T, et al. Cerebral aneurysms in childhood and adolescence. *J Neurosurg* 1989;70:420-5.
- Meyer FB, Reeves AL. Pediatric and adolescent aneurysms. *Contemp Neurosurg* 1990;12(5):1-6.
- Newcomb AL, Munns GF. Rupture of aneurysm of the circle of Willis in the newborn. *Pediatrics* 1949;3:769.
- Nishio A, Sakaguchi M, Murata K, et al. Anterior communicating artery aneurysm in early childhood: report of a Case. *Surg Neurol* 1991;35:224-9.
- Patel AN, Richardson AE. Ruptured intracranial aneurysms in the first two decades of life: a study of 58 patients. *J Neurosurg* 1971;35:571-6.
- Piatt JH, Clunie DA. Intracranial arterial aneurysm due to birth trauma: case report. *J Neurosurg* 1992;77:799-803.
- Pickering LK, Hogan GR, Gilbert EF. Aneurysm of the posterior inferior cerebellar artery: rupture in a newborn. *Am J Dis Child* 1970;119:155-8.
- Shimauchi M, Yamakawa Y, Maruoka N, Miyake K. Ruptured intracranial aneurysm in a 19 day old infant. *Neurol Med Chir (Tokyo)* 1989;29:1047-50.
- Stehbens WE. Medial defects of the cerebral arteries of some mammals. *Nature* 1957;179:327-8.
- Stehbens WE. Intracranial arterial aneurysms in pathology of the cerebral blood vessels. St. Louis: CV Mosby, 1972:351-470.
- Stehbens WE. Intracranial berry aneurysms in infancy. *Surg Neurol* 1982;18:58-60.
- Tan MP, McConachie NS, Vloeberghs M. Ruptured fusiform cerebral aneurysm in a neonate. *Child Nerv Syst* 1998;14:467-9.
- Thompson RA, Pribram HF. Infantile cerebral aneurysm associated with ophthalmoplegia and quadripareisis. *Neurol* 1969;19:785-9.
- Thrush AL, Marano GD. Infantile intracranial aneurysm: report of a case and review of the literature. *AJNR* 1988;9:903-6.
- Weir B. Aneurysms affecting the nervous system. Baltimore: Williams & Wilkins, 1987.
- Wierdis T, Giannini V, Laia E. Foetal and neonatal cerebrovascular disease: early results of postmortem carotid angiography. *Panminerva Med* 1965;7:325-38.