

# RECOMBINANT TISSUE PLASMINOGEN ACTIVATOR IN THE TREATMENT OF INTRAVENTRICULAR HEMORRHAGE SECONDARY TO PERIVENTRICULAR ARTERIOVENOUS MALFORMATION BEFORE SURGERY: CASE REPORT

## Krishna Kumar, M.B., M.S.

Department of Surgery, Section of Neurosurgery, Regina General Hospital, University of Saskatchewan, Regina, Saskatchewan, Canada

## Denny D. Demeria, M.D.

Department of Surgery, Section of Neurosurgery, Regina General Hospital, University of Saskatchewan, Regina, Saskatchewan, Canada

## Ashok Verma, M.D.

Department of Radiology, Regina General Hospital, University of Saskatchewan, Regina, Saskatchewan, Canada

## Reprint requests:

K. Kumar, M.B., M.S., F.R.C.S. (C), Medical Office Wing, Regina General Hospital, Regina, SK S4P 0W5, Canada.  
Email: krishna.kumar@rqhealth.ca

Received, September 10, 2002.

Accepted, December 5, 2002.

**OBJECTIVE AND IMPORTANCE:** Intraventricular hemorrhage (IVH) is known to cause acute obstructive hydrocephalus, refractory elevated intracranial pressures (ICPs), and lowered cerebral perfusion pressures, leading to cortical ischemia. Frequent obstruction of external ventricular drains as a result of thrombus is a recurring theme. We present a case of IVH secondary to periventricular arteriovenous malformation (AVM) that was not visible at admission angiography and was treated by intraventricular infusion of recombinant tissue plasminogen activator before surgical intervention.

**CLINICAL PRESENTATION:** An 11-year-old boy presented with acute onset of headache followed by two seizures, loss of consciousness, decerebration, right temporal hematoma, IVH, and acute obstructive hydrocephalus.

**INTERVENTION:** A right external ventricular drain was placed but functioned poorly. ICP could not be controlled by conventional methods. Five milligrams of recombinant tissue plasminogen activator was injected into the ventricular system via the external ventricular drain. This was repeated daily for 4 days. This treatment resulted in progressive improvement in ICP and clinical status. Once the clot partially cleared, magnetic resonance imaging and magnetic resonance angiography suggested the presence of a right periventricular arteriovenous malformation, which was confirmed by angiography and subsequently resected.

**CONCLUSION:** Recombinant tissue plasminogen activator is effective in resolving IVH causing obstructive hydrocephalus and uncontrollable ICP posing a life-threatening situation, secondary to ruptured arteriovenous malformation, before surgical intervention.

**KEY WORDS:** Arteriovenous malformation, Fibrinolysis, Hydrocephalus, Intraventricular hemorrhage, Recombinant tissue plasminogen activator

*Neurosurgery* 52:964-969, 2003

DOI: 10.1227/01.NEU.0000053028.06474.C6

www.neurosurgery-online.com

Intraventricular hemorrhage (IVH) secondary to trauma, ruptured arteriovenous malformation (AVM), or aneurysm carries a grave prognosis (17). These lesions are notorious for causing uncontrollable elevated intracranial pressures (ICPs) and reduced cerebral perfusion pressures (CPPs), leading to ischemia as a result of recurrent obstruction of external ventricular drains (EVDs). This, in turn, is responsible for the high morbidity and mortality of these patients. The literature suggests that in cases of ruptured AVM or aneurysm, intraventricular fibrinolytic therapy should be initiated after the aneurysm or the AVM has been surgically or endovascularly secured. Thus far, there is only one report in the literature of the use of recombinant tissue plasminogen activator (rtPA) when treating an unsecured AVM (13). Moreover, some authors have postulated that rtPA is contraindicated because of the perceived danger of rehemorrhage in these cases (16).

We present a case of a ruptured AVM situated in the right temporal lobe, just medial to the temporal horn. This resulted in IVH filling the lateral, third, and fourth ventricles, which subsequently caused life-threatening obstructive hydrocephalus and raised ICP, which was refractory to conventional therapy. This was treated with intraventricular rtPA to lyse the hematoma, retain the patency of the EVD, and normalize the ICP, which allowed for subsequent visualization and resection of the AVM.

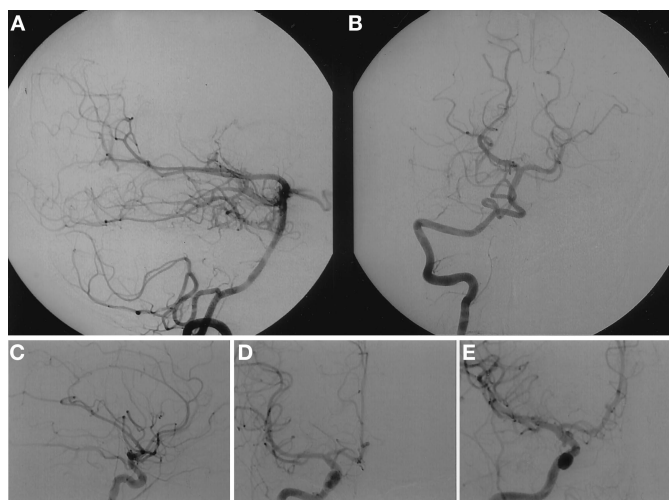
## CASE REPORT

A previously well 11-year-old boy awoke one morning screaming; he complained of severe generalized headache and experienced episodes of vomiting. He became unconscious while en route to the local hospital and sustained two generalized tonicoclonic seizures. He was noted to have anisocoria,

with the right pupil being greater than the left. He was intubated and transferred to our facility for further investigation.

On presentation to our emergency department, the patient was decerebrate, with a Glasgow Coma Scale score of 4. Pupils were now equal and reactive. A fundoscopic examination was within normal limits. Laboratory investigations revealed a normal coagulation profile. A computed tomographic (CT) scan of the head revealed extensive IVH filling the entire ventricular system, with predominance in the right frontal and temporal horns, with a resultant midline shift of 4 mm (Fig. 1). The severity of the IVH was a score of 4 according to the Le Roux classification (10). A pancerebral angiogram demonstrated no evidence of aneurysm, AVM, or arterial spasm (Fig. 2).

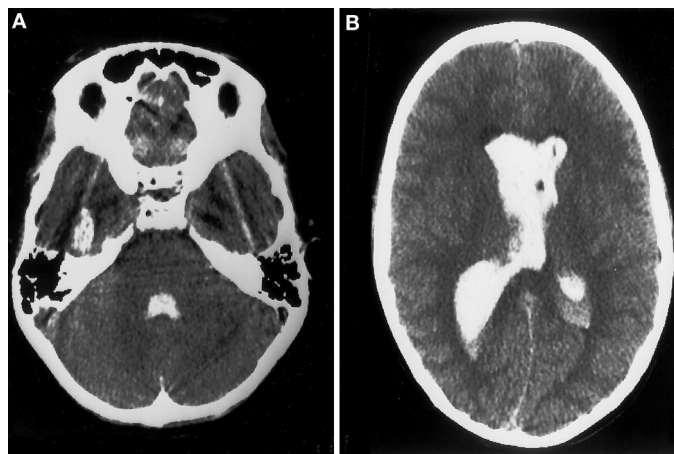
The patient was transferred to the operating room, and an EVD was introduced into the right frontal horn. Thick, bloody cerebrospinal fluid (CSF) began to flow through the ventriculostomy under high pressure. In the intensive care unit, the patient was sedated and paralyzed with atracurium. However, the ICP remained elevated, ranging between 20 and 60 mm Hg, despite frequent administration of mannitol. The EVD required frequent irrigation, because blood products frequently obstructed it. Phenobarbital coma was introduced on Day 3 after admission, because the ICP peaked at 80 mm Hg for 1 hour and the CPP decreased to 30 mm Hg. Unfortunately, the phenobarbital coma failed to control the elevated ICP and precipitated difficulties in maintaining the CPP because of the hypotensive effects of phenobarbital. Therefore, it was discontinued. Despite these efforts, the patient's ICP remained elevated to 40 mm Hg. The CPP decreased to 45 mm Hg. The possibility of intraventricular rtPA was considered as a rescue measure to control the ICP by way of clot lysis. After discussing this with other colleagues, we explained the situation to the family. The risks and benefits of rtPA were presented, and the family agreed to its off-label use. Thus, on Day 4 after admission, 5 mg of rtPA in 5 ml of normal saline



**FIGURE 2.** A and B, right vertebral angiograms obtained at admission (A, lateral view; B, anteroposterior view). C–E, right carotid angiograms obtained at admission (C, lateral view; D, anteroposterior view; E, oblique view). There is no evidence of aneurysm or AVM in either the anterior or posterior circulation.

was administered through the EVD, followed by 1 ml of sterile water. The catheter was clamped for 1 hour and then opened. There was immediate flow of bloodstained CSF. The ICP normalized over the next 12 hours. A CT scan showed a 30% decrease in the amount of intraventricular blood (Fig. 3). However, the ICP began to increase again. Encouraged by the positive response to the initial rtPA administration, we decided to repeat administration of rtPA for the next 3 consecutive days. Each day, before administration of the rtPA, a CT scan was repeated to follow the progress of clot lysis and to ensure that no new hemorrhage occurred as a complication of rtPA administration. After the last dose, a CT scan revealed no midline shift and no ventricular dilation, with only 15% residual blood in the right lateral ventricle compared with the initial CT scan. The ICP could now be controlled by intermittent venting of the EVD. The atracurium was discontinued, and sedation was reduced. By Day 10 after admission, the patient still required EVD venting two to three times per day to maintain the ICP within the normal range. The EVD was removed from the right side and reinserted on the left to prevent the possibility of infection. The patient was extubated on Day 9 after admission. By Day 15 after admission, the ventriculostomy was no longer required and was removed. A repeat CT scan on Day 16 showed normal ventricles, complete resolution of IVH, and a low-density lesion just medial to the right temporal horn, secondary to the hemorrhage that was in this area (Fig. 4). This was the area that was previously obscured by blood products.

To further evaluate the pathogenesis of the hemorrhage, magnetic resonance imaging (MRI) was performed 1 month after admission; to our surprise, the MRI scan revealed flow voids in the right temporal lobe, raising the suspicion of an AVM (Fig. 5). There was also extensive signal abnormality



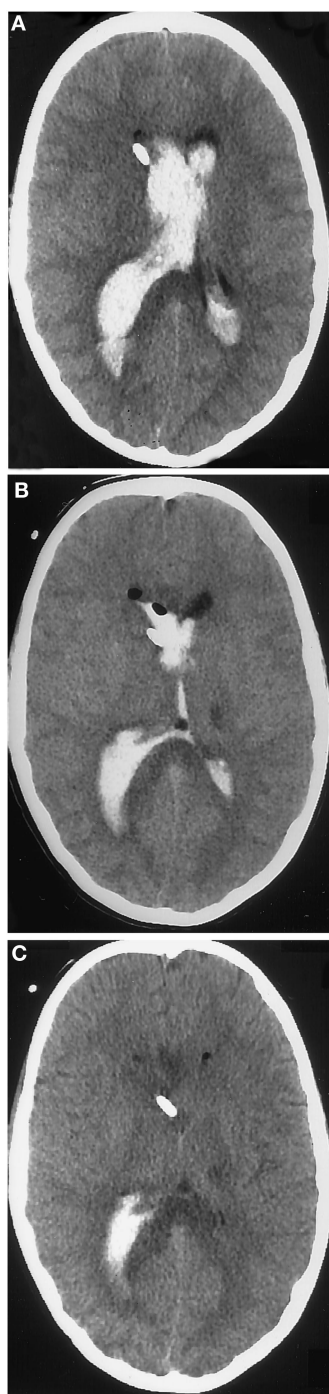**FIGURE 1.** A and B, unenhanced axial CT scans of the head at two different levels obtained at admission to hospital, showing blood filling the lateral, third, and fourth ventricles.

throughout the right temporal lobe. A repeat cerebral angiogram was performed, which confirmed the presence of an AVM in the right temporal lobe, fed by the parietal branches of the right posterior cerebral artery (Fig. 6). The AVM was best visualized on a right vertebral injection. Subsequently, the patient underwent craniotomy, and the AVM was excised. A postoperative angiogram confirmed its total excision (Fig. 7). The patient was discharged 7 days after surgery.

The patient has since been followed up on an outpatient basis, with the most recent review being 6 months after resection of his AVM. On examination, he is alert and oriented. He has a left homonymous hemianopsia, mild left-sided ataxia, and hyperreflexia with bilateral flexor plantar responses. Sensory functions are within normal limits. He has since returned to school; however, he requires personal assistance in language and mathematics.

## DISCUSSION

IVH is a significant complication of hemorrhage regardless of cause and carries a high morbidity and mortality rate (3, 7, 11, 20). This is because of persistently raised ICP, which is difficult to control, despite the use of EVDs, because of recurrent blockage by blood clots occupying the ventricular system. This complication is compounded by the obstruction of the CSF pathways by blood products in the subarachnoid space. A direct correlation exists between persistently elevated ICP, resulting in reduced

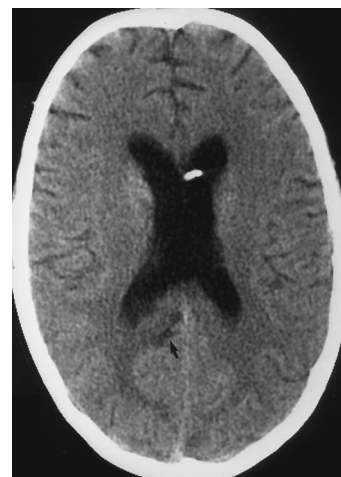

**FIGURE 3.** Unenhanced axial CT scans of the head. A, an EVD in place in the right frontal horn. B, CT scan performed 24 hours after the initial dose of rtPA was administered. C, CT scan after the fourth dose of intraventricular rtPA. There is complete clearing of blood from the frontal horns, with residual blood in the right temporal horn.

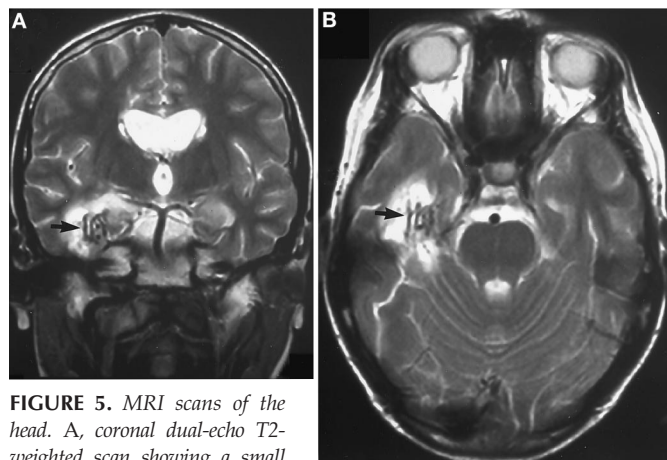
CPP, and cortical ischemia, leading to a poor prognosis (14, 19). Correlation also exists in predicting the extent of ventricular dilation and the amount of intraventricular blood on early CT scans (3, 7, 15). Therefore, the thrust of intervention in IVH is to rapidly eliminate the intraventricular blood, to divert the ventricular CSF, to decrease ventricular dilation, and to normalize the ICP (12). Surgical evacuation of intraventricular blood is hazardous, if not impossible, when most of the ventricular system is filled with blood (12). The EVD usually fails in elimination of the intraventricular blood, because it is frequently obstructed by thrombus; natural clot lysis

has a latency period of 48 to 72 hours after the initial ictus (16). It is during this latency period that extrinsic rtPA could accelerate the natural intrinsic process of clot lysis if injected at an optimum dose. In cases in which the ICP cannot be controlled, the mortality of such patients approaches 78% (17).

Under these desperate circumstances, various fibrinolytic agents have been tested in cases of IVH caused by aneurysmal rupture, trauma, or hypertension. Currently, the contraindications for intraventricular administration of fibrinolytics include unsecured cerebral aneurysms, untreated AVMs, and uncorrected coagulopathies. In most cases, fibrinolytic therapy is initiated only after the aneurysm has been secured (2, 4,



**FIGURE 4.** Unenhanced axial CT scan of the head, obtained at Day 16 after admission. An EVD is seen in the left lateral ventricle. There is complete resolution of the IVH. Low-density lesions are noted just medial to the right temporal lobe (arrow).



**FIGURE 5.** MRI scans of the head. A, coronal dual-echo T2-weighted scan showing a small cluster of flow-void abnormalities in the anteromedial aspect of the right temporal lobe (arrow). B, axial T2-weighted fast field echo revealing similar abnormalities (arrow).

16, 21). There is only one publication describing the use of rtPA for IVH in a case of ruptured AVM before surgical excision (13). The current report may be the second reported case of the successful use of rtPA before excision of an AVM in the treatment of IVH associated with uncontrolled elevated ICP. Our case presents a unique feature regarding how rtPA can help discover the source of IVH when the blood completely obscures the region of the underlying pathology. This report supports the observation by Mayfrank et al. (13) that intraventricular administration of rtPA is not necessarily contraindicated without previous excision of a ruptured AVM. Indeed, the potential lifesaving benefits outweigh the inherent risks of rehemorrhage in such a case.

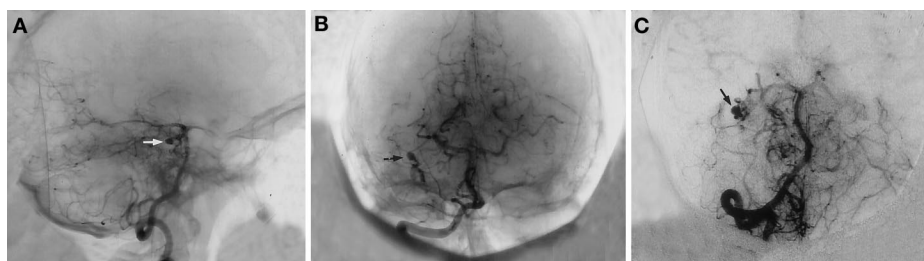
The use of rtPA was considered in this case because of the desperate situation with which we were confronted when our attempts at controlling ICP and maintaining CPP by conventional methods had failed. We initially used EVD, hyperventilation, atracurium, and finally phenobarbital coma. Intraventricular rtPA was chosen in preference to other fibrinolytic agents because of its significantly higher lytic effects on experimental subarachnoid hemorrhages on a per molar basis (9). We chose a dose of 5 mg of rtPA because the literature has demonstrated that doses between 2 and 5 mg have been used without hemorrhagic sequelae (4, 5, 9, 12, 18). The duration of intraventricular fibrinolytic therapy in this case was determined by the guidelines suggested in the literature (1, 6, 12), with specific attention being given to the maintenance of ventricular drainage, CT evidence of intraventricular clot resolution, and the ability to normalize the ICP. In our patient, four doses of rtPA were required to achieve stabilization of his ICP and CPP.

The use of rtPA was considered in this case because of the desperate situation with which we were confronted when our attempts at controlling ICP and maintaining CPP by conventional methods had failed. We initially used EVD, hyperventilation, atracurium, and finally phenobarbital coma. Intraventricular rtPA was chosen in preference to other fibrinolytic agents because of its significantly higher lytic effects on experimental subarachnoid hemorrhages on a per molar basis (9). We chose a dose of 5 mg of rtPA because the literature has demonstrated that doses between 2 and 5 mg have been used without hemorrhagic sequelae (4, 5, 9, 12, 18). The duration of intraventricular fibrinolytic therapy in this case was determined by the guidelines suggested in the literature (1, 6, 12), with specific attention being given to the maintenance of ventricular drainage, CT evidence of intraventricular clot resolution, and the ability to normalize the ICP. In our patient, four doses of rtPA were required to achieve stabilization of his ICP and CPP.

**rtPA Dosage**

The optimal dosage of rtPA remains a controversial issue. Until now, few studies have investigated the dose-effect relationship of rtPA for IVH treatment. Most of the clinical studies (9, 12, 18) report the total milligram dose of rtPA without mentioning the total interventricular clot volume. A review of the literature (4, 5, 17) detailing rtPA treatment and patient outcomes after a dose of 8 mg of rtPA shows that patients with moderate IVH (Graeb score, 5–8) had a lower incidence of good outcome and a higher mortality rate than those with severe IVH (Graeb score, 9–12). It seems that 8 mg was probably an excessive dose for patients with moderate IVH.

Wang et al. (22), in a recent work, addressed the dose-effect relationship of rtPA in the treatment of experimental IVH in the rodent model. After induction of experimental IVH in the left lateral ventricle, either 0.25 to 2 µg of rtPA or Ringer’s saline was injected, and results were compared with those in controls and rats receiving injections of saline solution. Residual intraventricular clot volumes, ventricular volumes, regional cerebral blood flow, and brain histopathology were

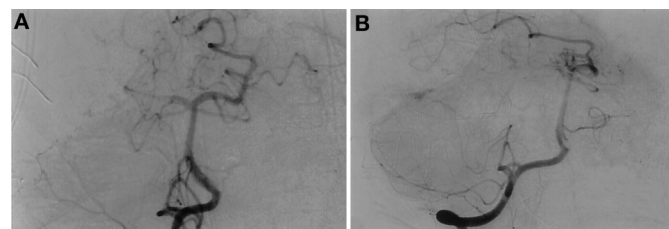


**FIGURE 6.** Right vertebral angiograms (A, lateral view; B, anteroposterior view; C, oblique view) repeated 5 weeks after admission showing the AVM (arrows) in the right temporal lobe fed by branches of the posterior cerebral artery.

examined. Doses of 0.5 to 2 µg of rtPA induced lysis of 80 to 88% of clot at 24 hours. Regional cerebral blood flow, an indicator of possible brain ischemia, was decreased to 37% of baseline value at 24 hours after the buildup of IVH compared with the controls. An analysis of various subgroups revealed that a dose of 0.5 µg of rtPA alleviated this, whereas doses of 1 to 2 µg were associated with a decrease in regional cerebral blood flow by 36 to 40%. Higher doses of rtPA (1–2 µg) induced a greater degree of severe periventricular edema, choroid plexus edema, and bilateral intraventricular leukocytosis. After reviewing the standards of clinical practice and reviewing the literature, Wang et al. (22) concluded that an optimal dosage of 0.1 mg of rtPA per milliliter of blood should be used. This indicates that the dose of rtPA must be carefully determined by the quantity of IVH to efficaciously reduce the mass effect and to avoid unnecessary adverse reactions.

**Role of MRI**

MRI is moderately effective in detection of AVM as a cause of intracerebral hemorrhage or IVH, particularly in a younger population. In an analysis of a patient population less than 20 years old with intracerebral hemorrhage, Griffiths et al. (8) found that AVMs were responsible for 65%, aneurysms accounted for 5%, and no cause was detected for intracerebral hemorrhage or IVH in the remaining 30% of the patients. A review of the literature fails to give any guidelines regarding the stage of clot resolution at which MRI can diagnose the underlying cause of hemorrhage, especially when the admission CT scan and cerebral angiography are negative. The reason for the AVM not being visualized at admission by CT



**FIGURE 7.** Postoperative right vertebral angiograms (A, anteroposterior view; B, lateral view) showing total excision of the AVM.

scan and angiography may have been the compressive effect of the hematoma on the AVM, preventing its visualization. In these circumstances, MRI at admission may also not reveal an underlying AVM because of the absence of flow voids. A few days after ictus and before cerebral angiography is repeated, MRI has the greatest potential in disclosing the underlying cause, as was the case here.

## CONCLUSIONS

This case study illustrates that rtPA can be used without producing hemorrhagic sequelae in cases of IVH secondary to a ruptured AVM before surgical excision, when other conventional methods have failed. Although this is only the second such case reported in the literature, it confirms that the presence of an unsecured AVM is not an absolute contraindication for fibrinolytic therapy, as has been propagated previously. Although the recent study by Wang et al. (22) concludes that a dose of 0.1 mg/ml of rtPA should be used, the specific effect of rtPA alone on neural tissue remains to be identified.

## REFERENCES

- Akdemir H, Selcuklu A, Pasoglu A, Oktem IS, Kavunue I: Treatment of severe intraventricular hemorrhage by intraventricular infusion of urokinase. *Neurosurg Rev* 18:95–100, 1995.
- Azmi-Ghadimi H, Heary RF, Farkas JE, Hunt CD: Use of intraventricular tissue plasminogen activator and Guglielmi detachable coiling for the acute treatment of casted ventricles from cerebral aneurysm hemorrhage: Two technical case reports. *Neurosurgery* 50:421–425, 2002.
- de Weerd AW: The prognosis of intraventricular haemorrhage. *J Neurol* 222:46–51, 1979.
- Findlay JM, Grace MG, Weir BKA: Treatment of intraventricular hemorrhage with tissue plasminogen activator. *Neurosurgery* 32:941–947, 1993.
- Goh KY, Poon WS: Recombinant tissue plasminogen activator for the treatment of spontaneous adult intraventricular hemorrhage. *Surg Neurol* 50:526–532, 1998.
- Grabb PA: Traumatic intraventricular hemorrhage treated with intraventricular recombinant-tissue plasminogen activator: Technical case report. *Neurosurgery* 43:966–969, 1998.
- Graeb DA, Robertson WD, Lapointe JS, Nugent RA, Harrison PB: Computed tomographic diagnosis of intraventricular hemorrhage: Etiology and prognosis. *Radiology* 143:91–96, 1982.
- Griffiths PD, Beveridge CJ, Gholkar A: Angiography in non-traumatic brain hematoma: An analysis of 100 cases. *Acta Radiol* 38:797–802, 1997.
- Kajimoto Y, Ohta T, Kuroiwa T: Comparison of intrathecally administered urokinase, tissue type plasminogen activator, and combination of urokinase and lysine-plasminogen for clot lysis after experimental subarachnoid hemorrhage in dogs. *Neurosurgery* 40:572–577, 1997.
- Le Roux PD, Haglund MM, Newell DW, Grady MS, Winn HR: Intraventricular hemorrhage in blunt head trauma: An analysis of 43 cases. *Neurosurgery* 31:678–685, 1992.
- Little JR, Blomquist GA Jr, Ethier R: Intraventricular haemorrhage in adults. *Surg Neurol* 8:143–149, 1977.
- Mayfrank L, Lippitz B, Groth M, Bertalanffy H, Gilsbach JM: Effect of recombinant tissue plasminogen activator on clot lysis and ventricular dilatation in the treatment of severe intraventricular haemorrhage. *Acta Neurochir (Wien)* 122:32–38, 1993.
- Mayfrank L, Rohde V, Gilsbach JM: Fibrinolytic treatment of intraventricular haemorrhage preceding surgical repair of ruptured aneurysms and arteriovenous malformations. *Br J Neurosurg* 13:128–131, 1999.
- Meyer SA, Kessler DB, Van Heertum RL, Thomas CE, Fink ME, Brannigan T: Effect of intraventricular blood on global cortical perfusion in acute intracerebral hemorrhage: A single-photon emission computed tomographic study. *Ann Neurol* 38:288, 1995 (abstr).

- Mohr G, Ferguson G, Khan M, Malloy D, Watts R, Benoit B, Weir B: Intraventricular haemorrhage from ruptured aneurysm: Retrospective analysis of 91 cases. *J Neurosurg* 58:482–487, 1983.
- Naff NJ: Intraventricular hemorrhage in adults. *Curr Treat Options Neurol* 1:173–178, 1999.
- Nieuwkamp DJ, de Gans K, Rinkel GJ, Algra A: Treatment and outcome of severe intraventricular extension in patients with subarachnoid or intracerebral hemorrhage: A systematic review of the literature. *Neurology* 247:117–121, 2000.
- Rhode V, Schaller C, Hassler WE: Intraventricular recombinant tissue plasminogen activator for lysis of intraventricular hemorrhage. *J Neurol Neurosurg Psychiatry* 58:447–451, 1995.
- Rosenberg GA, Saland L, Kyner WT: Pathophysiology of periventricular tissue changes with raised CSF pressure in cats. *J Neurosurg* 59:606–611, 1983.
- Rusalleda J, Peiro A: Prognostic factors in intraparenchymatous hematoma with ventricular haemorrhage. *Neuroradiology* 28:34–37, 1986.
- Usui M, Saito N, Hoya K, Todo T: Vasospasm prevention with postoperative intrathecal thrombolytic therapy: A retrospective comparison of urokinase, tissue plasminogen activator, and cisternal drainage alone. *Neurosurgery* 34:235–245, 1994.
- Wang YC, Lin CW, Shen CC, Lai SC, Kuo JS: Tissue plasminogen activator for the treatment of intraventricular hematoma: The dose-effect relationship. *J Neurol Sci* 202:35–41, 2002.

## COMMENTS

I would not recommend knowingly instilling tissue plasminogen activator (rtPA) into the ventricles of patients with known unsecured, ruptured vascular lesions. In this case, however, it is likely that the arteriovenous malformation (AVM) was relatively protected from rebleeding because of some degree of posthemorrhagic thrombosis or focal pressure from the hematoma. Furthermore, it was likely fairly distant from the site of administration of the rtPA, which may have reduced the risk of recurrent bleeding. However, catastrophic bleeding can occur even with the administration of small doses of intracranial rtPA. This point is well documented in the literature. If the initial angiography had shown an AVM, I would have operated and resected it and then administered the rtPA. If not, I would have administered rtPA, as the authors did. Generally, though, at my institution, my colleagues and I administer 0.5 to 1 mg twice a day rather than the doses administered here.

**R. Loch Macdonald**  
*Chicago, Illinois*

The authors have exercised aggressive and thoughtful management of a difficult case with a dismal prognosis. Their heroic interventions clearly contributed to lifesaving and eventually to the favorable outcome. This case illustrates several salient features related to acute intraventricular hemorrhage (IVH) from periventricular AVMs. The authors could be criticized in retrospect for not diagnosing the AVM during the acute phase of the illness. A contrast-enhanced computed tomographic scan would likely have revealed the lesion, and certainly magnetic resonance imaging performed earlier would have alerted the authors to the AVM. A review of the initial arteriogram and selected images displayed in the article reveals a suspicious vascular blush in the inferior temporal region, where the AVM was subsequently discovered. It is likely that careful analysis of all angiographic films would have revealed a hint of the compressed nidus. Nevertheless, it

is not unusual for a small AVM to be angiographically occult in the setting of acute compression and elevated intracranial pressure (ICP). A repeat angiogram clearly revealed the lesion.

Ironically, had the authors suspected that they were dealing with an acutely ruptured periventricular AVM, they would have been less likely to use intraventricular rtPA thrombolysis. In turn, they would have been less likely to administer lifesaving treatment! The common wisdom has largely contraindicated intracranial thrombolysis in the setting of untreated AVMs and aneurysms. Yet, another report in the literature also confirms that thrombolysis may be used without inevitable rebleeding from the AVM. Periventricular AVMs are particularly prone to rehemorrhage, and the safety of this treatment is particularly notable in this regard. Nevertheless, I must caution that these two reported cases do not prove the safety of this treatment with high confidence. It may be advisable to include cases of known AVMs with otherwise intractable ICP in subsequent Phase I clinical trials to assess the safety of intraventricular rtPA. The mortality rates of patients with undrained ventricular casts associated with intractable intracranial hypertension is high. Hence, judicious, compassionate use of this treatment should be considered in such cases, and it is preferable that this information be monitored in ongoing clinical trials designed to address the safety and effectiveness of intraventricular thrombolysis.

**Issam A. Awad**  
Denver, Colorado

**K**umar et al. present an interesting case of a pediatric patient who had a diffuse IVH from a ruptured AVM. The initial angiographic evaluation did not reveal the source of the hemorrhage, and external ventricular drainage was difficult because of repeated episodes of catheter occlusion by clot. In this difficult clinical situation, a decision was made to instill rtPA into the lateral ventricle. This treatment was successful in establishing reliable external ventricular drainage with subsequent control of ICP. Hemorrhage from the AVM did not recur.

This interesting case report documents the feasibility of the intraventricular administration of rtPA for the treatment of IVH in a patient with a ruptured AVM. I do not think, however, that this approach can be recommended as a routine treatment. If an AVM ruptures into the ventricular system and rtPA causes lysis of clot in the ventricular system, one must assume that this treatment will increase the risk of recurrent hemorrhage. That

this did not happen in one or two cases is of interest but is not reassuring.

I wonder if the authors would have administered intraventricular rtPA if the source of hemorrhage had been documented on the initial angiogram. When facing a similar situation and with the knowledge that the source of hemorrhage is a ruptured AVM, I would elect to proceed with surgical evacuation of the intraventricular clot rather than administer rtPA. I have, in fact, used this approach successfully on several occasions. The authors have successfully treated a young patient in a difficult situation and report their experience in a clear, concise fashion, but they probably should not use this treatment in this type of situation again.

**Robert E. Harbaugh**  
Lebanon, New Hampshire

**K**umar et al. provide additional evidence supporting the utility of administering intraventricular rtPA to manage severe IVH. That the authors successfully cleared the ventricles and saved the patient's life despite the presence of a periventricular AVM is noteworthy in several respects. First, it underscores the need for rapid and aggressive treatment in patients with ICP secondary to hydrocephalus. Although there are definite risks in using local thrombolytic therapy in patients with unsecured vascular lesions, these risks are justified when not using thrombolytics would lead to almost certain death or severe, permanent deficits. This case also underscores that early rebleeding from AVMs, even in the periventricular region, is less common than early rebleeding from arterial aneurysms (with or without associated AVMs). One might surmise that early rebleeding from a ruptured AVM nidus is comparatively rare, especially in angiographically occult cases, in part because the cause of rehemorrhage is less likely to be clot resolution than other factors such as ongoing thrombosis of critical venous drainage. Whatever the case, if the patient had presented with a visible AVM, we would have made every effort to secure the bleeding site endovascularly before administering rtPA. If this procedure is not possible and the patient is dying from untreated hydrocephalus, intraventricular rtPA might be indicated in selected cases after careful consideration of all options.

**E. Sander Connolly, Jr.**  
**Sean D. Lavine**  
New York, New York

**Customer Service Contact Information**

CNS Members: Call Sue Souders at: 301/223-2325.

Non-CNS Members: Call either 301/223-2300 or 1-800/638-3030.

Customer Service fax: 301/223-2400.

Customer Service email: customerservice@lww.com