

Case of Stroke in a 7-Year-Old Male After Parvovirus B19 Infection

Battista Guidi, MD*,
Patrizia Bergonzini, MD*,
Giuliano Crisi, MD*,
Giuliana Frigieri, MD*,
Marinella Portolani, MD[†]

A 7-year-old male presented sudden-onset left hemiparesis, left-sided paresthesia, central paralysis of the left VII cranial nerve, and subsequent headache. Magnetic resonance scans were obtained 24 hours after admission. T₂-weighted images disclosed hyperintensities located mainly in the posterior portion of the lenticular nucleus and in the head and body of the right caudate nucleus. A diagnosis of ischaemic stroke was made on the basis of neuroradiologic findings. Laboratory tests undertaken to establish the cause of stroke revealed parvovirus B19 infection preceding the neurologic abnormalities. In the absence of other known risk factors for stroke the possibility of parvovirus B19's being correlated with stroke onset is discussed.
© 2003 by Elsevier Science Inc. All rights reserved.

Guidi B, Bergonzini P, Crisi G, Frigieri G, and Portolani M. Case of stroke in a 7-year-old male after parvovirus B19 infection. *Pediatr Neurol* 2003;28:69-71.

Introduction

The incidence of stroke in childhood has been gauged at one to three per 100,000 children in all ethnic and racial groups. The causes of stroke in children differ from those in adults. In children, it is most commonly caused by or associated with congenital heart disease, vascular disease,

blood disorders (including iron-deficient anemia), hypercoagulation states, head injury, congenital metabolic disease (especially mitochondrial disorders), sickle cell disease, and vasculitis caused by bacterial or viral infection [1,2]. Albeit rare in adults, hemicranial stroke has also been reported in children. The bacterial infections associated with stroke include *Borrelia*, *Mycoplasma*, *Rickettsiae*, and *Streptococcus* and *Haemophilus*; viral infections include varicella-zoster virus, Epstein-Barr virus, influenza A and B, parainfluenza virus, paramyxovirus and enterovirus [1-3]. Despite the increased availability of diagnostic tests, the etiology of stroke remains unknown in 30-50% of cases [1].

A case of ischaemic stroke after parvovirus B19 infection in a 7-year-old male is described.

Case Report

A previously healthy 7-year-old male was referred to the hospital because of headache and motor disorders. Neurologic examination revealed hemiparesis and left-side paresthesias, facial paresthesias, and central paralysis of the left VII cranial nerve. Consciousness, language, sensory functions, and the remaining cranial nerves were normal. Family medical evaluation failed to disclose vascular or metabolic disorders or blood changes. Clinical evaluation revealed no diseases other than sporadic episodes of headache in the months before admission. White blood cell count was normal (white blood cells, 4,820/mL; 51% neutrophils; 35% lymphocytes; 3% eosinophils; 1% monocytes). C-reactive protein content (0.30 mg/dL) and erythrocyte sedimentation rate (1 hour = 17 mm) were normal. Cranial computed tomography scans were normal, whereas a waking electroencephalogram revealed a one-sided asymmetry caused by slowing of background activity in the right hemisphere with a disappearance of eye opening.

Naproxen taken orally (250 mg twice) for suspected migraine resolved the headache, whereas the remaining neurologic abnormalities persisted. Brain and brainstem T₂-weighted magnetic resonance scans obtained 24 hours after admission revealed right hyperintensities mainly in the posterior portion of the lenticular nucleus and in the head (mainly the inferior part) and body of the caudate nucleus. Magnetic resonance angiography failed to disclose blood flow changes in the neck vessels and the visualized portions of the circle of Willis; no moyamoya signs were detected. Neuroradiologic findings indicated recent stroke confirmed by diffusion-weighted sequences (Fig 1).

Further investigations delineated the following results. Color Doppler of the supra-aortic arteries demonstrated increased intracranial resistance on the right side, with normalization of the finding at follow-up 2 weeks later; transcranial Doppler results were normal; results of electrocardiogram, Holter, routine echocardiogram and echocardiogram during injection of shaken saline solution, and Valsalva maneuver were normal. Levels of lactic acid, ammonia, pyruvate, folic acid, and vitamins B12 and B6 were normal; hemoglobin electrophoresis and amino acid pattern on serum and urine tests were normal; homocysteine, plasma, and urine

From the *Centre of Neuroradiology, Hospital Ramazzini-Carpi (MO) Italy; and [†]Centre for Diagnosis of Viral Diseases, University Hospital, Via del Pozzo, 87 Modena 41100 Italy.

Communications should be addressed to:
Dr. Portolani; Department of Hygiene, Microbiology and Biostatistics;
University of Modena and Reggio Emilia; via Campi 287, 41100
Modena, Italy.

Received May 2, 2002; accepted July 31, 2002.

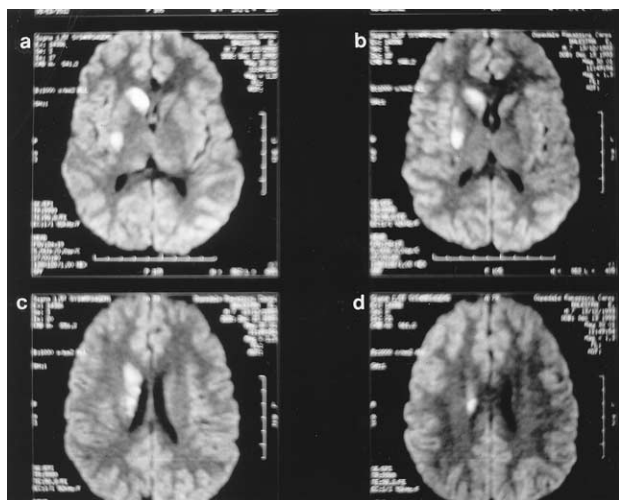


Figure 1. Axial “diffusion” MRI scans: Hyperintensities mainly in the posterior portion of the lenticular nucleus and in the head and body of the caudate nucleus (24 hours after admission). Parameter of the study: SE/EPI; TR, 9999; TE, 98.8/.

organic acid levels were normal; and search for 7 dehydrocholesterol, celiac profile, lipid pattern, and coagulation time were normal. Search for the G20210A mutation of the prothrombin gene and search for the Leiden G 1691A factor V mutation were negative. Autoimmune tests indicated a transient mild positivity for antinuclear antibodies, lupus anticoagulant, and antismooth muscle antibodies; the search for antiphospholipid antibodies proved negative.

Results of laboratory tests for bacteria and viruses known to be associated with stroke in children [1–3] were negative. Instead, the search for antibodies against a panel of other common viruses disclosed an antibody arrangement toward parvovirus B19 that was typical of active infection and confirmed by the subsequent trend of the antibody response and the persistence of genomic virus sequences in serum (Table 1).

Serologic and virologic search for parvovirus B19 in the cerebrospinal fluid was impossible because the child’s parents did not consent to lumbar puncture.

An anticoagulant treatment with acetylsalicylic acid (100 mg/day) was followed by a rapid resolution of neurologic abnormalities and normalization of the clinical features in 36 to 48 hours. Clinical follow-up results were normal except for a nonitching rash on the patient’s face and legs 20 days after stroke onset; the rash resolved spontaneously 4 to 5 days later. Brain and brainstem magnetic resonance scans 3 weeks later illustrated a resolution of ischaemic stroke lesions in the body of the

Table 1. Parvovirus B19 antibodies and Parvovirus B19 DNA in the patient’s serum at different days of the disease onset

Serum sample: days from disease onset	Parvovirus B19 antibody values*		Parvovirus B19 DNA†
	Ig M	Ig G	
4	5.55	1.6	+
10	4.94	5.96	+
24	1.56	5.98	+
83	0.25	5.6	+

* Search for antibodies was performed by ELISA commercial kits (Denka, Seiken Co, LTD, Tokyo, Japan). Antibody values were expressed by an index that was obtained from optical density (OD) value of the specimen/OD value of the standard. An index value ≥ 1 was considered to be a positive result both for Ig M and Ig G antibody.

† Search for parvovirus B19 DNA was performed by nested PCR [15].

caudate nucleus, whereas the lesions persisted in the lenticular nucleus, as confirmed by diffusion-weighted sequences.

On discharge the patient continued to take acetylsalicylic acid (100 mg/day), and results of the clinical follow-up examination three months later were normal. The child has not presented further headache or migraine episodes.

Discussion

Ischemic stroke in children is rare and caused by myriad factors. Migraine may also be responsible but is not as common as in adult stroke. This stroke patient may have manifested migraine, as evidenced by his episodes of headache in the months before neurologic abnormalities arose. However, the headache features, lack of aura, short duration, and mild intensity, ruled out this cause on the basis of the 1988 classification of the International Headache Society.

No known risk factors for stroke emerged from the patient’s clinical evaluation. Most laboratory test results were normal, except for a slight positivity for lupus anticoagulant, antismooth muscle antibodies, and antinuclear antibodies indicative of vascular damage. Microbiologic and virologic tests negative for pathogens known to be risk factors for hemorrhagic stroke disclosed an active parvovirus B19 infection (Table 1) whose onset preceded the neurologic features, as demonstrated by the kinetics of immunoglobulin M and immunoglobulin G antibodies.

A number of viruses have been implicated as possible risk factors for childhood stroke [1–3]. Reported cases of viral origin involved the cerebral vessels, with vasculitis, irregular stenosis, and angiitis-like changes ascribed to the direct effect of the virus on the vascular tunica media or an immune-mediated reaction [3,4,5].

A MEDLINE search failed to yield bibliographic references on a possible correlation between childhood stroke and parvovirus B19 infection. Parvovirus B19 is a single-stranded DNA nonenveloped virus that can be transmitted before or after birth. The horizontal transmission of the virus is a common occurrence since frequencies of parvovirus B19 seropositivity reacting 50% and 90% in young adults and in the elderly respectively has been reported [6]. Parvovirus B19 in children generally causes a mild systemic illness followed by the appearance of an erythematous rash (erythema infectiosum, or fifth disease). Neurologic complications of parvovirus B19 infections, first suggested by reports of encephalopathy in patients with erythema infectiosum [7], have been subsequently confirmed by reports of peripheral neuropathies [8], meningitis [9,10], and meningoencephalitis [11]. Other clinical manifestations associated with Parvovirus B19 are systemic vasculitis [12] and severe arterial occlusive disease [13].

In the absence of known risk factors for stroke, the literature data that are reported here describe the ability of parvovirus B19 to reach the central nervous system and cause vascular injury suggest a correlation between B19 infection and hemorrhagic stroke in this 7-year-old patient.

The postulated association between the virus and the present case of cerebral vascular disease is interesting because the parvovirus B19 infection remained clinically silent until the appearance of a typical rash 3 weeks after the onset of neurologic signs. The long period of viremia documented in the patient (Table 1) is in agreement with literature reports on the possibility of long persistence of parvovirus B19 after primary infection [14].

The correlation between parvovirus B19 infection and stroke onset cannot be proved in our patient because we could not undertake virologic and serologic tests on his cerebrospinal fluid. Nevertheless, our findings strongly suggest that parvovirus B19, in addition to known viruses, may be responsible for stroke in children and, even when medical evaluation fails to disclose general or specific clinical signs of recent or ongoing viral infection, a viral etiology of the stroke should not be excluded.

References

- [1] **Riikonen RR**, Santavuori P. Hereditary and acquired risk factors for childhood stroke. *Neuropediatrics* 1994;25:227-33.
- [2] **Kirkham FJ**. Stroke in childhood. *Arch Dis Child* 1999;81:85-9.
- [3] **Grau AJ**, Buggle F, Becher H, et al. Recent bacterial and viral infection is a risk factor for cerebrovascular ischemia: clinical and biochemical studies. *Neurology* 1998;50:196-203.
- [4] **Ganesan V**, Kirkham FJ. Mechanisms of ischaemic stroke after chickenpox. *Arch Dis Child* 1997;76:522-25.
- [5] **Hausler MG**, Ramaekers VT, Reul J, Meilicke R, Heimann G. Early and late onset manifestations of cerebral vasculitis related to varicella zoster. *Neuropediatrics* 1998;29:202-207.
- [6] **Anderson LJ**, Tork JJ. The clinical spectrum of human Parvovirus B19 infections. *Curr Clin Top Infect Dis* 1991;11:267-80.
- [7] **Balfour HH, Jr**, Schiff GM, Bloom JE. Encephalitis associated with erythema infectiosum. *J Pediatr* 1970;77:133.
- [8] **Nigro G**, D'Eufemia F, Zerbini M, Krzysztafiak A, Finocchiaro R, Giardini O. Parvovirus B19 infection in a hypogammaglobulinemic infant with neurological disorders and anemia: successful immunoglobulin therapy. *Pediatr Inf Dis J* 1994;13:1019-21.
- [9] **Tsuji A**, Uchida N, Asamura S, Matsunaga Y, Yamazaki S. Aseptic meningitis with erythema infectiosum. *Eur J Pediatr* 1990;149:449-50.
- [10] **Okumana A**, Ichikawa T. Aseptic meningitis caused by human parvovirus B19. *Arch Dis Child* 1993;68:784-85.
- [11] **Barah F**, Vallely PJ, Chiswick ML, Cleator GM, Kerr JR. Association of human parvovirus B19 infection with acute meningoencephalitis. *Lancet* 2001;358:729-30.
- [12] **Finkel TH**, Torok TJ, Ferguson PJ, et al. Chronic parvovirus B19 infection and systemic necrotising vasculitis: Opportunistic infection or aetiological agent? *Lancet* 1994;21:1255-58.
- [13] **Dingli D**, Pfizenmaier DH, Arromdee E, et al. Severe digital arterial occlusive disease and acute parvovirus B19 infection. *Lancet* 2000;356:312-14.
- [14] **Musiani M**, Zerbini M, Gentilomi G, Plazzi M, Gallinella G, Venturoli S. Parvovirus B19 clearance from peripheral blood after acute infection. *J Inf Dis* 1995;172:1360-63.
- [15] **Durigon EL**, Erdman DD, Gary GW, Pallansch MA, Torok TJ, Anderson LJ. Multiple primer pairs for polymerase chain reaction (PCR) amplification of human parvovirus B19 DNA. *J Virol Methods* 1993;44:155-65.