

Short Communication

Long lasting impaired cerebral blood flow after ecstasy intoxication

JOSEF FINSTERER, MD, PhD,¹ CLAUDIA STÖLLBERGER, MD,² CHRISTINE STEGER, MD²
AND ALOIS KROISS, MD³

¹Neurological Department, KA Rudfstiftung, ²Second Medical Department and ³Department of Nuclear Medicine, Krankenanstalt Rudolfstiftung, Vienna, Austria

Abstract

Four hours after having taken 10 ecstasy tablets a Grand Mal seizure occurred in a 19-year-old woman followed by coma, hyperthermia, tachycardia, tachypnea, and renal failure. After awakening she was oriented but presented with helplessness, disconcertion, hallucinations, panic attacks, and amnesic syndrome. Computed tomography and magnetic resonance imaging scans of the brain were normal. [⁹⁹Tc]-hexamethylpropyleneamine oxime (HMPAO)-single photon emission computed tomography (SPECT), 20 days after intoxication, showed reduced, inhomogeneous, supratentorial tracer uptake bilaterally. Electroencephalography (EEG) disclosed diffuse slowing and occasionally generalized sharp waves. Valproic acid was begun. Except for slight amnesia, neuropsychological deficits had disappeared and [⁹⁹Tc]-HMPAO-SPECT normalized, 29 days later. Decreased cortical blood flow was explained by vasoconstriction following ecstasy-induced depletion of serotonin.

Key words

addiction, adverse reaction, central nervous system, cerebral blood flow, ecstasy, intoxication, side-effect.

INTRODUCTION

Ecstasy or 3,4-methylenedioxymethamphetamin (MDMA, Adams), first synthesized in 1914 as an appetite suppressant, induces a sense of euphoria, loss of inhibition, a feeling of benevolence, closeness and empathy, increased sensuality, and enhanced sociability. Because of these latter effects, ecstasy has become a popular, illicit, recreational, abused designer drug among the young and older jet set at dance-clubs and rave parties, where it is combined with all night dancing, crowded conditions, poor hydration and loud sound.¹ At the top of its widespread popularity is the mistaken belief that it is safe and hardly toxic, provided that large volumes of liquid are consumed to prevent dehydration.^{1,2} On the contrary, ecstasy has an unpredictable toxicity with various short-term and long-term side-effects such as acute and chronic psychiatric

abnormalities,^{3–5} central nervous system (CNS) abnormalities, cardiac arrhythmias, hypertension, tachypnea, impaired liver function, muscle rigidity, rhabdomyolysis, myoglobinuria, creatine kinase (CK) elevation up to 500 000 U/L, hyperpyrexia, sweating, dehydration, acute renal failure, metabolic acidosis, hyponatremia, and disseminated intravascular coagulation (DIC) syndrome.^{1,6,7} The CNS abnormalities include seizures,³ subarachnoidal hemorrhage, cerebral infarction, intracranial bleeding,³ coma, dilated pupils, cerebral venous thrombosis, hyperthermia, hot flashes, nystagmus, ataxia, trismus, jaw clenching and autonomic dysfunction. Ecstasy is generally described as non-addictive, although addiction has been reported.^{8,9} Recent studies have shown that the CNS abnormalities are partly due to depletion of serotonin and damage of serotonergic nerve endings by ecstasy,² explaining the short- or long-term decreased cerebral blood flow.² Visualization of the decreased cerebral blood flow following ecstasy intoxication was only rarely possible.² Here we describe a patient with ecstasy intoxication and prolonged abnormal [⁹⁹Tc]-hexamethylpropyleneamine oxime (HMPAO)-single photon emission computed tomography (SPECT).

Correspondence address: Dr J. Finsterer, Pos-fach 348, 1180 Wien, Austria. Email: duarte@jet2web.cc

Received 20 March 2002; revised 20 June 2002; accepted 23 July 2002.

CASE REPORT

A 19-year-old woman was admitted with coma, fever, tachycardia and tachypnea after a single Grand Mal seizure. From the emergency doctor she received diazepam, ajmalin and adenosin. Taking the history with her girl friend revealed that she had ingested 10 tablets of ecstasy approximately 4 h prior to the seizure. No other drugs were taken. She had not consumed a larger volume of liquids along with the ecstasy tablets. Concerning the previous medical history, there was head trauma with loss of consciousness as a baby, head trauma with loss of consciousness for several minutes after a fall in 1999, repeated falls from horse-backs without neurological deficits, weight loss, two collapses and occasional tremor within 6 weeks prior to admission. Additionally, she suffered from bronchial asthma since childhood, for which she regularly took anti-asthmatic medication. Her grandmother described her as sluggish since puberty. A sister of her mother suffered from epilepsy.

Clinical examination on admission revealed coma, round, normally wide pupils, which reacted promptly to direct and indirect light, fasciculations of the tongue, myocloni, tachycardia and tachypnea (Glasgow coma scale: 8). Body temperature was 40°C. Blood pressure was 150/90 mmHg. Electrocardiography (ECG) showed sinustachycardia of 170 b.p.m. and ascending ST elevation in II and avF. Blood gas analysis was normal. X-ray of the lungs showed a right-sided infiltrate but was normal 2 days later. Blood chemical investigations are given in Table 1, revealing slight renal insufficiency, transient hyper-CK-emia, increased C-reactive protein, and leukocytosis. Urine analysis for

drugs yielded a positive result for amphetamines and opiates. The positive urine test for opiates was interpreted as either false positive or due to contamination of the ecstasy tablets with opiates. A computed tomography (CT) scan of the brain was normal. The patient received low-dose heparin, cefuroxim, pantoprazol and sodium chloride in addition to her anti-asthmatic drugs. On the 2nd hospital day the patient woke up and was oriented. She now experienced panic attacks and visual hallucinations, which consisted of ugly figures and mice, particularly at night. The course of blood chemical values is given in Table 1. Normocardia recurred on the 3rd hospital day. Clinical neurologic examination 5 days after the acute intoxication revealed amnesia, dissimulation, general memory loss, helplessness, disconcertion, but was otherwise normal. Magnetic resonance imaging (MRI) of the cerebrum 19 days after intoxication was normal. The [⁹⁹Tc]-HMPAO-SPECT, 20 days after intoxication, showed reduced, inhomogeneous tracer uptake without side difference supratentorially (Fig. 1).

Clinical neurologic examination 22 days after intoxication revealed amnesia with memory loss, particularly for faces and events, inappetence, bradyphrenia, crankiness, tiredness, positive pyramidal signs on the right upper limb, and exaggerated patella tendon reflexes bilaterally. Nerve conduction studies of the right median nerve and needle electromyography (EMG) of the right brachial biceps were normal. Electroencephalography (EEG) 22 days after intoxication showed theta-activity over the frontal regions and short-duration generalized theta-groups with embedded sharp waves. Because of the clinical presentation and the EEG, valproic acid (600 mg/day) was given,

Table 1. Course of blood chemical values during and after hospitalization

Variable	Reference limits	Days after intoxication									
		0 (4.49 am)	0 (6.19 am)	0 (7.31 am)	0 (5.56 pm)	1	2	3	5	12	15
Creatinin	≤1.1 mg/dL	2.2	1.8	1.9	1.1	0.8	0.9	0.8	0.9	1.0	ND
Uric acid	2.5–6 mg/dL	ND	ND	11.6	ND	ND	ND	ND	3.3	ND	ND
AST	≤15 U/L	ND	ND	33	ND	174	105	ND	148	32	16
ALT	≤17 U/L	ND	ND	15	ND	68	78	ND	125	80	50
CK	≤70 U/L	611	1140	1086	5380	6568	2588	3726	6587	518	135
CK-MB	≤11 U/L	8	10	14	>190	>190	59	69	178	14	9
CHE	3500–8500 U/L	ND	ND	1289	ND	1046	ND	ND	ND	ND	1973
CRP	≤0.6 mg/dL	ND	ND	1.9	ND	7.9	4.4	2.0	0.9	0.9	ND
WBC	4.0–9.0/nL	16.8	ND	14.9	8.3	8.9	9.3	8.2	8.6	9.2	ND
RBC	4.0–5.2/pL	4.35	ND	3.48	3.40	3.34	3.5	3.86	4.32	4.89	ND
Thrombo	150–450/nL	406	ND	252	127	98	160	245	336	652	ND

BUN, blood urea nitrogen; GGT, γ -glutamyl transpeptidase; AST, aspartate-aminotransferase; ALT, alanine-aminotransferase; CK, creatine kinase; CK-MB, muscle isoform of CK; CHE, cholinesterase; WBC, white blood cell count; RBC, red blood cell count; Thrombo, thrombocytes; CRP, C-reactive protein; ND, not done.

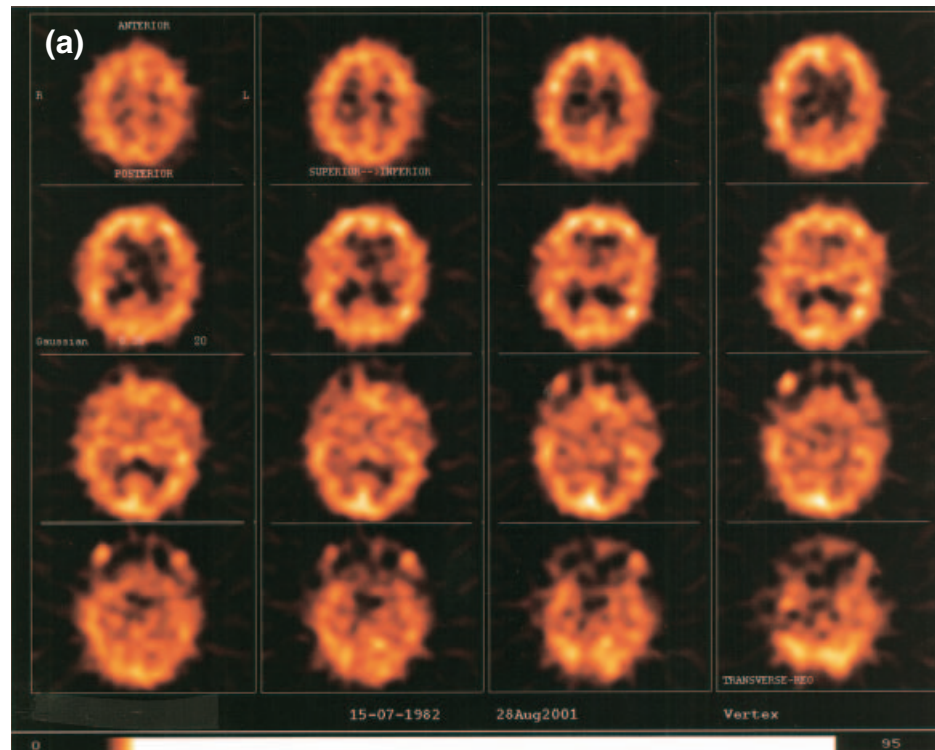
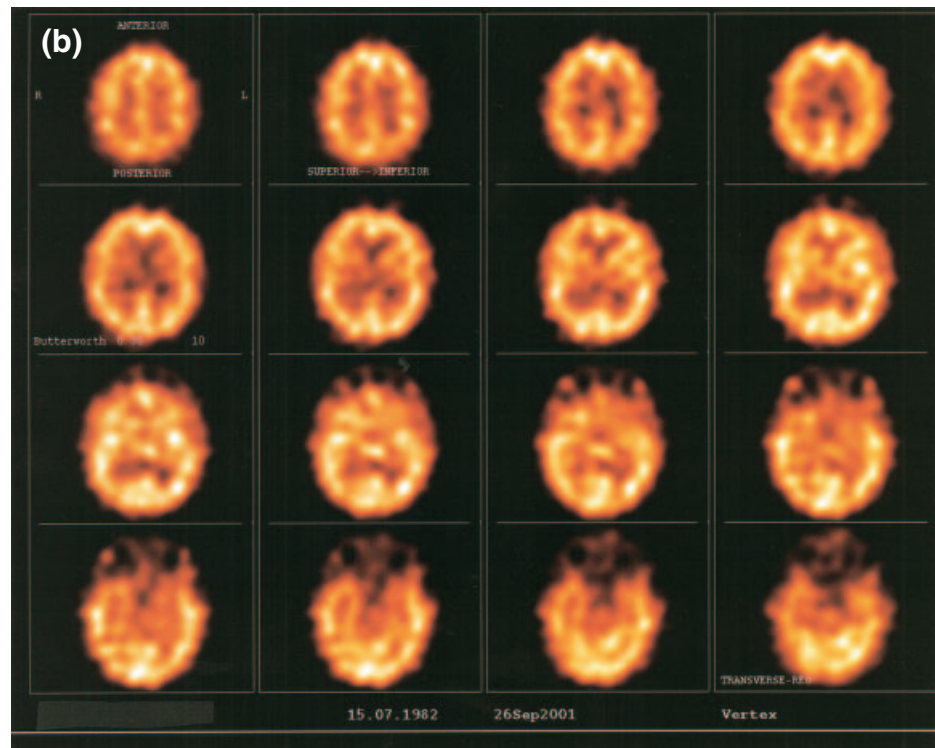


Figure 1. [^{99}Tc]-hexamethylpropyleneamine oxime (HMPAO)-single photon emission computed tomography (SPECT) of the described patient, 20 days after acute ecstasy intoxication shows inhomogeneous reduction of the tracer uptake supratentorially, predominantly in the temporal and parietal regions, and absent delineation of the basal ganglia from the surrounding tissue (a). Twenty-nine days later, tracer uptake had become more homogenous and was almost normal (b). The investigations were carried out with a digital double-head gamma camera (Vertex Plus; Adac, Milpitas, USA) using high-resolution collimators with a 64×64 matrix in steps of 6° . Slices of 4 mm were evaluated using a Gauß filter and the attenuation correction of Chang. The $^{99\text{m}}\text{Tc}$ was applied in a dosage of 740 mBq.



with success. Clinical neurologic examination 41 days after intoxication and after 19 days on valproic acid showed markedly improved retrograde amnesia and exaggerated patella tendon reflexes exclusively. The

EEG still showed occasional generalized sharp waves and so valproic acid was increased to 900 mg/day. Twenty-nine days after the first investigation, [^{99}Tc]-HMPAO-SPECT was almost normal (Fig. 1).

DISCUSSION

The acute manifestations of the ecstasy intoxication in the presented patient were seizure, hyperthermia, coma, hallucinations, amnesic syndrome, depression, sinustachycardia, elevated liver enzymes, acute renal failure, and the abnormal HMPAO-SPECT. That hypoperfusion on HMPAO-SPECT was related to the paroxysmal activity on EEG is rather unlikely, because the SPECT normalized despite ongoing paroxysmal activity on EEG. Furthermore, ictal HMPAO-SPECT usually shows hyperperfusion rather than hypoperfusion.¹⁰ The previous head traumata were regarded as not being responsible for the SPECT abnormalities because there was no history of long-term neurological deficits. Cerebral hypoxia during the Grand Mal seizure or during cardiac rhythm abnormalities, which could also explain the abnormal SPECT findings, is rather unlikely because there was no epileptic state and no severe rhythm abnormality, except sinustachycardia on admission. Alternatively, the abnormal cortical blood flow might have been caused by pCO₂ changes, which may occur spontaneously in injured patients with hyperventilation. However, blood gas analysis was normal on admission and during hospitalization.

The abnormal SPECT findings in the presented patient can be explained by a long-term ecstasy-induced reduction of the cerebral blood flow due to vasoconstriction. Vasoconstriction and thus reduced cerebral blood flow may be due to the ecstasy-induced depletion of serotonin (5-hydroxytryptamin, 5-HT), which is a potent constrictor of the cerebrovascular smooth muscles.² Involvement of 5-HT in the regulation of the cerebral blood flow is well-documented.^{11,12} Already a previous study using ⁹⁹Tc-HMPAO-SPECT on 21 patients with a history of recreational ecstasy use has shown impaired cerebral blood flow following ecstasy intake.² In the eight patients of this study who received ecstasy for study purposes, HMPAO-SPECT showed significantly decreased cerebral blood flow in most of the brain regions 25 days (10–80 days) after the last intake. The most prominent reductions were seen in the caudate, the superior parietal cortices and the right dorsolateral frontal cortex.² These findings are in line with those of the present investigation. In those patients who had only a history of ecstasy intake, global and regional cerebral blood flow were normal compared to 21 age- and sex-matched controls.

Generally, intoxication with ecstasy goes along with a massive release of 5-HT from presynaptic vesicles of 5-HT-neurons and inhibition of 5-HT uptake. Depletion of 5-HT causes oxidative stress due to increased generation of free radicals and diminished antioxi-

dative capacity of the brain.¹³ Reactive metabolites such as glutathione are produced, forming adducts with intracellular nucleophilic sites,¹⁴ which is why ascorbic acid is recommended to prevent the neurochemical and behavioral response.¹³ The 5-HT depletion from 5-HT neurons is enhanced by malonate.¹¹ Ecstasy also causes long-term destruction of presynaptic 5-HT neurons, axons and axon terminals in animal models.¹ Loss of 5-HT neurons has been implicated in memory loss.¹² Depletion of 5-HT additionally induces prolonged vasoconstriction of the cerebral vasculature,² resulting in persistent decrease of the regional cerebral blood flow, as confirmed by HMPAO-SPECT. Ecstasy also reduces the anterograde axonal transport in 5-HT neurons,¹⁵ and reduces vitamin C and E concentrations in the striatum and hippocampus.¹³ Furthermore, ecstasy increases intracellular 5-HT concentration in the striatum, thereby eliciting the serotonin syndrome.¹³ Also the globus pallidus is particularly sensitive to ecstasy.¹² Additionally, ecstasy causes long-lasting effects on the glucose metabolism in the human brain.¹⁶ At least some of the psychomotor stimulant effects of ecstasy might be coupled with an increase in prefrontal and striatal acetylcholine release.¹⁷ Drugs that increase gamma-aminobutyric acid (GABA) receptor channel opening are neuroprotective against ecstasy-induced damage.¹⁸

A differential diagnosis to the ecstasy-induced serotonin syndrome that has to be considered in the present patient is neuroleptic malignant syndrome (NMS). This is a rare but life-threatening complication of the neuroleptic treatment, characterized by extrapyramidal signs (muscle rigidity, dystonia, akinesia and tremor), autonomic disturbances (hyperthermia, tachycardia, variable blood pressure, altered consciousness) and abnormal laboratory findings such as elevated CK and leukocytosis.^{19,20} In rare cases NMS may overlap with the serotonin syndrome.²¹ Arguments for NMS in the present patient are hyperthermia, altered consciousness, elevated CK and leukocytosis. Arguments against NMS in the present patient are that she had not received neuroleptic drugs prior to the onset of symptoms and the lack of extrapyramidal symptoms. Furthermore, ¹⁵CO₂-positron emission tomography (PET) in NMS showed increased cerebral blood flow (compared to decreased cerebral blood flow in the present patient) in the occipital cortex, striatum and cerebellum, reflecting the higher metabolic demands of these regions. However, these patients received bromocriptin which itself increases the cerebral blood flow.²⁰ The SPECT with the tracer isopropyl-p-iodoamphetamine showed asymmetrical uptake in the basal ganglia of patients with NMS who did not receive bromocriptin.²⁰

The present case shows that ecstasy intoxication may accompany a subacute, global decrease in cerebral blood flow, visualized by [⁹⁹Tc]-HMPAO-SPECT, even weeks after the intoxication. This long-term adverse effect of ecstasy is explained by ecstasy-induced depletion of serotonin and its metabolites resulting in prolonged vasoconstriction of the cerebral vessels.

REFERENCES

- Burgess C, O'Donohoe A, Gill M. Agony and ecstasy: A review of ecstasy effects and toxicity. *Eur. Psychiatry* 2000; **15**: 287–294.
- Chang L, Grob CS, Ernst T *et al.* Effect of ecstasy [3,4-methylenedioxymethamphetamine (ecstasy)] on cerebral blood flow: A co-registered SPECT and MRI study. *Psychiatry Res.* 2000; **98**: 15–28.
- Jansen KL. Ecstasy (ecstasy) dependence. *Drug Alcohol Depend.* 1999; **53**: 121–124.
- Thomasius P, Schmolke M, Kraus D. Ecstasy ('ecstasy') use: An overview of psychiatric and medical sequelae. *Fortschr. Neurol. Psychiatr.* 1997; **65**: 49–61.
- Zakzanis KK, Young DA. Memory impairment in abstinent ecstasy ('ecstasy') users: A longitudinal investigation. *Neurology* 2001; **56**: 966–969.
- Garbino J, Henry JA, Mentha G, Romand JA. Ecstasy ingestion and fulminant hepatic failure: Liver transplantation to be considered as a last therapeutic option. *Vet. Hum. Toxicol.* 2001; **43**: 99–102.
- Mueller PD, Korey WS. Death by 'ecstasy': The serotonin syndrome? *Ann. Emerg. Med.* 1998; **32**: 377–380.
- Bhattachary S, Powell JH. Recreational use of 3,4-methylenedioxymethamphetamine (ecstasy) or 'ecstasy': Evidence for cognitive impairment. *Psychol. Med.* 2001; **31**: 647–658.
- Croft RJ, Mackay AJ, Mills AT, Gruzelier JG. The relative contributions of ecstasy and cannabis to cognitive impairment. *Psychopharmacology* 2001; **153**: 373–379.
- Koh S, Jayakar P, Resnick T, Alvarez L, Litt RE, Duchowny M. The localizing value of ictal SPECT in children with tuberous sclerosis complex and refractory partial epilepsy. *Epileptic Disord.* 1999; **1**: 41–46.
- Nixdorf WL, Burrows KB, Gudelsky GA, Yamamoto BK. Enhancement of 3,4-methylenedioxymethamphetamine neurotoxicity by the energy inhibitor malonate. *J. Neurochem.* 2001; **77**: 547–654.
- Reneman L, Booij J, Schmand B *et al.* Memory disturbances in 'Ecstasy' users are correlated with an altered brain serotonin neurotransmission. *Psychopharmacology* 2000; **148**: 322–324.
- Shankaran M, Yamamoto BK, Gudelsky GA. Ascorbic acid prevents 3,4-methylenedioxymethamphetamine (ecstasy)-induced hydroxyl radical formation and the behavioural and neurochemical consequences of the depletion of brain 5-HT. *Synapse* 2001; **40**: 55–64.
- Carvalho M, Carvalho F, Bastos ML. Is hyperthermia the triggering factor for hepatotoxicity induced by 3,4-methylenedioxymethamphetamine (ecstasy)? An in vitro study using freshly isolated mouse hepatocytes. *Arch. Toxicol.* 2001; **74**: 789–793.
- Callahan BT, Cord BJ, Ricaurte GA. Long-term impairment of anterograde axonal transport along fibre projections originating in the rostral raphe nuclei after treatment with fenfluramine or methylenedioxymethamphetamine. *Synapse* 2001; **40**: 113–121.
- Buchert R, Obrocki J, Thomasius R *et al.* Long-term effects of 'ecstasy' abuse on the human brain studied by FDG PET. *Nucl. Med. Commun.* 2001; **22**: 889–897.
- Acquas E, Marrocu P, Pisanu A *et al.* Intravenous administration of ecstasy (3,4-methylenedioxymethamphetamine) enhances cortical and striatal acetylcholine release in vivo. *Eur. J. Pharmacol.* 2001; **418**: 207–211.
- Colado MI, O'Shea E, Esteban B, Green AR. Studies on the neuroprotective effect of the enantiomere of AR-A008055, a compound structurally related to clomethiazole, on ecstasy ('ecstasy')-induced neurodegeneration in rat brain. *Psychopharmacology* 2001; **157**: 82–88.
- De Reuck J, Van Aken J, Van Landegem W, Colardyn F. Position emission tomographic studies of changes in cerebral blood flow and oxygen metabolism in neuroleptic malignant syndrome. *Eur. Neurol.* 1991; **31**: 1–6.
- Nisijima K, Matoba M, Ishiguro T. Single photon emission computed tomography with 123I-IMP in three cases of the neuroleptic malignant syndrome. *Neuroradiology* 1994; **36**: 281–284.
- Demirkiran M, Jankovic J, Dean JM. Ecstasy intoxication: An overlap between serotonin syndrome and neuroleptic malignant syndrome. *Clin. Neuropharmacol.* 1996; **19**: 157–164.