

- Bertina RM, Koeleman BP, Koster T, et al. Mutation in blood coagulation factor V associated with resistance to activated protein C. *Nature* 1994;369:64–67.
- Poort SR, Rosendaal FR, Reitsma PH, Bertina RM. A common genetic variation in the 3' untranslated region of the prothrombin gene is associated with elevated plasma prothrombin levels and an increase in venous thrombosis. *Blood* 1996;88:3698–3703.
- Bruijn de SFTM, Stam J, for the Cerebral Venous Sinus Thrombosis Study Group. Randomized, placebo-controlled trial of anticoagulant treatment with low-molecular-weight heparin for cerebral sinus thrombosis. *Stroke* 1999;30:484–488.
- Den Heijer M, Rosendaal FR, Blom HJ, Gerrits WBJ, Bos GMJ. Hyperhomocysteinemia and venous thrombosis: a meta-analysis. *Thromb Haemost* 1998;80:874–877.
- Deschiens MA, Conard J, Horellou MH, et al. Coagulation studies, factor V Leiden, and anticardiolipin antibodies in 40 cases of cerebral venous thrombosis. *Stroke* 1996;27:1724–1730.
- Martinelli I, Sacchi E, Landi G, Taioli E, Duca F, Mannucci PM. High risk of cerebral-vein thrombosis in carriers of a prothrombin gene mutation and in users of oral contraceptives. *N Engl J Med* 1998;338:1793–1797.
- Soria JM, Almasy L, Souto JC, et al. A new locus on chromosome 18 that influences normal variation in activated protein C resistance phenotype and factor VIII activity and its relation to thrombosis susceptibility. Available at: [www.bloodjournal.org](http://www.bloodjournal.org) (Blood–2002–06–1792).
- Aidi S, Chaunu MP, Biousse V, Bousser MG. Changing pattern of headache pointing to cerebral venous thrombosis after lumbar puncture and intravenous high-dose corticosteroids. *Headache* 1999;39:559–564.

---

# Pure dysarthria due to small cortical stroke

Jong S. Kim, MD; Sun U. Kwon, MD; and Te G. Lee, MD

---

**Abstract**—The authors describe six patients who presented with dysarthria as their isolated or major symptom from a small cortical stroke. Five had infarction and one had hemorrhage. In the patients with ischemic stroke, the lesions were identified by diffusion-weighted MRI but not by T-2 weighted MRI. The lesions were located lateral to the precentral knob usually at the most lateral part of the imaging. The presumed pathogenesis included embolism in five patients and hypertensive hemorrhage in one.

NEUROLOGY 2003;60:1178–1180

---

Pure or predominant dysarthria with minimal other neurologic signs can be seen in patients with strokes involving the corticobulbar tract, usually at the lenticulocapsular or pontine base areas.<sup>1</sup> Isolated dysarthria due to cortical stroke is considered rare.<sup>1–3</sup> The rarity may reflect the small size of the infarct so that it is not detectable by CT or conventional MRI. Diffusion-weighted MRI (DWI) has been shown to be more sensitive in identifying acute, small ischemic lesions than conventional MRI<sup>4</sup> and has helped us to identify small cortical strokes producing isolated weakness of the hand<sup>5</sup> or fingers.<sup>6</sup> We describe six patients who presented with dysarthria as their isolated or major symptom due to cortical strokes. The lesions were identified by DWI in five of them.

**Subjects and methods.** Between March 2001 and November 2002, out of 1,397 admitted stroke patients we identified 6 consecutive patients (0.43%) in the Asan Medical Center who had isolated dysarthria without or with only minimal other neurologic symptoms or signs due to small cortical strokes. MRI was performed by echoplanar imaging using a 1.5-T whole body scanner (Signa Cvi, GE Medical Systems, Milwaukee, WI). Scans consisted of an axial T2-weighted fast-spin echo sequence (TR/TE 4500/118 msec), T1-weighted sequence (TR/TE 400/8 msec) with 20 slices covering whole brain, 5-mm slice thickness and 2-mm interslice gap. Axial diffusion trace sequence (single-shot echo planar spin echo sequence,  $b = 1,000$  seconds/mm<sup>2</sup>, TR/TE 5,000/139 msec)

was also obtained. MR angiogram (MRA) and EKG were performed in all the patients, and echocardiograms were performed in five.

**Results. Demography and risk factors.** The demography and clinical characteristics of the patients are summarized in the table. There were six patients (four men and two women), ranging in age from 34 to 82 years. Risk factors included hypertension in two and current cigarette smoking in three. Two patients (Patients 1 and 2) had atrial fibrillation and one (Patient 3) had patent foramen ovale with right to left shunt. One (Patient 5) had a history of unstable angina. None had a history of stroke.

**Clinical findings.** All the patients suddenly developed dysarthria, which was their chief complaint. The dysarthria was mild to moderate, and their speech was not unintelligible. In Patient 3, dysarthria was transient (lasting approximately 3 hours), whereas it persisted in others. Although both lingual and labial sounds were impaired, the former was more markedly abnormal. There was no evidence of aphasia; none showed paraphasia, stuttering, or sparse verbal output. Understanding, naming, repetition, reading, and writing were normally performed. None showed orobuccal apraxia, and three (Patients 1, 2, and 5) had mild and transient dysphagia. Mild lower facial paresis was noted in four (Patients 1, 4–6). All were able to protrude their tongues, and obvious tongue deviation was not observed. However, rapid wiggling of the tongue was clumsy bilaterally in all except Patient 3. Soft palate movements were symmetric in all the patients.

In addition, Patient 3 described mild and transient weakness of her right thumb, which was not detected at the time of examination. Patient 1 had paresthesia over the right perioral area, tongue, and the tip of his thumb where pinprick sensation was mildly decreased. Otherwise, there were no ataxia, spasticity, gait

From the Department of Neurology (Drs. Kim and Kwon), University of Ulsan, Asan Medical Center; and the Department of Neurology (Dr. Lee), Kyung Hee University, Seoul, South Korea.

Received February 19, 2002. Accepted in final form December 17, 2002.

Address correspondence and reprint requests to Dr. Jong S. Kim, Department of Neurology, Asan Medical Center, Song-pa PO Box 145, Seoul 138-600, South Korea; e-mail: [jongskim@amc.seoul.kr](mailto:jongskim@amc.seoul.kr)

1178 Copyright © 2003 by AAN Enterprises, Inc.

Copyright © Lippincott Williams & Wilkins. Unauthorized reproduction of this article is prohibited.

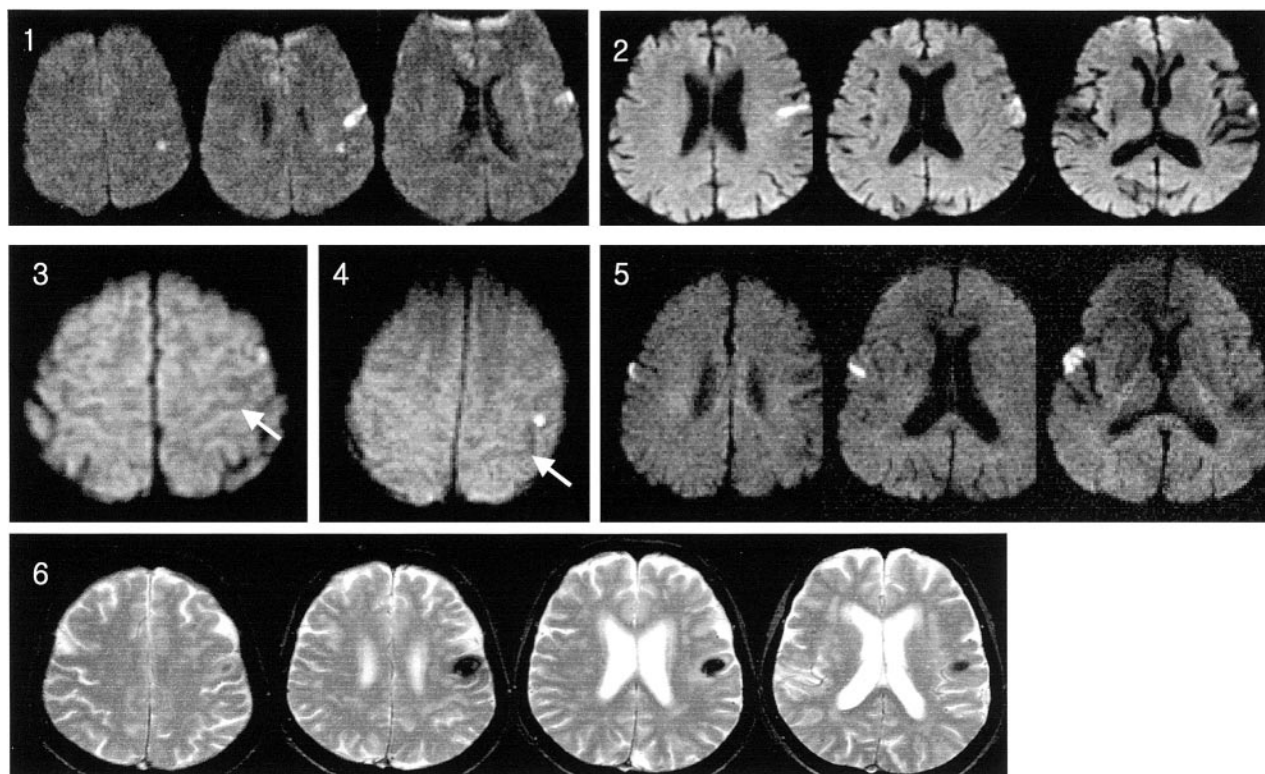
**Table Summary of the patients**

Variables	Patient no.					
	1	2	3	4	5	6
Sex/age, y	M/53	M/82	F/34	M/44	M/66	F/72
Risk factors	Af, SM	Hypertension, Af	PFO with shunt	R-L SM	SM, History of CHD, mild DA, mild DP, mild FP, clumsy TM	Hypertension
Neurologic findings	Moderate DA, mild DP, mild FP, clumsy TM, sensory symptoms in perioral & thumb area	Moderate DA, mild DP, clumsy TM		Mild DA, mild FP, clumsy TM		Moderate DA, mild FP, clumsy TM
MR angiogram	Normal	Normal	Normal	Lt M2 occlusion (later recanalized)	Rt ICA stenosis	Normal
Treatment	Warfarin	Warfarin	Warfarin	Antiplatelet	Antiplatelet	Antihypertensives
Follow-up	9 Months	6 Months	10 Months	6 Months	1 Month	2 Months
Sequelae	Mild DA, tongue paresthesia	Mild DA	None	Mild DA	None	Mild DA

Af = atrial fibrillation; SM = cigarette smoking; PFO = patent foramen ovale; CHD = coronary heart disease; DA = dysarthria; DP = dysphagia; FP = facial paresis; TM = tongue movements.

difficulties or muscle weakness in the extremities. The patients were treated with anticoagulation agents (Patients 1–3) and antiplatelets (Patient 4 and 5). The severe carotid stenosis in Patient 5 (see below) was treated with angioplasty and stent insertion. The patients were followed up for 1 to 10 months, when four of them (Patients 1, 2, 4, and 6) had mild residual dysarthria. Patient 1 had remaining paresthesia at the center of his tongue. None experienced recurrent strokes.

**MRI and MRA findings.** MRIs were taken in 1 to 3 days after the onset of stroke. The MRI findings are presented in the figure. Five patients had infarction and one (Patient 6) had hemorrhage. The lesions were located on the left in five and on the right in one. In all patients with ischemic stroke, the lesions were detected by DWI but not by T2-weighted MRI. MRAs showed normal findings in four, severe ipsilateral proximal internal carotid artery stenosis in one (Patient 5), and occlusion of the M2 portion of the middle



**Figure.** Patients 1–5: Diffusion weighted MRIs show small cortical infarcts producing isolated dysarthria. White arrows (Patients 3 and 4) indicate cortical knob representing hand motor area. Patient 6: T2-weighted MRI shows a small cortical hemorrhage. (Numbers indicate patient numbers.)

cerebral artery in one (Patient 4). In Patient 4, a follow-up MRA 3 days later showed that the occluded vessel was recanalized.

**Discussion.** Our patients presented with isolated or nearly isolated dysarthria due to cortical stroke. The absence of mutism and the presence of impaired tongue movements differentiate our patients' symptoms from aphemia,<sup>7</sup> although the articulatory difficulty may be similar. The ischemic lesions of our five patients were identified by DWI but not by conventional T-2 weighted MRI, illustrating the superiority of DWI in detecting small, superficial cortical infarcts. Our results therefore suggest that the rarity of cortical stroke producing isolated dysarthria<sup>1,2</sup> is in part caused by technical difficulty in identifying small cortical infarcts that may not be differentiated from CSF space with T2-weighted MRI.

In Patients 3 and 4, we were able to identify the precentral knob, an alleged motor-representing area for the hand<sup>8</sup> (see the figure, white arrows). In these patients, the small infarcts were located lateral to the precentral knob. In others, the lesions were located at the most lateral cortical area in the level of the lateral ventricle. Some of the lesions are relatively large and probably include subcortical motor fibers, which could have possibly contributed to the dysarthria. However, the lesions are predominantly cortical and distinguished from previously reported subcortical infarcts producing pure dysarthria.<sup>1-3</sup> In our series, the majority of lesions were located on the left side, suggesting the presence of cerebral dominance in regulating bulbar muscles. Left-sided dominance was also observed in patients with isolated dysarthria due to subcortical lesions.<sup>3</sup> However, cerebral dominance was not observed in the previous report studying tongue deviation.<sup>9</sup>

The dysarthria of our patients was probably caused by central lower cranial nerve paresis.<sup>3</sup> However, the facial or soft palate muscle weakness was minimal, and all were able to protrude their tongues. Unexpectedly, obvious tongue deviation was not observed, although there were clumsy tongue movements. In a previous report,<sup>9</sup> 29% of 300 patients with stroke had tongue deviation, which was usually associated with large lesions producing marked facial/brachial paresis. Perhaps, the small lesions associated with minimal neurologic deficit may be

related to the absence or paucity of objective signs for the lower cranial nerve palsy in our patients.

Patient 3 additionally had transient weakness of the thumb, while Patient 1 had sensory symptoms restricted to the perioral area, tongue, and the tip of the thumb. Although the presence of sensory symptoms in Patient 1 may be related to an involvement of posteriorly located sensory cortex, this could not be documented by MRI alone. Nevertheless, involvement of a thumb but not other fingers seems to agree with the classic motor/sensory topography that thumb-representing region is adjacent to the facial area.<sup>10</sup>

Considering clinical findings, risk factors, and MRA results, an embolism from the heart (Patients 1-3) or internal carotid artery (Patient 5) was considered a likely pathogenesis. Although Patient 4 did not have emboligenic cardiac or proximal arterial diseases, relatively rapid recanalization of the M2 portion of the MCA suggested that an embolism was also a likely pathogenic mechanism. Thus, isolated dysarthria due to cortical infarction seems to be most often caused by emboli that probably occlude one of the distal branches of the MCA. Nevertheless, Patient 5 had hypertensive hemorrhage, illustrating the diversity of etiologies producing pure cortical dysarthria.

## References

1. Kim JS. Pure dysarthria, isolated facial paresis, or dysarthria-facial paresis syndrome. *Stroke* 1994;25:1994-1998.
2. Ichikawa K, Kageyama Y. Clinical anatomic study of pure dysarthria. *Stroke* 1991;22:809-812.
3. Urban PP, Wicht S, Hopf HC, Fleischer S, Nickel O. Isolated dysarthria due to extracerebellar lacunar stroke: a central monoparesis of the tongue. *J Neurol Neurosurg Psychiatry* 1999;66:495-501.
4. Albers GE, Lansberg MG, Norbash AM, et al. Yield of diffusion-weighted MRI for detection of potentially relevant findings in stroke patients. *Neurology* 2000;54:1562-1567.
5. Gass A, Szabo K, Behrens S, Rossmannith C, Hennerici M. A diffusion-weighted MRI study of acute ischemic distal arm paresis. *Neurology* 2001;57:1589-1594.
6. Kim JS, Chung JP, Ha SW. Isolated weakness of index finger due to small cortical infarction. *Neurology* 2002;58:985-986.
7. Ruff RL, Arbit E. Aphemia resulting from a left frontal hematoma. *Neurology* 1981;31:353-356.
8. Yousry TA, Schmid UD, Alkadhi H, et al. Localization of the motor and hand area to a knob on the precentral gyrus. *Brain* 1997;120:141-157.
9. Umapathi T, Venketasubramanian N, Leck KJ, Tan CB, Lee WL, Tjia H. Tongue deviation in acute ischemic stroke: a study of supranuclear twelfth cranial nerve palsy in 300 stroke patients. *Cerebrovasc Dis* 2000;10:462-465.
10. Penfield W, Boldrey E. Somatic motor and sensory representation in the cerebral cortex of man as studied by electrical stimulation. *Brain* 1937;60:389-443.

# Neurology<sup>®</sup>

## Pure dysarthria due to small cortical stroke

Jong S. Kim, Sun U. Kwon and Te G. Lee

*Neurology* 2003;60;1178-1180

DOI 10.1212/01.WNL.0000055930.28954.E9

This information is current as of April 8, 2003

<b>Updated Information &amp; Services</b>	including high resolution figures, can be found at: <a href="http://www.neurology.org/content/60/7/1178.full.html">http://www.neurology.org/content/60/7/1178.full.html</a>
<b>References</b>	This article cites 10 articles, 9 of which you can access for free at: <a href="http://www.neurology.org/content/60/7/1178.full.html#ref-list-1">http://www.neurology.org/content/60/7/1178.full.html#ref-list-1</a>
<b>Citations</b>	This article has been cited by 6 HighWire-hosted articles: <a href="http://www.neurology.org/content/60/7/1178.full.html#otherarticles">http://www.neurology.org/content/60/7/1178.full.html#otherarticles</a>
<b>Subspecialty Collections</b>	This article, along with others on similar topics, appears in the following collection(s): <b>All Cerebrovascular disease/Stroke</b> <a href="http://www.neurology.org/cgi/collection/all_cerebrovascular_disease_stroke">http://www.neurology.org/cgi/collection/all_cerebrovascular_disease_stroke</a> <b>Cranial neuropathy</b> <a href="http://www.neurology.org/cgi/collection/cranial_neuropathy">http://www.neurology.org/cgi/collection/cranial_neuropathy</a> <b>Infarction</b> <a href="http://www.neurology.org/cgi/collection/infarction">http://www.neurology.org/cgi/collection/infarction</a>
<b>Permissions &amp; Licensing</b>	Information about reproducing this article in parts (figures, tables) or in its entirety can be found online at: <a href="http://www.neurology.org/misc/about.xhtml#permissions">http://www.neurology.org/misc/about.xhtml#permissions</a>
<b>Reprints</b>	Information about ordering reprints can be found online: <a href="http://www.neurology.org/misc/addir.xhtml#reprintsus">http://www.neurology.org/misc/addir.xhtml#reprintsus</a>

*Neurology*® is the official journal of the American Academy of Neurology. Published continuously since 1951, it is now a weekly with 48 issues per year. Copyright . All rights reserved. Print ISSN: 0028-3878. Online ISSN: 1526-632X.

