



CASE STUDY

## Transient cerebral arteriopathy in infancy associated with enteroviral infection

PASCALE RIBAI,<sup>1</sup> CORINNE LIESNARD,<sup>2</sup> GEORGES RODESCH,<sup>3</sup> SANDA GIURGEA,<sup>4</sup>  
DENIS VERHEULPEN,<sup>1</sup> PHILIPPE DAVID,<sup>3</sup> PATRICK VAN BOGAERT<sup>1</sup>

<sup>1</sup>Department of Paediatric Neurology; <sup>2</sup>Department of Virology; <sup>3</sup>Department of Neuroradiology; Université Libre de Bruxelles, Hôpital Erasme, Brussels Belgium; <sup>4</sup>Department of Neurology, Centre Hospitalier Università de Tivoli, La Louvière, Belgium

We report the case of an 18-month-old boy who presented aphasia and right hemiplegia of acute onset. The neurological deficit completely resolved after a few hours, but identical transient neurological deficits and seizures occurred during the following days. Imaging showed proximal stenosis of the medial cerebral artery and deep ischaemic lesions in the territory of this artery. Analysis of the cerebrospinal fluid showed pleocytosis and an active enteroviral infection with positive RNA detection. The evolution was consistent with transient cerebral arteriopathy of childhood as magnetic resonance angiography showed normalization of the arterial lesions. This is the first report of an enteroviral infection associated with this entity. We want to stress the importance of performing a cerebrospinal fluid analysis when an ischaemic stroke of unclear aetiology occurs in a child.

*Keywords:* Stroke. Childhood. Virus. Enterovirus. Arteriopathy. Infection.

### Introduction

One-third to one-half of childhood ischaemic strokes occur without any predisposing factors.<sup>1,2</sup> A subgroup of these patients presents with a relatively homogenous clinico-radiological picture characterized by subcortical infarcts and angiographic abnormalities of the basal arteries of the carotid system. Because these lesions of the arterial walls stabilize or regress after weeks or months, this entity has been called 'transient cerebral arteriopathy'.<sup>3</sup> Viral infections, and more specifically varicella-zoster virus (VZV) infection, are incriminated in the pathophysiology of this entity. This hypothesis is supported by epidemiological data showing that VZV infection occurs significantly more frequently in the months preceding the stroke in these children than in age-matched controls<sup>4</sup> and by the identification of IgG against VZV in the cerebrospinal fluid (CSF) in some patients.<sup>5,6</sup> We report a case of this so-called transient cerebral arteriopathy where active enteroviral infection was demonstrated in the patient.

### Case report

VD, an 18-month-old boy, suddenly developed right hemiplegia and global aphasia. Both symptoms completely regressed after 1 hour. A second transient episode of right hemiplegia and aphasia occurred on the same day. The child was then admitted. The only relevant feature in his past history was a transient skin rash 1 month previously. His clinical examination on admission was completely normal; he was afebrile and there were no dermatological or digestive signs. Brain computerized tomography (CT) scan was normal. Electroencephalogram (EEG) did not show any epileptiform activity, making a diagnosis of epilepsy unlikely. However, on the next day, he presented several tonic-clonic seizures which were successfully treated with intravenous phenytoin. The neurological examination remained normal. A lumbar puncture showed 29 nucleated cells per mm<sup>3</sup> with 78% lymphocytes; glucose and proteins were within the normal range. Two days after admission, he presented a third episode of right

Received 5.8.02. Revised 15.1.03. Accepted 16.1.03.

Correspondence: Dr P Van Bogaert, Department of Pediatric Neurology, ULB-Hôpital Erasme, 808 route de Lennik, B-1070 Brussels, Belgium; Tel: +32-2555-4364; Fax: +32-2555-3942; e-mail: pvanboga@ulb.ac.be

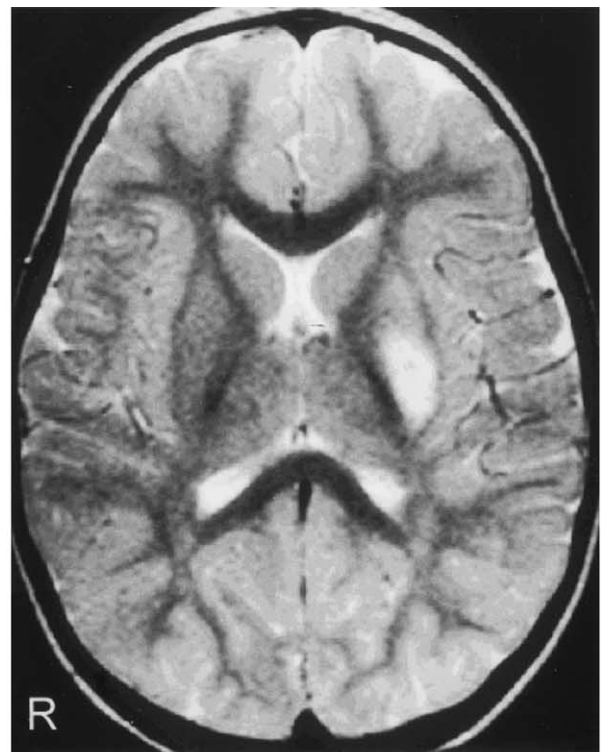
hemiplegia and aphasia. An intravenous anticoagulation treatment was then initiated, considering the possibility of recurrent embolisms. Again he completely recovered his deficits after 72 hours. Cardiac ultrasonography was normal and heparin was stopped after 7 days. Cranial magnetic resonance imaging (MRI) and angiography (MRA), performed respectively 2 and 9 days after the onset, showed a hypersignal lesion on T2-weighted images, likely to reflect an ischaemic lesion of the basal ganglia (Fig. 1a) and probable thrombosis of the left medial cerebral artery in its distal portion.

A search for viral infection was performed and included detection of viral material in the CSF using polymerase chain reaction (PCR) techniques and detection of antibodies in early and late sera. Enterovirus RNA was detected in the CSF using reverse transcriptase (RT)-PCR. PCR for herpes simplex virus (HSV) and VZV were negative. Determination of serum VZV antibodies indicated past contact with the virus (IgG 1/32–IgM 0). Early and late assessment of serum complement fixation antibodies toward an enteroviral antigenic pool and the six Coxsackie B antigens showed a significant rise of these antibodies from a titer of 1/2 in an early sample to 1/256 after 2 months, compatible with a recent enteroviral infection, most probably due to a Coxsackie B2 virus. Assessment for recent infection due to HSV, cytomegalovirus, *Borrelia burgdorferi*, Epstein–Barr virus, toxoplasma and measles was negative. Other blood tests including dosage of resistance to activated protein C, protein C, protein S, antithrombin type III, antiphospholipid antibodies, homocystein and lactic acid, were within the normal ranges. Profiles of plasma amino acids and urine organic acids were normal. Funduscopy and slit lamp examination were normal.

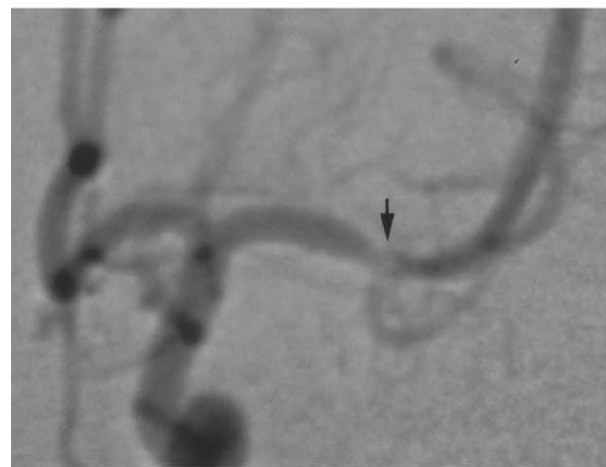Conventional arteriography performed 2 months after the onset showed narrowing of the left medial cerebral artery (Fig. 1b). The 2-year follow-up did not indicate any residual disability nor recurrence. MRA controlled after 1 year was completely normal.

## Discussion

We report a case of ischaemic stroke which fulfills the criteria for the so-called 'transient cerebral arteriopathy' as defined by Chabrier *et al.*<sup>3</sup> These include:



(a)



(b)

**Fig. 1.** (a) T2-weighted MR image showing hypersignal of the left lenticular nucleus. (b) Angiography after selective catheterism of the left internal carotid artery showing narrowing of the M1 segment of the sylvian artery (arrow).

- (1) localization of the infarcts in basal ganglia and internal capsule;
- (2) angiographic aspect characterized by the presence of multiple lesions (narrowing, occlusion) which are often unilateral and concern mainly the initial parts of basal arteries of the carotid system;

- (3) stabilization or regression of the lesions on angiographic follow-up: this discrete entity has been reported in children with ischaemic stroke, with an average age at onset of 5 years.<sup>3,6-11</sup>

Some cases of transient arteriopathy have been related to a VZV infection.<sup>3,6,9-13</sup> Our patient had evidence of previous VZV infection. However, the stroke was probably related to an enteroviral infection. Indeed, enteroviral RNA was identified in the CSF using RT-PCR and seroconversion against a Coxsackie B virus was documented. This is, to our knowledge, the first reported case of transient cerebral arteriopathy clearly associated with an enteroviral infection. Two previous reports of transient neurological deficits associated with an enteroviral infection documented by positive RT-PCR and pleocytosis in the CSF are reported in the literature, but in none of them are available neuroradiological data to support a diagnosis of transient cerebral arteriopathy.<sup>14,15</sup>

The mechanisms by which viral infections induce stroke are likely to be an inflammatory process of the arterial wall, as suggested by the angiographic findings. In the cases of VZV-associated stroke, reactivation of latent infection in the trigeminal ganglion and viral invasion of the blood vessels via the trigeminal axons has been proposed.<sup>13,16</sup> Other possible mechanisms are immune reactions secondary to distant infection or transient deficiency of protein S and protein C due to circulating auto-antibodies and immune complex formation.<sup>17</sup>

Pleocytosis in the CSF was observed in our patient. This further supports the viral aetiopathogenic hypothesis of this entity. Among 25 children with presumed VZV-associated ischaemic stroke, results of CSF analysis were mentioned in nine cases and an increase of cell count was observed in four cases.<sup>3,6,9-13</sup> As CSF analysis is not routinely performed in children with stroke, we would like to stress the need for performing an extensive infectious evaluation including cell count in the CSF, serum and CSF viral antibody research, and PCR for various possible viral pathogens of the central nervous system when the cause of the stroke remains unexplained.

## References

- Nicolaidis P, Appleton RE. Stroke in children. *Dev Med Child Neurol* 1996;**38**:172-80.
- Kirkham FJ, Prengler M, Hewes DK, *et al.* Risk factors for arterial ischemic stroke in children. *J Child Neurol* 2000;**15**:299-307.
- Chabrier S, Rodesch G, Lasjaunias P, *et al.* Transient cerebral arteriopathy: a disorder recognized by serial angiograms in children with stroke. *J Child Neurol* 1998;**13**:27-32.
- Sebire G, Meyer L, Chabrier S. Varicella as a risk factor for cerebral infarction in childhood: a case-control study. *Ann Neurol* 1999;**45**:679-80.
- Hausler MG, Ramaekers VT, Reul J, *et al.* Early and late onset manifestations of cerebral vasculitis related to varicella zoster. *Neuropediatrics* 1998;**29**:202-7.
- Caekbeke JF, Peters AC, Vandvik B, *et al.* Cerebral vasculopathy associated with primary varicella infection. *Arch Neurol* 1990;**47**:1033-5.
- Powell FC, Hanigan WC, McCluney KW. Subcortical infarction in children. *Stroke* 1994;**25**:117-21.
- Shirane R, Sato S, Yoshimoto T. Angiographic findings of ischemic stroke in children. *Childs Nerv Syst* 1992;**8**:432-6.
- Ichiyama T, Houdou S, Kisa T, *et al.* Varicella with delayed hemiplegia. *Pediatr Neurol* 1990;**6**:279-81.
- Kamholz J, Tremblay G. Chickenpox with delayed contralateral hemiparesis caused by cerebral angiitis. *Ann Neurol* 1985;**18**:358-60.
- Silverstein FS, Brunberg JA. Postvaricella basal ganglia infarction in children. *AJNR Am J Neuroradiol* 1995;**16**:449-52.
- Liu GT, Holmes GL. Varicella with delayed contralateral hemiparesis detected by MRI. *Pediatr Neurol* 1990;**6**:131-4.
- Ganesan V, Kirkham FJ. Mechanisms of ischaemic stroke after chickenpox. *Arch Dis Child* 1997;**76**:522-5.
- Wakamoto H, Ohta M, Nakano N, *et al.* SPECT in focal enterovirus encephalitis: evidence for local cerebral vasculitis. *Pediatr Neurol* 2000;**23**:429-31.
- Roden VJ, Cantor HE, O'Connor DM, *et al.* Acute hemiplegia of childhood associated with Coxsackie A9 viral infection. *J Pediatr* 1975;**86**:56-8.
- Eidelberg D, Sotrel A, Horoupian DS, *et al.* Thrombotic cerebral vasculopathy associated with herpes zoster. *Ann Neurol* 1986;**19**:7-14.
- Nguyen P, Reynaud J, Pouzol P, *et al.* Varicella and thrombotic complications associated with transient protein C and protein S deficiencies in children. *Eur J Pediatr* 1994;**153**:646-9.