

Rapid Spontaneous Resolution of Signs of Intracranial Herniation Due to Subdural Hematoma

—Case Report—

Kunihide IMAI

Department of Neurosurgery, Hokuetsu Hospital, Shibata, Niigata

Abstract

An 83-year-old female presented with signs of intracranial herniation due to subdural hematoma (SDH) which resolved rapidly and spontaneously. This patient showed bilateral decerebrate postures due to left SDH on admission. Since she had serious neurological symptoms and critical systemic conditions caused by an asthma attack, conservative treatment including osmotherapy and mechanical ventilation was performed instead of surgical intervention. Her signs of intracranial herniation resolved only 6 hours after admission. Although the SDH did not diminish rapidly, she showed excellent neurological improvement even with conservative treatment only. Characteristic serial changes on computed tomography corresponding to the neurological improvements were seen. She was discharged with slight right hemiparesis and slight dementia that were present prior to this admission. The rapid resolution of signs of intracranial herniation was attributable to the spontaneous diminution of SDH. The diminution or disappearance of hematomas probably depended on the redistribution of cerebrospinal fluid into the hematoma in the present case.

Key words: herniation signs, spontaneous resolution, natural history, subdural hematoma

Introduction

Rapid spontaneous resolution of signs of herniation is extremely rare, with only a very few reported cases.^{1,8,10,11,15)} Patients with signs of herniation should undergo immediate surgery to prevent uncal or central herniation. However, even successful surgical intervention does not prevent death or vegetative state in most patients with signs of herniation.^{10,11)} Here, we describe a patient with subdural hematoma (SDH) who developed signs of herniation that resolved 6 hours after admission with only conservative treatment.

Case Report

An 83-year-old female was transferred unconscious to our institute by ambulance. A few years previously, she appeared to have suffered from cerebral infarction and developed slight right hemiparesis. She had a previous history of asthma. She had never

suffered from hepatic diseases. Her coagulant factors such as prothrombin time, partial thromboplastin time, and platelet count were within the normal range.¹⁵⁾ There was no known history of head trauma. However, her family noticed that she had tended to fall to the right a few days previously. She became stuporous while sitting in her house. She was transferred to our hospital by ambulance about 30 minutes after the onset.

On admission, there were no signs of subcutaneous hematoma in the head. Her consciousness level was 6 (E1 V2 M3) according to the Glasgow Coma Scale (GCS). She manifested bilateral decerebrate postures. Both her pupils were fixed, measuring 4 × 4 mm at midpositions. Funduscopic examination found no retinal or preretinal bleeding. Skull radiography revealed no fractures. Computed tomography (CT) on admission revealed a subdural hematoma over the entire left cerebral hemisphere with a thickness of approximately 1.5 cm, and a low-density band between the hematoma and the

Received July 24, 2002; Accepted November 18, 2002

Author's present address: K. Imai, M.D., Department of Immunology and Zoology, Graduate School of Medicine, Niigata University, Niigata, Japan.

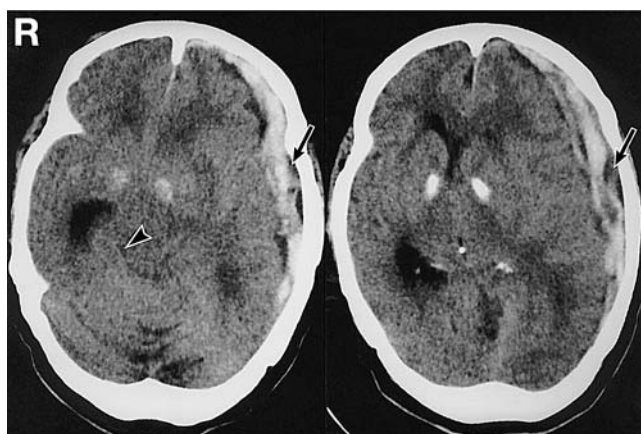


Fig. 1 Computed tomography scans performed immediately after admission revealing a subdural hematoma over the entire left cerebral hemisphere with a thickness of approximately 1.5 cm. A low-density band (arrow) was present between the hematoma and the inner wall of the skull bone. Almost complete obliteration of the contralateral ambient cistern (arrowhead) was seen in addition to marked shift of the midline structures to the right.

inner wall of the skull (Fig. 1). Almost complete obliteration of the contralateral ambient cistern was noted in addition to marked shift of the midline structures to the right. The left lateral ventricle was compressed, but no cerebral contusions were observed. Systematically, her respiration was characterized by wheezing and piping. Her arterial blood gas was PO_2 20.8 mmHg, PCO_2 45.8 mmHg, and SaO_2 32.4%. She seemed to have suffered an asthma attack. Her blood pressure on admission was 150/60 mmHg. Results of laboratory examinations including coagulation studies were within the normal range.

Taking her systemic conditions and neurological symptoms into consideration, we thought that open direct surgery would be dangerous. We decided to manage the patient conservatively under close observation. She was intubated and mechanically ventilated. Soon after the artificial ventilation was started, both pupils narrowed and became reactive. About 6 hours after admission, she could obey simple commands and her GCS score was 11 (E4 V1T M6). Two days after admission, she was weaned from artificial ventilation because of her excellent arterial blood gas data.

CT taken 2 days after admission revealed marked diminution of the hematoma (Fig. 2). The midline shift markedly improved and the contralateral

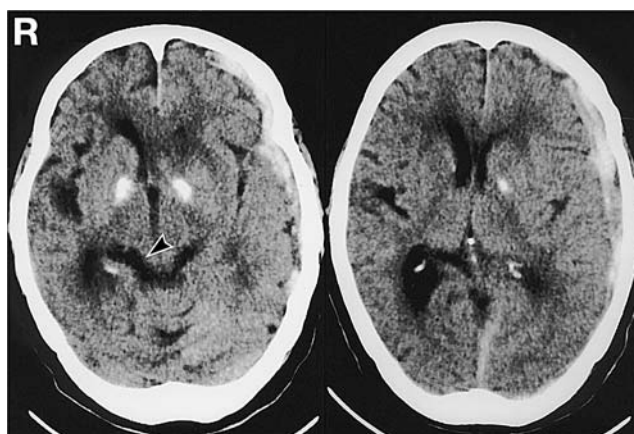


Fig. 2 Computed tomography scans taken 2 days after admission revealing marked diminution of the hematoma. The midline shift had partially improved and the contralateral ambient cistern (arrowhead) was identified.

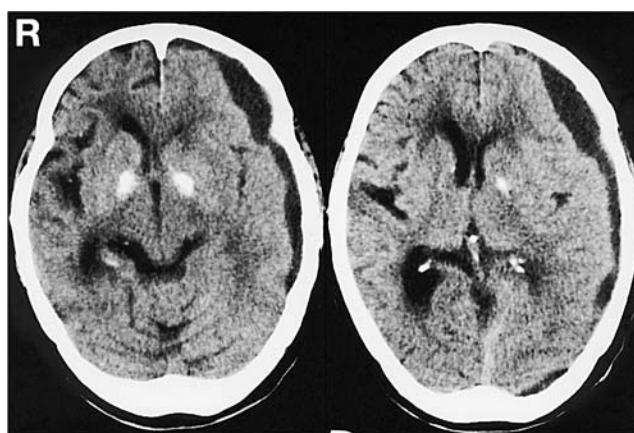


Fig. 3 Computed tomography scans taken 7 days after admission showing excellent decrease of the shift of the midline structures. The hematoma appeared as a low-density area.

ambient cistern could be identified. Four days after admission, she was extubated. During the treatment course, osmotherapy including intravenous administration of glycerol was performed instead of operative procedures. About 7 days after admission, she became almost alert. CT showed a marked decrease in the shift of the midline structures 7 days after admission (Fig. 3). After undergoing rehabilitation for about 2 months, she was discharged with slight right hemiparesis, similar to that noted prior to admission. Forty-five days after admission, CT demonstrated complete disappearance of the SDH.

Table 1 Cases of acute subdural hematoma with relatively rapid resolution

Author (Year)	Age/ Sex	Previous history	Side	Herniation signs	Interval*	Low- density band	Contusion	Acute brain swelling	Skull fracture	Way of diagnosis	Treatment	Outcome
Makiyama et al. (1985) ⁽¹⁰⁾	61 yrs/F	no	lt	mydriasis	3 days	yes	yes	yes	NC	CT	mechanical ventilation	dead
Nagao et al. (1986) ⁽¹³⁾	17 yrs/F	no	rt	no	12 hrs	no	yes	yes	NC	CT	conservative	GR
Polman et al. (1986) ⁽¹⁶⁾	3 yrs/F	Klippel-Weber	rt	no	2 days, 17 hrs	yes	no	no	no	CT	conservative	GR
	26 yrs/F	no	rt	NC	6 hrs	no	yes	yes	NC	CT, MR imaging	mechanical ventilation, mannitol	GR
Niikawa et al. (1989) ⁽¹⁵⁾	63 yrs/M	cirrhosis	rt	no	1 day	yes	no	no	no	CT	conservative	GR
	16 yrs/M	no	lt	mydriasis	2 days	yes	no	no	no	CT	barbiturate	MD
	27 yrs/F	no	lt	no	6 hrs	yes	lt temporal	no	no	CT	conservative	GR
	48 yrs/M	no	rt	anisocoria	6 hrs	no	bifrontal	yes	yes	CT	craniectomy	GR
Arai et al. (1990) ⁽¹⁾	8 mos/M	no	lt	anisocoria	3 days	yes	no	no	NC	CT	glycerol	GR
	8 mos/M	no	rt	anisocoria	5 days	no	no	no	NC	CT	conservative	GR
Joki et al. (1992) ⁽⁶⁾	21 yrs/F	no	lt	no	8 hrs	yes	no	yes	no	CT	conservative	GR
	23 yrs/M	no	lt	no	24 hrs	no	no	yes	no	CT	conservative	GR
Matsuyama et al. (1997) ⁽¹¹⁾	18 yrs/M	no	lt	anisocoria	3 hrs	yes	no	no	no	CT	mannitol	GR
Suzuki et al. (1998) ⁽¹⁷⁾	7 yrs/M	no	rt	no	3 hrs	yes	no	no	no	CT, MR imaging	conservative	GR
	60 yrs/M	diabetes mellitus	lt	no	12 hrs	yes	yes	no	no	CT, MR imaging	conservative	GR
Kimura et al. (2000) ⁽⁸⁾	88 yrs/F	no	lt	anisocoria	4 days	yes	no	no	no	CT	trephination	MD
Present case	83 yrs/F	no	lt	mydriasis	1 wk	yes	no	no	no	CT	mechanical ventilation, glycerol	GR

*Interval between the onset and disappearance of acute subdural hematoma. CT: computed tomography, GR: good recovery, MD: moderately disabled, MR: magnetic resonance, NC: not commented.

Discussion

Initially, we must demonstrate that the present patient manifested signs of herniation including bilateral decerebrate postures due to the mass effect of the SDH and not to the systemic hypoxia. If the neurological symptoms of this patient were induced by systemic hypoxia, she would manifest flaccid paralysis in her extremities with bilateral mydriasis instead of decerebrate posture. Decerebrate posture is a neurological symptom that indicates discontinuity between the cerebral hemispheres and brain stem of the patient. Presumably systemic hypoxia cannot cause this discontinuity selectively. In addition, CT on admission demonstrated disappearance of the contralateral ambient cistern due to SDH despite the atrophic brain (Fig. 1). Therefore, we considered that the signs of herniation were caused by the mass effect of SDH and not by systemic hypoxia.

Secondly, we must differentiate whether the hematoma of our patient was acute SDH (ASDH) or chronic SDH (CSDH). Our patient may have suffered rebleeding into CSDH, resulting in the manifestation of signs of herniation.^{5,7,14} However, no rapid spontaneous resolution of signs of herniation has been associated with CSDH.^{5,7,14} Otherwise, some slight trauma may have caused tearing of a bridging vein, resulting in bleeding into the posttraumatic hygroma which is considered the precursor to CSDH.¹² The traumatic hygroma communicates with the subarachnoid space through an arachnoid tear in most cases.⁴ Based on this speculation, we suggest that the low-density area was posttraumatic hygroma and not subdural effusion, although we have no intraoperative confirmation.

All reported cases of spontaneous resolution of signs of herniation were associated with ASDH.^{1,8,10,11,15} Therefore, the mechanism of the resolution is likely to be related to the diminution of ASDH.^{1,3,6,8-11,13,15-17} However, the reason why such spontaneous resolution occurs in the cases of ASDH and no in those of CSDH remains unknown.^{5,7,14}

ASDH usually disappears relatively rapidly, but posttraumatic hygroma may develop during the course. Probably small vessels with numerous fenestrations of the neomembrane result in leakage of serum fluid with resultant enlargement of the subdural hygroma.⁴

Spontaneous resolution of signs of herniation due to SDH (mainly ASDH) within 24 hours is extremely rare and may be related to a rapid decrease in intracranial pressure.² The signs of herniation in our patient observed on admission resolved within only 6 hours. Only eight of the many case reports on the

disappearance and diminution of ASDH described the resolution of signs of herniation.^{1,8,10,11,15} (Table 1). The ASDH in most previous cases disappeared completely within 24 hours after the onset.^{6,10,11,13,15-17} However, in our case, the hematoma took more than one week to disappear completely. Considering this length of time, our case might be in a different category. We have never previously observed rapid clinical improvement and spontaneous resolution of signs of herniation in patients with SDH.

The mechanism underlying the rapid resolution of SDH (mainly ASDH) is both interesting and somewhat inexplicable.¹⁴ Dura mater tears or skull fractures may allow the clot to be pushed into the diploic bone of the skull or soft tissues, where it may be more rapidly absorbed.³ However, skull radiography showed no fractures in our patient. Other cases of spontaneous disappearance of ASDH have been reported.^{6,11,13,15,17}

We consider that the mechanism of the signs of herniation may have involved the fluid collection.^{1,6,8,10,11,15} The hematoma may have been diluted by cerebrospinal fluid due to the tearing of the arachnoid and then washed out.¹¹ In some cases, the low-density area between the hematoma and the inner wall of the skull was designated as a low-density band.^{8,10,13,17} The low-density band may suggest the flow of cerebrospinal fluid into the subdural space, which indicates a good outcome for patients with ASDH.^{3,10,11,13,15} This low-density band was also noted in our patient. We considered that this band was related to the mechanism of diminution of SDH in the acute stage.

Conservative treatment of patients with ASDH is certainly not preferable to operative procedures.^{3,10} However, conservative therapy can be justified in some cases depending on observations of the clinical state,¹⁶ especially if an operative procedure cannot be performed because of the critical conditions of the patient. The prognosis is not necessarily pessimistic.^{9,11,13,15-17}

References

- 1) Arai H, Ohba M, Onuma T: [Rapid spontaneous resolution of acute infantile subdural hematoma. A report of two cases]. *Shoni No No Shinkei* 15: 155-159, 1990 (Jpn, with Eng abstract)
- 2) Clifton GL, Grossman RG, Makela ME, Miner ME, Handel S, Sadhu V: Neurological course and correlated computerized tomography findings after severe closed head injury. *J Neurosurg* 52: 611-624, 1980
- 3) Fujioka S, Hamada J, Kaku M, Ushio Y: [Rapid resolution of acute subdural hematoma. Report of two cases]. *Neurol Med Chir (Tokyo)* 30: 827-831, 1990

- (Jpn, with Eng abstract)
- 4) Hasegawa M, Yamashita T, Yamashita J, Suzuki M, Shimada S: Traumatic subdural hygroma: pathology and meningeal enhancement on magnetic resonance imaging. *Neurosurgery* 31: 580-585, 1992
 - 5) Horimoto C, Miyazaki T, Miyazaki H, Kawano M: [Clinical study of reaccumulation and persistence of chronic subdural hematoma; setting an Ommaya reservoir]. *No Shinkei Geka* 18: 507-510, 1990 (Jpn, with Eng abstract)
 - 6) Joki T, Hashimoto T, Akachi K, Boku M, Suzuki K, Nakamura N: [Rapid resolution of acute subdural hematoma: Report of two cases]. *No Shinkei Geka* 20: 915-919, 1992 (Jpn, with Eng abstract)
 - 7) Kao MC: Sedimentation level in chronic subdural hematoma visible on computerized tomography. *J Neurosurg* 58: 246-251, 1983
 - 8) Kimura H, Nogaki H, Sawa H, Tamaki N: [Rapid spontaneous resolution of a severe acute subdural hematoma in an elderly woman]. *No Shinkei Geka Journal* 9: 561-564, 2000 (Jpn, with Eng abstract)
 - 9) Kuroiwa T, Tanabe H, Takatsuka H, Arai M, Sakai N, Nagasawa S, Ohta T: Rapid spontaneous resolution of acute extradural and subdural hematomas. *J Neurosurg* 78: 126-128, 1993
 - 10) Makiyama Y, Katayama Y, Ueno Y, Koike Y, Tsubokawa T: Acute subdural hematomas spontaneously disappearing within 3 days following closed head injury. *Nihon Univ J Med* 27: 123-127, 1985
 - 11) Matsuyama T, Shimomura T, Okumura Y, Sakaki T: Rapid resolution of symptomatic acute subdural hematoma: case report. *Surg Neurol* 48: 193-196, 1997
 - 12) Mori K, Maeda M: Delayed magnetic resonance imaging with Gd-DTPA differentiates subdural hygroma and subdural effusion. *Surg Neurol* 53: 303-311, 2000
 - 13) Nagao T, Aoki N, Mizutani H, Kitamura K: Acute subdural hematoma with rapid resolution in infancy. *Neurosurgery* 19: 465-467, 1986
 - 14) Nakashima H, Tomita S, Yoshino K, Norikane H, Baba Y, Doi A, Tsuboi S: [A case of chronic subdural hematoma in a hemodialyzed patient]. *No Shinkei Geka* 14: 675-679, 1986 (Jpn, with Eng abstract)
 - 15) Niikawa S, Sugimoto S, Hattori T, Ohkuma A, Kimura T, Shinoda J, Funakoshi T: Rapid resolution of acute subdural hematoma. *Neurol Med Chir (Tokyo)* 29: 820-824, 1989
 - 16) Polman CH, Gijsbers CJ, Heimans JJ, Ponssen H, Valk J: Rapid spontaneous resolution of an acute subdural hematoma. *Neurosurgery* 19: 446-448, 1986
 - 17) Suzuki Y, Kawamata T, Matsumoto H, Kunii N, Matsumoto K: [A resolving sign of acute subdural hematoma: from report of two cases]. *No Shinkei Geka* 26: 1025-1029, 1998 (Jpn, with Eng abstract)

Address reprint requests to: K. Imai, M.D., Department of Immunology and Zoology, Graduate School of Medicine, Niigata University, 1-757 Asahimachi-dori, Niigata 951-8585, Japan.