

Pediatric Blunt Carotid Injury

—Case Report—

Shinya OSHIRO, Hirokazu OHNISHI, Mika OHTA, and Hirohito TSUCHIMOCHI

Department of Neurosurgery, Sasebo Central Hospital, Sasebo, Nagasaki

Abstract

A 5-year-old boy was struck by a pickup truck, and admitted with Glasgow Coma Scale score of 14. Initial computed tomography (CT) showed no evidence of intracerebral lesions except for a skull fracture. Repeat CT 5 hours later showed hyperdense middle cerebral artery (MCA) sign, but he did not show any focal signs. Eighteen hours after the accident, he developed left hemiparesis. CT revealed a fresh infarction in the right MCA territory, associated with definite hyperdense MCA sign. He was immediately transferred to our hospital for further evaluation. Emergent angiography revealed a rat tail-shaped occlusion of the right internal carotid artery at the C-3 level. Cross-filling of the right MCA territory was insufficient for collateral circulation. He was treated conservatively because of the significant risk of hemorrhagic change from the established infarction. His hemiparesis improved gradually, and he was discharged on foot. Hyperdense MCA sign in a child is an important clinical sign for the early detection of cerebral ischemia after blunt carotid injury, before any focal signs appear.

Key words: blunt carotid injury, child, dissecting occlusion, hyperdense middle cerebral artery sign

Introduction

Blunt carotid injury is a rare but potentially devastating traumatic insult, causing mortality of between 20% and 40%, and permanent neurological deficits in 40–80% of the patients.^{9,12)} The outcome is thought to be compromised by diagnostic delay. The importance of early detection and treatment is well known, but most patients do not present with focal signs or symptoms and frequently have a multitude of other severe injuries, further confusing, and delaying the diagnostic work-up.^{3–5,7,8,15,19)}

We describe a pediatric case of blunt carotid injury in which hyperdense middle cerebral artery (MCA) sign was detected by computed tomography (CT) before the patient showed any focal signs.

Case Report

A 5-year-old boy was struck by a pickup truck, and admitted to a hospital near the accident scene. He had a Glasgow Coma Scale score of 14 (E3, V5, M6), and could move all four extremities equally. His injuries included a right clavicle fracture, local head

lacerations of the frontal and occipital regions, and skin abrasions of the upper limbs. CT showed no evidence of intracerebral lesions except for a fracture of the right occipital bone (Fig. 1A). He was observed conservatively. CT was repeated 5 hours later for early detection of delayed traumatic injuries, and detected a high-density area at the horizontal portion of right MCA (Fig. 1B). However, he did not show any focal signs at that time. Eighteen hours after the accident, he developed left hemiparesis. Further CT revealed a fresh infarction appearing as low-density areas associated with a clear high-density appearance at the main trunk of the MCA, which is known as hyperdense MCA sign (Fig. 2). The patient was immediately transferred to our hospital due to the strong suspicion of occlusive vascular lesions after blunt carotid injury.

On admission, neurological examination found he was slightly confused with moderate left hemiparesis. There was no hematoma or swelling on his neck. Urgent cerebral angiography under general anesthesia demonstrated that the right internal carotid artery (ICA) was tapered to occlusion in the proximal portion at the C-3 level (Fig. 3A). The right

Received July 31, 2002; Accepted November 18, 2002

Author's present address: S. Oshiro, M.D., Department of Neurosurgery, Okinawa Prefectural Miyako Hospital, Hirara, Okinawa, Japan.

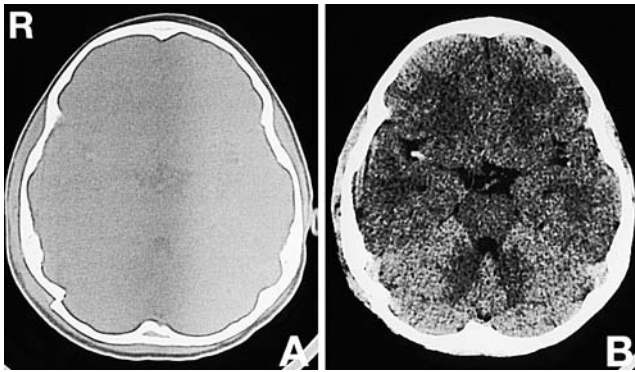


Fig. 1 (A) Initial bone window computed tomography (CT) scan showing displacement of the fractured right occipital bone. (B) CT scan of the brain taken 5 hours later showing a small high-density component at the horizontal portion of the right middle cerebral artery but without intracerebral lesions.

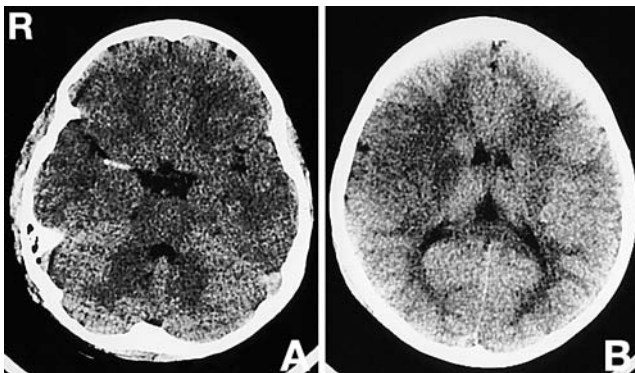


Fig. 2 Emergent computed tomography scans just after the development of left hemiparesis showing (A) a clear high-density appearance at the main trunk of the right middle cerebral artery (MCA) or hyperdense MCA sign, and (B) fresh infarction appearing as low-density areas in the territory of the right MCA.

anterior and posterior cerebral arteries were partially filled via the communicating arteries, but no rapid cross-filling of the right MCA territory could be confirmed (Fig. 3B). He was treated conservatively with osmotic diuretic agent and dextran because of the confirmed low-density lesions. Anticoagulation or thrombolysis therapy and surgical intervention could not be undertaken due to the significant risk of life-threatening hemorrhage from the established infarction. His hemiparesis improved gradually, and

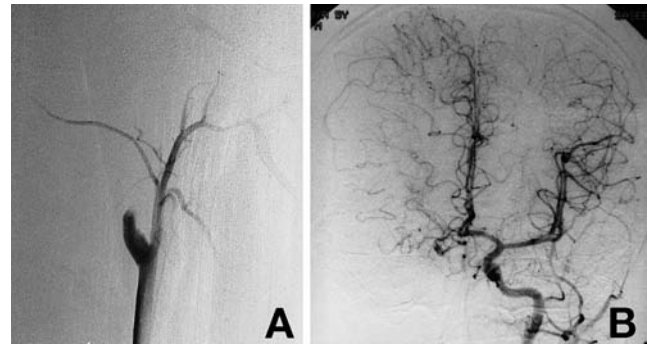


Fig. 3 Conventional angiograms taken under general anesthesia. (A) Lateral right common carotid arteriogram demonstrating rat tail-shaped tapering of the proximal internal carotid artery, indicating a dissecting occlusion. (B) Anteroposterior left common carotid arteriogram demonstrating little cross-filling of the right middle cerebral artery territory.

by post-trauma day 10 he was able to walk briefly without assistance. Magnetic resonance (MR) angiography on day 31 revealed a rat tail-shaped occlusion of the ICA similar to that found by the previous angiography. He was discharged on foot on post-trauma day 67.

Discussion

Conventional CT is the first diagnostic test performed in patients with stroke. However, CT often detects no abnormalities during the first few hours after onset of cerebral ischemia. Early signs of MCA infarction include hyperdense MCA sign, loss of the "insular ribbon," and hemispheric sulcus enhancement. Hyperdense MCA sign is an indirect sign indicating an intraluminal clot from a thrombus or embolus.^{11,13,16,21} Interpretation of hyperdense MCA sign requires caution, because it may not represent vascular occlusion. A false sign of occlusion can be produced by calcification in the vessel walls, which is often associated with both diabetes mellitus and hypertension.¹⁷ However, unilateral hyperdense MCA sign in a child cannot be caused by calcification. In our case, the second CT performed on initial hospitalization demonstrated hyperdense MCA sign before any focal signs had appeared, suggesting the presence of low perfusion in the MCA territory.

Blunt carotid injury is rarely reported in the pediatric population.^{6,10} The incidence appears to be markedly less in children compared to adults, which may be a reflection of physiologic and anatomic differences including increased vascular

elasticity.¹⁰⁾ However, the overall mortality shows no clear differences between pediatric and adult cases.¹⁰⁾ Associated injuries are common and frequently include closed head injuries, chest trauma, and long bone fractures. In particular, clavicle fractures are associated with an eight-fold increased risk of blunt carotid injury, presumably because of the proximity to the great vessels of the neck.¹¹⁾ In our case, an earlier definitive diagnosis of blunt carotid injury should have been made at the initial hospitalization based upon careful evaluation of the radiographic findings and coexistence of the associated injuries.

The definitive diagnosis of carotid artery occlusion is generally based on angiography, but may not be appropriate in all patients. Therefore, various noninvasive techniques, such as ultrasonography, MR angiography, and three-dimensional CT angiography, have been used to screen patients with a high index of clinical suspicion.^{2,14,18,22)} However, these noninvasive techniques are less sensitive than conventional angiography. In our case, angiography was performed to confirm the diagnosis of occlusive carotid lesions and the collateral blood supply.

The management or treatment of patients with blunt carotid injury is influenced by both the diversity of injury types (dissections or thrombosis) and hemodynamic considerations.^{4,14,15)} The objective is to prevent the development of neurological events resulting from thrombosis, propagation of clots, thromboembolism, or vessel occlusion. In patients without complete occlusion of the carotid artery, systemic anticoagulation is used to prevent arterial thrombosis and embolization. Moreover, surgical repair with or without bypass graft and interventional stenting may have a specific role in the treatment of nonocclusive lesions.^{1,4,8,14,15,20)} In the present case, an earlier definitive diagnosis of blunt carotid injury could have prevented or reduced the cerebral ischemia by indicating systemic anticoagulation or endovascular stenting. On the other hand, the outcome in patients with complete occlusion is unpredictable because of the individual variations in the anatomy of the collateral circulation and the circle of Willis. High mortality and poor outcomes for patients with occlusive lesions are generally correlated to the initial degree of neurological dysfunction.⁴⁾ It is unclear whether any management or therapy can change the poor prognosis, especially since many of these patients are considered too high risk for anticoagulation therapy. An extracranial-intracranial bypass procedure might lead to a better outcome if early CT findings of ischemia are not demonstrated.

Early diagnosis of blunt carotid injury is impor-

tant, but is often difficult in practice. Hyperdense MCA sign in a child may be a helpful diagnostic indicator for the early detection of cerebral ischemia after blunt carotid injury before any focal signs appear. Earlier definitive diagnosis and better treatment decisions can lead to improved neurological outcomes in patients with a strong suspicion of blunt carotid injury.

References

- 1) Biffi WL, Moore EE, Ryu RK, Offner PJ, Novak Z, Coldwell DM, Franciose RJ, Burch JM: The unrecognized epidemic of blunt carotid arterial injuries: early diagnosis improves neurologic outcome. *Ann Surg* 228: 462-470, 1998
- 2) Bok APL, Peter JC: Carotid and vertebral artery occlusion after blunt cervical injury: the role of MR angiography in early diagnosis. *J Trauma* 40: 968-972, 1996
- 3) Carrillo EH, Osborne DL, Spain DA, Miller FB, Senler SO, Richardson JD: Blunt carotid artery injuries: difficulties with the diagnosis prior to neurologic event. *J Trauma* 46: 1120-1125, 1999
- 4) Cogbill TH, Moore EE, Meissner M, Fischer RP, Hoyt DB, Morris JA, Shackford SR, Wallace JR, Ross SE, Ochsner MG, Sugerman HJ: The spectrum of blunt carotid injury to the carotid artery: a multicenter perspective. *J Trauma* 37: 473-479, 1994
- 5) Davis JW, Holbrook TL, Hoyt DB, Mackersie RC, Field TO, Shackford SR: Blunt carotid artery dissection: incidence, associated injuries, screening, and treatment. *J Trauma* 30: 1514-1517, 1990
- 6) Duke BJ, Partington MD: Blunt carotid injury in children. *Pediatr Neurosurg* 25: 188-193, 1996
- 7) Fabian TC: Carotid artery trauma: management based on mechanism of injury. *J Trauma* 30: 953-963, 1990
- 8) Fabian TC, Patton JH, Croce MA, Minard G, Kudsk KA, Pritchard FE: Blunt carotid injury: importance of early diagnosis and anticoagulant therapy. *Ann Surg* 223: 513-525, 1996
- 9) Fakhry SM, Jaques PF, Proctor HJ: Cervical vessel injury after blunt trauma. *J Vasc Surg* 8: 501-508, 1988
- 10) Lew SM, Fruminento C, Wald SL: Pediatric blunt carotid injury: a review of the National Pediatric Trauma Registry. *Pediatr Neurosurg* 30: 239-244, 1999
- 11) Leys D, Pruvo JP, Godefroy O, Rondepierre P, Leclerc X: Prevalence and significance of hyperdense middle cerebral artery in acute stroke. *Stroke* 23: 317-324, 1992
- 12) Martin RF, Eldruo-Jorgensen J, Clark DE, Bredenberg CE: Blunt trauma to the carotid arteries. *J Vasc Surg* 14: 789-795, 1991
- 13) Moulin T, Cattin F, Crepin-Leblond T, Tatu L, Chavot D, Piotin M, Viel JF, Rumbach L, Bonneville

- JF: Early CT signs in acute middle cerebral artery infarction: predictive value for subsequent infarct locations and outcome. *Neurology* 47: 366-375, 1996
- 14) Okada Y, Shima T, Nishida M, Yamane K, Kagawa R: Traumatic dissection of the common carotid artery after blunt injury to the neck. *Surg Neurol* 51: 513-520, 1999
 - 15) Parikh AA, Luchette FA, Valente JF, Johnson RC, Anderson GL, Blebea J, Rosenthal GL, Hurst JM, Johannigman JA, Davis K Jr: Blunt carotid artery injuries. *J Am Coll Surg* 185: 80-86, 1997
 - 16) Petitti N: The hyperdense middle cerebral artery sign. *Radiology* 208: 687-688, 1998
 - 17) Rauch RA, Bazan C III, Larsson EM, Jinkins JR: Hyperdense middle cerebral arteries identified on CT as a false sign of vascular occlusion. *AJNR Am J Neuroradiol* 14: 669-673, 1993
 - 18) Rogers FB, Baker EF, Osler TM, Shackford SR, Wald SL, Vieco P: Computed tomographic angiography as a screening modality for blunt cervical arterial injuries: preliminary results. *J Trauma* 46: 380-385, 1999
 - 19) Rubio PA, Ruel JG Jr, Beall AC Jr, Jordan GL Jr, Debaek ME: Acute carotid artery injury: 25 years' experience. *J Trauma* 14: 967-973, 1974
 - 20) Vishteh AG, Marciano FK, David CA, Schievink WI, Zabramski JM, Spetzler RF: Long-term graft patency rates and clinical outcomes after revascularization for symptomatic traumatic internal carotid artery dissection. *Neurosurgery* 43: 761-768, 1998
 - 21) von Kummer R, Meyding-Lamade U, Forsting M, Rosin L, Rieke K, Hacke W, Sartor K: Sensitivity and prognostic value of early CT in occlusion of the middle cerebral artery trunk. *AJNR Am J Neuroradiol* 15: 9-18, 1994
 - 22) Weller SJ, Rossitch E Jr, Malek AM: Detection of vertebral artery injury after cervical spine trauma using magnetic resonance angiography. *J Trauma* 46: 660-666, 1999

Address reprint requests to: S. Oshiro, M.D., Department of Neurosurgery, Okinawa Prefectural Miyako Hospital, 807 Higashi-Nakasone, Hirara, Okinawa 906-0007, Japan.
e-mail: oshiro_shinya@hosp.pref.okinawa.jp.