

Luca Massimi
Jacques Moret
Giampiero Tamburrini
Concezio Di Rocco

Dissecting giant vertebro-basilar aneurysms

Received: 23 January 2003
Published online: 25 March 2003
© Springer-Verlag 2003

L. Massimi (✉) · G. Tamburrini
C. Di Rocco
Pediatric Neurosurgery,
Catholic University School of Medicine,
Largo A. Gemelli, 8, 00168 Rome, Italy
e-mail: lucamax30@hotmail.com
Tel.: +39-06-30154587

J. Moret
Service de Neuroradiologie
Interventionnelle,
Fondation Ophthalmologique Rothschild,
Paris, France

Abstract *Object:* Vertebro-basilar dissecting aneurysms (VDAs) are very rare in children. Strokes or subarachnoid hemorrhage are characteristic clinical manifestations, but often only non-specific symptoms are found. Radiological diagnosis may be difficult to obtain and therapy hard to perform. We report on a child who presented with an intracranial mass effect due to a giant VDA.

Methods: The patient was a 8-year-old girl with right hemiparesis, ataxia, dysphagia and dysphonia and worsening of her neurological deficits. Neuroimaging discovered a giant dissecting aneurysm arising from the left vertebral artery and involv-

ing the vertebro-basilar junction. Endovascular treatment by coil embolization was performed. The post-operative course initially showed a remarkable improvement in her clinical condition. Afterwards, she developed cerebral hemorrhage and died. *Conclusion:* VDAs may have an unusual presentation and their therapy still remains a challenge. Endovascular embolization is a valid option but, as it is surgery, it may cause the death of the patient.

Keywords Dissecting aneurysm · Intracranial vertebral artery · Therapy · Endovascular embolization

Background

Introduction

Dissection of intracranial arteries may result in a dissecting aneurysm (aneurysmal dilatation of the artery caused by the presence of blood within its wall) [49]. The vertebral artery is the most common intracranial site of such a process, followed by the basilar artery, the internal carotid artery, and the middle cerebral artery [8]. The vertebral arteries also represent the most frequent vessels involved in multiple dissections [30, 51]. Males are more frequently affected than females [50].

In spite of being increasingly recognized in adults [25], intracranial vertebro-basilar dissecting aneurysms (VDAs) are extremely rare in the pediatric population [19, 35, 37, 41, 43] and their definition is still under discussion. However, they may be associated with severe morbidity and mortality because of the possibility of

generating strokes. Strokes are quite frequent in children with VDAs because of a secondarily reduced distal flow (narrowing of the arterial lumen as a consequence of the growth of an intramural hematoma or thrombosis) or embolic phenomena [4, 12, 32]. Subarachnoid hemorrhage is uncommon in children in comparison with adults [4, 9, 27]. Subarachnoid hemorrhage has not significantly influenced the outcome in some series [49], while in others it is thought to be responsible for a grim prognosis [33]. Subclinical manifestations may occur [4].

Bilateral dissection and the initial severity of the stroke are the two deciding factors for poor prognosis in patients with VDAs [4]. Also, the location may affect the outcome, since, for instance, basilar artery dissecting aneurysms have a worse prognosis than vertebral ones [8]. According to Yamaura et al. [50], a favorable outcome can be found in 60% of surgical cases, with moderate to severe disability in 35%, and a poor outcome in 5%. Mortality rate has decreased in the last few years [31]

compared with past years [3], but overall mortality still remains high (26%) [49].

Etiopathogenesis

Although “spontaneous” VDAs have been reported by several authors [12, 23, 37, 45, 50], trivial injuries cannot be excluded so that the real incidence of “true spontaneous” dissections remains obscure. Actually, fibromuscular dysplasia [2, 23, 39] and other risk factors, such as inheritance of intracranial aneurysms [36, 40], connective tissue disorders such as Marfan’s syndrome [35, 36, 38], Moyamoya disease [48], systemic lupus erythematosus [9], syphilitic arteritis, poliarteritis nodosa, degeneration of the media [8], and oral contraceptives [23] are frequently found in cases of “spontaneous” extra- or intracranial dissections.

Trauma represents the most common predisposing factor for VDAs during childhood. Posttraumatic dissections can share etiology with one or more of the previously mentioned factors. Posttraumatic VDAs often result from minor cranio-cervical injuries such as blunt trauma [50], sporting and playing activities or neck manipulation [26, 33]. They may also be secondary to road accidents or iatrogenic injuries (surgical manipulation or endovascular procedures).

An initial transmural bleeding, with secondary hematoma formation into the vessel wall (subintimal, intramedial or subadventitial) is thought to lead to the aneurysmatic dilatation of the artery. Subarachnoid hemorrhage generally arises from subadventitial dissection (with or without luminal connection), while arterial lumen occlusion may be the consequence of a subintimal hematoma [6, 10]. Sometimes, hemorrhage occurs into an atheromatous plaque [6]. Besides atherosclerosis, associated histopathological findings are represented by cystic or mucoid medial degeneration, adventitial neovascularization, disruption of internal elastic lamina and media [6, 34, 52]. In particular, disruption of internal elastic lamina seems to play an important role in the genesis of nonatherosclerotic cerebral dissecting aneurysms [28].

Clinical presentation

The usual clinical manifestations of VDAs in children are represented by neurological symptoms following transient ischemic attacks (vertigo, transient loss of consciousness, unilateral facial paresthesia, visual field defects) or strokes (hemiparesis, cranial nerve palsy, Wallemborg’s syndrome, ataxia), which result from brainstem, thalamic, cerebellar or cerebral infarcts [5, 7, 15, 24, 33, 35]. Another possible clinical presentation is recurrent torticollis [11]. Signs and symptoms of subarachnoid hemorrhage in children are observed less commonly than in the adult population [3, 4, 9, 16].

The main symptoms of VDA in the pediatric age are severe headaches and neck pain [11, 13, 33, 35]. Headaches are often the first symptom of arterial dissection and can precede neurological disturbances by days or up to months [24, 42]. Headaches may be recurrent, steady or pulsating, and generally ipsilateral to the side of dissection [42, 50]. They may occur acutely and be severe after a major head injury; in other instances, they may remain subtle, such as in the case of a minor trauma. Neck pain is a frequent manifestation of VDAs [33] and it may also occur as an isolated symptom [21]. This phenomenon is often misinterpreted as being due to musculoskeletal disorders and acquires significance only when neurological deficits appear [11].

Vertebro-basilar dissecting aneurysms can exert an intracranial mass effect affecting cerebellar, brainstem or cranial nerve functions [8, 11, 13]: in this instance, a giant dissecting aneurysm may be found [29].

Evaluation and management

The recognition of VDAs may be delayed because of nonspecific symptoms and/or difficult differential diagnosis with other cerebral posterior circulation disorders [4, 7]. On these grounds, the proposal of early investigation for VDA in children with manifestations of a posterior stroke may be justified [46]. Hemodynamic abnormalities are frequently found in patients with VDAs [5] and Doppler ultrasonography represents an effective technique for early evaluation. Computed tomography and MRI are useful for evaluating associated brain infarcts, although these investigations may allow, in some cases, the direct visualization of the lesion and the detection of some radiological findings of arterial dissection (intimal flap, intravascular hematoma). Transfemoral angiography still represents the main diagnostic tool. In fact, there are several angiographic findings that can suggest VDA: luminal stenosis or occlusion (“string sign”), aneurysmal dilatation preceding or following a focal narrowing of the vessel lumen (“pearl and string sign”), true and false (intramural) lumen producing a double channel (“double lumen sign”), isolated fusiform dilatation, and intimal flap [8, 22, 32]. In spite of this, correct angiographic diagnosis may remain difficult to perform because of the rarity of the specific signs (e.g., double lumen sign, intimal flap) and the misinterpretation of other findings (e.g., “string” or “pearl and string” may be considered to be the consequences of a vasospasm following the rupture of a saccular aneurysm in patients with associated subarachnoid hemorrhage) [8, 46, 52]. Repeating angiography can show different images from previous scans [20].

The role of computerized tomographic angiography and magnetic resonance angiography is still under definition even if some authors propose them as alternative diagnostic modalities to invasive techniques [17, 22].

Management of VDAs may be challenging.

Most of authors recommend heparin immediately after ischemic damage and, subsequently, anticoagulant oral therapy; however, this type of treatment is not universally accepted, in particular in cases of subarachnoid hemorrhage or large cerebral infarcts [3, 17, 18, 47, 52]. In cases of subarachnoid hemorrhage, surgical or endovascular treatment should be performed, if possible (e.g., vasospasm), acutely or subacutely to reduce the risk of rebleeding even if a second rupture occurs as late as more than 1 month after the first [12, 27].

The goal of an urgent or elective invasive treatment for VDAs is to prevent bleeding or rebleeding, to avoid or reduce ischemic irreversible damages and, if necessary (giant aneurysm), to achieve neural decompression. The surgical techniques include clipping, trapping, and wrapping [8, 27, 50]. Clipping or ligature aim at obtaining an arterial occlusion as proximal as possible to the dissection site. Trapping is useful if, after proximal occlusion, further aneurysmal growth is observed due to blood flow from the contralateral circulation. It is important to carry out a test occlusion (the balloon must be placed proximal to the aneurysm) before clipping or trapping to evaluate if the dissected artery is the dominant vessel, and if its occlusion is not tolerated by the patient [44, 50]. When anatomical or functional conditions do not allow clipping or trapping of the VDA, wrapping can be performed, but the effectiveness of this maneuver is still unknown [12]. Thanks to the special clips available nowadays, it is possible to make an external clipping in some cases [27].

Additional surgical procedures include opening the aneurysm and thrombectomy (neural decompression in case of giant aneurysms), performing in situ or extra-/intracranial bypass (if collateral circulation is not able to supply parent vessel occlusion), and resecting the dissected arterial segment with end-to-end anastomosis or an autologous vein graft.

Surgery of VDAs may be very difficult to perform, especially when dissecting aneurysms arise above the origin of the PICA [50] because of the risk of incidental damage to the vertebral perforating arteries [12].

In cases of unclippable aneurysms, endovascular techniques represent an effective option [14, 43]. In recent years, thanks to technological advances and increased experience in the field, endovascular treatment has indeed become an efficient and safe alternative to surgical treatment [4, 11, 12]. Avoiding the heavy approach of craniotomy and direct manipulation of aneurysm are the principal advantages of this type of procedure [11]. Nevertheless, endovascular treatment may fail (e.g., in cases of aneurysm with a wide neck) [35], and transient or permanent complications have also been described [12].

The most frequent endovascular technique modality for treating VDAs is balloon occlusion [11, 12, 14, 47]. Via a transfemoral approach, a detachable balloon is positioned at the dissection site to prevent luminal recanaliza-

tion from collateral arteries, and to reduce the risk of the occlusion of the perforating vessels. There are several variants of simple balloon occlusion: one or two detachable silicone balloons may be used as the sole embolic agent or in combination with fibered platinum coils; if a single balloon is used, it may be inflated with hydroxyethyl methacrylate to achieve good solidification before its detachment [12]. The absence of a secondary embolism is one of main advantages of balloon occlusion.

Detachable coil embolization is an interesting alternative to balloon occlusion [1, 4, 25]. Several kinds of coil are available and they are used more and more in adults thanks to their greater ductility in comparison with balloons [4, 12, 25]. According to some authors [11], the risk of embolism due to the slow flow of the vessel occluded by detachable coils may be reduced by treating the aneurysm with histoacryl resin. Both balloon occlusion and coil embolization require a test occlusion before they are performed.

Case report

A 8-year-old girl, with a 4-month history of ingravescent dysphagia and anorexia, was admitted to our Pediatric Neurosurgery Department on February 2001 because of an obvious deterioration in her neurological condition, characterized by dysphonia, right facial nerve palsy, right brachio-crural hemiparesis, gait disturbance, and remarkable weight loss. There were no congenital or acquired risk factors for VDA. No history of minor or major cranio-cervical injuries, headache or neck pain was reported. Physical examination revealed right facial nerve palsy, end-position nystagmus, left soft palate palsy, dysphonia, right spastic hemiparesis with overexcitable deep tendon reflexes. Neuroimaging (CT scan, MRI, angio-CT scan with 3D reconstructions) indicated an extra-axial, oval, sharp-edged, expansive process of nearly 4 cm in diameter, with contrast enhancement. The mass lesion was compressing the brain stem and the fourth ventricle, and induced an obvious displacement of the basilar artery. It protruded through the occipital foramen caudally, and caused an angulation of the bulbopontine junction within the prebulbar cistern rostrally. Flow void was valuable within the lesion; there was hypertensive triventricular hydrocephalus (Fig. 1). Cerebral angiography showed a giant dissecting aneurysm of the left vertebral artery extending to the vertebro-basilar junction (Fig. 2). The contralateral vertebral artery was hypoplastic.

Clinical signs and symptoms improved following antiedemic therapy. An endovascular treatment was suggested because of the complexity of the lesion, which appeared to prevent effective surgical therapy. The young patient underwent a partial embolization of the aneurysm with mechanically detachable coils. The choice of a partial embolization was based on the necessity of avoiding the risk that the complete thrombosis of the aneurysm and the possible consequent rapid increase in volume might induce the blocking of the posterior circulation and/or the rupture of the aneurysm wall. Forty-eight hours after the intervention, the girl showed further improvement in her neurological deficits. However, 3 days after the endovascular treatment, she experienced a sudden worsening of her neurological condition with the abrupt loss of consciousness and onset of coma. An urgent CT scan showed tetrahemoventriculus, acute hypertensive hydrocephalus, and subarachnoid hemorrhage. The girl underwent an urgent right frontal external ventriculostomy and a cerebral angiography, which showed the embolization of the aneurysm; neither of the vertebral arteries could be visualized (Fig. 3A). A few hours later, after a further worsening of

Fig. 1 T1-weighted **A** axial and **B** sagittal MRI, **C** T1-weighted coronal MRI after gadolinium, and **D** T2-weighted sagittal MRI demonstrating a posterior cranial fossa round mass lesion, displacing and severely compressing the brain stem

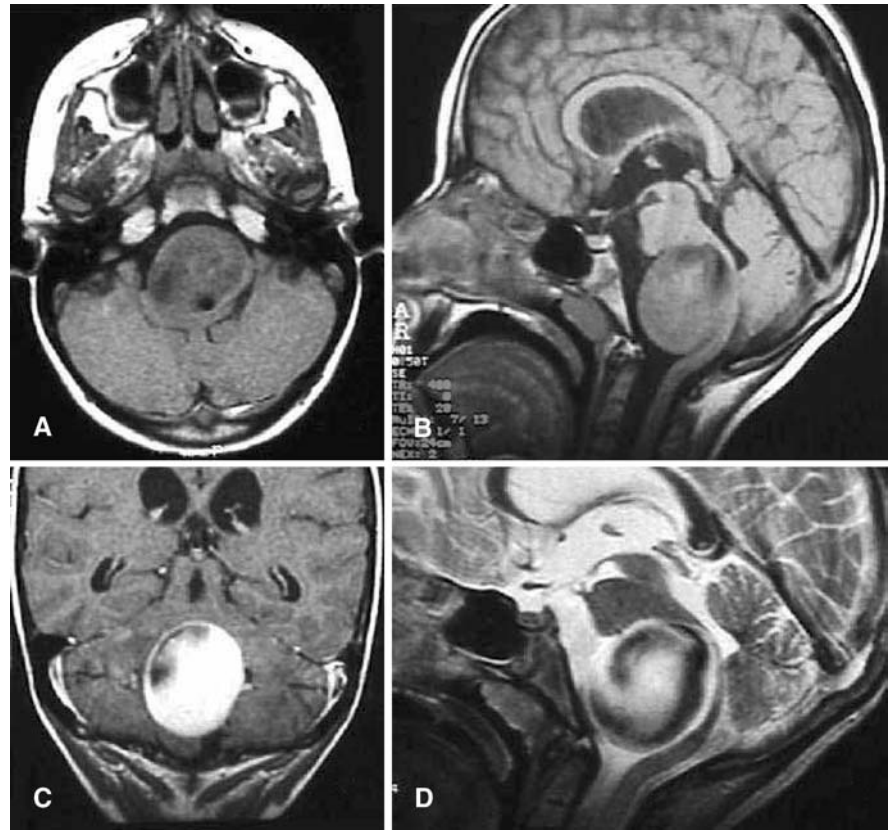
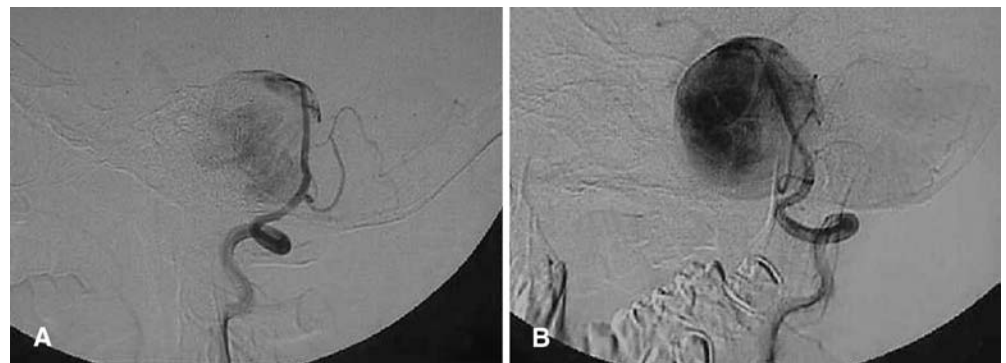


Fig. 2A, B Digital cerebral angiography. **A** Lateral and **B** oblique views show a voluminous aneurysm of the terminal segment of the left vertebral artery, extending to the vertebral-basilar junction



the clinical condition with bradycardia, a new CT demonstrated signs of rebleeding with an increase in the amount of blood within the ventricular system and the subarachnoid spaces (Fig. 3B). A new cerebral angiography suggested the fissuration of the posterior wall of the aneurysm (Fig. 4A) and its caudal dislocation through the occipital foramen due to endocranial hypertension (Fig. 4B). Unfortunately, death occurred a few hours later.

Conclusion

Giant VDAs are very rare in childhood and hard to recognize; these lesions may insidiously progress making their management a real challenge. Endovascular tech-

niques are an effective therapeutic option when the aneurysms are unclippable, although they carry significant risk, as demonstrated by the immediate good outcome of our young patient followed by her death later. Like surgical treatment, lethal complications may occur after endovascular treatment, due to the possibility of hemorrhage, the possible progression of the artificially induced thrombosis, and the occlusion of the perforating branches supplying the brainstem.

Fig. 3 **A** Cerebral angiography (left ICA, lateral view) after endovascular treatment demonstrates the aneurysm excluded by coils and the basilar artery anteriorly dislocated; vertebral arteries are not visible. **B** CT scan after rebleeding showing tetrahemoventriculus, sub-arachnoid hemorrhage and hypertensive hydrocephalus (axial view)

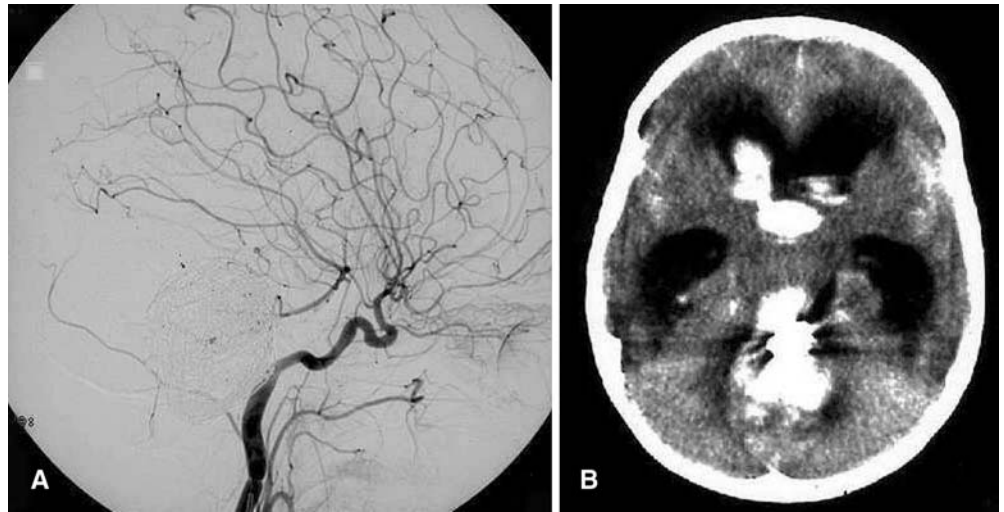
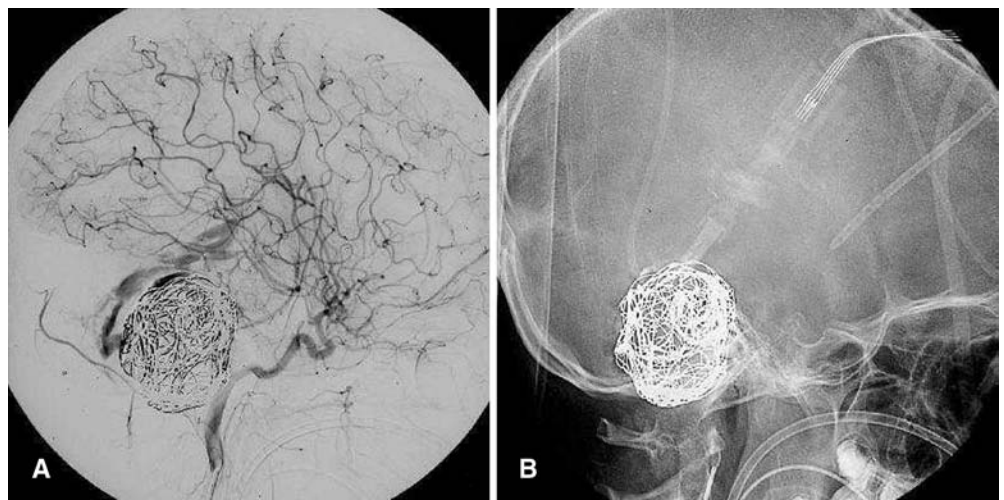


Fig. 4A, B Cerebral angiography after rebleeding. **A** The lateral view (right ICA) shows contrast medium passing into the ventricular system from the posterior wall of the aneurysm. **B** Imaging without bone subtraction: the aneurysm protrudes through the occipital foramen



References

- Amagasaki K, Yasishita T, Yagi S, Kuroda K, Nishigaya K, Nukui H, Amasaki K (1999) Serial angiography and endovascular treatment of dissecting aneurysms of the anterior cerebral and vertebral arteries. Case report. *J Neurosurg* 91:682–686
- Anson J, Crowell RM (1991) Cervicocranial arterial dissection. *Neurosurgery* 29:89–96
- Berger MS, Wilson CB (1984) Intracranial dissecting aneurysms of the posterior circulation. Report of six cases and review of the literature. *J Neurosurg* 61:882–894
- Coley SC, Clifton A (1999) Dissecting vertebral artery aneurysm: diagnosis and coil embolization. *Br J Radiol* 72:408–411
- De Bray JM, Penisson-Besnier J, Dubas R, Emile J (1997) Extracranial and intracranial vertebrobasilar dissection: diagnosis and prognosis. *J Neurol Neurosurg Psychiatry* 63:46–51
- Endo S, Nishijima M, Nomura H, Tekaku A, Okada E (1993) A pathological study of intracranial posterior circulation dissecting aneurysms: report of three autopsied cases and review of the literature. *Neurosurgery* 33:732–738
- Feudale F, Liebelt E (2000) Recognizing vertebral artery dissection in children: a case report. *Pediatr Emerg Care* 16:184–188
- Friedman AH (1996) Arterial dissection. In: Wilkins RH, Rengachary SS (eds) *Neurosurgery*, 2nd edn. McGraw-Hill, New York
- Friedman AH, Drake CG (1984) Subarachnoid hemorrhage from intracranial dissecting aneurysm. *J Neurosurg* 60:325–334
- Goldstein SJ (1982) Dissecting hematoma of the cervical vertebral artery: case report. *J Neurosurg* 56:451–454

11. Grosso S, Mostardini R, Venturi C, Bracco S, Casasco A, Berardi R, Balestri P (2002) Recurrent torticollis due to dissecting cerebral artery aneurysm in a pediatric patient. Results of endovascular treatment by using coil embolization. *Neurosurgery* 50:204–207
12. Halbach VV, Higashida RT, Dowd CF, Fraser KW, Smith TP, Teitelbaum GP, Wilson CB, Hieshima GB (1993) Endovascular treatment of vertebral artery dissections and pseudoaneurysms. *J Neurosurg* 79:183–191
13. Hasan I, Wapnik S, Kutscher ML, Couldwell WT (2002) Vertebral arterial dissection associated with Klippel-Feil syndrome in a child. *Childs Nerv Syst* 18:67–70
14. Hodes JE, Aymard A, Gobin YP, Rufenacht D, Bien S, Reizine D, Gaston A, Merland JJ (1991) Endovascular occlusion of intracranial vessels for curative treatment of unclippable aneurysms: report of 16 cases. *J Neurosurg* 75:694–701
15. Horowitz IN, Niparko NA (1994) Vertebral artery dissection with bilateral hemiparesis. *Pediatr Neurol* 11:252–254
16. Jacobi G, Riepert T, Kieslich M, Bohl J (2001) [Fatal outcome during physiotherapy (Vojta's method) in a 3-months old infant. Case report and comments on manual therapy in children] (in German). *Klin Padiatr* 213:76–85
17. Khurana DS, Bonnemann CG, Dooling EC, Ouelette EM, Buonanno F (1996) Vertebral artery dissection: issues in diagnosis and management. *Pediatr Neurol* 14:255–258
18. Kidooka M, Okada T, Sonobe M, Nakazawa T, Handa J (1993) Dissecting aneurysm of the anterior cerebral artery: report of two cases. *Surg Neurol* 39:53–57
19. Kim SH, Kosnik F, Madden C, Rusin J, Wack D, Bartkowski H (1997) Cerebellar infarction from a traumatic vertebral artery dissection in a child. *Pediatr Neurosurg* 27:71–77
20. Kitanaka C, Tanaka J-I, Kuwahara M, Teraoka A, Sasaki T, Takakura K (1994) Nonsurgical treatment of unruptured intracranial vertebral artery dissection with serial follow-up. *J Neurosurg* 80:667–674
21. Krespi Y, Gurol ME, Coban O, Tuncay R, Bahar S (2002) Vertebral artery dissection presenting with isolated neck pain. *J Neuroimaging* 12:179–182
22. Lanzino G, Kaptain G, Kallmes DF, Dix JE, Kassel NF (1997) Intracranial dissecting aneurysm causing subarachnoid hemorrhage: the role of computerized tomographic angiography and magnetic resonance angiography. *Surg Neurol* 48:477–481
23. Leys D, Lesoin F, Pruvo JP, Gozet G, Jomin M, Petit H (1987) Bilateral spontaneous dissection of extracranial vertebral artery. *J Neurol* 234:237–240
24. Lotze TE, Paolicchi J (2000) Vertebral artery dissection and migraine headaches in children. *J Child Neurol* 15:694–696
25. Lylyk P, Ceratto R, Hurvitz D, Basso A (1998) Treatment of a vertebral dissecting aneurysm with stents and coils: technical case report. *Neurosurgery* 43:385–388
26. Mas JL, Henin D, Bousser MG, Chain F, Hauw JJ (1989) Dissecting aneurysm of the vertebral artery and cervical manipulation: a case report with autopsy. *Neurology* 39:512–515
27. Mizutani T, Aruga T, Kirino T, Miki Y, Saito I, Tsuchida T (1995) Recurrent subarachnoid hemorrhage from untreated ruptured vertebrobasilar dissecting aneurysms. *Neurosurgery* 36:905–913
28. Mizutani T, Miki Y, Kojima H, Suzuki H (1999) Proposed classification of nonatherosclerotic cerebral fusiform and dissecting aneurysms. *Neurosurgery* 45:253–260
29. Nagao S, Kinugasa K, Bukeo T, Nishimoto A, Harada Y (1987) [Giant, fusiform and dissecting aneurysms at the vertebro-basilar junction – report of five cases and their clinical pathophysiological aspects] (in Japanese). *No Shinkei Geka* 15:1093–1100
30. Otawara Y, Ogasawara K, Ogawa A, Kogure T (2002) Dissecting aneurysms of the bilateral vertebral arteries with subarachnoid hemorrhage: report of three cases. *Neurosurgery* 50:1372–1374
31. Pozzati E, Padovani R, Fabrizi A, Sabattini L, Gaist G (1991) Benign arterial dissection of the posterior circulation. *J Neurosurg* 75:69–72
32. Pozzati E, Andreoli A, Limoni P, Casmiro M (1994) Dissecting aneurysms of the vertebrobasilar system: study of 16 cases. *Surg Neurol* 41:119–124
33. Saeed AB, Shuaib A, Al-Sulaiti G, Emery D (2000) Vertebral artery dissection: warning symptoms, clinical features and prognosis in 26 patients. *Can J Neurol Sci* 27:292–296
34. Sasaki O, Ogawa H, Koike T, Koizumi T, Tanaka R (1991) A clinicopathological study of dissecting aneurysms of the intracranial vertebral artery. *J Neurosurg* 75:874–882
35. Schievink WI (1997) Intracranial aneurysm. *N Engl J Med* 336:28–40
36. Schievink WI (2001) Spontaneous dissection of the carotid and vertebral arteries. *N Engl J Med* 344:898–906
37. Schievink WI, Mokri B, Piepgras DG (1994) Spontaneous dissections of cervicocephalic arteries in childhood and adolescence. *Neurology* 44:1607–1612
38. Schievink WI, Parisi JE, Piepgras DG, Mischels VV (1997) Intracranial aneurysms in Marfan's syndrome: an autopsy study. *Neurosurgery* 41:866–870
39. Schievink WI, Meyer FB, Parisi JE, Wijndicks EF (1998) Fibromuscular dysplasia of the internal carotid artery associated with alpha 1-antitrypsin deficiency. *Neurosurgery* 43:229–233
40. Schievink WI, Parisi JE, Piepgras DG (1998) Familial intracranial aneurysms: an autopsy study. *Neurosurgery* 43:1258–1259
41. Schoenberg BS, Mellinger JF, Schoenberg DG (1978) Cerebrovascular disease in infants and children: a study of incidence, clinical features, and survival. *Neurology* 28:763–768
42. Silbert PL, Mokri B, Schievink WI (1995) Headache and neck pain in spontaneous internal carotid and vertebral artery dissection. *Neurology* 45:1517–1522
43. Silverboard G, Tart R (2000) Cerebrovascular arterial dissection in children and young adults. *Semin Pediatr Neurol* 7:289–300
44. Su CC, Watanabe T, Yoshimoto T, Ogawa A, Ichige A (1990) Proximal clipping of dissecting intracranial vertebral aneurysm – effect of balloon Matas test with neurophysiological monitoring. Case report. *Acta Neurochir* 104:59–63
45. Tanaka K, Waga S, Kojima T, Shimizu T, Niwa S (1989) Non traumatic dissecting aneurysms of the intracranial vertebral artery: report of six cases. *Acta Neurochir (Wien)* 100:62–66
46. Tekin S, Aykut-Bingol C, Aktan S (1997) Case of intracranial vertebral artery dissection in young age. *Pediatr Neurol* 16:67–70
47. Tsukahara T, Wada H, Satake K, Yaoita H, Takahashi A (1995) Proximal balloon occlusion for dissecting vertebral aneurysms accompanied by subarachnoid hemorrhage. *Neurosurgery* 36:914–919
48. Yamashita M, Tanaka K, Matsuo T, Yokoyama K, Fujii T, Sakamoto H (1983) Cerebral dissecting aneurysms in patients with Moyamoya disease. *J Neurosurg* 58:120–125

49. Yamaura A (1994) Nontraumatic intracranial arterial dissection: natural history, diagnosis and treatment. *Contemp Neurosurg* 16:1–6
50. Yamaura A, Watanabe Y, Saeki N (1990) Dissecting aneurysms of the intracranial vertebral artery. *J Neurosurg* 72:183–188
51. Yasui T, Sakamoto H, Kishi H, Komiyama M, Iwai Y, Yamanaka K, Nishikawa M (1998) Bilateral dissecting aneurysms of the vertebral arteries resulting in subarachnoid hemorrhage: case report. *Neurosurgery* 42:162–165
52. Yonas H, Agamanolis D, Takaoka Y, White RJ (1977) Dissecting intracranial aneurysms. *Surg Neurol* 8:407–415