

Cortical auditory disorder caused by bilateral strategic cerebral bleedings. Analysis of two cases

Imre Szirmai,* Marianna Farsang, and Maria Csüri

Department of Neurology, Faculty of Medicine, Semmelweis University, Balassa u.6., Budapest H-1083, Hungary

Accepted 11 October 2002

Abstract

The authors present the anatomical and clinical features of cortical auditory dysfunction in two patients, in whom hypertensive bleedings destroyed the cortical auditory centres in both hemispheres. The second haemorrhage occurred four years after the first bleeding in both cases. The bleedings isolated the cortical hearing centres due to the destruction of the right and left temporal white matter. During the clinical course the symptomatology has changed in both patients: pure word deafness has transformed to cortical deafness and generalised auditory agnosia. Normal pattern of brain stem auditory evoked potentials suggested intact auditory pathways. Authors conclude that transformation of clinical forms of cortical auditory disorder can be explained by the tissue reaction to the subcortical bleeding in the cortical auditory centres.

© 2002 Elsevier Science (USA). All rights reserved.

Keywords: Word deafness; Cortical deafness; Auditory agnosia; Bilateral temporal haemorrhages

1. Introduction

Word deafness was first described by Lichtheim (1985) who presented a patient with selective impairment of comprehension, repetition, and writing to dictation, while spontaneous speech was preserved. Word deafness can be differentiated from Wernicke- and transcortical sensory aphasia; sensory aphasic patients can neither read nor write, while word deafness patients are capable of written communication. Depending on the ability to comprehend verbal stimuli, recognise environmental sounds and music, word deafness is divided into four symptom-complexes. (A) In pure word deafness the patients can be considered deaf, but only to verbal stimuli, while they recognise non-verbal noises and intonation of speech (Kanter, Day, Heilman, & Gonzalez-Rothi, 1986, Mendez & Geehan, 1988). Reading and writing are preserved because these do not need auditory input. The pure word deafness usually is the result of bitemporal vascular

lesions developing at different times (Kanter et al., 1986, Praamstra, Hagoort, Maassen, & Crul, 1991, Takahashi et al., 1992). (B) In cortical deafness any auditory signals cannot be perceived in the cortex. Some patients deny hearing noises in spite of reacting adequately to them (Mendez & Geehan, 1988). (C) In pure auditory agnosia patients are able to perceive, but unable to recognise noises and their sources in contrast to the intact comprehension of speech. The pure auditory agnosia is usually caused by lesion in the non-dominant associative auditory area. (D) In generalised auditory agnosia patients cannot differentiate spoken words and noises or music and they are not able to recognise the source of the noises as well (Kanter et al., 1986).

Cortico-subcortical auditory deficit is most frequently caused by ischemic cerebrovascular accident (Buchman, Garron, Trost-Cardamone, Wichter, & Schwartz, 1986); it is rare to find in cases with tumor (Karibe et al., 2000) and epilepsy (Fung, Sue, & Somerville, 2000). We present the clinical history and follow up of two patients with various stages of verbal and non-verbal cortical auditory deficit syndromes, caused by bilateral temporo-subinsular haemorrhages.

* Corresponding author. Fax: +36-1-210-0337.

E-mail address: szirmai@neur.sote.hu (I. Szirmai).

2. Case reports

Patient 1. NB 51-year-old right-handed retired car mechanic (education: 8 years primary school) who suffered a left-sided hemiparesis in 1994 due to a right temporo-medial and insular haemorrhage. The patient recovered completely except the non-dominant parietal symptoms (see in Table 1). In 1998 he was repeatedly admitted to our hospital because of sudden confusion and “mental deficit.” Relatives noticed the weakness of the right arm and leg, his spontaneous speech was comprehensible but he did not answer verbal questions. Neurologist found high blood pressure, right-sided homonymous hemianopia, supranuclear facial paresis, and slight hemiparesis on the right side with pyramidal signs. His speech was well articulated, but he could not comprehend and repeat spoken words. He responded correctly to written instructions, he could read printed text, described pictures well, he could match written words with pictures and objects correctly, made no mistakes in letter discrimination. He could write and copy words and geometric figures. According to the modified Western Aphasia Battery, acalculia and finger agnosia and left–right disorientation was detected. Sentence construction and completion was impaired. At admission he complained of hearing loss, but he could perceive environmental noises and oriented towards their sources and could specify them (slamming the door, rattling the key, slapping the hand) but could not comprehend spoken language. These symptoms reveal pure word deafness. The MRI showed left-sided bleeding within the posterior limb of external capsula and the subinsular and paraventricular white matter with thin perifocal edema and the post-haemorrhagic old infarct in the right superior temporal region (Fig. 1). The following day his symptoms worsened: he could perceive, but could not specify the sources of the noises (knocking on the table, slapping, ringing the bell). These were the signs of generalised auditory agnosia. According to the second MRI the perifocal edema increased. Brain stem auditory evoked potentials revealed intact auditory pathways. Electroencephalography (EEG) showed bilateral slow waves, single photon emission computed tomography (SPECT) found bilateral perfusion loss in the temporal regions. On the third day he gave no re-

action either to noises or music. His spontaneous speech and the ability to read and obeying commands worsened, he changed letters, used neologisms indicating a sensory aphasia which lasted for only two days. One week after admission the aphasic features of his speech disappeared, motor symptoms improved. The patient did not react to noises, music, spoken words—cortical deafness was diagnosed. Auditory perception has not improved, four months later the symptoms were the same. Since then he communicates in writing, and there is no sign of aphasia. Control MRI scans showed regression of the haemorrhage. Four months after the second stroke residual hypointensity around the bleeding, caused by tissue methaemoglobin was seen on the MRI scan in both patients.

Patient 2. MJ 58-year-old right-handed retired plasterer (education: 8 years primary school) with hypertension and paroxysmal tachycardia who suffered right-sided hemiplegia and global aphasia in 1994 due to a left striatal haemorrhage destroying the temporal operculum and undercut the parietal region. After a few months his gate improved and presented only slight word finding deficit (residual symptoms see in Table 1). In 1998 he suddenly experienced “deafness.” The patient complained about acoustic illusions (sounds of a radio) just before stroke. At admission moderate right-sided hemiparesis was found with spasticity and pyramidal signs. He could not understand speech, was not able to match spoken words with objects and pictures, did not react to noises and music (cortical deafness), but he could read and understand written words, however he had difficulties in matching written words with objects due to residual word finding deficit (Table 2.). He recognised and named letters well. Patient could write his name, copy words and sentences in block letters, hesitancy and aphasic character especially in use of nouns was observed. In MJ the first bleeding in 1994 did not cause orientation deficit and finger agnosia—the patient was able to select fingers correctly although he had inconsistency to name them because of the word finding deficit. At the time of the second bleeding word finding deficit, finger agnosia, and impaired left–right orientation was found.

CT and MRI showed recent right-sided deep temporal haemorrhage extending from the opercular supe-

Table 1
Residual symptoms after the first stroke

	Patient 1 (NB)	Patient 2 (MJ)
Motor symptoms	None	Moderate right-sided spastic hemiparesis
Motor speech	Normal	Word finding deficit, impaired fluency
Speech comprehension	Normal	Normal
Handwriting	Intact	Clumsy with agrammatism
Impaired hearing	No	No
Non-dominant parietal symptoms	Left–right disorientation	None

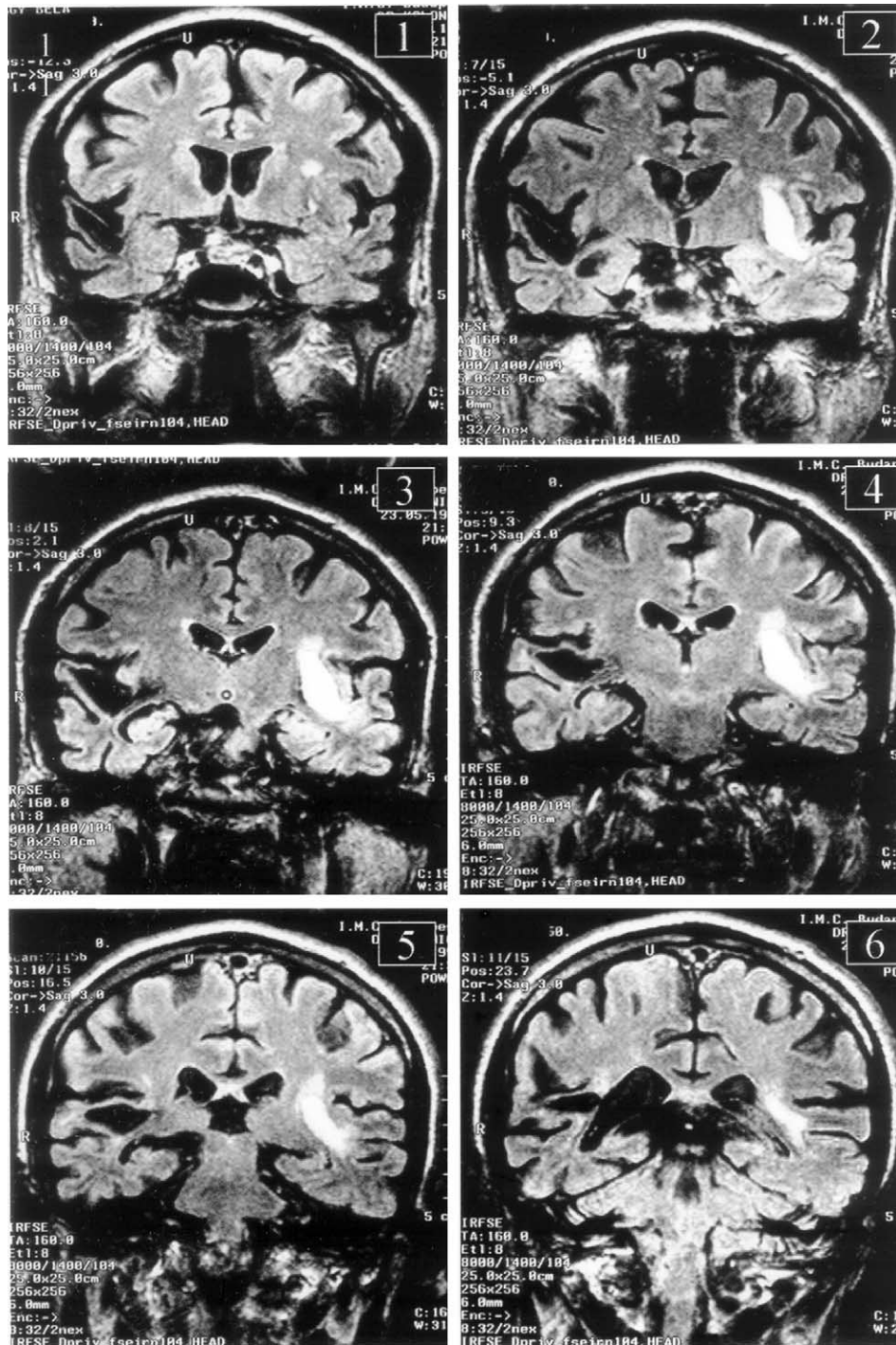


Fig. 1. Patient NB, six consecutive coronal FLAIR MR images from mid-frontal to parietal planes. Hypodense infarct as a remnant of the old right-sided haemorrhage in the superior temporal gyrus extends from the level of the head of the caudate nucleus to the parieto-occipital sulcus. It destroys the subinsular white matter from the level of the anterior commissure to the pulvinar. Atrophy of the superior temporal gyrus and the dilatation of the neighbouring subarachnoid spaces are visible. The recent, left-sided subinsular lateral and deep temporal haemorrhage extends from the level of the head of the caudate nucleus to the trigonum of the lateral ventricle. This destroys completely the subinsular white matter, the claustrum and the external capsule, spreads into the white matter of the left superior temporal gyrus and into the deep white matter of the frontal opercular cortex.

rior temporal region to the claustrum affecting the basal ganglia with small perifocal edema (Fig. 2). Brain stem auditory evoked potentials were normal. EEG recorded

theta and delta waves bilaterally. SPECT revealed bilateral perfusion deficit in temporo-parietal region with left-sided dominance. There was no improvement in the

Table 2
Western aphasia battery modified for patients with cortical auditory dysfunction

Days	Patient 1 (NB)					Patient 2 (MJ)				
	1	2	3–4	10	cca 120	1	2	3–4	10	cca 120
<i>Spontaneous speech</i>	Preserved	Preserved	Sensory aphasia- phonemic parapha- sias, neologisms	Preserved	Preserved	Non-fluent with word finding deficit.				
<i>Picture description</i>	Preserved	Preserved	Sensory aphasia- phonemic parapha- sias, neologisms	Preserved	Preserved	Non-fluent with word finding deficit and circumscriptions				
<i>Auditory tasks</i>	Not applicable	Not applicable	Not applicable	Not applicable	Not applicable	Not applicable	Not applicable	Not applicable	Not applicable	*
<i>Written tasks</i>										
Yes or no questions ^c	48/60	51/60	21/60	54/60	54/60	33/60	36/60	30/60	33/60	36/60
Word recognition ^{a,b}	36/ 48 ^c	35/48 ^c	5/48 ^d	33/48	35/48	22/48	27/48	31/48	26/48	30/48
Sequential commands ^c	38/80	38/80	0/80 ^d	34/80	42/80	14/80	12/80	18/80	14/80	18/80
Repetition	Not applicable	Not applicable	Not applicable	Not applicable	Not applicable	Not applicable	Not applicable	Not applicable	Not applicable	22/100 ^e
Object naming	18/ 20 ^f	18/20 ^f	3/ 20 ^g	19/20 ^f	18/20 ^f	9/20	11/20	8/20	10/20	12/20
Verbal fluency ^c	17/20	18/20	0/20 ^d	19/20	18/20	7/20	8/20	8/20	8/20	10/20
Sentence completion ^a	3/5	2/5	0/5 ^d	4/5	3/5	4/10	6/10	4/10	4/10	6/10
Answers to written questions ^c	10/10	10/10	0/10 ^d	10/10	10/10	4/10	4/10	4/10	4/10	6/10

* Residual auditory agnosia: the patient is able to respond partially to the auditory commands: yes or no questions 30/60; matching spoken words with objects (3/6), drawings (2/6), figures (2/6), letters (4/6), numbers (2/6), colours (3/6), furniture (4/6), body parts (3/6), fingers (2/6), left–right recognition (1/6); sequential commands (10/80); repetition (60/100); object naming (8/20, with phonemic cue 10/20); verbal fluency (6/20); sentence completion (2/10); answering questions (0/10).

^a Numbers indicating correct answers out of the total.

^b Not applicable for letters and numbers.

^c The deficit is due to the finger agnosia and left–right confusion.

^d The patient did not understand the command.

^e Collected score out of the maximum.

^f Not improved by tactile or phonemic cues.

^g Improved by tactile or phonemic cues.

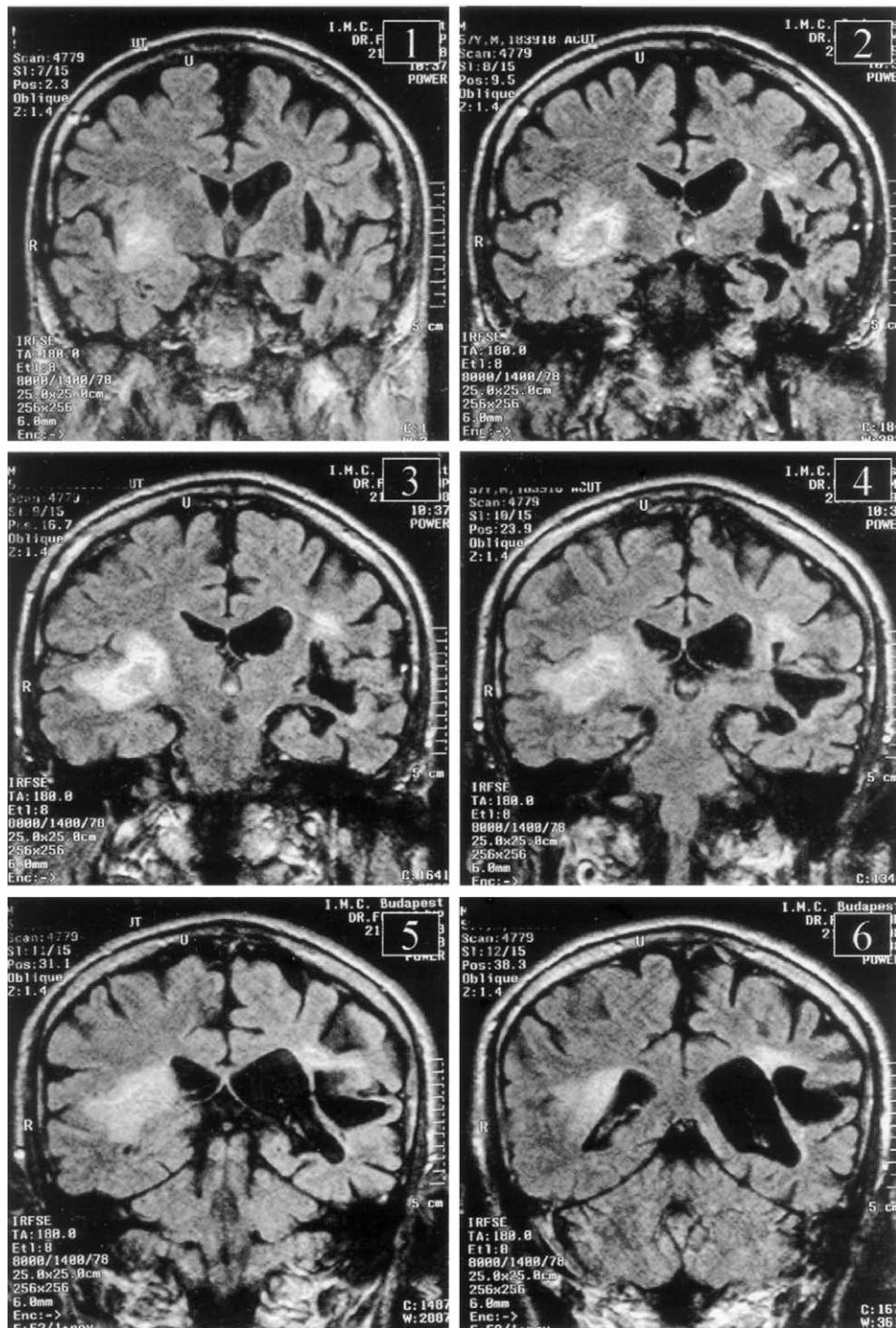


Fig. 2. Patient M.J. coronal FLAIR MR images. The remnant of the old left-sided haemorrhage destroys the subinsular white matter and the posteromedial part of the superior temporal gyrus. It destroys also the deep white matter in the posterior part of the middle frontal gyrus, the frontal opercular cortex and the lateral edge of the genu of the internal capsule. The lateral ventricle is widened on this side. The subacute right-sided haemorrhage with perifocal edema spreads in the middle lateral part of the right striato-capsular region, extending from the level of the amygdala to the trigonum of the lateral ventricle and tears off the association fibres of the supramarginal gyrus. The lateral ventricle is modelled on the right side.

auditory dysfunction during the first 10 days of hospitalisation. Six weeks later the perfusion was normal on the right but there was no improvement on the left side. After four months only residual symptoms of auditory agnosia were found: he comprehended most of spoken

words, he matched words with objects and pictures, recognised music and sang simple melodies, there was no finger agnosia, orientation failure and dyscalculia. He could identify sources of several noises. His audiometry was normal. Comprehension of spoken words

was aided by lip reading, but he needed support in sentence completion. Control MRI found significant regression of the haemorrhage and thin perifocal rim of methemoglobin.

3. Discussion

There are two levels of auditory information processing: acoustic (pre-phonemic) and phonemic. These levels can be recognised according to the symptoms of pure word deafness, namely: bilateral upper temporal lesion causes acoustic damage of speech, while unilateral lesion in the dominant hemisphere causes phonemic type of word deafness (Auerbach, Allard, Naeser, Alexander, & Albert, 1982). The latter is often associated with sensory aphasia. In case of associated non-dominant hemisphere damage, patients often neglect their handicap. In patients with cortical deafness audiometry reveals abnormal hearing threshold (Kanter et al., 1986). Unilateral damage of the primary auditory cortex does not cause cortical deafness, but the hearing threshold of the contralateral ear can be elevated, particularly in the domain of brief acoustic signals. Sometimes patients complain of hearing problems, voices are mistaken as noises, and they usually misinterpret spoken words as foreign language.

According to the literature most of the cortical auditory disorders are of ischemic origin. In our two cases bilateral bleedings of similar locations developing at different times destroyed the strategic auditory centres. Our cases confirm the previous observation (Buchman et al., 1986) that the sequence of cerebral injury determines the clinical picture. In patient NB the right hemisphere bleeding preceded the left, the latter caused transient sensory aphasia. In patient MJ the left hemispheric bleeding occurred first and caused global aphasia, which recovered with rest-symptom of word finding deficit. After the right-sided second bleeding, the recent symptoms—especially the appearance of finger agnosia, suggest that some cortical functions ought have to be taken over by the subdominant hemisphere.

Classification of cortical auditory disorders seems to be divergent. Benson et al. divided word deafness into three subgroups (Alexander & Benson, 1991, Chap. 10, Benson & Ardila, 1996): patients of the first group have paraphasic, fluent speech with a few agrammatisms and slight anomia. They are able to read, but uncertain in writing. In these cases the left upper temporal gyrus, the primary auditory cortex and connecting fibres to the upper posterior temporal convolution are generally damaged. The second group of word deafness fit the diagnostic criteria of generalised auditory agnosia. There is an inability to recognise sounds as music, noises, or spoken words (Benson & Ardila, 1996; Motomura, Yamadori, & Mitani, 1986) caused by extensive

bilateral posterior temporal damage. In the third type, the lesions are bilateral and destroy the auditory cortex and/or auditory pathways in the dominant hemisphere. The posterior part of the upper temporal gyrus may be intact. In these cases disorientation in time was reported. Damages separate the left primary auditory cortex from the Wernicke-area, or dissect fibres between the medial geniculate body and the primary auditory cortex in both hemispheres. Geschwind (1965) was the first who defined pure word deafness as a disconnection syndrome.

Because of the lack of verbal communication the commands of Western batteries had to be transformed to written form. We observed transformation of the basic symptoms of cortical auditory disorders, which can be explained by the changing size of the perifocal edema affecting the connections of the Wernicke-area and the supramarginal gyrus in the left hemisphere. In patient NB who suffered no auditive deficit after the first, right-hemispheric bleeding, the second, left-sided haemorrhage caused pure word deafness then generalised auditory agnosia that changed to cortical deafness during the observation period. The second haemorrhage probably undercut the left temporal cortex and resulted, apart from acute word deafness, in transient sensory aphasia and alexia. At that time there might have been no functional derangement of the left primary and the secondary auditory areas, but the spread of the edema should have reached the Wernicke's area white matter. Later, the perifocal edema involved the temporal association cortex, resulting in generalised auditory agnosia. In the case of NB cortical deafness was attributed to the lesion of both primary auditory areas and/or subcortical white matter. Regarding the symptomatology our case is similar to that described by Praamstra et al. (1991) where the rest symptoms (anomia) of aphasia already existed and the patient acquired word deafness four years later when the second bleeding destroyed the connections of the non-dominant auditory cortical areas. Changing symptomatology of central auditory deficit was also published by Mendez and Geehan (1988). Regarding the mechanism of word deafness it is important to know that visual processing is regularly preserved and seems to be satisfactory to comprehend written words. This reinforces the previous observations that acoustic and visual cognitive functions can be stimulated separately from each other (Mayeux & Kandel, 1991). Pure word deafness in most of the reported cases could be explained by the isolation of Wernicke's area due to the interruption of the association and/or auditory radiation fibres (Takahashi et al., 1992).

Despite the similarity of the location of the lesions in our patients there are remarkable differences in the clinical course of the disease. In one-year follow up we have not found improvement in the clinical symptoms of NB. Communication was better when the patient read

lips. MJ improved significantly in comprehension of the acoustic signals but the use of verbal cues and sentence completion remained impaired.

Acknowledgments

We thank to Professor József Kenéz and Zsuzsanna Kopcsányi for the imaging studies, to A. Kamondi and T. Kovács for their valuable help.

References

- Alexander, M. P., & Benson, D. F. (1991). The aphasia and related disturbances. In R. J. Joynt (Ed.), *Clinical Neurology*. Philadelphia: Lippincott.
- Auerbach, S. H., Allard, T., Naeser, M., Alexander, M. P., & Albert, M. L. (1982). Pure word deafness: Analysis of a case with bilateral lesions after a defect at the prephonemic level. *Brain*, 105, 271–300.
- Benson, D. F., & Ardila, A. (1996). *Aphasia—A clinical perspective*. New York, Oxford: Oxford University Press.
- Buchman, A., Garron, D. C., Trost-Cardamone, J. E., Wichter, M. D., & Schwartz, M. (1986). Word deafness: One hundred years later. *Journal of Neurology, Neurosurgery, and Psychiatry*, 49, 489–499.
- Fung, V. C. S., Sue, C. M., & Somerville, E. R. (2000). Paroxysmal word deafness secondary to focal epilepsy. *Neurology*, 54, 533–534.
- Geschwind, N. (1965). Disconnexion syndromes in animals and man. Part I and II. *Brain*, 88, 237–294, see also pp. 585–644.
- Kanter, S. L., Day, A. L., Heilman, K. M., & Gonzalez-Rothi, L. J. (1986). Pure word deafness: A possible explanation of transient deterioration after extracranial–intracranial bypass grafting. *Neurosurgery*, 18, 186–189.
- Karibe, H., Yonemori, T., Matsuno, F., Honmou, O., Minamida, Y., Uede, T., Tanabe, S., & Hashi, K. (2000). A case of tentorial meningioma presented with pure word deafness. *Brain-Nerve*, 52, 997–1001.
- Lichtheim, M. L. (1985). On aphasia. *Brain*, 7, 433–484.
- Mayeux, R., & Kandel, E. R. (1991). Disorders of language: The aphasia. In E. R. Kandel, J. H. Schwartz, & T. M. Jessell (Eds.), *Principles of Neural Science* (pp. 839–851). New York: Elsevier.
- Mendez, M. F., & Geehan, G. R. (1988). Cortical auditory disorders: Clinical and psychoacoustic features. *Journal of Neurology, Neurosurgery, and Psychiatry*, 51, 1–9.
- Motomura, N., Yamadori, A., & Mitani, Y. (1986). Left thalamic infarction and disturbance of verbal memory: A clinico-anatomical study with a new method of computed tomographic stereotaxic lesion localisation. *Annals of Neurology*, 20, 671–676.
- Praamstra, P., Hagoort, P., Maassen, B., & Crul, T. (1991). Word deafness and auditory cortical function. *Brain*, 114, 1197–1225.
- Takahashi, N., Kawamura, M., Shinotou, H., Hirayama, K., Kaga, K., & Shindo, M. (1992). Pure word deafness due to left hemisphere damage. *Cortex*, 28, 295–303.