

Short communication

Transient global amnesia associated with an acute infarction in the retrosplenium of the corpus callosum

Kozue Saito*, Kazumi Kimura, Kazuo Minematsu, Atsushi Shiraishi, Makoto Nakajima

Cerebrovascular Division, Department of Medicine, National Cardiovascular Center, Fujishirodai, Suita, Osaka 565-8565, Japan

Received 25 October 2002; received in revised form 3 January 2003; accepted 6 January 2003

Abstract

We present a patient with transient global amnesia (TGA) whose diffusion-weighted imaging (DWI) study showed a high-intensity signal in the left retrosplenium of the corpus callosum. In previous studies, lesions in the retrosplenium caused permanent but not transient global amnesia, called retrosplenial amnesia, by involving the thalamocortical portion of the Papez' circuit. This is the first report indicating that TGA can be associated with acute infarction only in the left retrosplenium of the corpus callosum.

© 2003 Elsevier Science B.V. All rights reserved.

Keywords: Transient global amnesia; Brain infarction; Diffusion-weighted imaging; Retrosplenium of corpus callosum

1. Introduction

Transient global amnesia (TGA) is a well-known syndrome characterized by an acute and transient loss of anterograde and recent retrograde memory, with preservation of alertness, attention and self-identity, and without any other neurological deficits [1].

Recently, several clinical studies revealed that acute ischemic lesions were often visualized in the hippocampus and other posterior circulation areas with diffusion-weighted imaging (DWI) in patients with TGA [2–4]. For example, Hakan et al. [2] reported a TGA patient who had hyperintense lesions in the both hippocampus and retrosplenium on DWI. On the other hand, Gass et al. [5] studied acute stage TGA patients using DWI, and found no evidence of acute ischemic change. Furthermore, epidemiologic studies suggest an association of TGA with migraine [1,6]. Olsen and Jorgensen [7] theorized that spreading depression, by affecting the hippocampus, might cause TGA. Thus, the etiology of TGA remains unclear.

Here, we report that a DWI study revealed an acute ischemic lesion only in the retrosplenium of the corpus callosum in a patient with TGA. To the best of our knowl-

edge, this is the first report of such a case. It may be useful in characterizing the etiology and the pathological lesions associated with TGA.

2. Case report

The patient was a 58-year-old right-handed man. He had a history of hypertension but no head trauma, epilepsy or migraine. On February 23, 2002, he slept at 4:00 a.m. after watching the Atlanta Olympic Games on TV without any problem. In the next day, when he watched the Olympic games on TV again, he asked his wife repeatedly why the Olympic games were being held at that time. He could not understand his wife's explanation briefly, but then immediately forgot it. He did not remember that he had visited his friend in the previous day. He could not identify himself and his family members. His family took him to a hospital. There, he repeatedly asked his wife why he was at the hospital. An attending physician diagnosed him as having anterograde and recent retrograde memory loss with preservation of alertness, attention and self-identity. A brain CT scan showed only an old infarction in the left caudate head. One hour later, the patient was transferred to our hospital for further evaluations. Upon arrival, blood pressure was 190/100 mm Hg, with a regular pulse rate of 100/min. Except for the memory deficits, his neurological findings were normal. Physical examinations revealed no abnormalities in the

* Corresponding author. Tel.: +81-6-6833-5012; fax: +81-6-6872-7486.

E-mail address: ksaito@hsp.nccvc.go.jp (K. Saito).

chest, abdomen and extremities. In laboratory studies, blood cell counts, liver and renal functions, serum cholesterol and blood glucose levels, arterial blood gasses, and coagulation systems were normal. Electrocardiogram, chest X-ray, and transthoracic echocardiography findings were normal. Carotid ultrasonography and transcranial color sonography revealed no abnormalities in bilateral extra-/intracranial cerebral arteries. The patient's amnesia and repetitive questioning gradually resolved. After he had stayed overnight at our hospital, the next morning, he was well oriented, and recovered anterograde and recent retrograde memory except for that of during the attack, which was not recovered finally. The total duration of the amnesia was about 20 h.

Two days after the attack, MRI studies including DWI were performed using a Siemens MAGNETOM Vision 1.5-Tesla MR unit with echo-planar capability. Conventional MRI studies included T1-weighted (repetition time [TR]/echo time [TE], 630/14), T2-weighted (TR/TE, 5400/99) and fluid-attenuation inversion recovery (FLAIR) (TR/TE/inversion time [TE], 9000/105/2400) images. A DWI study was performed with a spin-echo echo-planar imaging sequence, and diffusion gradients were applied in the x , y and z directions, with b -value of 1000 s/mm². DWI revealed only a small lesion of high signal intensity in the left retrosplenium of the corpus callosum (Fig. 1). The small ischemic lesion was also detected on the T2-weighted and FLAIR images. Apparent diffusion coefficient (ADC) could not be calculated because of the small lesion size. Magnetic resonance angiography (MRA) showed no stenotic lesions in the intracranial arteries.

Three days after the attack, single photon emission CT scans revealed no abnormalities in brain perfusion. On day

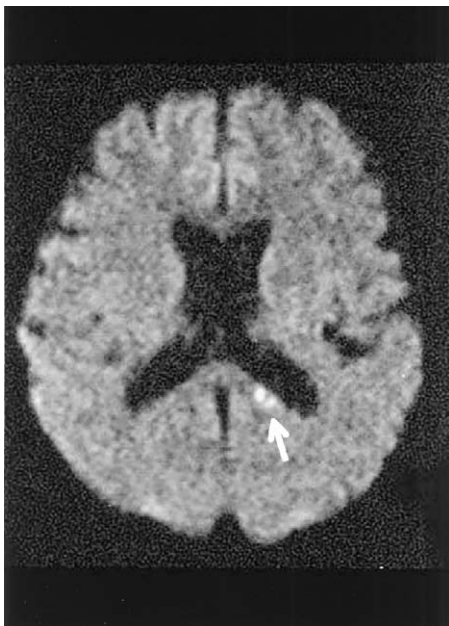


Fig. 1. An axial DWI shows a hyperintense lesion in the left splenium of the corpus callosum (arrow).

6, a contrast-transesophageal echocardiography study detected patent foramen ovale (PFO), but no atrial septal aneurysm. On day 11, venoscintigraphy revealed a defect in the main trunk of the right popliteal vein with a good collateral pathway, suggesting a possibility of deep venous thrombosis (DVT) in the right leg. He was diagnosed as having TGA associated with acute brain infarction in the left retrosplenium of the corpus callosum, perhaps due to paradoxical embolism through PFO. He started taking 100 mg/day aspirin, and was discharged to his home 24 days after the attack.

3. Discussion

The retrosplenial cortex provides an alternative route for reciprocal connections between the anterior thalamus and the medial temporal structures involved in memory (Papez' circuit). Lesions in the retrosplenial cortex may disrupt connection between the anterior thalamus and hippocampus, and thus may cause memory disturbance. Valenstein et al. [8] reported a case of retrograde and anterograde amnesia following hemorrhage from an arteriovenous malformation situated close to the retrosplenium of the corpus callosum. They termed this amnesia "retrosplenial amnesia". Subsequently, a few cases of retrosplenial amnesia caused by brain infarction or hemorrhage were reported [9,10]. In all the patients, amnesia was permanently continued.

Recently, several authors reported that TGA occurred in the patients with acute infarction in the hippocampus with and without lesions in other posterior-circulation areas, including the retrosplenium of the corpus callosum [2]. In the present case, the lesion was restricted to the retrosplenium of the corpus callosum.

Some investigators indicated a relationship between TGA and PFO. In a study by Klotzsch et al. [11], PFO was observed in 55% of 53 TGA patients, being more frequent than the 27% of 100 control subjects. Brain infarction associated with PFO trends to occur more frequently in the posterior circulation than in the anterior circulation [12]. Our patient had PFO and possible DVT in the right leg. Therefore, we strongly suspected he had a paradoxical embolism.

TGA has been associated with epilepsy [13] as well as ischemia [2–4]. Some cases caused by epileptic mechanism, called transient epileptic amnesia, have been reported [14,15]. The abnormality of EEG, short duration, reoccurrence, good response to antiepileptic drugs may help in the differential diagnosis with TGA. In our case, he had no abnormalities on EEG. Therefore, we diagnosed that TGA in our case was caused by ischemia.

It might be difficult to conclude that the ischemic lesion in the retrosplenium of the corpus callosum caused TGA in the present patient. First, it was possible that an embolus might occlude transiently arteries supplying the thalamus, hippocampus and other regions important for memory

during the TGA attack. DWI could not always detect transiently ischemic lesions. Second, the lesion was too small to calculate the ADC value. Therefore, it lacked definite evidence that the hyperintense lesion on DWI was an acute infarct. However, this case may aid in characterizing the relationship between lesions and etiology of TGA.

Acknowledgements

This study was supported in part by Research Grants for Cardiovascular Disease (12A-4, 14C-1) from the Ministry of Health, Labor and Welfare of Japan and by Special Coordinating Funds for Promoting Science and Technology (Strategic Promotion System for Brain Science) from the Science and Technology Agency of Japan.

References

- [1] Hodges JR, Warlow CP. The aetiology of transient global amnesia: a case-control study of 114 cases with prospective follow-up. *Brain* 1990;113:639–57.
- [2] Hakan A, Karen LF, Kei Y, Walter JK. Diffusion-weighted MRI characterizes the ischemic lesion in transient global amnesia. *Neurology* 1998;51:901–3.
- [3] Matsui M, Imamura T, Sakamoto S, Ishii K, Kazui H, Mori E. Transient global amnesia: increased signal intensity in the right hippocampus on diffusion-weighted magnetic resonance imaging. *Neuroradiology* 2002;44:235–8.
- [4] Woolfenden AR, O'Brien MW, Schwartzberg RE, Norbash AM, Tong DC. Diffusion-weighted MRI in transient global amnesia precipitated by cerebral angiography. *Stroke* 1997;28:2311–4.
- [5] Gass A, Gaa J, Hirsch J, Schwartz A, Hennerici MG. Lack of evidence of acute ischemic tissue change in transient global amnesia on single-shot echo-planar diffusion-weighted MRI. *Stroke* 1999;30:2070–2.
- [6] Zorzon M, Antonutti L, Mase G, Biasutti E, Vitrani B, Cazzato G. Transient global amnesia and transient ischemic attack: natural history, vascular risk factors, and associated conditions. *Stroke* 1995;26:1536–42.
- [7] Olsen J, Jorgensen MB. Leao's spreading depression in the hippocampus explains transient global amnesia: a hypothesis. *Acta Neurol Scand* 1986;73:219–20.
- [8] Valenstein E, Bowers D, Verfaellie M, Heilman KM, Day A, Watson RT. Retrosplenial amnesia. *Brain* 1987;110:1631–46.
- [9] Takayama Y, Kamo H, Ohkawa Y, Akiguchi I, Kimura J. A case of retrosplenial amnesia. *Clin Neurol* 1991;31:331–3.
- [10] Kasahata N, Kawamura M, Shiota J, Araki S, Sugita K. A case of verbal amnesia due to left retrosplenial lesion. *Jpn J Stroke* 1994;16:290–5.
- [11] Klotzsch C, Sliwka U, Berlit P, Noth J. An increased frequency of patent foramen ovale in patients with transient global amnesia. *Arch Neurol* 1996;53:504–8.
- [12] Gautier JC, Durr A, Koussa S, Lascault G, Grosgeat Y. Paradoxical cerebral embolism with a patent foramen ovale. *Cerebrovasc Dis* 1991;1:193–202.
- [13] Fisher CM, Adams RV. Transient global amnesia. *Acta Neurol Scand* 1964;40:7–83.
- [14] Pritchard PB, Holmstrom VL, Roitzsch JC, Giacinto J. Epileptic amnesic attacks: benefit from antiepileptic drugs. *Neurology* 1985;35:1188–9.
- [15] Zeman AZJ, Boniface SJ, Hodges JR. Transient epileptic amnesia: a description of the clinical and neuropsychological features in 10 cases and a review of the literature. *J Neurol Neurosurg Psychiatry* 1998;64:435–43.