

Differential Diagnosis of Dementia: Clinical Examination and Laboratory Assessment

Michael S. Mega, MD, PhD

Director, Memory Disorders and Alzheimer's Disease Clinic
Department of Neurology, Laboratory of Neuro Imaging,
and UCLA Alzheimer's Disease Research Center
UCLA School of Medicine
Los Angeles, California

Recent breakthroughs in putative disease-modifying interventions for Alzheimer's disease (AD) underscore the urgency of making the earliest possible diagnosis. In the absence of a convenient and reliable laboratory test for AD, the clinical assessment is still the cornerstone of the diagnostic approach. This article provides a basis for conducting an assessment within the realities of a busy clinical practice for patients complaining of cognitive decline. The assessment will enable the clinician to diagnose the earliest manifestation of AD.

Dementia is a syndrome that, like fever, requires a systematic evaluation to identify its many causes (**Table I**). In the United States, 2 definitions are applied to the syndrome of dementia. The first defines dementia as an acquired, persistent decline involving at least 3 of the following 5 domains: language, memory, visuospatial skills, executive function (calculation, abstraction, judgment, etc), and personality and mood (1). Persistent decline from previous function must not be secondary to delirium. Furthermore, memory dysfunction is not required to meet the above criteria, thus allowing the stroke patient with aphasia, depression, and poor executive function — but intact memory — to meet dementia criteria. The second, more constrained definition (2) requires impairment in short- and long-term memory with additional decline in at least 1 other domain (eg, abstraction, judgment, language, praxis, visuospatial skills, or personality) that interferes with either occupational or social functioning or interpersonal relationships.

Abnormalities cannot be secondary to delirium and should not be based on “nonorganic” causes (eg, depression, schizophrenia). The application of this more constrained definition and its criteria is often hampered in the nursing home setting where no social or occupational challenges exist but where patients frequently manifest an acquired, persistent decline in multiple domains. Although dementia prevalence estimates are affected by the dementia criteria applied (3), 75% of patients with moderate to severe dementia and >95% with mild impairment escape diagnosis in the primary care setting (4).

Clinical diagnostic criteria for probable Alzheimer's disease (AD) (5) and vascular dementia (VaD) (6), the 2 most common causes of dementia in the elderly, have helped standardize the assessment and diagnosis of these disorders. These criteria are provided, along with their typical clinical profiles, in **Table II** and **Table III**. A “definite” diagnosis of most dementia disorders can be made from pathologic evaluation only. The accu-

TABLE 1. MAJOR CAUSES OF DEMENTIA BASED ON CORTICAL, SUBCORTICAL, OR MIXED DYSFUNCTION*

<i>Cortical</i>	<i>Mixed</i>
Alzheimer's disease	Multiinfarct dementia
Frontal lobe degeneration	Infections
	Slow virus dementias
<i>Subcortical</i>	General paresis
Extrapyramidal syndromes	Toxic/metabolic encephalopathies
Lewy body disease	Systemic illnesses
Parkinson's disease	Endocrinopathies
Huntington's disease	Deficiency states
Progressive supranuclear palsy	Drug intoxications
Wilson's disease	Heavy metal exposure
Spinocerebellar degeneration	Industrial toxins
Fahr's disease	Miscellaneous syndromes
Hydrocephalus	Posttraumatic
Dementia of depression	Postanoxic
Demyelinating disease	Neoplastic
HIV encephalopathy	
Vascular dementias	
Lacunar state	
Binswanger's disease	

*The differential diagnosis of infrequent dementia etiologies is broad and should be conducted by a neurologist. Adapted with permission from Cummings JL, Benson DF. *Dementia: A Clinical Approach*. Boston, Mass: Butterworth-Heinemann; 1992.

cy of the clinical diagnosis of AD, compared with pathologic assessment, has increased from above 80% to above 90% over the last 2 decades, due mainly to the application of these clinical diagnostic criteria (7,8).

CLINICAL EXAMINATION

The essential elements of the mental status examination include the assessment of 5 cognitive domains: language, memory, visuospatial function, executive function (the ability to manipulate previously acquired knowledge, eg, multitasking, abstraction, judgment, calculation), and personality and mood. A patient's performance across the 5 domains reveals distinct clinical profiles for various dementia etiologies. The criteria for AD and VaD listed in **Table II** and **Table III** underscore a contrast in the profiles of these 2 disorders.

The classic profile of cognitive dysfunction in AD is typically one of a progressive memory-encoding defect called *amnesia* (long-term memory is also

KEY POINT

Dementia is a syndrome that, like fever, requires a systematic evaluation to identify its many causes.

eventually affected), empty speech with loss of the meanings of words, poor visuospatial skills, executive dysfunction with loss of insight into the severity or even presence of these deficits, and personality change marked by prominent apathy with psychosis and agitation later in the disease course. Motor abnormalities are absent until the severe stage.

This profile contrasts with the typical presentation of VaD (9) that has a memory-retrieval deficit (with usually spared long-term memory), loss of word retrieval, occasional visuospatial defects, and poor executive function with personality change, also

TABLE II. CRITERIA FOR PROBABLE ALZHEIMER'S DISEASE AND VASCULAR DEMENTIA*

Criteria for the Diagnosis of Probable Alzheimer's Disease (5)

1. Dementia present
2. Onset between 40 and 90 years of age
3. Deficits in 2 or more cognitive areas
4. Progression of deficits >6 months
5. Consciousness undisturbed
6. Absence of other reasonable diagnosis

Criteria for the Diagnosis of Probable Vascular Dementia (6)

1. Dementia present
- 2a. Focal neurologic signs
- 2b. Vascular lesion(s) on brain imaging
3. A relationship between 1 and 2 with either
 - Onset within 3 months of a stroke
 - Abrupt cognitive deterioration
 - Fluctuating stepwise progression

*The best that can be achieved in the premorbid diagnosis for these and most other degenerative disorders is a "probable" diagnosis. (The diagnosis shifts to "possible Alzheimer's disease" if another brain-based disorder is present but does not significantly contribute to the clinical picture or if there is an atypical presentation. "Possible vascular dementia" is met if the 3-month time requirement is not achieved.)

marked by prominent apathy but rare psychosis. VaD patients have vascular risk factors (eg, hypertension, diabetes, cardiac disease) and a decline that is usually gradual, not stepwise. Abnormalities are always present on structural imaging. Focal findings on neurologic examination may be subtle, such as a decreased arm swing on one side only during "stressed" gait when the patient is asked to walk on the toes or heels. Other common neurologic signs and symptoms are dysarthria, parkinsonism, incontinence, and gait difficulty.

Early in the course of the disease, the characteristic profiles of AD and VaD underscore the importance of approaching dementia as a syndrome with the goal of distinguishing the specific diagnosis from normal aging or reversible causes. Even rapid initial evaluation reveals distinct clinical profiles for patients with different types of dementia (10). Cognitive assessment of patients with the earliest dementia is a daunting task and often requires formal neuropsychologic testing; in pre-clinical cases a follow-up evaluation separated by 9 months or more is necessary to prove the existence of an acquired, persistent decline. The Mini-

KEY POINT

The essential elements of the mental status examination include assessment of 5 domains: language, memory, visuospatial function, executive function, and personality and mood. A patient's performance across these domains reveals distinct clinical profiles for various dementia etiologies.

Mental State Examination (MMSE) (11) is a widely used tool with norms adjusted for age and education (12). Unfortunately, a "ceiling effect" (scores of ≥ 26 of 30) is found when applying the MMSE to the early AD patient. The assessment of the 5 domains for a patient with a near-normal MMSE within a 15-minute clinical evaluation is provided below.

Attention (1 minute)

Delirium must first be ruled out to ensure the

TABLE III.

CHARACTERISTIC CLINICAL PROFILE FOR ALZHEIMER'S DISEASE AND VASCULAR DEMENTIA

Profile of Alzheimer's Disease (Cortical Profile)

Intact attention
 Poor long- and short-term memory, amnesia typical
 Poor language, loss of word meaning
 Poor visuospatial function
 Poor executive function
 Prominent apathy with psychosis and agitation later in disease
 Absence of focal lesions on exam or imaging

Profile of Vascular Dementia (Subcortical Profile)

Intact attention
 Poor short-term memory, retrieval deficit typical
 ± Language, loss of word retrieval
 ± Visuospatial function
 Poor executive function
 Prominent apathy with rare psychosis
 Presence of focal lesions on exam or imaging

patient is capable of paying attention during the examination of the cognitive domains. The best test of attention is digit span; 7 plus or minus 2 digits forward and 5 plus or minus 1 digit backward is normal. This simple test, correctly performed, rules out the large differential diagnosis of confusional states, or delirium, and allows the clinician to proceed with the mental status test.

Language (1 minute)

A detailed language evaluation includes an assessment of fluency, comprehension, naming, repetition, reading, and writing. Most early AD patients perform well on the clinical assessment of language, thus a detailed language exam is impractical in the primary care setting. The best rapid evaluation of the distributed regions subserving language is a 1-minute verbal fluency task. The naming of the members of a given category (eg, animals) is an executive language function that has well-documented age- and education-based norms (13). For a high-school-educated person, the mean number of animals named in 1 minute is 18 and the lower limit of normal is 12. The early AD patient can rarely produce more than 10 animals in 1 minute.

Although sensitive, verbal fluency is not a specific test; frontal subcortical vascular disease will also impair a patient's verbal fluency performance.

Memory (7 minutes)

Most of the clinical evaluation is concentrated on the memory examination. Memory testing should distinguish between an amnesic disorder (ie, inability to *learn* new information), which is typically seen in AD, and a retrieval deficit (ie, difficulty *accessing* previously learned material), which is the hallmark of normal aging when seen in isolation and the hallmark of subcortical dementias like cerebral vascular disease when accompanied by executive dysfunction. Distinguishing between these 2 memory disorders is possible by using a 5- to 10-word list and asking the patient to recite back the list after each of 3 presentations. The number of correctly recited items for each presentation is recorded, providing a learning curve for the task and assuring the examiner of attempted encoding. After a 5-minute delay occupied with the other mental status tasks described on the next page, the patient is asked to recall as many of the presented items as possible.

Any item not produced during free recall should then be cued with a category clue. For example, if one of the words not recalled is “dog,” then the examiner would ask the patient, “One of the words you missed was an animal. Does that help?” If the category clue does not help the patient retrieve the item, then the examiner should next give a multiple-choice clue: “Was the animal a cat, dog, or bird?” If category or multiple-choice clues result in significant improvement in the number of items produced by the patient over the number spontaneously recalled, then the patient is considered to have a retrieval deficit disorder, not amnesia. New information is learned but there is difficulty in retrieving it; thus, cues help the patient. In memory testing it is important to distinguish between amnesia and a retrieval deficit because in AD, as opposed to other dementing disorders, amnesia is prominent (10).

Visuospatial Skills (2 minutes)

Early visuospatial dysfunction is subtle in AD patients, and 2-dimensional copying tasks are usually performed well. The earliest changes in the visuospatial domain are best demonstrated with 3-dimensional copying—can the patient draw a cube with internal lines—or by an assessment of map localization skills by history—does the patient get lost in familiar environments. Another method of determining changes in this domain is by asking the patient questions about overlearned routes—“How would you drive from your house to the closest market?”—in the presence of a family member who can confirm the answer.

Executive Function (2 minutes)

Executive function is defined as the ability to manipulate previously acquired knowledge. Multitasking is an exquisite test of executive function, perhaps best demonstrated during the preparation of a large meal when all dishes must arrive well prepared at the same time. Calculations with 1- and 2-digit equations and simple word problems, as well as abstractions using similarities and proverb interpretation, test the patient’s ability to manipulate knowledge (ie, cognition). Executive functions are traditionally considered frontal system tasks. Frontal system function also can be assessed throughout the

entire clinical interview by noting any evidence of perseveration, disinhibition, or easy distractibility.

Personality and Mood (2 minutes)

In addition to conducting an organized assessment of the 4 cognitive domains, persistent changes in personality and mood, the 5th domain, should be identified either by observation during the exam or by querying the spouse or caregiver. Often in AD, before any changes in cognition are noted, subtle changes in the patient’s personality (eg, apathy or depression) occur that may represent significant risk factors for ensuing AD (14, 15). Behavior can be rapidly assessed in the office with the Neuropsychiatric Inventory (NPI) (16), a reliable and valid instrument capable of assessing 10 common behaviors in dementia patients. **Figure 1** shows the spectrum of behaviors captured by the NPI across the range of disease severity in AD (17). Disengagement and apathy are the most common early behavioral changes. Agitation, common in advanced patients, is a management challenge and may manifest as motor restlessness or as oppositional aggressiveness. The source of agitation is often delusions, which affect 30% to 50% of patients, mainly those in the middle phase of the illness. Delusional patients exhibit a more accelerated cognitive decline than patients without delusions. Mood changes span elation (in 5% to 20% of AD patients) to depression (20% to 40%). Anxiety concerning upcoming events, psychomotor agitation, wandering, or pacing pose some of the most difficult management problems. Neuroleptics may exacerbate psychomotor agitation by inducing akathisia. Behavioral changes present the greatest challenge in the treatment of AD patients.

When the results of the clinical assessment and history suggest the dementia syndrome, laboratory and imaging studies should be ordered to rule out reversible causes of cognitive decline and assist the accurate diagnosis. **Figure 2** provides an overview of the assessment process.

LABORATORY ASSESSMENT

Laboratory assessment of patients with a question of dementia is targeted at identifying reversible causes. With the improvement in primary care

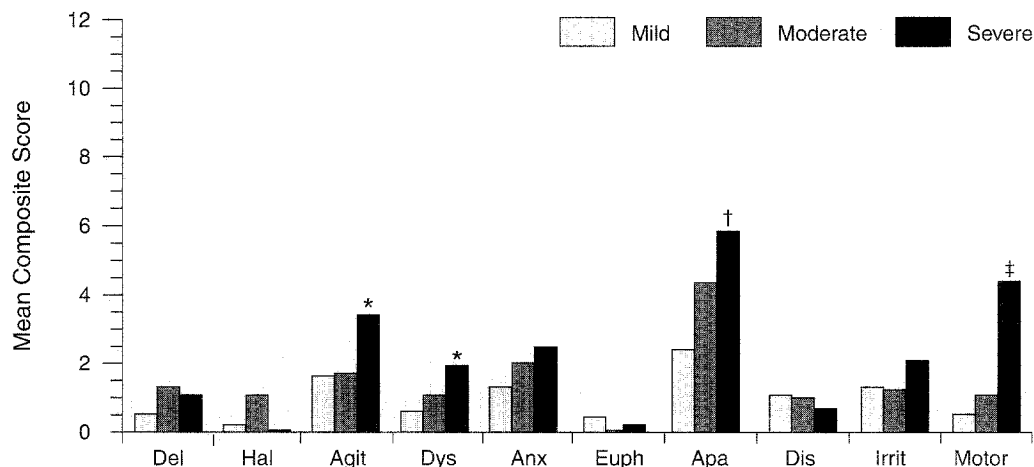


Figure 1. Mean composite subscores of the 10 Neuropsychiatric Inventory behaviors across the 3 Mini-Mental State Examination (MMSE) groups. Mild = MMSE scores 21–30; Moderate = MMSE scores 11–20; Severe = MMSE scores 0–10. Del = delusions; Hal = hallucinations; Agit = agitation; Dys = dysphoria; Anx = anxiety; Euph = euphoria; Apa = apathy; Dis = disinhibition; Irrit = irritability; Motor = aberrant motor behavior.

*Significantly different from mild group ($P < 0.05$).

†Significantly different from mild group ($P < 0.01$).

‡Significantly different from all groups ($P < 0.01$).

Adapted with permission from Mega MS, Cummings JL, Fiorello T, Gornbein J. The spectrum of behavioral changes in Alzheimer's disease. *Neurology*. 1996;46:130–135.

screening, the percentage of patients with a reversible dementia presenting to specialty memory disorder clinics has declined from 11% in 1972 to 1% in 1994 (18). Laboratory and structural imaging studies are required (Table IV) in the initial assessment to identify reversible causes as well as focal lesions, significant white matter disease implicating VaD and preventive treatment, or significant medial temporal atrophy consistent with AD. Repeated imaging studies after a diagnosis is made are unnecessary unless an acute process is suspected. In AD, functional studies such as positron emission tomography (PET) or single-photon emission computed tomography (SPECT) typically show abnormalities most marked in the parietal and temporal lobes bilaterally (Figure 3) and are most useful in differentiating early AD from normal aging or frontotemporal degeneration but are not required in the dementia evaluation (19). Apolipoprotein E genotyping is not useful in isolation in applying the clinical criteria of AD but may increase specificity of the diagnosis (correctly iden-

tifying those without the disease) when patients do not have the $\epsilon 4$ allele if the diagnosis is in question (20). Another potential biomarker is the combined assessment of cerebral spinal fluid amyloid $\beta_{(1-42)}$ protein ($A\beta_{42}$) and tau concentrations (low $A\beta_{42}$ protein with high tau) that have a positive predictive value of 90% and negative predictive value of 95% based on the clinical diagnosis of probable AD (21). The best current biomarker based on the pathologic diagnosis of definite AD, and superior to the clinical diagnosis of probable AD, is the combination of medial temporal atrophy on structural imaging with parietal impairment on functional imaging (22).

Routine laboratory studies are most crucial when acute changes in mental function or behavior are evident. Under these circumstances the evaluation of reversible causes of delirium must be thorough. Increased confusion or obtundation inappropriate for a patient's stage of dementia may be secondary to infection; thus, blood and urine cultures should be obtained even in the absence of a

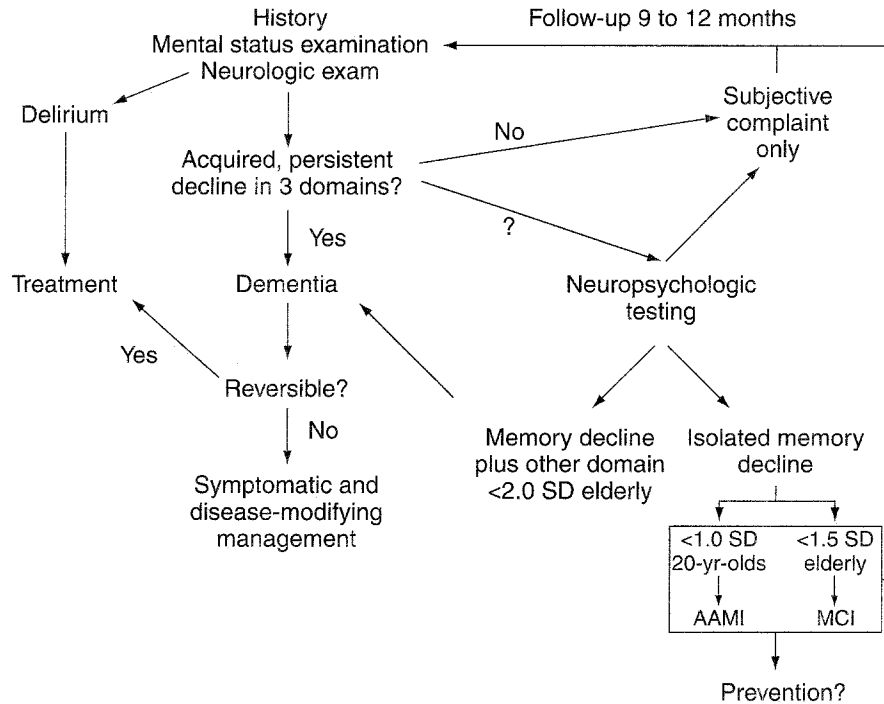


Figure 2. Flowchart of the assessment of a patient complaining of cognitive decline. AAMI = age-associated memory impairment; MCI = mild cognitive impairment.

KEY POINT

The combination of medial temporal atrophy on structural imaging with parietal impairment on functional imaging may be the best current biomarker of AD based on the pathologic diagnosis of definite AD.

fever or elevated white blood cell count. Dehydration is often a major cause of decompensation in the institutionalized elderly. Electrolyte tests should be obtained if dehydration is suspected. Patients in the advanced stages of dementia are particularly sensitive to the adverse sedative effects of medications; thus, pharmacologic regimens should be reviewed and drugs discontinued as appropriate. All management changes and interventions must be negotiated with the patient's family because they often do not want life-prolonging measures for their relative.

CASE STUDY

First Evaluation

A 75-year-old, right-handed woman was taken by her husband to a memory disorders clinic complaining of a 3- to 5-year history of decline in memory. The history was provided mainly by the patient's husband who said that 5 years prior to presentation he first noticed abnormalities in his wife's ability to operate a new videocassette recorder and a new 35-mm camera. He also reported a decline in her ability to cook large meals for dinner parties, which first began 3 years prior to presentation. Approximately 2 years prior to presentation, he began noticing difficulty with his wife's memory such that she was unable to shop for food without a detailed list. She frequently forgot conversations that transpired between them or episodes that had occurred days prior. Approximately 6 months prior to presentation, he noted that she forgot which cards were played in their bridge club when previously she had been an excellent player. The patient agreed with the history of memory problems but felt that her cooking was unaffected.

TABLE IV.

LABORATORY EVALUATION FOR DEMENTIA

Required Laboratory Tests

Complete blood count
Serum electrolytes, calcium, glucose, blood urea nitrogen/creatinine and liver function tests
Thyroid-stimulating hormone, free thyroid index
Serum vitamin B₁₂
Structural imaging study (CT or MRI)

Optional Laboratory Tests

Syphilis serology
Sedimentation rate
HIV testing
Chest x-ray
Urinalysis, 24-hour urine for heavy metals, toxicology screen
Neuropsychologic testing
Lumbar puncture
Apolipoprotein E genotyping, A β ₄₂/tau cerebral spinal fluid analysis
Electroencephalography
Single-photon emission computed tomography
Positron emission tomography

Both the patient and her husband denied any problems with language function, visuospatial function, or any change in personality or mood. The patient continued to be quite active socially and took part in community activities. Despite her memory problem, she was still capable of functioning almost independently with copious listkeeping.

Medical history. The patient had a history of mild hypertension treated with an angiotensin-converting enzyme inhibitor. She had undergone a hysterectomy. The patient was receiving treatment with captopril and estrogen. In addition, she reported taking multivitamins and ginkgo biloba. Family history, social history, and general examination were unremarkable.

Mental status. The patient's attention was intact on digit span: 6-digits-forward, 5-digits-backward. Her MMSE score was 28 of 30; she missed 2 recall questions. Language was normal for expression, comprehension, and repetition. Naming was intact, with 15 of 15 items on a modified Boston Naming Test correctly identified. Verbal fluency showed 19 animals produced in 1 minute, and reading and

writing ability were entirely normal. Memory testing using a 10-word list (23) showed a learning curve of 4, 6, and 8 after 3 trials; after a 5-minute interval with interference, the patient spontaneously recalled 1 of the 10 words. Recognition performance, using 10 target items and 10 foils, produced 5 additional items with 3 false-positives. Visuospatial function showed no problem in copying a 2-dimensional figure and some mild strategy difficulty but good copying of a 3-dimensional cube. Executive function showed no problem with calculation ability for 2-digit addition and multiplication; however, word problems showed some hesitancy and difficulty in response, although answers were eventually correct. Frontal system evaluation showed no perseveration or loss of set; reciprocal programs, go-no-go, and alternating programs were all intact. (See Cummings and Benson [10] for an overview of this neurobehavioral examination.) The elemental neurologic exam was entirely normal.

Diagnostic studies. On the initial evaluation, the patient underwent formal neuropsychologic testing, functional imaging with [¹⁸F]-fluorodeoxyglucose positron emission tomography (FDG-PET), and

structural imaging with 3-dimensional coronal volumetric and double-echo magnetic resonance imaging (MRI). Neuropsychologic evaluation revealed a normal full-scale intelligence quotient. Language evaluation was intact except for animal naming, which was in the low-average range. Verbal and nonverbal memory testing showed impairments on encoding and storage that were >1.5 standard deviations (SD) below age- and education-matched norms. Executive function showed spotty performance, with 2 of 4 tests at approximately 1 SD below age- and education-matched norms. Interpretation of neuropsychologic testing concluded that the patient did not meet criteria for dementia according to the *Diagnostic and Statistical Manual of Mental Disorders, Fourth Edition* (2); however, the patient did meet criteria for an amnesic disorder in that memory was the only domain significantly affected for both encoding and storage. FDG-PET showed essentially normal metabolism in the frontal, parietal, and occipital cortices as well as subcortical structures, but demonstrated decreased metabolism in medial temporal lobe regions, left greater than right (**Figure 4**).

MRI analysis showed no significant cerebrovascular disease either cortically or subcortically without masses or cortical atrophy; however, there was mild to moderate volume loss in medial temporal structures by qualitative assessment. Laboratory evaluation showed normal chemistry panel-20, complete blood count, thyroid stimulating hormone, and vitamin B₁₂ levels; a negative fluorescent treponemal antibody absorption test; and a normal erythrocyte sedimentation rate.

Diagnosis. The history, examination, and diagnostic studies at initial evaluation invoked the following differential diagnosis: amnesic disorder. The patient also met criteria for mild cognitive impairment (24–27), as evidenced by at least one memory test score >1.5 SD below age- and education-matched norms in the absence of other significant abnormalities on neuropsychologic testing, except for some mild to moderate executive dysfunction as reflected in both history and neuropsychologic testing. Also, the possibility of preclinical AD could not be ruled out.

Second Evaluation

The patient returned for a follow-up visit approximately 1 year after the initial presentation. The interim history was significant for progressive declines in memory function with continued preservation of language and visuospatial function. The MMSE score was 27. Questionable executive dysfunction had evolved, with ensuing difficulty in preparing meals, balancing a checkbook, and paying household bills. Change in personality with moderate anxiety during social interactions also ensued over this interim period. Repeat neuropsychologic testing was significant for progressive decline in both verbal and visual memory, with scores >2 SD below age- and education-matched mean scores on memory tests, but still above 2 SD performance in executive function, and some improvement in visuospatial function with continued unimpaired language function. PET in comparison with the initial evaluation showed progressive metabolic declines in medial temporal structures (left greater than right) with continued preservation of metabolism in dorsolateral frontal, high parietal, and occipital cortices (**Figure 4**). Structural imaging showed no evidence of new cerebrovascular disease but progressive atrophy in medial temporal structures.

Differential diagnosis at follow-up suggested early AD, given the addition of executive dysfunction by history and the emergence of anxiety added to the memory dysfunction, thus implicating 3 domains with an acquired, persistent decline—a presentation sufficient to achieve the criteria for dementia.

Summary of Case Study

Their case study illustrates a typical assessment strategy directed toward a patient presenting with an early memory complaint. When a memory problem is reported with no clear etiology on clinical examination, laboratory assessment, or imaging evaluation, it is often necessary to follow the patient and repeat the entire evaluation in 9 months to 1 year if complaints persist. In this case study, a persistent decline was observed in >2 domains at the follow-up examination compared with the baseline assessment with normal laboratory findings and imaging that suggest a progressive process;

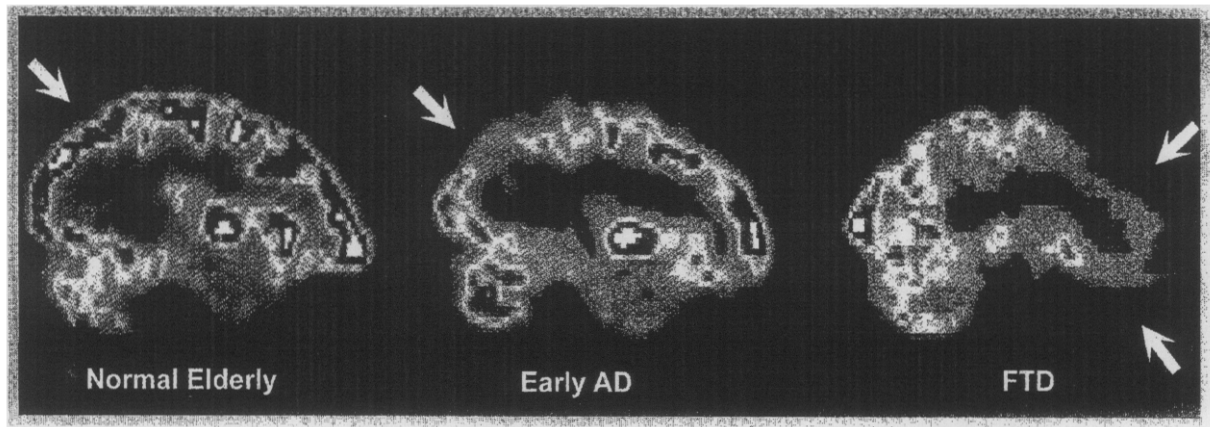


Figure 3. $[^{18}\text{F}]$ -fluorodeoxyglucose positron emission tomography of a normal patient (left), Alzheimer's disease (AD) patient (middle), and frontotemporal degeneration (FTD) patient (right). Note the decreased signal in the parietal regions for the AD patient (see arrows).

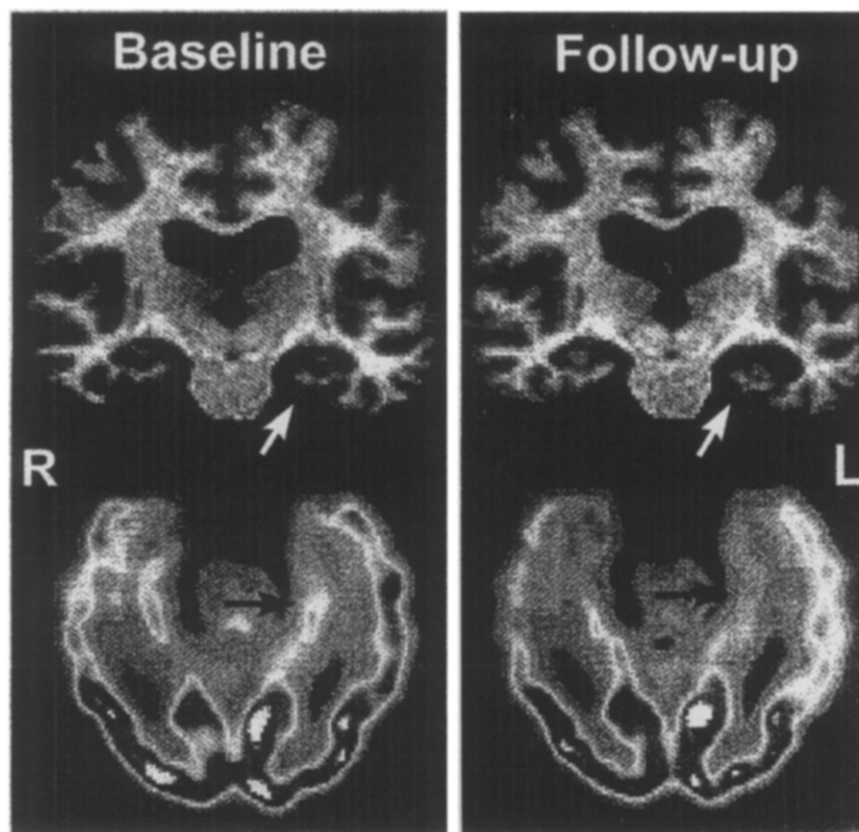


Figure 4. Coronal 3-dimensional magnetic resonance images and oblique axial slices through the long axis of the hippocampus of $[^{18}\text{F}]$ -fluorodeoxyglucose positron emission tomography at baseline evaluation and at follow-up 18 months later showing progressive atrophy and metabolic decline in left hippocampus for the patient described in the case study (arrows). Both scans were registered to the UCLA Alzheimer's Disease Atlas.

thus, a degenerative disorder is the most likely diagnosis. The diagnosis is made despite a near-normal MMSE. The patient's initial performance on the memory testing demonstrated a failure to learn information (ie, amnesia). Amnesia results from damage to the medial temporal lobe as seen in the patient's PET and follow-up MRI study, whereas a retrieval deficit usually occurs from either normal aging or frontal dysfunction.

CONCLUSIONS

Dementia is a syndrome that has multiple reversible and irreversible causes. The evaluation of the patient presenting with a cognitive complaint is assisted by an organized approach to the mental status examination that focuses a concise assessment of 5 domains: language, memory, visuospatial function, executive function, and personality and mood. AD and VaD, the 2 leading causes of dementia in the elderly, have specific clinical profiles that can be distinguished by the primary care physician. The earliest manifestation of AD can also be distinguished from normal aging but may require formal neuropsychologic testing and a follow-up evaluation, separated by a year, to confirm an acquired, persistent decline in multiple cognitive domains. The combination of structural imaging assessing medial temporal atrophy and functional imaging such as SPECT identifying parietal dysfunction may be the best current biomarker for early AD. The importance of diagnosing the earliest manifestation of AD is underscored by the rapid development of drugs that promise to slow the progression of the disease or its manifestation in those at risk.

REFERENCES

1. Cummings JL, Benson DF, LoVerne S. Reversible dementia: illustrative cases, definition, and review. *JAMA*. 1980;243:2434-2439.
2. APA. *Diagnostic and Statistical Manual of Mental Disorders, Fourth Edition*. Washington, DC: American Psychiatric Press; 1994.
3. Erkinjuntti T, Østbye T, Steenhuis R, et al. The effect of different diagnostic criteria on the prevalence of dementia. *N Engl J Med*. 1997;337:1667-1674.
4. Gifford DR, Cummings JL. Rating dementia screening tests: methodologic standards to rate their performance. *Neurology*. 1999;52:224-227.
5. McKhann G, Drachman D, Folstein M, et al. Clinical diagnosis of Alzheimer's disease: report of the NINCDS-ADRDA Work Group, Department of Health and Human Services Task Force on Alzheimer's Disease. *Neurology*. 1984;34:939-944.
6. Roman GC, Tatemichi TK, Erkinjuntti T, et al. Vascular dementia: diagnostic criteria for research studies. Report of the NINDS-AIREN International Workshop. *Neurology*. 1993;43:250-260.
7. Victorhoff J, Mack WJ, Lyness SA, Chui HC. Multicenter clinicopathological correlation in dementia. *Am J Psychiatry*. 1995;152:1476-1484.
8. Lopez OL, Becker JT, Klunk W, et al. Research evaluation and diagnosis of probable Alzheimer's disease over the last two decades: I. *Neurology*. 2000;55:1854-1862.
9. Looi JCL, Perminder SS. Differentiation of vascular dementia from AD on neuropsychological tests. *Neurology*. 1999;53:670-678.
10. Cummings JL, Benson DF. *Dementia: A Clinical Approach*. 2nd ed. Boston, Mass: Butterworth-Heinemann; 1992.
11. Folstein MF, Folstein SE, McHugh PR. "Mini-mental state": a practical method for grading the mental state of patients for the clinician. *J Psychiatry Res*. 1975;12:189-198.
12. Crum RM, Anthony JC, Bassett SS, Folstein MF. Population-based norms for the Mini-Mental State Examination by age and educational level. *JAMA*. 1993;269:2386-2391.
13. Lezak M. *Neuropsychological Assessment*. 2nd ed. New York: Oxford University Press; 1983.
14. Jorm AF, Van Duijn CM, Chandra V, et al. Psychiatric history and related exposures as risk factors for Alzheimer's disease: a collaborative re-analysis of case-control studies. EURODEM Risk Factors Research Group. *Int J Epidemiol*. 1991; 20(Suppl 2):S43-S47.
15. Geerlings MI, Schoevers RA, Beekman AT, et al. Depression and risk of cognitive decline and Alzheimer's disease. Results of two prospective community-based studies in The Netherlands. *Br J Psychiatry*. 2000;176:568-575.
16. Cummings JL, Mega MS, Gray K, et al. The Neuropsychiatric Inventory: comprehensive assessment of psychopathology in dementia. *Neurology*. 1994;44:2308-2314.
17. Mega MS, Cummings JL, Fiorello T, Gornbein J. The spectrum of behavioral changes in Alzheimer's disease. *Neurology*. 1996;46:130-135.
18. Weytingh MD, Bossuyt PM, van Crevel H. Reversible dementia: more than 10% or less than 1%? A quantitative review. *J Neurol*. 1995;242:466-471.
19. Mega MS, Thompson PM, Toga AW, Cummings JL. Neuroimaging in dementia. In: Mazziotta JC, Toga AW, Frackowiak R, eds. *Brain Mapping: The Disorders*. Orlando, Fla: Academic Press; 2000: 217-293.
20. Mayeux R, Saunders AM, Shea S, et al. Utility of the apolipoprotein E genotype in the diagnosis of

- Alzheimer's disease. *N Engl J Med.* 1999;338:506-511.
21. Andreasen N, Minthon L, Davidsson P, et al. Evaluation of CSF-tau and CSF-A β 42 as diagnostic markers for Alzheimer disease in clinical practice. *Arch Neurol.* 2001;58:373-379.
 22. Jobst KA, Barnettson LP, Shepstone BJ, and members of OPTIMA. Accurate prediction of histologically confirmed Alzheimer's disease and the differential diagnosis of dementia: the use of NINCDS-ADRDA and DSM-III-R criteria, SPECT, X-ray CT, and Apo E4 in medial temporal lobe dementias. Oxford Project to Investigate Memory and Aging. *Int Psychogeriatrics.* 1998;10:271-302.
 23. Fillenbaum GG, Beekly D, Edland SD, et al. Consortium to Establish a Registry for Alzheimer's Disease: development, database structure, and selected findings. *Top Health Inf Manage.* 1997;18:47-58.
 24. Petersen RC, Smith GE, Waring SC, et al. Mild cognitive impairment: clinical characterization and outcome. *Arch Neurol.* 1999;56:303-308.
 25. Boon AJW, Tans JTJ, Delwel EJ, et al. The Dutch normal-pressure hydrocephalus study. How to select patients for shunting? An analysis of four diagnostic criteria. *Surg Neurol.* 2000;53:201-207.
 26. Morris JC, Storandt M, Miller JP, et al. Mild cognitive impairment represents early-stage Alzheimer disease. *Arch Neurol.* 2001;58:397-405.
 27. Chui HC, Mack W, Jackson JE, et al. Clinical criteria for the diagnosis of vascular dementia. A multicenter study of comparability and interrater reliability. *Arch Neurol.* 2000;57:191-196.



Dialogue Box

ADVISORY BOARD

What is normal pressure hydrocephalus (NPH) and how is it diagnosed?

MEGA

NPH is a syndrome that requires the presence of enlarged ventricles on structural imaging without evidence of cerebral spinal fluid (CSF) outflow obstruction (ie, communicating hydrocephalus) and with lumbar puncture opening pressure in the high normal range (180 to 200 mm H₂O). The classic triad of gait difficulty, cognitive decline, and incontinence are rarely present in all cases. There is still no agreement on the diagnostic criteria or which clinical features best predict response to shunting.

ADVISORY BOARD

What is the advantage to the patient of making the diagnosis of mild cognitive impairment (MCI)? What is the potential downside?

MEGA

Given the promise of new treatments directed at slowing the course of the disease in AD patients and the benefit of early diagnosis for the imple-

mentation of these disease-modifying therapies, it would seem imperative to identify patients in the preclinical stage of the disease. Currently the best predictor of preclinical AD is the diagnosis of MCI since 30% to 50% of these individuals will develop AD in 3 to 5 years. The only potential disadvantage in making the diagnosis of MCI is the distress it may cause the patient and the increased short-term costs of medical treatment.

ADVISORY BOARD

Is the difficulty in clinically differentiating dementia and depression great enough that a trial of antidepressant medication is a strong consideration in most patients with dementia?

MEGA

When dementia is secondary to depression, the characteristic of the clinical profile is that of subcortical dysfunction (see Table I) with a retrieval-type memory deficit and relatively intact language and visuospatial function but poor executive function with decreased mood. Only patients with clear depression should be treated with antidepressant medications. If the dementia is due to depression, when the mood improves with treat-



Dialogue Box

ment so should the dementia; thus, the dementia of depression is a reversible dementia. If the cognitive deficit does not improve with the resolution of the mood disorder, then the clinician should suspect an alternate dementia diagnosis.

ADVISORY BOARD

Is the workup for dementia the same for patients seen in the earlier stages of dementia as opposed to those already severely impaired?

MEGA

When the severely impaired patient presents for an *initial* evaluation of dementia, then the clinical workup should include the required tests listed in Table IV. If this basic evaluation has been documented in the clinical record at a time when the dementia was present, then only a more focused evaluation should be conducted based on the clinical course or specific presenting signs that may be atypical for the patient's stage of the disease, such as a positive Babinski's sign in an ambulatory patient or a seizure in a mid-stage patient.

ADVISORY BOARD

What patients being worked up for dementia should have HIV testing included in their initial evaluation?

MEGA

Testing for HIV should not be routinely done. Only those patients at high risk for HIV exposure should have HIV testing included in their clinical evaluation of a dementia syndrome.

ADVISORY BOARD

Is performance of a nontreponemal serologic test adequate for excluding syphilis as the cause of the patient's dementia?

MEGA

When a patient is deemed at high risk for sexually transmitted diseases and has dementia, then a fluorescent treponemal antibody absorption test is preferred to screen for syphilis as the possible etiology of the dementia. If this is positive, a lumbar puncture must be performed to evaluate for any abnormality in CSF studies. If CSF abnormalities are present, treatment with high-dose intravenous penicillin G is recommended for 14 days.

ADVISORY BOARD

How accurately can the diagnosis of VaD be made clinically?

MEGA

The clinical criteria for VaD have poor interrater reliability, and the clinical diagnosis of VaD, based on pathologic assessment, shows a high overlap with AD pathology. Thus, pure VaD appears to be a rare disorder.

ADVISORY BOARD

In a patient with clinically suspected AD at any stage of the disease, which imaging method would you choose if you only had one chance at imaging?

MEGA

The best imaging method to evaluate a patient with dementia is an MRI study. It is now the recommendation of the American Academy of Neurology that a structural imaging study of some type be obtained from any patient evaluated for dementia to rule out mass or vascular lesions.