

Ö. N. Pamuk · N. Çakır · M. Soy · M. Aktoz
Y. Çelik · O. Akdemir

Mitral valve vegetation and cerebral emboli in a primary antiphospholipid syndrome patient who had hepatitis C virus infection: report of a case and review of the literature

Received: 27 May 2002 / Accepted: 12 August 2002
© Clinical Rheumatology 2003

Abstract We report the case of 36-year-old woman who came to us with a history of recurrent miscarriages and who was later diagnosed as having primary antiphospholipid syndrome (PAPS) and chronic hepatitis C virus (HCV) infection. The patient was referred to us with generalised seizures; cranial MRI revealed multiple embolic infarcts in both frontal lobes and a focal cortical infarct in the left frontoparietal lobe. Her echocardiography showed mitral valve vegetation and insufficiency. The patient was put on oral anticoagulant therapy and during her 8-month follow-up period no thrombotic events occurred. We report this case because it was the first in which PAPS, valvular disease, a cerebral embolic event and HCV infection were coexistent in the same patient. We also review other cases in which there was valvular vegetation and a cerebral ischaemic event associated with PAPS.

Keywords Anticardiolipin antibody (aCL) · Antiphospholipid syndrome (APS) · Cerebral embolic event · Hepatitis C virus (HCV) infection · Mitral valve vegetation

Introduction

Cardiac valvular abnormalities are reported in approximately one-third of primary antiphospholipid syndrome (PAPS) patients [1]. Different studies state that PAPS mostly involves the mitral valve and that the predominant functional abnormality is regurgitation [1–3]. Also, various reports claim that there is a close relationship between valvular lesions in PAPS and

cerebral ischaemic events [3,4]. In this report, we describe a patient with PAPS and hepatitis C virus (HCV) infection who presented to us with epileptic seizures, who had mitral valve vegetation and regurgitation and whose cranial MRI revealed multiple cerebral infarcts. We also summarise similar cases found in a search of Medline. In addition, we review the association between HCV, other viral infections, and the clinical manifestations of anticardiolipin antibodies (aCL).

Case report

A 36-year-old woman was hospitalised in our department with the complaint of two recurrent generalised seizures within the last month. Her past medical history revealed migraine headaches for 5 years and five abortions during 1989–1994, four of which were in the second trimester of pregnancy. No fetal abnormality had been diagnosed in any of the aborted fetuses. The patient had no any other symptom typical for any rheumatologic or neurologic disease. She had never smoked or used any drugs recently.

On physical examination her blood pressure was 120/80 mmHg, pulse rate 78/min and temperature 36.5°C. On cardiac auscultation a grade III pansystolic murmur on the apex was heard, radiating to the axilla. The spleen was palpated 2 cm below the costal margin. Neurological examination was normal.

The full blood count was as follows: Hb 10.7 g/dl; leukocytes 6400/mm³; lymphocytes 2100/mm³; platelets 94 000/mm³; ESR was 33 mm/h, CRP 0.3 mg/dl (N: 0–0.5), ALT, 24 U/L (N: 5–37); and AST was 21 U/L (N: 5–37). Blood biochemistry and urinalysis were within the normal ranges. Prothrombin time was 12 s (N: 10–13) and activated partial thromboplastin time (aPTT) 94 s (N: 23–34). VDRL test was positive at a titre of 0.5 and the microhaemagglutination assay test for *Treponema pallidum* was negative. The patient's lupus anticoagulant was detected in a dilute Russell's viper venom-based assay. Anticardiolipin antibody IgG (ELISA) was 67.7 GPL/U (N: 0–8), and IgM was 10.8 MPL/U (N: 0–8). Antinuclear antibody, rheumatoid factor, anti-dsDNA and cryoglobulin were negative. Serum C₃ complement was 36.3 mg/dl (N: 50–59) and C₄ complement <10 mg/dl (N: 10–40). HBsAg was negative; however, anti-HCV antibody and HCV-RNA (PCR) were positive.

Cranial MRI showed multiple small embolic infarcts in both frontal lobes, and also a focal cortical infarct in the left frontoparietal lobe. A transthoracic echocardiography was performed to find out the source of emboli and to explain the heart murmur. This

Ö. N. Pamuk (✉) · N. Çakır · M. Soy · M. Aktoz · Y. Çelik
O. Akdemir
Koca Sinan Mah, Sadık Ahmet Cad. Varlı Apt. No: 25 Daire:2,
Edirne, Turkey
Tel.: +90 284 235 00 01
E-mail: onpamuk80@hotmail.com

showed a hypoechogenic, oval-shaped, highly mobile vegetation on the mitral valve which was 7×9 mm in size (Fig. 1). Colour flow Doppler ultrasound examination revealed severe mitral valve regurgitation. The echocardiography was otherwise normal. Multiple blood cultures were obtained but no growth occurred in any of them.

The patient was diagnosed with PAPS and her cerebral ischaemic–thromboembolic event and mitral valve pathology were thought to be associated with PAPS. She was put on oral anticoagulant therapy with warfarin to prevent the possible thromboembolic complications of PAPS. She was also given carbamazepine as an antiepileptic. During the 8-month control period she had no neurological or other thromboembolic complications.

Discussion

Our patient, with recurrent fetal losses, prolonged aPTT, thrombocytopenia, positive lupus anticoagulant and the presence of aCL, was diagnosed as having PAPS. This was because she had no other clinical condition or drug intake that could lead to the formation of aCL and she did not fulfil the diagnostic criteria for SLE.

In our patient, the mitral valve vegetation and regurgitation were possibly related to the PAPS. In PAPS two different echocardiographic patterns can be present: valve masses (vegetations) and valvular thickening [1]. However, in one study it is claimed that vegetative lesions are more frequent in SLE, and irregular valvular thickening more frequent in PAPS [5]. Although there are studies which report that valvular disease in both PAPS and APS secondary to SLE is more frequent than in SLE [1,5,6], there are also studies which do not confirm this, or even which claim the opposite [1,2].

The development of cerebral ischaemic events in PAPS has a multifactorial aetiology. However, different studies say that the presence of aCL – whether there is underlying SLE or not – has a relationship with ischaemic neurologic events and valvular disease [3,4]. It is suggested that large and friable vegetations on the endocardial surface of mitral and aortic valves might be potential sources of emboli [1]. Another study reports that the presence of aCL in patients with mitral or aortic

valve regurgitation increases the risk of cerebral emboli [3,4]. In our case, the generalised seizures, multiple cerebral infarcts on cranial MRI and the mitral vegetation all have a cause-and-effect relationship. Although there are many cases reporting the association of mitral valve thickening and cerebral emboli, the coexistence of mitral vegetation and cerebral emboli in PAPS has been reported quite rarely. A summary of the some important features of such PAPS patients reported in the literature so far is given in Table 1 [3,7–12].

Antiphospholipids probably have no direct pathogenic role on valvular injury. Rather, they promote thrombus formation on immunologically damaged valvular endothelium, possibly owing to immune complexes [1,13]. In one study, immunoglobulin and complement component deposits were demonstrated by immunohistochemical methods on the injured valves of primary or secondary APS patients [14]. However, it is still not known whether the deposition of aCL is the primary event or secondary to another initiating event.

In one study [3] hypocomplementaemia was detected in most PAPS patients, similar to our case. Although the cause of hypocomplementaemia is not known for certain, it might be linked to circulating antigen–antibody complexes, complement consumption and activation owing to interaction between antibodies and the platelet membrane or the endothelial surface [3].

Our patient with PAPS also had chronic HCV infection. It is known that aCL are increased in hepatitis C and that HCV might play a role in the pathogenesis of APS [15]. It has also been reported that, in addition to HCV, various viral infections such as cytomegalovirus (CMV), parvovirus B19 and human immunodeficiency virus (HIV) might induce aCL [16]. Different studies reported that transient neurological deficits, cerebral perfusion defects, primary pulmonary hypertension and osteonecrosis in HIV infection were associated with aCL [17–19]. There was one report of a patient with APS and CMV infection who developed mesenteric and femoropopliteal thrombosis [20]. Although we know that these viral infections might induce aCL, the association between aCL in these infections and thrombotic events is less certain [21].

An increased incidence of aCL has been reported in HCV-infected individuals; however, these antibodies are usually at a low titre and the general consensus is that they are of no clinical significance [21–23]. There are also studies with contrary results which suggest that aCL in HCV infection are associated with thrombosis [15]. In addition, there was a report of one patient with chronic HCV infection and aCL-associated thrombotic disease who was administered interferon- α therapy [24]. This led to a complete biochemical and virological response, together with marked improvement of the thrombosis. There was relapse of viral hepatitis and recurrence of thrombosis with an increased aCL titre 3 months after the end of interferon treatment. This case might be proof that aCL-associated thrombosis was related to HCV infection. In our case, we do not know whether the

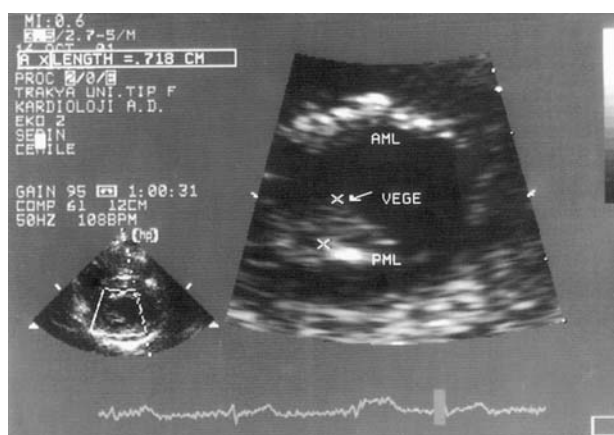


Fig. 1 A hypoechogenic, oval-shaped 7×9 mm mass compatible with a vegetation is seen on the atrial wall of the posterior mitral leaflet

Table 1 The general features of patients with primary antiphospholipid syndrome, mitral valve vegetation and cerebral ischaemic event

Case (reference)	Age/Sex	Echocardiography	Cerebral event	CT or MRI	Therapy	Follow-up	Outcome
Anderson et al. [7]	37/F	MR, MVV	TIA's	—	—	—	—
Asherson et al. [8]	—	MR, late MS, MVV	Chorea	—	—	—	—
Pope et al. [3]	43/F	MR, MVV, MVT	TIA, AF	MINF	Warfarin	4 yrs	infrequent AF
Pope et al. [3]	38/M	MT, MVV	AF	MINF	ASA + Warfarin	5 yrs	mild dizziness
Pope et al. [3]	23/M	MVP, MVV, MR	CVA	MINF	GC + Warfarin	5 yrs	mild seizures
Jafar et al. [9]	44/M	MVV, MR	Stroke	MINF	Warfarin	—	—
Nickele et al. [10]	46/F	MVM*	CVA	INF	MVR + Warfarin	4 mo	no problem
Skyrme-Jones et al. [11]	16/F	MVV	CVA	MINF	Warfarin	9 mo	resolution of MVV
Hino et al. [12]	50/F	MVV	CVA	INF	—	—	—
Our case	36/F	MVV, MR	Seizures	MINF	Warfarin	6 mo	no problem

* A mass not resembling a vegetation was detected on the mitral valve. Surgery revealed that the excised mass was a fibrin clot
 INF, cerebral infarct; MINF, multiple cerebral infarcts; MR, mitral regurgitation; MVV, mitral valve vegetation; MVT, mitral

valve thrombosis; MVP, mitral valve prolapse; MS, mitral stenosis; MVR, mitral valve replacement; CVA, cerebrovascular accident; AF, amaurosis fugax; TIA, transient ischaemic attack; GC, glucocorticoids; ASA, salicylates

hepatitis C was responsible for the presence of aCL. However, our case is interesting in that none of the PAPS cases with valvular abnormality and cerebral emboli reported until now had HCV infection.

In APS patients with thromboembolic events and those with aCL-associated valvular disease, secondary prevention of the thromboembolic process and anti-thrombotic therapy is indicated. In a large controlled series [25] it was shown that high-intensity (INR >3) oral anticoagulant therapy was quite effective in the prevention of thromboembolic events. However, there are also reports stating that lower-intensity treatment was equally effective [26]. Our patient was put on oral anticoagulant therapy only, with a target INR of 2.5–3, and no recurrence of thromboembolic phenomena occurred within 8 months.

As a result, in PAPS the frequently reported cerebral ischaemic events, mitral valve involvement and vegetations might be closely associated with one another. In case of any cerebral event in PAPS, the diagnostic method of choice is echocardiography, which might detect the probable source of emboli. In addition, anti-coagulant therapy must be instituted during the early period. To our knowledge, our case is the first in the literature in which cerebral emboli and cardiac valvular pathology were associated with PAPS and HCV infection. In spite of the numerous studies reporting contrary results, the association of aCL with the clinical manifestations of HCV and other viral infections needs to be determined.

References

- Hojnik M, George J, Ziporen L, Shoenfeld Y (1996) Heart valve involvement (Libman-Sacks endocarditis) in the antiphospholipid syndrome. *Circulation* 93: 1579–87
- Vianna JL, Khamashta MA, Ordi-Ros J et al. (1994) Comparison of the primary and secondary antiphospholipid syndrome: a European multicenter study of 114 patients. *Am J Med* 96: 3–9
- Pope JM, Canny CLB, Bell DA (1991) Cerebral ischemic events associated with endocarditis, retinal vascular disease, and lupus anticoagulant. *Am J Med* 90: 299–309
- Barbut D, Borer JS, Gharavi A et al. (1992) Prevalence of anticardiolipin antibody in isolated mitral or aortic regurgitation, or both, and possible relation to cerebral ischemic events. *Am J Cardiol* 70: 901–5
- Galve E, Candell-Riera J, Pigrau C, Permanyer-Miralda G, Garci-del-Castillo H, Soler-Soler J (1988) Prevalence, morphologic types, and evolution of cardiac valvular disease in systemic lupus erythematosus. *N Engl J Med* 319: 817–23
- Galve E, Ordi J, Barquinero J, Evangelista A, Vilardell M, Soler-Soler J (1992) Valvular heart disease in the primary antiphospholipid syndrome. *Ann Intern Med* 116(1): 43–7
- Anderson D, Bell D, Lodge R, Grant E (1987) Recurrent cerebral ischemia and mitral valve vegetation in a patient with antiphospholipid antibodies. *J Rheumatol* 14: 839–41
- Asherson RA, Lubbe WF (1988) Cerebral and valve lesions in SLE: association with antiphospholipid antibodies. *J Rheumatol* 15: 539–43
- Jafar MZ, Morgan MC, Gorcsan J (1994) Transesophageal echocardiographic detection of multiple mitral valve masses in primary antiphospholipid syndrome with stroke. *Am Heart J* 127: 445–6
- Nickele GA, Foster PA, Kenny D (1994) Primary antiphospholipid syndrome and mitral valve thrombosis. *Am Heart J* 128: 1245–7
- Skyrme-Jones RA, Wardrop CA, Wiles CM, Fraser AG (1995) Transesophageal echocardiographic demonstration of resolution of mitral vegetations after warfarin in a patient with the primary antiphospholipid syndrome. *J Am Soc Echocardiogr* 8: 251–6
- Hino H, Hashimoto Y, Hara Y, Terasaki T, Uchino M (1998) Brain infarct due to non-bacterial thrombotic valvular vegetation associated with primary antiphospholipid antibodies – a case report. *Rinsho Shinkeigaku* 38: 931–5
- Ford SE, Charette EJP, Knight J, Pym J, Ford P (1990) A possible role for antiphospholipid antibodies in acquired cardiac valve deformity. *J Rheumatol* 17: 1499–503
- Ziporen L, Goldberg I, Arad M et al. (1996) Libman-Sacks endocarditis in the antiphospholipid syndrome: immunopathologic findings in deformed heart valves. *Lupus* 5: 196–205
- Prieto J, Yuste JR, Belouqui O et al. (1996) Anticardiolipin antibodies in chronic hepatitis C: implications of hepatitis C virus as the cause of the antiphospholipid syndrome. *Hepatology* 23: 199–204

16. Dalekos GN, Zachou K, Liaskos C (2001) The antiphospholipid syndrome and infection. *Curr Rheumatol Rep* 3: 277–85
17. Rubbert A, Bock E, Schwab J et al. (1994) Anticardiolipin antibodies in HIV infection: association with cerebral perfusion defects as detected by 99mTc- HMPAO SPECT. *Clin Exp Immunol* 98: 361–8
18. Opravil M, Pechere M, Speich R et al. (1997) HIV-associated primary pulmonary hypertension. A case control study. Swiss HIV Cohort Study. *Am J Respir Crit Care Med* 155: 990–5
19. Brown P, Crane L (2001) Avascular necrosis of bone in patients with human immunodeficiency virus infection: report of 6 cases and review of literature. *Clin Infect Dis* 32: 1221–6
20. Labarca JA, Rabagliati RM, Radigan FJ et al. (1997) Antiphospholipid syndrome associated with cytomegalovirus infection: case report and review. *Clin Infect Dis* 24: 197–200
21. Ordi-Ros J, Villarreal J, Monegal F, Saucedo S, Esteban I, Vilardell M (2000) Anticardiolipin antibodies in patients with chronic hepatitis C virus infection: characterization in relation to antiphospholipid syndrome. *Clin Diagn Lab Immunol* 7: 241–4
22. Buskila D (2000) Hepatitis C-associated arthritis. *Curr Opin Rheumatol* 12: 295–9
23. Harada M, Fujisawa Y, Sakisaka S et al. (2000) High prevalence of anticardiolipin antibodies in hepatitis C virus infection: lack of effects on thrombocytopenia and thrombotic complications. *J Gastroenterol* 35: 272–7
24. Alric L, Oskman F, Sanmarco M et al. (1998) Association of antiphospholipid syndrome and chronic hepatitis C. *Br J Rheumatol* 37: 589–90
25. Khamashta MA, Cuadrado MJ, Mujic F, Taub NA, Hunt BJ, Hughes GRV (1995) The management of thrombosis in the antiphospholipid syndrome. *N Engl J Med* 332: 993–7
26. Prandoni P, Simioni P, Girolami A (1996) Antiphospholipid antibodies, recurrent thromboembolism, and intensity of warfarin anticoagulation. *Thromb Haemost* 75: 859