

Cervical Epidural Hematoma Causing Hemiparesis

A 75-YEAR-OLD woman had severe pain in the posterior area of her neck and shoulder and a slight right-sided hemiparesis. She had a 5-year history of angina pectoris and atrial fibrillation and had taken warfarin sodium for more than 5 years to prevent embolic events. She had also had a minor ischemic stroke at age 65 years. Neurological examination findings revealed a slight right-sided hemiparesis with hypesthesia to touch and pain in the right upper extremity. There was no unilateral facial paralysis. Her deep tendon reflexes were symmetrical bilaterally, and a Babinski sign was present in the right tendon. Routine laboratory testing revealed a prolonged prothrombin time of 21.9 seconds (international normalized ratio, 2.05). An electrocardiogram showed atrial fibrillation; there were no signs of cardiac ischemia. A computed tomographic scan of the brain revealed no abnormalities. The patient was admitted with the presumptive diagnosis of embolic cerebrovascular accident. Because the prothrombin time was el-

evated secondary to warfarin treatment, additional antiplatelet therapy was started.

Urinary retention developed 12 hours after antiplatelet therapy, and neck pain and motor disturbance worsened. Magnetic resonance imaging of the cervical spine revealed a cervical epidural hematoma (CEH) between levels C3 and C4 (**Figure**, A and B). Fresh frozen plasma and vitamin K were given to reverse anticoagulation, and an emergent decompressive laminectomy with hematoma removal was performed. She recovered and was discharged without neurological deficit 3 weeks postsurgery.

COMMENT

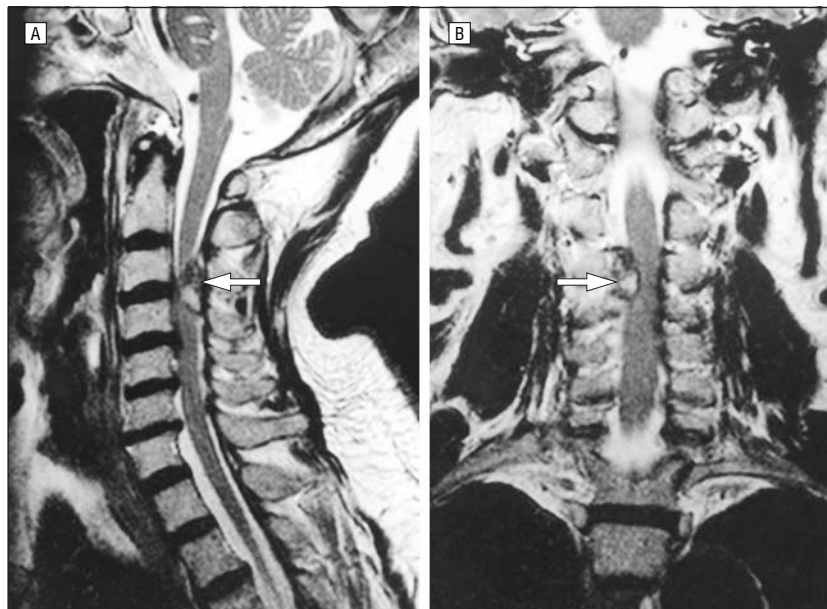
Cervical epidural hematoma is a rare but dangerous complication of anticoagulant therapy.¹ Hemiparesis is a common symptom of cerebrovascular accident but a rare feature of CEH.² It may be erroneously attributed to a cerebral cause, especially with preexisting cerebral embolic events. Although cervical radicular pain is one of the earliest symptoms and a hallmark of

CEH, it may be misattributed to a cardiac cause, particularly with preexisting coronary disease. This error can lead to the addition of anticoagulants or antiplatelet drugs, which can have grave consequences if CEH is the cause. It is important to establish whether hemiparesis is due to cerebral embolism because this requires completely different treatment from that caused by CEH. The possibility of CEH must be considered in any patient taking anticoagulant agents who complains of local or referred spinal pain associated with limb weakness, sensory deficits, or urinary retention. A high index of suspicion, prompt recognition, and immediate intervention are essential to prevent major morbidity from CEH.

Noriaki Sakamoto, MD
Tsukuba

Kiyoyuki Yanaka, MD, PhD
Department of Neurosurgery
Institute of Clinical Medicine
University of Tsukuba
Tsukuba, Ibaraki 305-8575
Japan

Yuji Matsumaru, MD, PhD
Tadao Nose, MD, PhD
Tsukuba



Sagittal (A) and coronal (B) T2-weighted magnetic resonance imaging scans showing the cervical epidural hematoma (indicated by white arrows).

Author contributions: Study concept and design (Drs Yanaka and Nose); acquisition of data (Drs Sakamoto and Matsumaru); analysis and interpretation of data (Drs Yanaka and Matsumaru); drafting of the manuscript (Dr Sakamoto); critical revision of the manuscript for important intellectual content (Drs Yanaka and Nose); obtained funding (Dr Yanaka); administrative, technical, and material support (Dr Yanaka); study supervision (Drs Yanaka and Nose).

REFERENCES

1. Harik SI, Raichle ME, Reis DJ. Spontaneously remitting spinal epidural hematoma in a patient on anticoagulants. *N Engl J Med.* 1971;284:1355-1357.
2. Groen RJ, van Alphen HA. Operative treatment of spontaneous spinal epidural hematomas. *Neurosurgery.* 1996;39:494-509.