



Agnosia for scenes in topographagnosia

Mario F. Mendez*, Monique M. Cherrier

Departments of Neurology and Psychiatry & Biobehavioral Sciences, University of California at Los Angeles, Los Angeles, CA 90073, USA

Received 24 January 2002; received in revised form 7 January 2003; accepted 7 January 2003

Abstract

Topographagnosia is most commonly attributed to an agnosia for landmarks. In order to define the nature of this agnosia, we studied a patient with isolated topographic disorientation (TD) after a stroke in the right medial occipitotemporal region. The patient got lost in familiar environments but could readily read and draw maps, describe familiar routes, and provide correct directions. He had normal perceptual test performance and met criteria for topographagnosia rather than for other forms of topographic disorientation. Two ecologically valid route tests assessed the nature of his agnosia. On a familiar route, he could recognize major landmarks. He could not, however, recognize route configurations made up of combinations of visual features each lacking individual distinctiveness. On a test of route learning, he learned landmarks that differed in minor details and could use them to orient himself along a route. He had difficulty, however, recognizing and learning scenes lacking salient landmarks. This agnosia for scenes was worse for semantically-related environments, but improved with semantic knowledge such as street names. In addition, the patient lacked overt prosopagnosia but tended toward semantic errors in the recognition of famous faces. Together these findings suggest that this patient's inability to recognize a route resulted from an inability of intact perceptual units for scenes, composed of specific visual configurations of individually indefinite features, from accessing stored representations.

© 2003 Elsevier Science Ltd. All rights reserved.

Keywords: Topographic disorientation; Environmental disorientation; Spatial agnosia; Visual agnosia; Prosopagnosia; Route(s)

1. Introduction

Topographic disorientation (TD) is the inability to find one's way in a familiar environments and to learn new routes. The concept of TD dates to Hughlings Jackson (1876) who described environmental difficulty in a patient with a glioma of the right temporal lobe (Jackson, 1932). Since then, clinicians have observed TD in posterior circulation strokes, dementia, and a number of other conditions. Studies examining neuroanatomic correlates of TD have implicated medial occipitotemporal regions, hippocampus, posterior parahippocampal gyrus, and parietal cortex, with right greater than left hemisphere involvement (Barrash, Damasio, Adolphs, & Tranel, 2000; Maguire et al., 1998; McCarthy, Evans, & Hodges, 1996).

The underlying cognitive mechanisms for TD are not entirely clear. TD is dissociable from other cognitive deficits and occurs without other explanatory perceptual or memory problems. Landmark recognition and spatial map construc-

tion are two important cognitive operations that assist navigation through familiar surroundings (Paterson & Zangwill, 1945). Accordingly, TD may be largely due to failure to recognize unique landmarks (topographagnosia) or to failure to retrieve spatial maps of an area (topographic amnesia) (De Renzi, Faglioni, & Villa, 1977; Hécaen, Tzortzis, & Rondot, 1980; Maguire, Burke, Phillips, & Staunton, 1996; McCarthy et al., 1996). Questions arise, however, about the role and extent of perceptual or memory changes. Both topographagnosia and topographic amnesia may have at least subtle perceptual changes and both usually involve spatial memory. For example, most patients with TD have both retrograde and anterograde memory difficulty for routes; only mild cases are restricted to impairments in navigating new routes (Habib & Sirigu, 1987).

This study examined a rare patient who lost the ability to find his way in familiar environments, but retained the ability to recognize landmarks. In the absence of agnosia for major landmarks, TD for familiar routes could result from visuospatial difficulties in integrating spatial relationships or an inability to access or retrieve adequate mental maps. Based on this patient's clinical presentation and history, we hypothesized that problems in recognizing complex visual scenes would prove to be the source of his TD. The study used ecologically valid route tests to determine the cognitive

* Corresponding author. Present address: Neurobehavior Unit (116AF), West Los Angeles Veterans Affairs Medical Center, 11301 Wilshire Blvd., Los Angeles, CA 90073, USA. Tel.: +1-310-478-3711x42696; fax: +1-310-268-4181.

E-mail address: mmendez@ucla.edu (M.F. Mendez).

difficulties associated with navigating a familiar route and learning a new route. These tests identified whether problems were more in the recognition of salient landmarks or of non-descript scenes. Further visuo-perceptual and visual memory tasks characterized whether the patient's TD was associated with perceptual problems, such as difficulty with visual integration, or with memory problems, such as difficulty with visuospatial learning.

2. Case report

GN, a 76-year-old, right-handed man, developed TD after a stroke. Initially, he complained of the acute onset of headache, dizziness and imbalance, and scintillations at the periphery of his left visual field. GN considered this his usual migraine headache but became alarmed when he experienced a "strobe light" effect while watching people move. As these acute symptoms resolved, he became aware of environmental disorientation. GN had difficulty finding his way in familiar surroundings such as the hospital and his neighborhood. In addition, he had difficulty seeing things in the upper left quadrant of his visual field.

His medical history was significant for recurrent migraine headaches since age 25, hypertension, coronary artery disease with prior bypass surgery, and a history of prostatic carcinoma removed by radical prostatectomy. His usual headaches began with an aura of warmth around his head, followed by throbbing pressure behind both eyes, nausea, phonophobia, and photophobia. His headaches responded well to caffeine and analgesics. His medications included amitriptyline (10 mg qhs), citalopram (20 mg), ranitidine (150 mg b.i.d.), verapamil (240 mg qd), and vitamin E and folic acid. GN had 16 years of education, worked in electronics, and had a negative history for familial diseases.

He underwent extensive mental status testing. GN scored a 29/30 on the Mini-Mental State Examination (Folstein, Folstein, & McHugh, 1975), missing one attentional item. His digit span was seven forward, and he performed normally on sustained attention tasks (e.g. the "A" vigilance test and months in reverse). Language examination revealed normal fluency, auditory comprehension, and repetition. He scored 14/15 on the abbreviated Mini-Boston Naming Test (Welsh et al., 1994) and generated a word-list of 18 "F" words in a minute. Reading and writing were intact. He was mildly impaired on an auditory verbal learning task, recalling 5/10 items spontaneously at 15 min and recognizing 8/10 without false positives. His remote memory was intact for current events and major historical incidents. On visuospatial tasks, he had normal constructions for three drawings, including a three-dimensional figure. On 5 min delayed recall, he failed to spontaneously recall the three test drawings but could recognize them from among 12 choices. There was no evidence of ideomotor apraxia, acalculia, digit agnosia, or right-left confusion. Frontal systems tasks such as alternating programs were normal.

His neurological examination was remarkable only for a visual field deficit in his upper left quadrant. The rest of his cranial nerves were intact. Coordination testing was normal and motor examination did not reveal abnormalities of power or tone. His reflexes were +2 and symmetrical without pathological reflexes, and his toes were downgoing. The sensory examination was intact to all modalities.

Magnetic resonance imaging (MRI) of the brain showed a large region of gyriform FLAIR and T2 weighted hyperintensity, and T1-weighted hypodensity, consistent with an infarction involving the right posterior-inferior temporal and occipital lobes, predominantly in the lingulus (see Fig. 1). MRI angiographic images of the great vessels of the neck showed normal appearing cerebral vasculature.

GN was diagnosed with a right posterior cerebral artery stroke and residual topographagnosic disorientation. The stroke was suspected to be migraneous in etiology, however, he was started on antiplatelet therapy (clopidogrel 75 mg). In addition to TD, the only other findings on his examination were mild memory retrieval difficulty and a persistent left quadrantanopia.

Further evaluation was undertaken at 2 months post-stroke. He was aware of his field cut, but denied other visual difficulties, such as problems with detecting depth, motion, color, or faces. He could not, however, find his way in his neighborhood, in previously traveled parts of the city, or around the hospital. Yet, he could give verbal directions of familiar routes, describe how to get out to the parking lot from the hospital, and instruct how to travel to his house. GN proudly described himself as having a "Thomas Street Guide" readily available in his mind. GN described his difficulty as "familiar routes now look unfamiliar" and denied that the difficulty was in detecting or describing landmarks. Familiar houses and streets, however, appeared unfamiliar until he recognized a major landmark.

GN's TD was improved by verbal cues and was particularly impaired in certain settings. Knowing the street names helped him get a mental picture and get oriented. In contrast, he had special problems with corridors, public bathrooms, and theaters. At one point, he could not get out of a public bathroom because he could not find the exit. He stated that "things look so similar in bathrooms; they look all white". Movie theaters, including their lobbies, all "looked the same". In the hospital and clinic, minor variations resulted in a loss of the sense of familiarity. For example, he relied on a yellow floor barrier for identification of a specific hospital corridor and became totally disoriented when it was moved.

GN underwent tests of basic visual functions. His visual acuity was 20/20 with glasses, but he remained with a left upper quadrantanopia on visual field testing. He had no difficulty naming colors of even minor differences in hue. GN performed normally on the Randot stereopsis plates, a motion parallax box, and an assessment of monocular depth cues (perspective, superimposition, relative size) (Mendez,

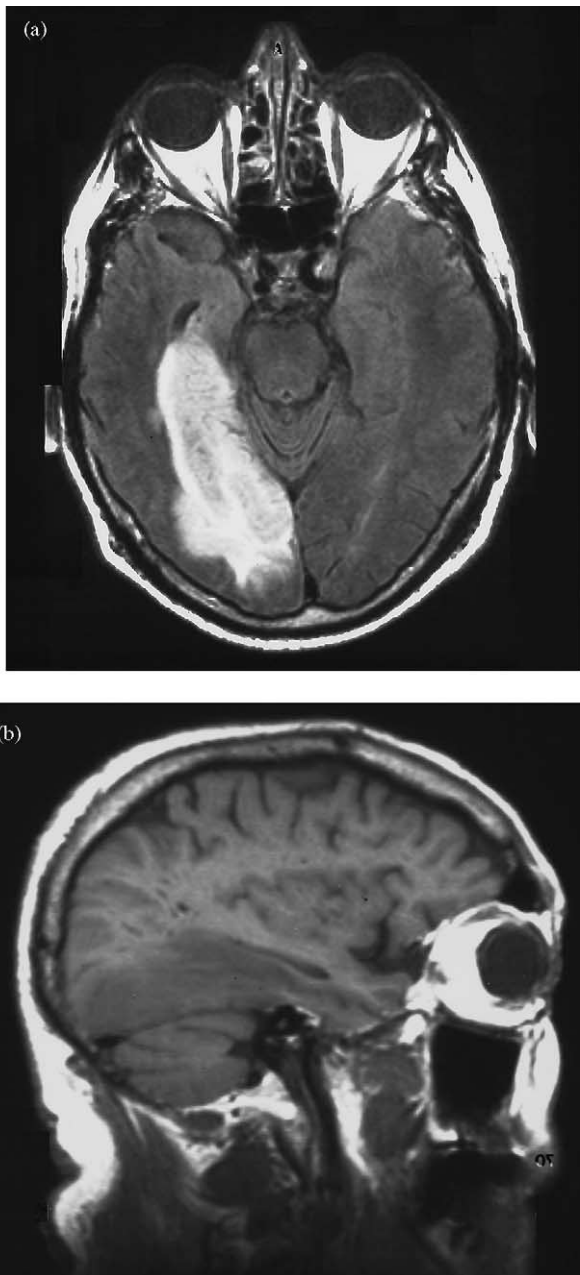


Fig. 1. Magnetic resonance images: (a) FLAIR image, horizontal cut, shows the stroke in medial occipitotemporal region prominently involving the lingual gyrus; (b) T1-weighted image, sagittal cut, shows the extent of the stroke in the right hemisphere.

Meadows, & Cherrier, 1996). Screening tests did not demonstrate object agnosia, drawing agnosia, simultanagnosia, oculomotor apraxia, or optic ataxia. GN did not have difficulty with dressing or in localizing stimuli in peripersonal space. He performed normally on a double simultaneous stimulation task and was able to draw an accurate floor plan of his house. In the clinic, he could not find his way out of the clinic area, into the correct corridor, and to the elevator.

3. Methods

In order to further characterize his visuo-perceptual and visuospatial abilities, GN underwent a series of complex visual tests followed by two specific route tests.

3.1. *The Benton Visual Form Discrimination Test (Benton, Hamsher, Varney, & Spreen, 1983)*

GN was asked to discriminate complex visual figures. Each one of 16 test items was composed of a set of three complex figures (two major and one peripheral) which must be matched with 1 of 4 items in a multiple choice paradigm. There were three types of potential errors: (1) displacement or rotation of the peripheral figure, (2) rotation of one of the major figures, and (3) distortion of one of the major figures.

3.2. *The Gollin Incomplete Figures (modified-5 series) (Gollin, 1960) and the Southern California Figure-Ground Visual Perception Test (modified-8 series) (Ayers, 1966)*

GN was asked to identify a series of incomplete Gollin drawings. The original set consisted of 20 picture sets of five line drawings of familiar objects in increasing degree of completeness. GN was administered five representative sets of Gollin figures: the cat, table, elephant, sailboat, and telephone. On the figure-ground test, he was asked to identify the three overlapping figures in each of first eight plates. Although these overlapping figures were developed for use with children, they have been a good screen for figure-ground discrimination in impaired adults.

3.3. *The Hooper Visual Organization Test (Hooper, 1983)*

In order to test complex visual integration, GN was shown 30 black and white line drawings that have been divided into component pieces and rotated or moved on the page. GN had to visually integrate the component parts and name the object.

3.4. *The Rey–Osterreith complex Figure Copy and Memory (Meyers & Meyers, 1995)*

In order to test visuospatial constructional ability and visual memory, GN was presented a complex figure to copy and was subsequently asked to repeat the test after a 30 min delay.

3.5. *Complex Picture Scanning (Mendez, Cherrier, & Cymerman, 1997)*

This test assessed the processing of details of a complex scene. This unstructured visual search task consisted of the presentation of a picture of a toy store with multiple visual

items. GN was instructed to “name as many observed objects as possible within 5 min”. Positive recognition was accepted if he named, visually described, or indicated usage of the objects.

3.6. *Mesulam Cancellation Task (visual search)* (Mesulam, 1985)

This test assessed visual search and consisted of an untimed, revised version of the Mesulam letter cancellation test. A 21.6 cm × 28 cm page with 100 different figures distributed randomly across the page was aligned along his midline. GN was instructed to circle a specific figure (a “sun” with a diagonal band) every time he saw the figure. There were 24 targets, 12 targets in each hemispace. The score was determined by the number of targets correctly canceled.

3.7. *The Benton Judgment of Line Orientation Test* (Benton et al., 1983)

This test assessed visuospatial orientation and consisted of 30 items preceded by 5 practice items. The test items were cards with a pair of partial lines, with each partial line corresponding to the orientation of one of the lines appearing in the stimulus card. GN was asked to determine which two lines on the grid below were in the same position as the stimulus lines. The lines were 3.8 cm long and arranged at different angles from center, corresponding to 18 in. differences.

3.8. *The Card Rotation Test* (Ekstrom, French, Harman, & Dermen, 1976)

This test evaluated the ability to mentally rotate and visualize geometric shapes. Each item of the test consisted of a drawing of a card cut into an irregular shape. To its right were six drawings of the same card, sometimes merely rotated and sometimes turned over to its other side. GN indicated whether or not the card had been turned over.

3.9. *Money’s Standardized Road Map Test of Direction Sense* (Money, 1976)

This test assessed sense of direction and orientation using a two-dimensional map. GN was shown an 8.5 in. × 11 in. black and white outline map of a neighborhood layout. The layout consisted of rectangular blocks evenly spaced with triangular blocks at various places. The examiner traced a practice route, and GN was asked to imagine himself walking the route traced with a felt-tip pen. He was asked to say which way he would go (right or left) at each turn. After GN responded correctly to the practice items, a longer route was drawn, and he was again asked to determine which way he would turn at each corner.

3.10. *The Benton Face Recognition Test* (Benton et al., 1983) and a *Famous Faces Recognition Task*

On the Benton test, GN was asked to match front-view photographs with six photographs presented either in front-view, three-quarters view, or in different lighting. He was also shown 24 photographs of famous people for naming or for identification. The famous people were politicians, entertainers, and other persons well known to most residents of Southern California.

3.11. *The Corsi Block-Tapping Task* (Milner, 1971)

This task involved nine 1.5 in. cubes fastened in random order on a black board. Each time the examiner tapped the blocks in a prearranged sequence, GN attempted to copy his tapping pattern. By adding one tap to each succeeding successful sequence the examiner ascertained GN’s immediate visual recall.

3.12. *Modified Visuospatial Learning Test* (Malec et al., 1992)

This test measured visuospatial learning. It was modified to substitute black buttons for specific designs. GN was shown a 5 × 7 black and white grid. On the grid were placed seven black buttons in a particular pattern. GN was allowed to examine the pattern for 10 s. The buttons were removed, and GN was asked to put the buttons back on the grid in their proper position. At this point, three additional identical buttons were included as distractor buttons for a total of 10 buttons. GN was instructed to remember the correct number of buttons as well as their placement. This process was repeated for a total of five trials. After a 30 min delay, GN was asked to recall the pattern from memory.

3.13. *Familiar Route: Home to Hospital (20 km)*

GN was tested on recall of the non-freeway route from his home in the West Los Angeles area to the hospital. This was a highly familiar route for him, but he could not longer drive it without getting lost. GN was provided with a schematic map of the area, devoid of any landmarks or words. GN was instructed to trace his route and to write the street names on the map. Twenty intersections or key roads were identified as key for his route. Subsequently, he was given pictures of landmarks and critical scenes along this route (see Figs. 2 and 3). Ten well-known landmarks and 10 critical scenes were presented each along with three distractors. These scenes were devoid of major, salient landmarks but were critical junctures required for deriving information necessary for successful navigation of the route. The distractors for landmarks and scenes consisted of one semantically-related (same street or neighborhood) item, a perceptually similar item, and a third totally unrelated item. If he recognized the



Fig. 2. Key landmark along route. Major chapel scene along route to hospital (picture was shown in color to the patient).

landmarks or scenes, he was then asked to indicate the direction he would take along the route. Missed landmarks or scenes were cued by providing the street names. Finally, two photographs of missed scenes varying in angle of photographic orientation, were presented, along with an equal number of distractors, for matching.

3.14. West LA Route Learning Test (Cherrier, Mendez, & Perryman, 2001)

This test was previously developed for testing route learning in patients with Alzheimer's disease and was slightly modified for use here. During a learning trial, the subject

and examiner walked a predetermined hospital route, and the examiner pointed out specific landmarks, often differing only in minor detail, and scenes without salient landmarks. The examiner instructed GN to remember the walking route as well as the indicated landmarks and scenes. After the learning trial, a test trial was administered in which GN was instructed to retrace the exact route and to point out the designated landmarks and scenes. The following items were measured during the test trial: walking recall of landmarks and scenes, necessity for route cues and redirection, route map recognition from one of four black and white maps, and picture recognition of landmarks and scenes. In this last section, GN was shown color photographs of landmarks and



Fig. 3. Key scene along route. One of the major entrances to the hospital; turn-off to the right (picture was shown in color to the patient).

scenes that were located on the route. GN was asked to indicate the correct choice among distractors.

4. Results

The results of the complex visual tests are summarized in Table 1. He performed quite well on perceptual tests including tests of complex figure discrimination, incomplete figure recognition and figure-ground analysis, visual integration, picture search and scanning, shape and angle visualization and rotation, and face discrimination. He did not demonstrate any spatial orientation problems, including in egocentric spatial orientation on the Mooney Map Test. The patient did manifest difficulty in spatial memory, evident on all visuospatial memory tests.

Although he readily identified most of the famous faces, his pattern of errors suggested semantic confusion. For example, John F. Kennedy was reported as Robert Kennedy, despite very distinctive profiles. Henry Kissinger was called Albert Einstein; although, he later correctly identified the picture of Einstein. Robert Mitchum, the actor, was reported as John Wayne. (He also misidentifying Sophia Loren as Jacqueline Kennedy and did not recognize former L.A.

mayor Tom Bradley.) He recognized all of the missed faces when given the correct names.

On the familiar route test, GN was able to draw maps of his neighborhood, area of Los Angeles in which he lived, and other regional maps. When given a schematic map without street names or markings, he quickly recognized it as his neighborhood and put in the streets. GN could quickly recognize pictures of the major landmarks in his neighborhood and area, and he could describe what direction to take from the landmarks. Most pictures of scenes in his neighborhood were not recognized. Street signs and names facilitated route recognition. Finally, he could visually match scenes varying in angle of photographic orientation.

On the route learning test, GN was able to adequately learn delineated landmarks along a new route. Some of these landmarks had only minor distinguishing features from each other. He also knew which direction to go in relation to the landmarks. When he arrived at a spot where there was a break in the learned landmarks, he quickly got lost and needed route cues to stay on course. He did not recognize scenes without salient landmarks either on the walking test or on subsequent picture recognition.

5. Discussion

This patient had a relatively isolated topographagnosic disorientation. He could not find his way in familiar surroundings, but he could describe and draw maps of familiar routes. When he was out on the actual routes, however, he quickly got lost. Unlike many case reports of topographagnosia, he could identify common buildings and landmarks and knew what direction to turn from them in order to find his way. The GN's problem appeared to be in deriving information from scenes and visual configurations of his environment.

There have been several different theories for TD (Barrash, 1998; Benton, Levin, & Van Allen, 1974; Pallis, 1955). Many authors supported the division into topographagnosia and topographic amnesia (Bottini, Cappa, Geminiani, & Sterzi, 1990; De Renzi et al., 1977; Hécaen et al., 1980; Landis, Cummings, Benson, & Palmer, 1986; Paterson & Zangwill, 1945; Welsh et al., 1994). Levine, Warach, and Farah (1985) suggested that these differences involved identification of salient landmarks used in route-learning, and the representation of spatial positions in mental maps, respectively (Levine et al., 1985). Grüsser and Landis (1991) further divided TD into four types. Type A was due to the formation of an incorrect percept (Grüsser & Landis, 1991) and Type B (apperceptive topographagnosia) to an inability to integrate perception in parallel across the visual field (Riddoch & Humphreys, 1987). Type C (associative topographagnosia) patients could not match a normal percept with its inner representation, and Type D (topographic amnesia) patients could not access inner representations of mental maps. More recently, Aguirre

Table 1
Visual Perception Tests

Test	GN's age	
	Adjusted score	Significance
Basic Perception Tests		
Benton Visual Form Discrimination Test	29	wnl
Gollin Figures (modified-5 series)	22	wnl
S. Calif Figure-Ground (modified-8 series)	18	wnl
Hooper Visual Organization	16	wnl
Rey-Osterreith Complex Figure Copy	32	wnl
Visuospatial Tests		
Complex Picture Scanning	19	wnl
Cancellation Task (visual search)	24	wnl
Benton Judgment of Line Orientation (form H)	25	wnl
Card Rotation Test	120	wnl
Money Road Map Test	32	wnl
Facial Processing Tests		
Benton Facial Recognition	43	wnl
Famous Faces Recognition	19	wnl
Recognition/description of person from name	24	wnl
Visual Memory Tests		
Corsi Block span 4; unable to reach 2-supraspan criterion after 20 trials		Abnormal
Rey-Osterreith Complex Figure 30 min recall	4	Low score
Modified Visuospatial Learning Test (trials 1–5)	16	Abnormal
Delayed 30 min recall	1	Abnormal

wnl: within normal limits.

and D'Esposito proposed a somewhat different set of TD subtypes (Aguirre & D'Esposito, 1999). They postulated the existence of an egocentric disorientation from problems coding body-centered spatial relations, and a heading disorientation from problems deriving a sense of direction, possibly related to difficulty coding allocentric spatial relations between objects. They also described a landmark agnosia and an anterograde topographic amnesia. Together, these classifications suggested that TD for familiar routes could result from visuospatial difficulties in integrating spatial relationships, an inability to access or retrieve adequate mental maps, or a continuum of agnosia for minor and major landmarks. Our patient was assessed for these putative mechanisms for TD.

This patient did not have evidence of visuospatial disturbances for TD. In this type of TD, the right superior parietal lobule is most often involved, but this area was spared in GN (Assal, 1969; Hécaen, Penfield, Bertrand, & Malmö, 1956; Newcombe & Ratcliff, 1990; Paterson & Zangwill, 1945). Furthermore, with damage to the egocentric coordinate system, other spatial difficulties have usually occurred, such as hemispatial neglect or Balint's syndrome. In heading disorientation, which may follow right posterior cingulate injury, salient landmarks have been devoid of orientation (location) value, but our patient knew which direction to proceed from landmarks (Brain, 1941; Whitty & Newcombe, 1973).

In addition to coding single objects in space, multiple visual objects must be integrated into a meaningful scene. The failure of integration in a spatially parallel fashion may result in reversion to a feature-by-feature identification strategy of details of landmarks (Paterson & Zangwill, 1945; Whitty & Newcombe, 1973). GN's ability to quickly describe complex scenes, learn landmarks with minor distinguishing features, and match scenes at different angles mitigates against this "apperceptive" or integrative agnosia.

Our patient's memory difficulty also does not explain his TD. Topographic amnesia could include difficulty in retrieving stored knowledge of spatial maps, in learning new maps, or in temporarily coding spatial relations in working memory (spatial sketchpad) (Hanley, Young, & Pearson, 1991). Unlike GN's performance, if there is retrieval difficulty, verbal descriptions of routes are impaired. Several investigators have proposed a deficit specific to forming new topographical memories (Assal, 1969; Barrash & Tranel, 1996; Epstein, DeYoe, Press, Rosen, & Kanwisher, 2001; Whiteley & Warrington, 1978). On the route learning test, however, GN demonstrates sufficient ability to learn new, designated landmarks. In addition, he could represent and use spatial information in working memory to access or use spatial maps and visualize a route.

This patient's lesion suggests associative topographagnosia similar to landmark agnosia. Similar to his lesion, the most frequent cause for landmark agnosia is a stroke involving the territory of the right posterior cerebral artery with infarction of the medial occipitotemporal cortex (Habib & Sirigu, 1987; Hécaen et al., 1980; Landis et al., 1986;

Whitty & Newcombe, 1973). GN's lesion includes the "lingual landmark area", a region straddling the right lingual sulcus specialized for the perception of salient environmental features such as buildings (Aguirre, Zarahn, & D'Esposito, 1998). The route tests revealed that GN's "landmark" agnosia was specifically for scenes. Visual scenes are a correlation of minor as well as major environmental features with each other (Polk & Farah, 1995), and damage to the lingual area may impair the identification of complex scenes as well as usual landmarks (Aguirre & D'Esposito, 1999; Barrash et al., 2000; Incisa della Rochetta, Cipolotti, & Warrington, 1996). There may be a continuum of damage to a single environmental representation area depending on the saliency of landmarks (Barrash, 1998).

Alternatively, these patients may be impaired in the arrangement of visual stimuli into coherent scenes. Like GN, those with landmark agnosia may become disoriented within buildings, suggesting that they are no longer able to distinguish the configurations of stimuli necessary to differentiate one place from another (Incisa della Rochetta et al., 1996). Although GN could tell the general direction to take from a recognized landmark, he quickly got lost if not actually viewing the landmark. Moreover, recent data shows that parieto-occipital junctions and parahippocampal gyri respond selectively to overall scenes, regardless of individual details (Epstein & Kanwisher, 1998; Nakamura et al., 2000). These findings suggest a specific deficit in interpreting the configuration of visual scenes that are important for navigation.

The roles of his PPA lesion and the hippocampal complex may support the concept of a deficit at the level of spatial configuration or geometry. The PPA is critical for combining the geometry and spatial cues of scenes into a unified topographical representation for encoding or consolidating into memory (Epstein et al., 2001; Ploner et al., 2000; Smith & Milner, 1981). The right PPA may be particularly necessary for spatial learning and encoding scenes that must be recognized "holistically" solely on the basis of spatial structure (Aguirre & D'Esposito, 1999; Ploner et al., 2000; Smith & Milner, 1981). The hippocampal complex plays a further role in the processing of scenes by the retention and retrieval of details about topographical and environmental features (Rosenbaum et al., 2000) (Table 2).

Further clues to the nature of his topographagnosia come from prosopagnosia (Landis et al., 1986; Maguire et al., 1996; McCarthy et al., 1996), a related category specific deficit involving the perception of familiar faces (Clarke, Lindemann, Maeder, Borruat, & Assal, 1997; De Renzi & di Pellegrino, 1998; Dixon, Bub, & Arguin, 1998; Kanwisher, McDermott, & Chun, 1997; Sams, Hietanen, Hari, Ilmoniemi, & Lounasmaa, 1997). Both cognitive disorders may correlate with disturbance of a "recognition network" in the anterior temporal cortex (Gorno-Tempini & Price, 2001; Mesulam, 1998; Tyrrell, Warrington, Frackowiak, & Rossor, 1990). Right medial temporal lobectomies may impair scene recognition, as well as face

Table 2
Topographic Orientation Tests

	GN's score	Correct (%)
Familiar route: home to hospital (12 miles)		
Schematic, unmarked map: indicate turns on route ($n = 20$)	20	100
Pictures of major landmarks (three distractors each) ($n = 10$)	10	100
Compass orientation from major route landmarks	9	90
Pictures of scenes without major landmarks (three distractors each) ($n = 10$)	1	10
Semantic errors (two correct when given street name)	5	
Perceptual errors	2	
Unrelated errors	2	
Choice of direction from identified landmarks or scenes ($n = 11$)	11	100
Misidentified scenes: match photos at different angles (nine distractors)	9	100
	GN's score	Normals
West LA Route Learning Test (Cherrier et al., 2001) ($n = 6$)		
Walking recall of 10 landmarks (spontaneous recall)	9	9.83 (0.41) ^a
Walking recall of 10 scenes (spontaneous recall)	2	9.3 (0.82)
Number of necessary route cues	Failed (>5 cues)	1.17 (1.17)
Route map recognition (real map with three distractors)	Failed to choose correct route	All six choose correct route
Landmark picture recognition among distractors	10	10
Scene picture recognition among distractors	1	9.83 (0.41)

^a Standard deviations in parentheses.

recognition (Spiers et al., 2001). In prosopagnosia, as in GN, face recognition may be worse for semantically-related people, indicating difficulty accessing similar stored representations (Clarke et al., 1997; Dixon et al., 1998; Nyffeler, Leeman, & Schneider, 2001). Moreover, his topographagnosia was worse for semantically-related scenes (theaters, bathrooms, public buildings). In contrast, prosopagnosic patients may access intact images of famous faces when presented with their names or other semantic information (De Renzi & di Pellegrino, 1998). Similarly, in GN, verbal tags, street names, and other semantic information facilitated route orientation.

In conclusion, the patient's topographagnosia corresponded with problems recognizing critical scenes rather than salient landmarks. There was a loss of sense of familiarity for familiar scenes, and he seemed to fail to recognize the interrelationships of minor elements that contribute to a specific scene. In addition, his appreciation of scene configurations improved with semantic cueing and suggested problems in semantic access. The mechanism for topographagnosia proposed in this case study can lead to further investigation and delineation of agnosia for scenes.

References

- Aguirre, G. K., & D'Esposito, M. (1999). Topographical disorientation: A synthesis and taxonomy. *Brain*, *122*, 1613–1628.
- Aguirre, G. K., Zarahn, E., & D'Esposito, M. (1998). An area within human ventral cortex sensitive to "building" stimuli: Evidence and implications. *Neuron*, *21*, 373–383.
- Assal, G. (1969). Regression des troubles de la reconnaissance des physiognomies et de la memoire topographique chez un malade opéré d' un hematome intracérébral pariéto-temporal droite. *Revue Neurologique*, *121*, 184–185.
- Ayers, A. J. (1966). *Southern California figure-ground visual perception test: Manual*. Los Angeles: Western Psychological Services.
- Barrash, J. (1998). A historical review of topographical disorientation and its neuroanatomical correlates. *Journal of Clinical and Experimental Neuropsychology*, *20*, 807–827.
- Barrash, J., Damasio, H., Adolphs, R., & Tranel, D. (2000). The neuroanatomical correlates of route learning impairment. *Neuropsychologia*, *38*, 820–836.
- Barrash, J., & Tranel, D. (1996). Neuropsychological correlates of route learning. *Journal of the International Neuropsychological Society*, *2*, 69–70.
- Benton, A. L., Hamsher, K. deS., Varney, N. R., & Spreen, O. (1983). *Contributions to neuropsychological assessment*. Oxford: Oxford University Press.
- Benton, A. L., Levin, H. S., & Van Allen, M. W. (1974). Geographical orientation in patients with unilateral cerebral disease. *Neuropsychologia*, *12*, 183–191.
- Bottini, G., Cappa, S., Geminiani, G., & Sterzi, R. (1990). Topographic disorientation: A case report. *Neuropsychologia*, *28*, 309–312.
- Brain, W. R. (1941). Visual disorientation with special reference to lesions of the right cerebral hemisphere. *Brain*, *64*, 244–272.
- Cherrier, M. M., Mendez, M. F., & Perryman, K. (2001). Route learning performance in Alzheimer's disease patients. *Neuropsychiatry, Neuropsychology and Behavioral Neurology*, *14*, 159–168.
- Clarke, S., Lindemann, A., Maeder, P., Borruat, F. X., & Assal, G. (1997). Face recognition and posteroinferior hemispheric lesions. *Neuropsychologia*, *35*, 1555–1563.
- De Renzi, E., & di Pellegrino, G. (1998). Prosopagnosia and alexia without object agnosia. *Cortex*, *34*, 403–415.
- De Renzi, E., Faglioni, P., & Villa, P. (1977). Topographical amnesia. *Journal of Neurology, Neurosurgery and Psychiatry*, *40*, 498–505.
- Dixon, M. J., Bub, D. N., & Arguin, M. (1998). Semantic and visual determinants of face recognition in a prosopagnosic patient. *Journal of Cognitive Neuroscience*, *10*, 362–376.
- Ekstrom, R. B., French, J. W., Harman, J. J., & Dermen, D. (1976). *Manual for kit of factor-referenced cognitive tests*. Princeton (NJ): Educational Testing Service.
- Epstein, R., DeYoe, E. A., Press, D. Z., Rosen, A. C., & Kanwisher, N. (2001). Neuropsychological evidence for a topographical learning

- mechanism in parahippocampal cortex. *Cognitive Neuropsychology*, 18, 481–508.
- Epstein, R., & Kanwisher, N. (1998). A cortical representation of the local visual environment. *Nature*, 392, 598–601.
- Folstein, M. F., Folstein, S. E., & McHugh, P. R. (1975). Mini-mental state: A practical method for grading the cognitive state of patients for the clinician. *Journal of Psychiatric Research*, 12, 189–198.
- Gollin, E. S. (1960). Developmental studies of visual recognition of incomplete objects. *Perceptual and Motor Skills*, 11, 289–298.
- Gorno-Tempini, M. L., & Price, C. J. (2001). Identification of famous faces and buildings: A functional neuroimaging study of semantically unique items. *Brain*, 124, 2087–2097.
- Grüsser, O.-J., & Landis, T. (1991). *Visual agnosias and other disturbances of visual perception and cognition* (pp. 411–431). London: Macmillan Press.
- Habib, A., & Sirigu, A. (1987). Pure topographical disorientation: A definition and anatomical basis. *Cortex*, 23, 73–85.
- Hanley, J. R., Young, A. W., & Pearson, N. A. (1991). Impairment of the visuo-spatial sketch pad. *Quarterly Journal of Experimental Psychology*, 43, 101–125.
- Hécaen, H., Penfield, W., Bertrand, C., & Malmö, R. (1956). The syndrome of apractognosia due to lesions of the minor cerebral hemisphere. *Archives of Neurology and Psychiatry*, 75, 400–434.
- Hécaen, H., Tzortzis, C., & Rondot, P. (1980). Loss of topographic memory with learning deficits. *Cortex*, 16, 525–542.
- Hooper, E. H. (1983). *Hooper visual organization test manual*. Los Angeles: Western Psychological Services.
- Incisa della Rochetta, A., Cipolotti, L., & Warrington, E. K. (1996). Topographical disorientation: Selective impairment of locomotor space. *Cortex*, 32, 727–735.
- Jackson, J. H. (1932). Case of large cerebral tumour with optic neuritis and with left hemiplegia and imperception. In J. H. Jackson (Ed.), *Selected writings* (pp. 146–152). London: Taylor.
- Kanwisher, N., McDermott, J., & Chun, M. M. (1997). The fusiform face area: A module in human extrastriate cortex specialized for face perception. *Journal of Neuroscience*, 17, 4302–4311.
- Landis, T., Cummings, J. L., Benson, D. F., & Palmer, E. P. (1986). Loss of topographical familiarity: An environmental agnosia. *Archives of Neurology*, 43, 132–136.
- Levine, D. N., Warach, J., & Farah, M. J. (1985). Two visual systems in mental imagery: Dissociation of the ‘what’ and ‘where’ in imagery disorders due to bilateral posterior cerebral lesions. *Neurology*, 35, 1010–1018.
- Maguire, E. A., Burgess, N., Donnett, J. G., Frackowiak, R. S., Frith, C. D., & O’Keefe, J. (1998). Knowing where and getting there: A human navigation network. *Science*, 290, 921–924.
- Maguire, E. A., Burke, T., Phillips, J., & Staunton, H. (1996). Topographical disorientation following unilateral temporal lobe lesions in humans. *Neuropsychologia*, 34, 993–1001.
- Malec, J. F., Ivnik, R. J., Smith, G. E., Tangalos, E. G., Petersen, R. C., Kokmen, E., & Kurland, L. T. (1992). Visual spatial learning test: Normative data and further validation. *Psychological Assessment*, 4, 433–441.
- McCarthy, R. A., Evans, J. J., & Hodges, J. R. (1996). Topographical amnesia: Spatial memory disorder, perceptual dysfunction, or category specific semantic memory impairment? *Journal of Neurology, Neurosurgery and Psychiatry*, 60, 318–325.
- Mendez, M. F., Cherrier, M. M., & Cymerman, J. (1997). Hemispatial neglect on visual search tasks in Alzheimer’s disease. *Neuropsychiatry, Neuropsychology and Behavioral Neurology*, 10, 203–208.
- Mendez, M. F., Meadows, S., & Cherrier, M. M. (1996). Depth perception in Alzheimer’s disease. *Perception and Motor Skills*, 83, 987–995.
- Mesulam, M.-M. (1985). *Principles of behavioral neurology*. Philadelphia: FA Davis.
- Mesulam, M.-M. (1998). From sensation to cognition. *Brain*, 121, 1013–1052.
- Meyers, J., & Meyers, K. (1995). *The Meyers scoring system of the Rey complex figure and the recognition trial: Professional manual*. Odessa (FL): Psychological Assessment Resources.
- Milner, B. (1971). Interhemispheric differences in the localization of psychological processes in man. *British Medical Bulletin*, 27, 272–277.
- Money, J. A. (1976). *Standardized road map test of direction sense: Manual*. San Rafael (CA): Academic Therapy Publications.
- Nakamura, K., Kawashima, R., Sato, N., Nakamura, A., Sugiura, M., Kato, T., Hatano, K., Ito, K., Fukuda, H., Schormann, T., & Zilles, K. (2000). Functional delineation of the human occipito-temporal areas related to face and scene processing. A PET study. *Brain*, 123, 1903–1912.
- Newcombe, F., & Ratcliff, G. (1990). Disorders of visuospatial analysis. In F. Boller, J. Grafman (Eds.), *Handbook of neuropsychology* (Vol. 2, pp. 333–356). Amsterdam: Elsevier.
- Nyffeler, T., Leeman, B., & Schneider, A. (2001). The professor or the resident? A misidentification of two faces. *Neurology*, 57, 556–557.
- Pallis, C. A. (1955). Impaired identification of locus and places with agnosia for colours. *Journal of Neurology, Neurosurgery and Psychiatry*, 18, 218–224.
- Paterson, A., & Zangwill, O. L. (1945). A case of topographical disorientation associated with a unilateral cerebral lesion. *Brain*, 68, 188–212.
- Ploner, C. J., Gaymard, B. M., Rivaud-Péchéux, S., Baulac, M., Clémenceau, S., Samson, S., & Pierrot-Deseilligny, C. (2000). Lesions affecting the parahippocampal cortex yield spatial memory deficits in humans. *Cerebral Cortex*, 10, 1211–1216.
- Polk, T. A., & Farah, M. J. (1995). Brain localization for arbitrary stimulus categories a simple account based on Hebbian learning. *Proceedings of the National Academy of Sciences of United States of America*, 92, 12370–12373.
- Riddoch, M. J., & Humphreys, G. W. (1987). A case of integrative visual agnosia. *Brain*, 110, 1431–1462.
- Rosenbaum, R. S., Priselac, S., Kohler, S., Black, S. E., Gao, F., & Nadel, L. et al., (2000). Remote spatial memory in an amnesic person with extensive bilateral hippocampal lesions. *Nature Neuroscience*, 3, 1044–1048.
- Sams, M., Hietanen, J. K., Hari, R., Ilmoniemi, R. J., & Lounasmaa, O. V. (1997). Face-specific responses from the human inferior occipito-temporal cortex. *Neuroscience*, 77, 49–55.
- Smith, M. L., & Milner, B. (1981). The role of the right hippocampus in the recall of spatial location. *Neuropsychologia*, 19, 781–793.
- Spiers, H., Burgess, N., Maguire, E., Baxendale, S. A., Hartley, T., Thompson, P. J., & O’Keefe, J. (2001). Unilateral temporal lobectomy patients show lateralized topographical and episodic memory deficits in virtual town. *Brain*, 124, 2476–2489.
- Tyrell, P. J., Warrington, E. K., Frackowiak, R. S., & Rossor, M. N. (1990). Progressive degeneration of the right temporal lobe studied with positron emission tomography. *Journal of Neurology Neurosurgery and Psychiatry*, 53, 1046–1050.
- Welsh, K. A., Butters, N., Beekly, D., Edland, S., Fillenbaum, G., & Heyman, A. (1994). The Consortium to Establish a Registry in Alzheimer’s Disease (CERAD). Part V. A normative study of the neuropsychological battery. *Neurology*, 44, 609–614.
- Whiteley, A. M., & Warrington, E. K. (1978). Selective impairment of topographical memory: A single case study. *Journal of Neurology, Neurosurgery and Psychiatry*, 41, 575–578.
- Whitty, C. W. M., & Newcombe, F. (1973). Oldfield’s study of visual and topographical disturbances in a right occipito-parietal lesion after 30 years duration. *Neuropsychologia*, 11, 471–475.