

## Neurocysticercosis Masquerading as a Cerebral Infarct

### ABSTRACT

The differential diagnosis of acute focal neurologic deficit in childhood is diverse. We report the case of a child presenting with an acute hemiparesis persisting for longer than 24 hours following a focal seizure. The clinical history, examination findings, and results of cranial magnetic resonance imaging (MRI) were initially interpreted as consistent with an arterial ischemic cerebral infarction. Follow-up cranial MRI performed 9 months later revealed changes indicative of neurocysticercosis. Review of original neuroimaging resulted in a revision of the diagnosis to neurocysticercosis. The clinical history, together with neuroimaging findings, is highly compatible with a diagnosis of neurocysticercosis but unusual because it occurred in a child resident in a nonendemic area who had never traveled to an endemic area and whose diet excluded pork. The case reported raises two important issues. The first is the need to carefully consider the differential diagnosis of acute hemiparesis, including unusual causes. Second, it raises awareness of the potential for neurocysticercosis to occur in low-risk patients in nonendemic areas. (*J Child Neurol* 2003;18:298–300).

Neurocysticercosis is increasingly seen in nonendemic areas as a result of increasing numbers of immigrants from endemic areas.<sup>1,2</sup> We report the case of a child in whom a diagnosis of neurocysticercosis was made despite his residence in a nonendemic country, lack of travel to an endemic area, and dietary exclusion of pork-containing foods. At presentation, with focal neurologic deficit, the patient was thought to have suffered an ischemic infarct. This case report is important because it highlights the need for careful consideration of the differential diagnosis of focal neurologic deficit in childhood and the need to consider unusual diagnoses such as neurocysticercosis, even in low-risk groups.

### Case Report

A 3-year-old British-born boy of Muslim Asian parents presented with an acute dense right hemiplegia following a right-sided focal seizure. The hemiplegia persisted beyond 24 hours. There had been no prodromal illness. Full blood count, clotting studies, and routine biochemistry were normal. Sickie screen was negative. Cranial computed tomography showed a low-density lesion in the left centrum semiovale that was reported to be consistent with a left middle cerebral artery territory infarct. He was commenced on low-dose aspirin and transferred to a tertiary pediatric neurology center 6 days after his initial presentation. At that time, the hemiparesis had substantially recovered, and neurologic examination confirmed only asymmetric tendon reflexes, which were brisker on the right, and a tendency for his right arm to draw up when running. General examination, including fundoscopy, was otherwise normal. Cranial magnetic resonance imaging (MRI) revealed a left posterior frontal lobe focal white-matter signal change with cortical sparing thought to be consistent with arterial ischemic infarct (Figures 1 and 2). The only potential risk factors for arterial ischemic stroke that were identified following a comprehensive stroke screen (which included echocardiography) were homozygosity for the C to T substitution in the *MTHFR* gene (but with normal plasma homocysteine levels) and a possible irregularity of the right middle cerebral artery demonstrated on magnetic resonance angiography. Because of the latter finding, low-dose aspirin was continued, and cranial imaging was repeated after an interval of 9 months. Magnetic resonance angiography of the circle of Willis was normal, but MRI demonstrated a dis-

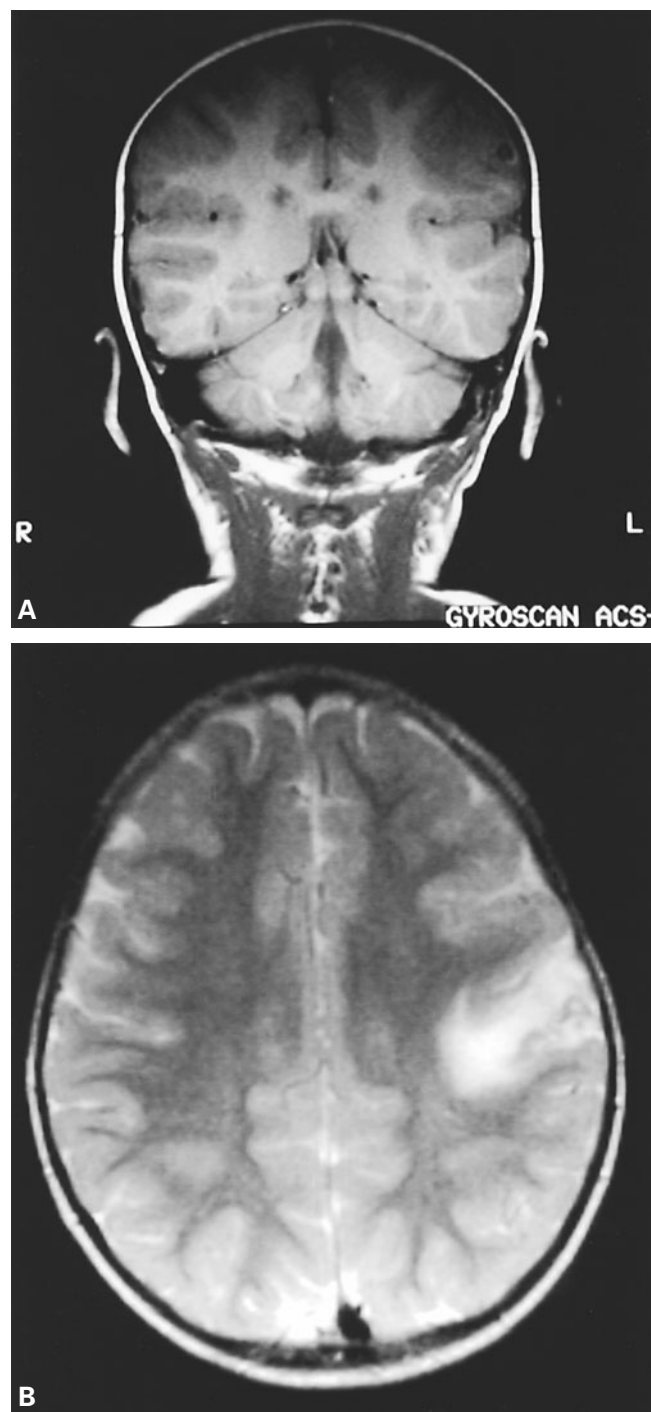


Figure 1. A, Coronal  $T_1$ -weighted magnetic resonance image (MRI), and B, axial  $T_2$ -weighted MRI at presentation. Left posterior frontal lobe focal white-matter edema with cortical sparing. There is a small, well-defined, rounded lesion of very low signal intensity at the gray–white-matter junction that represents the cysticercus.

crete, rounded lesion, hypointense on  $T_2$ -weighted images, at the gray–white-matter junction in the left frontoparietal region (Figure 3). At this stage, the diagnosis was re-evaluated, and the original cranial MRI was reviewed. In addition to left posterior frontal lobe focal white-matter edema with cortical sparing, which had previously been interpreted as indicative of ischemic infarction, a small, well-defined, rounded lesion of very low intensity on the  $T_1$ -weighted and fluid-attenuated inversion recovery scans was noted at the gray–white-matter junction. This had a bright center on all sequences (see Figures 1 and 2). The findings of both the original and repeat cranial MRI were consistent with a diagnosis of neurocysticercosis. There had been no

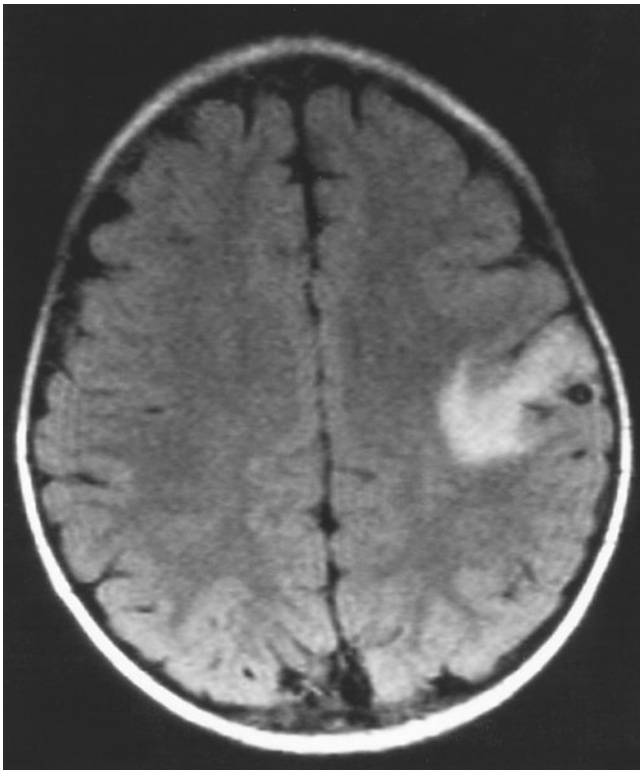


Figure 2. Axial fluid-attenuated inversion recovery images at presentation showing a radiologic pattern typical of vasogenic inflammatory edema. The distribution does not conform to a vascular territory. The low signal intensity lesion with a bright center can be seen again at the gray-white-matter junction.

travel to areas of endemicity, and the family had always excluded pork from their diet. Clinical review of the patient revealed that he was well, with no residual neurologic deficit and no further seizures. Aspirin was discontinued, and the patient and his family were treated with a single dose of vermicide to ensure bowel clearance.

### Discussion

Neurocysticercosis is the most common parasitic infection of the central nervous system. It is caused by *Taenia solium*, the pig tapeworm. When humans accidentally ingest the eggs of *T solium* in fecally contaminated water or food the eggs hatch, larvae enter the circulation and finally encyst (as cysticerci) in muscle and within the central nervous system; hence, neurocysticercosis may ensue.<sup>3</sup> By contrast, ingestion of undercooked pork containing cysticerci results in intestinal colonization by the tapeworm rather than neurocysticercosis, which occurs only if there is subsequent autoinfection by ingestion of food contaminated by the patient's own feces.<sup>3</sup> It has a mean incubation period of 4.8 years and is therefore infrequent in young children.<sup>1,2</sup> The most common presentation in children is with focal seizures in association with single parenchymal lesions. Other presentations include generalized seizures, focal neurologic deficit, and symptoms of raised intracranial pressure.<sup>2</sup> Diagnostic criteria for neurocysticercosis have been proposed and are divided into epidemiologic (individuals from endemic areas), minor (intracranial calcification, clinical features of neurocysticercosis, disappearance of cystic intracranial lesions after anticysticercal therapy), major (lesion suggestive of neurocysticercosis on cranial imaging and positive serology), and absolute

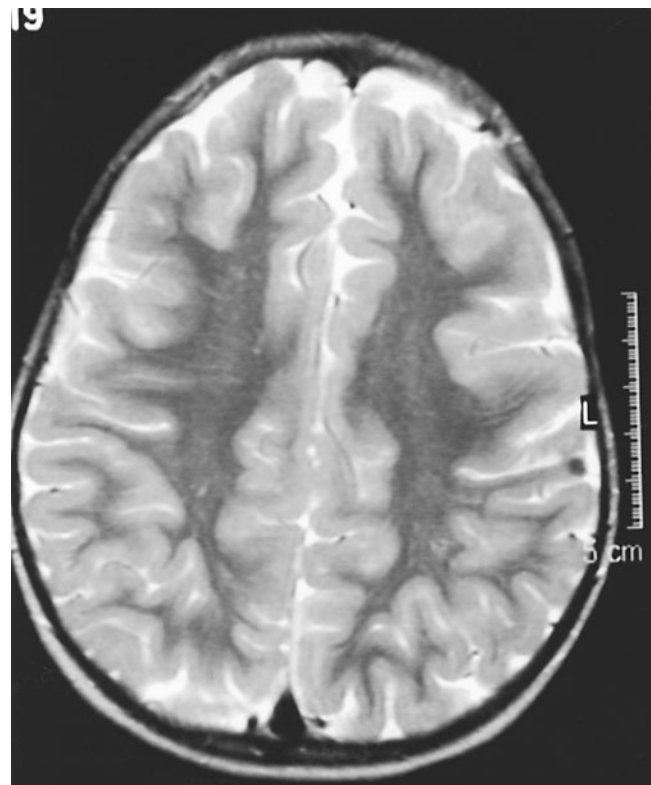

Figure 3. Axial T<sub>2</sub>-weighted image 9 months after presentation. The white-matter edema has resolved, but the discrete, hypointense, rounded lesion is still visible.

criteria (histologic demonstration of parasite from brain lesion or scolex on cranial imaging). Using this system, the clinical, laboratory, and radiologic findings of each case allow a definite, probable, or possible diagnosis to be made according to the number of major or minor features present. The presence of one absolute criterion allows a definite diagnosis to be made.<sup>3</sup> A definite diagnosis of neurocysticercosis can therefore be made on the sole basis of neuro-radiologic findings in some instances. Other investigations or clinical findings that may support a diagnosis of neurocysticercosis are fundoscopy, serology, stool examination for the ova of *T solium*, and soft-tissue radiography to look for intramuscular calcification. The yield from these has been shown to be very low, particularly in patients with single parenchymal lesions.<sup>2</sup>

The patient described had a clinical history compatible with a diagnosis of neurocysticercosis. He presented with a hemiparesis following a focal seizure; the neurologic deficit persisted for longer than would be anticipated with Todd's paresis. Focal seizures are the most common mode of presentation of neurocysticercosis in childhood.<sup>1,2</sup> Focal neurologic deficits, including hemiparesis, are also a recognized presenting feature of neurocysticercosis and can be difficult to distinguish from cerebrovascular disease.<sup>2</sup> Neurocysticercosis has also been reported to cause vasculitis resulting in cerebral infarction.<sup>4</sup> Unusual features in the history were lack of travel to an endemic area and dietary exclusion of pork. Stool examination for the presence of *T solium* was unfortunately not performed. It would have been of interest, particularly given the lack of identifiable risk factors for neurocysticercosis.

The radiologic findings were typical of neurocysticercosis, confirming a single parenchymal lesion with a bright center on all

sequences (see Figures 1 and 2). Parenchymal involvement can be divided into five radiologic stages.<sup>5</sup> The findings on the cranial MRI at presentation are compatible with stage 3 (see Figures 1 and 2). During this stage, the parasite dies, causing an inflammatory reaction with white-matter edema, and it is during this stage that patients usually become symptomatic. The second cranial MRI 9 months later reveals abnormalities consistent with stage 4 (see Figure 3). At this stage, lesions become hypointense on T<sub>2</sub>-weighted images, and the edema subsides. The final stage is that of calcification, which typically takes several years to develop.<sup>1,5</sup> When cranial imaging reveals a scolex, visible as a bright eccentric nodule within the parenchymal lesion, this is said to be diagnostic of neurocysticercosis.<sup>2,3</sup> The possibility of the radiologic findings being attributable to a cavernous hemangioma, which can have similar signal characteristics, was considered. However, there was no evidence of acute hemorrhage or mass effect to account for the acute presentation, thus making this an unlikely diagnosis.

A diagnosis of neurocysticercosis is the most likely explanation for the patient's presentation despite the lack of epidemiologic evidence. Treatment, other than a single dose of vermicide to eradicate bowel carriage, is not indicated in patients with single lesions.<sup>2</sup>

### Conclusions

When children present with focal neurologic deficit, a wide differential diagnosis should be considered, including hemorrhage, infarction, structural lesion, or infection. Neurocysticercosis can be spread by the fecal-oral route, allowing potential spread to low-risk groups in nonendemic areas, and should therefore be considered as a diagnostic possibility even in patients who have not traveled to endemic areas.

Elizabeth Wraige, MRCPCH  
 Department of Paediatric Neurology  
 John Graham, FRCP  
 Department of Radiology  
 Stephanie A. Robb, FRCPCH  
 Department of Paediatric Neurology  
 Wajanat Jan, FRCP  
 Department of Radiology  
 Guy's and St. Thomas' Trust  
 London, England

Received Sept 25, 2002. Received revised Dec 17, 2002. Accepted for publication Dec 19, 2002.

Address correspondence to Dr E. Wraige, Department of Paediatric Neurology, Newcomen Centre, Guy's Hospital, St. Thomas' Street, London SE1 9RT, England.

### References

- Morales NMO, Agapejev S, Morales RR, et al: Clinical aspects of neurocysticercosis in children. *Pediatr Neurol* 2000;22:287-291.
- Singi P, Ray M, Singhi S, Khandelwal N: Clinical spectrum of 500 children with neurocysticercosis and response to albendazole therapy. *J Child Neurol* 2000;15:207-213.
- Del Brutto OH, Wadia NH, Dumas M, et al: Proposal of diagnostic criteria for human cysticercosis and neurocysticercosis. *J Neurol Sci* 1996;142:1-6.
- Barkovich AJ: *Pediatric Neuroimaging*, 3rd ed. Philadelphia: Lippincott Williams & Wilkins, 2000.
- Litt AW, Mohuchy T: Case 10: neurocysticercosis. *Radiology* 1999;211:472-475.

## Mitochondrial Myopathy and Respiratory Failure Associated With a New Mutation in the Mitochondrial Transfer Ribonucleic Acid Glutamic Acid Gene

### ABSTRACT

We report a novel T14687C mutation in the mitochondrial transfer ribonucleic acid glutamic acid gene in a 16-year-old boy with myopathy and lactic acidosis, retinopathy, and progressive respiratory failure leading to death. A muscle biopsy showed cytochrome *c* oxidase-negative ragged-red fibers, and biochemical analysis of the respiratory chain enzymes in muscle homogenate revealed complex I and complex IV deficiencies. The mutation, which affects the trinucleotide (TΨC) loop, was nearly homoplasmic in the muscle DNA of the proband, but it was absent in his blood and in the blood from the asymptomatic mother, suggesting that it may have been a spontaneous somatic mutation in muscle. (*J Child Neurol* 2003;18:300-303).

Mutations in the mitochondrial transfer ribonucleic acid (RNA) genes are usually associated with multisystem disorders, lactic acidosis, and mitochondrial proliferation in muscle resulting in ragged-red fibers.<sup>1,2</sup> However, in rare cases, there is a tissue-specific distribution, at least clinically. As an example, mutations in the tRNA<sup>Leu</sup> gene have been predominantly associated with hypertrophic cardiomyopathy,<sup>3</sup> and mutations in the tRNA<sup>Ser(UCN)</sup> manifest almost constantly as nonsyndromic hearing loss.<sup>4</sup> Conversely, isolated skeletal myopathy has been associated with pathogenic changes in different transfer RNAs,<sup>5</sup> although only rarely the mutation was restricted to skeletal muscle.<sup>6</sup> In a few cases, preferential involvement of respiratory muscles leading to respiratory failure has been reported.<sup>7-11</sup>

We report a patient with exercise intolerance and severe respiratory involvement in whom we identified a novel sporadic mutation in the mitochondrial tRNA<sup>Glu</sup> gene, selectively affecting muscle.

### Case Report

#### Patient

A 16-year-old boy was referred to the Gaslini Institute for further investigation because of myopathy and respiratory failure. He was born at term to unrelated, healthy parents. Family history was negative for neuromuscular disorders. The neonatal period and the early psychomotor development were unremarkable. He presented at age 10 years with exercise intolerance and weakness, fatigue, tachycardia, and shortness of breath. In the following years, these symptoms had progressed to the point that he could not perform the normal daily activities. He never complained of cramps, myalgia, or pigmenturia. Physical examination revealed severe general conditions, with tachypnea, tachycardia, wheezing, retractions, and generalized muscle hypotrophy and weakness. However, there were no signs of cardiac failure. Pulmonary function tests revealed a forced vital capacity of 0.4 L (12% of predicted value) and a forced expiratory volume in 1 second of 0.55 L (14% of predicted value), indicating a severe restrictive ventilatory impairment, while the transcutaneous arterial oxygen saturation in room air was 90%. Fundus oculi revealed a pigmentary retinopathy. Laboratory investigations showed normal levels of glucose, urea, creatinine, total protein, liver enzymes, rheumatologic enzymes, and thyroid function. Resting lactic acid levels were increased (30.69 mg/dL; normal = 8-22 mg/dL). Determi-