

Case Report

A JUVENILE CASE OF CEREBELLAR ARTERIOVENOUS MALFORMATION (AVM) WITH GRADUAL ONSET OF HEADACHE AND ATAXIA

KIYOKO SUGITA, SADA O SUGA* and YOKO TANAKA

*Department of Pediatrics, Ichikawa General Hospital, Tokyo Dental College,
5-11-13 Sugano, Ichikawa 272-8513, Japan*

** Department of Neurosurgery, Ichikawa General Hospital, Tokyo Dental College,
5-11-13 Sugano, Ichikawa 272-8513, Japan*

Received 18 October, 2002/Accepted for Publication 6 December, 2002

Abstract

An 11-year-old male was admitted because of frequent vomiting and truncal ataxia which had lasted for over one week. He had clear consciousness but slowly-progressive mild headache and ataxic gait. Cranial CT revealed a 4 cm hematoma in the right cerebellar hemisphere. Angiography showed a 2×2 cm nidus of a pial arteriovenous malformation (AVM) in the right hemisphere fed from the right posterior inferior cerebellar artery and draining into the inferior hemispheric vein. We performed a surgical resection of the AVM after decompression therapy to counteract the brain edema. He recovered completely without any neurological deficits. This case suggests that cerebellar hemorrhage caused by AVM should be considered as a possible diagnosis when mild symptoms of headache and ataxia proceed gradually.

Key words: Arteriovenous malformation—Ataxia—Headache

CASE REPORT

An 11-year-old male was admitted because of nausea and truncal ataxia which had lasted for over one week. His initial symptoms were vomiting and faintness. He was clearly conscious but complained of slowly progressive mild headache and gait difficulty. Due to the mild clinical symptoms, he was treated with antiemetics by a general pediatrician for 5 days. He was referred to our hospital because there were no improvements in the symptoms

and he had begun to reel consistently to the right side. Dysphonia and right-limb neocerebellar signs were found on physical examination, but he was alert and well oriented. His muscle testing was within the normal range. Cranial CT and MR images revealed hemorrhage in the right cerebellar hemisphere (Figs. 1A and B). We made a diagnosis of arteriovenous malformation (AVM), which was confirmed by angiography (Fig. 2). We performed a surgical resection of the AVM after decompression therapy to counteract

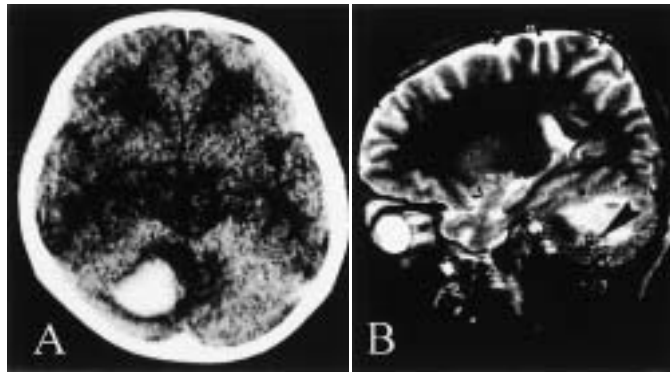


Fig. 1 Cranial CT (A: axial image) and MR image (B: sagittal image SE4000/100) revealed a 4×3 cm hemorrhage in the right cerebellar hemisphere. Flow void represented the nidus (▶).

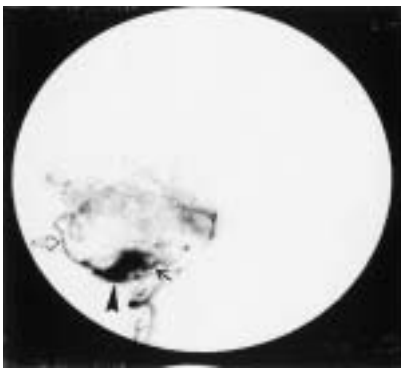


Fig. 2 Preoperative vertebral angiography in the early arterial phase showed an AVM (▶) and a feeding artery of posterior inferior cerebellar artery (→) in the right site of the cerebellum. An enlarged early-filling vein was draining vein which may be the inferior hemispheric vein (⇔).

the brain edema. He recovered without any neurological deficits such as ataxic gait or dysmetria.

DISCUSSION

Clinically manifest arteriovenous malformations in children are rare, and few pediatric series have been reported, especially in the cerebellum^{6,8)}. In children, the most common initial symptom of AVM is hemorrhagic stroke with high mortality and morbidity rates^{4,5)}. This was in contrast to the mortality rate for supratentorial AVM, the outcome of which has

improved significantly since the mid-1970s, presumably because of better diagnosis after the introduction of CT and improved neurosurgical and anesthetic techniques. Chaddock *et al.*³⁾ reported 16 children with cerebellar hemorrhage (five with an AVM) with a mortality rate of 3/16. Surgical evacuation has been recommended for treatment of acute cerebellar hemorrhage in adults. A more benign form of acute cerebellar hemorrhage had been identified, and nonsurgical treatment has been recommended for it previously⁷⁾. Brillman, however, described a patient who died from hydrocephalus one month after the nonsurgical treatment of a cerebellar hemorrhage²⁾. Thus, the exact indications for surgical treatment of acute cerebellar hemorrhage remain undefined.

The clinical presentation in this case conformed in part to the usual symptoms and signs described for acute cerebellar hemorrhage in adults; they include headache and vomiting, but he had no consciousness disturbance, cranial nerve abnormalities, or hemiparesis¹⁾. From the retrospective view, a CT scan should have been performed several days earlier in this case. The AVM was easily identifiable angiographically, as well as at operation, with obvious hemorrhage but relatively little mass effect. Fortunately, this case reported with gradual onset, underwent radical surgical resection, and recovered completely without any sequelae.

There are some previous papers suggesting that the prognosis for children with mild symptoms is good. Griffiths *et al.*⁵⁾ reported that the severity of the initial presentation was closely related with the size of the hematoma in the cerebellum, in that a hematoma >3 cm in diameter caused a severe presentation with a 65% mortality rate but that one <2 cm in diameter was associated with a mild presentation and a good outcome. In this case, the prognosis is excellent although a 4×4×3 cm hematoma existed in the posterior cranial fossa. The confined nature of hematoma appears to be important in the pathogenesis of the direct distortion of the adjacent brain stem in the relatively small volume of the child's posterior cranial fossa. The compression effect might have been slight enough to induce the progression of the clinical manifestations in this case even with a relatively large cerebellar hemorrhage.

The development of surgical resection of AVM has nowadays considerably modified the therapeutic management of AVM in both adults and children. A physician, therefore, should keep in mind the diagnosis of cerebellar hemorrhage, even though the presenting symptoms may be non-specific and mild and though the incidence of cerebellar AVM is very low in children.

REFERENCES

- 1) Brennan, R.W. and Bergland, R.M. (1977). Acute cerebellar hemorrhage: Analysis of clinical findings and outcome in 12 cases. *Neurology* **27**, 527–532.
- 2) Brillman, J. (1979). Acute hydrocephalus and death one month after nonsurgical treatment for acute cerebellar hemorrhage; Case report. *J Neurosurg* **50**, 374–376.
- 3) Chaddock, W.M., Duong, D.H., Kast, J.M. and Donahue, D.J. (1995). Pediatric cerebellar hemorrhages. *Childs Nerv Syst* **11**, 579–583.
- 4) Fults, D., Kelly, D.L. Jr. (1984). Natural history of arteriovenous malformations of the brain; A clinical study. *Neurosurgery* **15**, 658–662.
- 5) Griffiths, P.D., Blase, S., Armstrong, D., Chuang, S., Humphreys, R.P. and Harwood-Nash, D. (1998). Cerebellar arteriovenous malformations in children. *Neuroradiology* **40**, 324–331.
- 6) Harwood-Nash, D.C. and Fitz, C.R. (1976). *Neuroradiology in Infancy and Childhood*, vol. 3, pp. 902–964, Mosby, St. Louis.
- 7) Heiman, T.D. and Satya-Murti, S. (1978). Benign cerebellar hemorrhage. *Ann Neurol* **3**, 366–368.
- 8) Raimond, A.J. (1972). *Pediatric Neuroradiology*. pp. 642–654, Saunders, Philadelphia.

Reprint requests to:

Dr. Kiyoko Sugita
Department of Pediatrics,
Ichikawa General Hospital,
Tokyo Dental College,
5-11-13 Sugano, Ichikawa 272-8513,
Japan