

Acute Leukoencephalopathy after Inhalation of a Single Dose of Heroin

S. Vella¹
R. Kreis²
K. O. Lovblad³
M. Steinlin¹

Abstract

We describe extended and repeat magnetic resonance (MR) examinations in the case of a 16-year-old male who developed acute left-sided sensorimotor hemiplegia after a single dose of inhaled heroin. MRI revealed symmetrical hyperintense signals in T₂-weighted images and massive diffusion disorders in the diffusion weighted images predominantly in parieto-occipital subcortical white matter and both ventral globi pallidi with preservation of U fibers and no brain oedema. MR spectroscopy data were compatible with combined hypoxic and mitochondrial damage resulting in axonal injury without demyelination. Normal values and variations had been obtained from spectra of five age-matched subjects. This is the first reported MR follow-up study of leukoencephalopathy occurring acutely after a first inhaled dose of heroin. We postulate that toxic spongiform leukoencephalopathy in heroin addicts may be the outcome of a complex mechanism directly triggered by heroin and causing mitochondrial as well as hypoxic injury in specific and limited areas of white matter.

Key words

Leukoencephalopathy · inhaled heroin · MRI · magnetic resonance spectroscopy

Abbreviations

| | |
|-------------------|--------------------------|
| Ch _{tot} | choline compounds |
| Cr _{tot} | creatines |
| GABA | gamma-amino-butyric acid |

| | |
|--------------------|----------------------------------|
| Gln | glutamine |
| Glu | glutamate |
| Gly | glycine |
| Glx | Glu + Gln |
| Lac | lactate |
| ml | myo-inositol |
| ml _{tot} | ml + Gly |
| MM | macromolecular baseline spectrum |
| MR | magnetic resonance |
| NAA | N-acetylaspartate |
| NAAG | NAA-glutamate |
| NAA _{tot} | NAA + NAAG |
| ROI | regions of interest |
| WM | white matter |

Introduction

Heroin placed on an aluminum foil and heated with a flame produces a vapor that can be inhaled through a straw or tube. This technique (pyrolysis) separates a mixture of substances into its components by heating. It has been widely used in East Asia and is known as "Chinese blowing" or "chasing the dragon". Heroin vapor inhalation is becoming increasingly popular as it avoids risks associated with parenteral administration of the drug, including HIV and hepatitis infection. Several reports on a progressive spongiform leukoencephalopathy after long-term consumption of inhaled heroin have been published [5,8,12,13,15]. Initial symptoms were apathy, cerebellar dysarthria and ataxia, followed by spastic hemiparesis or quadriparesis, tremor, chorea, myoclonus, pseudobulbar palsy and blindness. Clinical signs occurred sometimes weeks after cessation of heroin inha-

Affiliation

¹ Division of Child Neurology, Inselspital, Bern, Switzerland

² Department of Clinical Research, University of Bern (Unit for MR Spectroscopy), Bern, Switzerland

³ Department of Neuroradiology, Inselspital, Bern, Switzerland

Correspondence

Silvano Vella M.D. · Centre for Pediatric Neurology and Sleep Disorders · Lindenhofspital · Bremgartenstraße 117, Postfach · 3001 Bern · Switzerland · E-mail: silvano.vella@gmx.net

Received: October 7, 2002 · Accepted after Revision: February 19, 2003

Bibliography

Neuropediatrics 2003; 34: 100–104 © Georg Thieme Verlag Stuttgart · New York · ISSN 0174-304X

lation. The mortality rate among those cases was 25%. MRI scans, performed in the survivors years later, showed diffuse, symmetrical white matter (WM) hyperintensities in the cerebellum, posterior cerebrum, internal capsule, and splenium of the corpus callosum [5,8,12]. We describe extended magnetic resonance (MR) examinations in the case of a 16-year-old male who developed clinical signs of leukoencephalopathy after a single dose of inhaled heroin. The MR investigations included quantitative short-echo-time MR spectroscopy and imaging at the onset of symptoms and 6 months later.

Case Report

Clinical history

The subject was found at home, about 36 hours after heroin intake. He was somnolent, but responded to questions (Glasgow Coma Scale of 13). Both legs and his buttocks were covered with decubitus ulcers, which caused him pain. Neurological examination revealed a gaze paresis on the left side and a left-sided sensorimotor hemiplegia with positive Babinski sign. A first brain CT scan showed hypodense alterations in the globus pallidus bilaterally. Metabolic urine screening was normal. Four days after admission the subject was alert and completely orientated. At discharge, one month later, his hemiplegia had completely recovered. Neuropsychological test batteries were normal, except for slow responses in arithmetical tasks, but this had been known before from school reports. The first MRI and MRS examinations were performed 5, respectively 8 days, after drug intake. A follow-up examination took place 6 months later.

Methods

Cranial MR images were obtained on a 1.5-T whole body unit with a quadrature head coil (Siemens Magnetom Vision, Erlangen, Germany). After a three-plane localiser, axial T₁-weighted images (T1WI: TR 528 ms, TE 12 ms; 24 slices with 5 mm thickness), axial T₂-weighted images (T2WI: TR 3176 ms, TE 98 ms; 24 slices with 5 mm thickness) and axial diffusion-weighted sequences (DWI: TR 4000 ms, TE 136 ms; 18 slices with 5 mm thickness, b factor 1000 s mm⁻²) and FLAIR sequences (TR 9000 ms, TE 119 ms, TI 2200 ms; 16 slices with 5 mm thickness) were acquired.

Localised ¹H-MR spectra were recorded on a 1.5 T MR scanner (Signa, General Electric, Milwaukee) using an optimised PRESS sequence (20 ms echo time [TE], 3.0 s repetition time, 1953 Hz spectral width, outer volume suppression, a 16-step phase cycle, and water presaturation) and the standard quadrature head coil [4]. Data fitting was performed with the LC-Model [10] based on a library of 22 model compounds including, choline compounds (Ch_{tot}), creatines (Cr_{tot}), GABA, glutamine (Gln), glutamate (Glu), glycine (Gly), lactate (Lac), myo-inositol (ml), N-acetylaspartate (NAA), NAA-glutamate (NAAG) and a macromolecular (MM) baseline spectrum [4]. (Calculated sums: NAA_{tot} [NAA + NAAG], ml_{tot} [ml + Gly], Glx [Glu + Gln]). Data processing included eddy current correction and scaling according to the size of brain tissue water from a biexponential fit of the TE decay of water. Quantitation was based on an assumed content of MR visible water and relaxation correction factors from [6]. Normal values and variations had been obtained from spectra of five age-matched

subjects (16 ± 1 years old). Concentrations that deviated more than two SD from the norm were considered abnormal.

Spectra were acquired from three regions of interest (ROI): 1) the left centrum semiovale (volume of 10 cm³, only partly in hyperintense WM), 2) right supraventricular WM (2.4 cm³, mostly in affected WM) and 3) occipital cortex (normal appearance on MRI, volume of 8 cm³).

Results

MRI

The acute findings were symmetrical, hyperintense signals in T2WI (Fig. 1a) and a massive diffusion disorder in the DWI (Fig. 1b) located predominantly in the parieto-occipital deep WM, but with preservation of U fibres and no brain oedema. In both ventral globi pallidi, there were hyperintense T₂ signals. The follow-up MRI demonstrated a decreased size of both the hyperintense signals in the deep WM and the globi pallidi in T2WI (Fig. 1c). The FLAIR images showed reduced, but persistent hyperintensities in deep WM (Fig. 1d). There were no signs of brain atrophy.

MRS

On day 8, the MR spectra of all 3 ROIs revealed metabolic features that deviated significantly from the norm (Table 1). In particular, all of them showed a decrease in NAA_{tot}. In both WM regions this was accompanied by a strong increase in Lac, a trend for increased Gln, as well as a substantial decrease in Ch_{tot}, Glu, and ml_{tot}. The concentration alterations tended to be more marked in the ROI that was placed almost exclusively in areas of MRI hyperintensities. In gray matter the only relevant abnormality was a 10% reduction of NAA_{tot} without accumulation of Lac. Six months later, most abnormalities had partially recovered. However, a deficit in NAA_{tot} remained for all ROIs and also the surplus in Gln remained in both WM regions. Ch_{tot}, ml_{tot}, and Cr_{tot} tended to be overcompensated. There was no increase in lipid signals in any spectra. The results of the two investigations are summarised in Table 1 and Fig. 2.

Discussion

Several neurological disorders have been described in association with heroin addiction such as acute thoracic and cervical myelopathy, optic neuropathy, rhabdomyolysis and chronic myopathy, mostly after intravenous administration [5]. Another rare complication is toxic leukoencephalopathy, which has been assumed to typically occur after inhalation of heroin pyrolysate. It was assumed that contamination of heroin with certain additives contributed to the development of encephalopathy. In the largest study, Wolters et al [15] analysed an outbreak of toxic encephalopathy affecting 47 persons within a few months. On autopsy, spongiform encephalopathy, characterized by fluid accumulation restricted to myelin sheets and without apparent injuries to the blood-brain barrier was seen. Meticulous work-up failed to reveal any causative agents and the neurologic outcome was not correlated with the duration of heroin addiction, or the quantity of heroin used. This type of encephalopathy was not re-

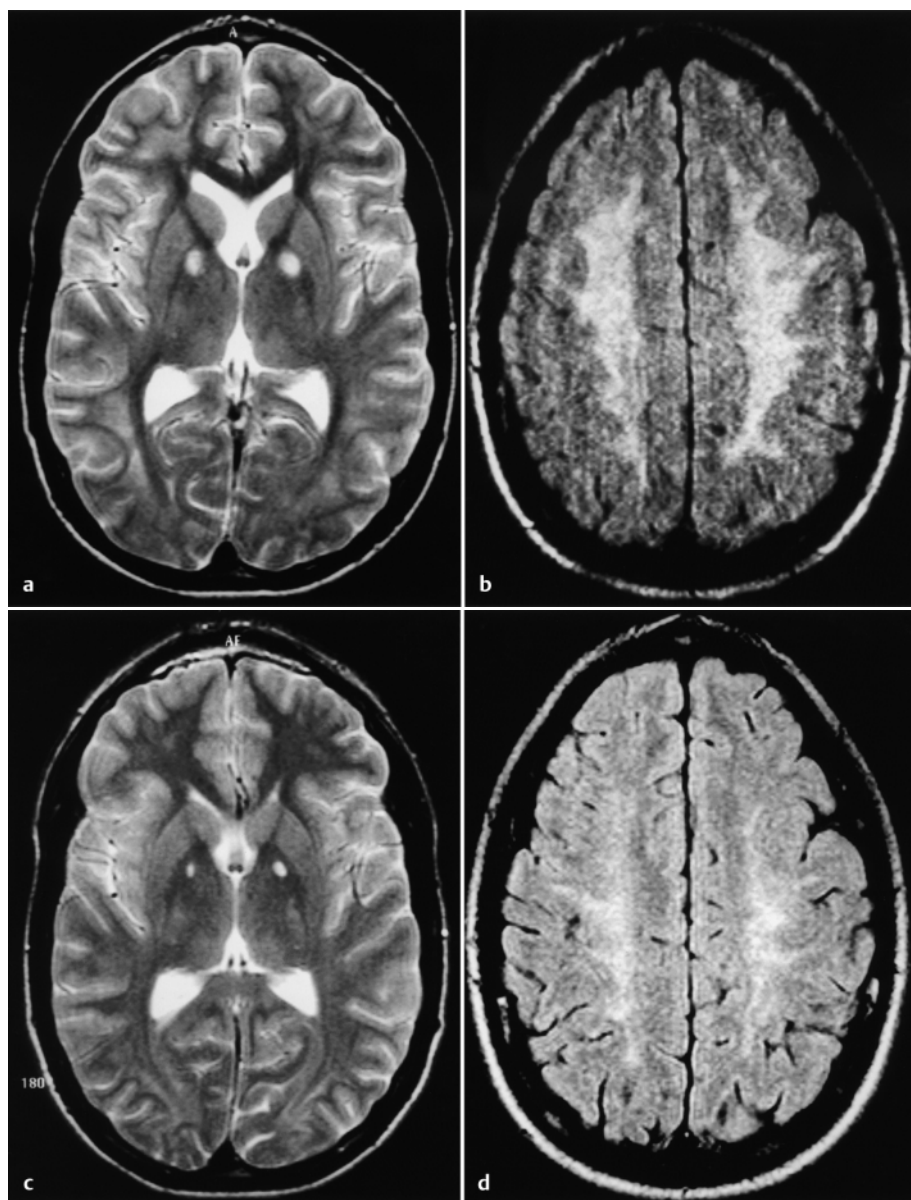


Fig. 1 **a to d** Initial MRI 5 days after heroin intake: **a** Hyperintensities in T2WI are found in the ventral globi pallidi and to a lesser degree in deep white matter. The U-fibres are preserved. **b** Marked diffusion disorder in axial DWI of deep white matter. At 6 months follow-up: **c** In the T2WI, a reduction in size of the lesions in the globi pallidi and in the deep white matter is seen. **d** FLAIR images show residual hyperintensities.

produced in animals exposed to different mixtures of heroin pyrolysates. Hence, the hypothesis that an additive caused this rare form of encephalopathy was not supported.

It was also questioned that a causative factor could be generated by way of heroin inhalation. However, a report of a 2.5-year-old child swallowing heroin accidentally, described the same clinical presentation and MRI findings [11] as in patients who inhaled heroin [8,12]. Coincidence of these findings with hypoxic or ischemic injuries of the brain can be ruled out, since the more occipital and cerebellar distribution of the lesions would have been unusual for such an etiology. In addition, many of the patients described in the literature died under monitoring in hospitals, providing reliable information that contributing causes of brain hypoxia/ischemia such as systemic hypoxia or cardiovascular failure were not present [5,12,15]. Underlying inborn errors of metabolism which typically involve the globus pallidus, are methylmalonic acidemia and succinic semialdehyde dehydrogenase deficiency. In our subject both the normal previous neurocognitive development and unremarkable urinary metabolic

screening on admission make these disorders unlikely. In retrospect, the pattern of globus pallidus and periventricular white matter lesions in MRI is also compatible with carbon monoxide exposure [9]. At the time, no blood levels of carbon monoxide had been obtained, but there had also not been any hints of such an exposure at the subject's home.

Kriegstein et al [8] applied MRS to regions of interest in cerebral white matter of three addicts who had inhaled heroin and had typical findings of toxic leukoencephalopathy. Lactate peaks of variable intensity were shown in two of the patients, and they concluded that mitochondrial damage with at least partial recovery could explain the observed clinical and MRS features.

The ^1H -MRS results in our subject are – where applicable – in qualitative agreement with this report. However, they extend beyond these results, because they were recorded with short echo-time and in a quantitative manner, such that more metabolites were observed and the changes could be reported in absolute units. The decreases in NAA_{tot} and Ch_{tot} that had been reported

Table 1 Metabolite contents[‡] of white matter ROIs in two examinations compared to normal values obtained from age-matched subjects. Significant abnormalities[#] are indicated in % (CSO = centrum semiovale)

| | CSO exam 1 | $\Delta^{\#}$ [%] | Affected WM exam 1 | $\Delta^{\#}$ [%] | CSO exam 2 | $\Delta^{\#}$ [%] | Affected WM exam 2 | $\Delta^{\#}$ [%] | Norm |
|------------|---------------|----------------------|-----------------------|----------------------|----------------|----------------------|-----------------------|----------------------|---------------|
| NA_{tot} | 7.0 ± 0.2 | -23% | 6.7 ± 0.4 | -27% | 8.1 ± 0.2 | -11% | 8.6 ± 0.5 | | 9.1 ± 0.7 |
| Cr_{tot} | 4.6 ± 0.1 | | 3.8 ± 0.3 | -18% | 5.0 ± 0.1 | | 4.7 ± 0.4 | | 4.6 ± 0.2 |
| Ch_{tot} | 1.3 ± 0.1 | -27% | 1.0 ± 0.1 | -42% | 2.0 ± 0.1 | | 2.2 ± 0.2 | | 1.8 ± 0.2 |
| ml_{tot} | 2.8 ± 0.2 | | 1.7 ± 0.3 | -51% | 4.6 ± 0.2 | | 4.2 ± 0.6 | | 3.6 ± 0.6 |
| Lac | 1.5 ± 0.2 | +371% | 3.6 ± 0.4 | +1081% | -0.1 ± 0.2 | | 0.0 ± 0.8 | | 0.3 ± 0.1 |
| Gln | 1.1 ± 0.4 | | 1.6 ± 0.8 | | 1.9 ± 0.4 | +255% | 2.3 ± 1.2 | | 0.5 ± 0.4 |
| Glu | 5.2 ± 0.4 | -17% | 3.8 ± 0.9 | -39% | 5.4 ± 0.4 | | 2.4 ± 1.3 | | 6.2 ± 0.5 |
| Gln+Glu | 6.3 ± 0.5 | | 5.4 ± 0.7 | | 7.3 ± 0.4 | | 4.7 ± 1.3 | | 6.8 ± 0.5 |

[‡] Given in units of mmol/kg, not corrected for potential changes in water content or relaxation times. Both corrections are expected to be minimal with the acquisition parameters used.

[#] Significant deviation from norm, if measured value was outside normal range defined by mean \pm 2 SD (where SD is taken as the variation within the control population for the large ROI, while SD represents the measurement uncertainty for the small ROI).

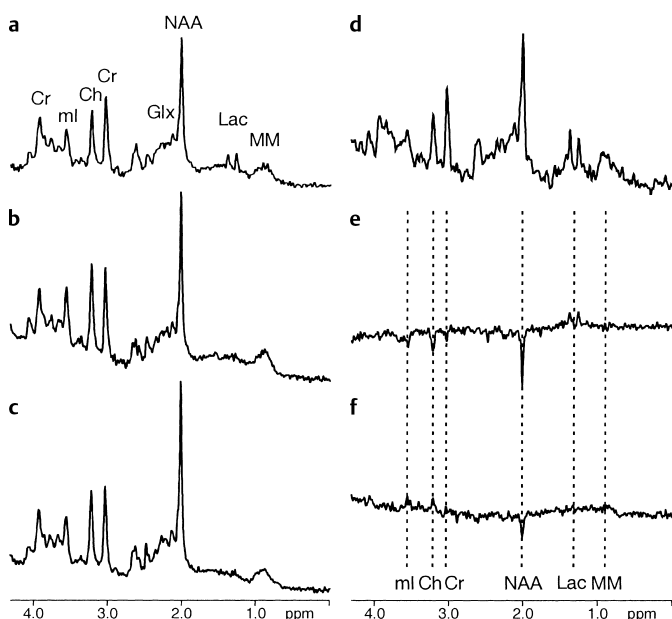


Fig. 2 Short TE ^1H -MR spectra of centrum semiovale in the patient, at 8 days (**a**) and 6 months (**b**) after heroin vapor inhalation, and compared to an averaged normal control spectrum from the same region (**c**). The spectrum from a ROI almost completely with the MRI hyperintensities from day 8 is plotted in (**d**). Difference spectra with respect to the norm obtained at the two time points are drawn in (**e**) and (**f**). [(e) = (a) - (c) and (f) = (b) - (c)]. The main features obtained by numeric analysis are evident also from the difference spectra: a persistent deficit in NAA, an initial rise in Lac, and initial deficits in Ch and ml that are reversed to excess concentrations at the 6 months follow-up.

relative to Cr before are now confirmed to be true in absolute units. Because these findings may be accompanied by a deficit in Cr in the affected brain WM, one can expect that the earlier report underestimated the depletions in NAA and Ch_{tot} somewhat within the lesions. The MRS results indicate that in the present case grey matter was not fully spared. In accordance with other reported cases [8], a lack of increase in Ch_{tot} and lipids indicates that acute demyelination or necrosis can be excluded. A deficit in NAA accompanied by an increase in Lac is seen in many

conditions. In particular, it would be in accordance with both a mitochondrial dysfunction and a hypoxic/ischemic event. Given the information from the other metabolites, one can try to evaluate the likelihood of these scenarios. A decrease in NA_{tot} , Cr_{tot} , Ch_{tot} and a relative increase in Gln in conjunction with elevated Lac have been observed as secondary effects of global hypoxia [7]. However, in this condition the regional distribution of abnormalities was quite different, with grey matter being primarily affected. Additionally, there was no ml depletion. Mitochondrial dysfunction in MELAS has been studied with quantitative MRS by Wilichowski et al [14]. Their results agree in terms of the appearance of Lac and the deficits for NAA, Cr_{tot} , Ch_{tot} , and Glu for some brain areas. Mitochondrial dysfunction, however, was neither associated with an increase in Gln, nor with a deficit in ml. Furthermore, grey matter was affected more than WM. Hence, the observed pattern of metabolic changes in this patient after heroin inhalation does not agree with either pure effects of mitochondrial dysfunction or with secondary hypoxic energy break down. In either case one has to invoke an unknown mechanism that aggravates metabolic sequelae in WM and furthermore a reason why ml is also decreased. Global reduction of metabolites is generally associated with hypo-osmolar states. A specific reason for a depletion of ml could be found in an osmolar imbalance in glial cells, caused by the surplus of Gln [3].

The follow-up exam showed a partially normalized metabolite profile, where a remaining deficit in neuronal metabolites (NA_{tot} , Glu) and a surplus of predominantly glial metabolites (ml, Gln) hint at reactive gliosis in response to the injury. The remaining NA_{tot} deficit in grey matter would also be compatible with an individually low NA_{tot} content, independent of the heroin inhalation. Also, DWI showed diffuse hyperintensities in deep WM with relative sparing of cortical matter. DWI probably provides a more unspecific marker of tissular motion than was previously thought and does not necessarily represent a specific assay for ischemic events at the neuronal level. In a previous case with onset of symptoms 2 months after heroin consumption, Chen et al [2] had similar findings with diffuse changes in the deep WM. They postulated that the diffuse decrease of apparent

diffusion coefficient in WM could be due to fluid entrapment within the myelin lamellae without demyelination. This would agree with both the literature and our MRS data, where signs of axonal injury were observed, but not demyelination.

Like the child with a single oral heroin ingestion [11], the presented patient did not demonstrate any clinical or radiological involvement of the cerebellum, in contrast to other reports that described ataxia and cerebellar lesions as key features of this entity [5, 8, 12, 13, 15].

In conclusion, this MR study is the first reported follow-up of leukoencephalopathy occurring acutely after a first inhaled dose of heroin. We postulate that toxic spongiform leukoencephalopathy in heroin addicts may be the outcome of a complex mechanism directly triggered by heroin and causing mitochondrial as well as hypoxic injury in specific and limited areas of white matter. Sparing of the cerebellum compared to other brain areas may reflect a higher cerebellar resistance to short-term toxic stress.

Acknowledgements

We would like to thank Prof. Robert Ouvrier, Department of Child Neurology, The Children's Hospital at Westmead, Sydney, Australia, for his help in the preparation of the manuscript. The study was supported by the Swiss National Science Foundation (31-59082.99), the Rudolf Kern Foundation and the Ruth de Bernardi Foundation, both Switzerland.

References

- ¹ Chang YJ, Tsai CH, Chen CJ. Leukoencephalopathy after inhalation of heroin vapor. *J Formos Med Assoc* 1997; 96: 758–760
- ² Chen CY, Lee KW, Lee CC, Chin SC, Chung HW, Zimmerman RA. Heroin-induced spongiform leukoencephalopathy: value of diffusion MR imaging. *J Comput Assist Tomogr* 2000; 24: 735–737
- ³ Häussinger D, Laubenberger J, vom Dahl S, Ernst T, Bayer S, Langer M et al. Proton magnetic resonance spectroscopy studies on human brain myo-inositol in hypo-osmolarity and hepatic encephalopathy. *Gastroenterology* 1994; 107: 1475–1480
- ⁴ Hofmann L, Slotboom J, Jung B, Maloca P, Boesch C, Kreis R. Quantitative ¹H-magnetic resonance spectroscopy of human brain: Influence of composition and parameterization of the basis set in linear combination model fitting. *Magn Reson Med* 2002; 48: 440–453
- ⁵ Hungerbuehler H, Waespe W. Leukoencephalopathie nach Inhalation von Heroin-Pyrolisat. *Schweiz Med Wochenschr* 1990; 120: 1801–1805
- ⁶ Kreis R. Quantitative localized ¹H-MR spectroscopy for clinical use. *Prog NMR Spectroscopy* 1997; 31: 155–195
- ⁷ Kreis R, Arciniegua E, Ernst T, Shonk TK, Flores R, Ross BD. Hypoxic encephalopathy after near-drowning studied by quantitative ¹H-magnetic resonance spectroscopy: Metabolic changes and their prognostic value. *J Clin Invest* 1996; 97: 1142–1154
- ⁸ Kriegstein AR, Shungu DC, Millar WS, Armitage BA, Brust JC, Chillrud S et al. Leukoencephalopathy and raised brain lactate from heroin vapor inhalation. *Neurology* 1999; 53: 1765–1773
- ⁹ O'Donnell P, Buxton PJ, Pitkin A, Jarvis LJ. The magnetic resonance imaging appearances of the brain in acute carbon monoxide poisoning. *Clin Radiol* 2000; 55: 273–80
- ¹⁰ Provencher SW. Estimation of metabolite concentration from localized in vivo proton NMR spectra. *Magn Reson Med* 1993; 30: 672–679
- ¹¹ Roulet Perez E, Maeder P, Rivier L, Deonna T. Toxic leukoencephalopathy after heroin ingestion in a 2 ½-year-old child. *Lancet* 1992; 340: 729
- ¹² Tan P, Algra PR, Valk Jaap, Wolters EC. Toxic leukoencephalopathy after inhalation of poisoned heroin: MR Findings. *AJNR* 1994; 15: 175–178
- ¹³ Weber W, Henkes H, Moller P, Bade K, Kuhne D. Toxic spongiform leukoencephalopathy after inhaling heroin vapor. *Eur Radiol* 1998; 8: 749–755
- ¹⁴ Wilichowski E, Pouwels PJ, Frahm J, Hanefeld F. Quantitative proton magnetic resonance spectroscopy of cerebral metabolic disturbances in patients with MELAS. *Neuropediatrics* 1999; 30: 256–63
- ¹⁵ Wolters EC, van Wijngaarden GK, Stam FC, Rengelink H, Lousberg RJ, Schipper MEI et al. Leukoencephalopathy after inhaling heroin pyrolysate. *Lancet* 1982; ii: 1233–1237