

ence, a painful spasm of the extensor muscles due to an increased forward bending position of the neck, often accompanies the headaches of children.⁵ Systemic musculoskeletal hypermobility, including hypermobility of the cervical spine, frequently explains the comorbidity of headaches with transitory pains in the locomotor system of children. I suggest, therefore, that in children with headaches, one should first look for organic/cervicogenic pain-generating mechanisms.

Gabor Ormos, MD

Department of Manual Medicine

National Institute for Rheumatology and Physiotherapy

Budapest, Frankel L. 25.

Hungary 1055

REFERENCES

1. Koenig MA, Gladstein J, McCarter RJ, Hershey AD, Wasiewski W. Chronic daily headache in children and adolescents presenting to tertiary headache clinics. *Headache*. 2002;42:491-500.
2. Fichtel A, Larsson B. Psychosocial impact of headache and comorbidity with other pains among Swedish school adolescents. *Headache*. 2002;42:766-775.
3. Gutman G. Das cervical-diencephal-statische Syndrom des Kleinkindes. *Man Med*. 1968;6:112-119.
4. Lewit K. Ligament pain and anteflexion headache. *Eur Neurol*. 1971;5:365-378.
5. Ormos G. Main types of cervical cephalgia. *Rheumatol Balneol Allergol*. 1978;XIX:88-92.

Migraine-Induced Stroke in a Patient With Migraine-Related Epilepsy

Patients with epilepsy are 2.4 times more likely to suffer from migraine, mostly migraine with aura or basilar migraine, than their relatives without epilepsy.^{1,2} The spectrum of epilepsy syndromes associated with migraine includes primary generalized seizures, benign childhood epilepsies, and partial-onset seizures.^{1,2} In many patients with migraine-related epilepsy (MRE), identical aura symptoms in both disorders or seizures evolving from migraine auras have been described,^{1,2} suggesting a significant pathophysi-

ological overlap of both events. We report a case of MRE associated with migrainous stroke in which valproate proved an efficient prophylaxis for both migraine with aura as well as absence epilepsy.

A 22-year-old woman was referred to us with right upper quadrant anopsia. The visual deficit was persistent after a migrainous aura that had started with a scintillating scotoma in the right visual hemifield. The patient suffered from migraine with aura since adolescence. Her auras usually consisted of teichopsia, aphasia, or mild hemiparesis of about 20 to 30 minutes' duration. Migraine auras were followed by pulsating hemicranial headache of 2 to 3 days' duration that was accompanied by photophobia, phonophobia, and nausea and was responsive to oral zolmitriptan. The patient described an aggravation of the headache by routine physical activity. She smoked about 10 cigarettes per day and took oral contraceptives. A close review of her medical history revealed episodes of reduced interpersonal contact lasting for about 5 seconds since aged 10. These episodes would very often coincide with a migrainous aura. Family history was remarkable for maternal migraine with aura.

Neurologic examination was normal except for the anopsia. A T2-weighted magnetic resonance imaging (MRI) detected a left occipital cortical infarct (Figure 1A, 1B). Proton MR spectroscopy (SVS Steam 135) of noninfarct tissue showed no signs of neuronal damage or underlying encephalopathy. Electroencephalography (EEG) disclosed generalized groups of 4- to 5-Hz spike and wave discharges lasting up to 3 seconds (Figure 1C). Genetic analysis was negative for mitochondrial mutations associated with the syndrome of myopathy, encephalopathy, lactic acidosis, and strokelike episodes (MELAS). Twenty-four-hour monitoring of electrocardiography and blood pressure were normal. Glucose tolerance test was within normal limits. Routine blood and cerebrospinal fluid parameters were physiological. Tests for prothrombotic factors and antiphospholipid antibodies were negative. Transcranial and extracranial duplex sonography of the cervicocephalic arteries and transesophageal echocardiography were unremarkable. No evidence of a patent foramen ovale was found.

We diagnosed a migraine-induced infarction based on the International Headache Society criteria. Prophyl-

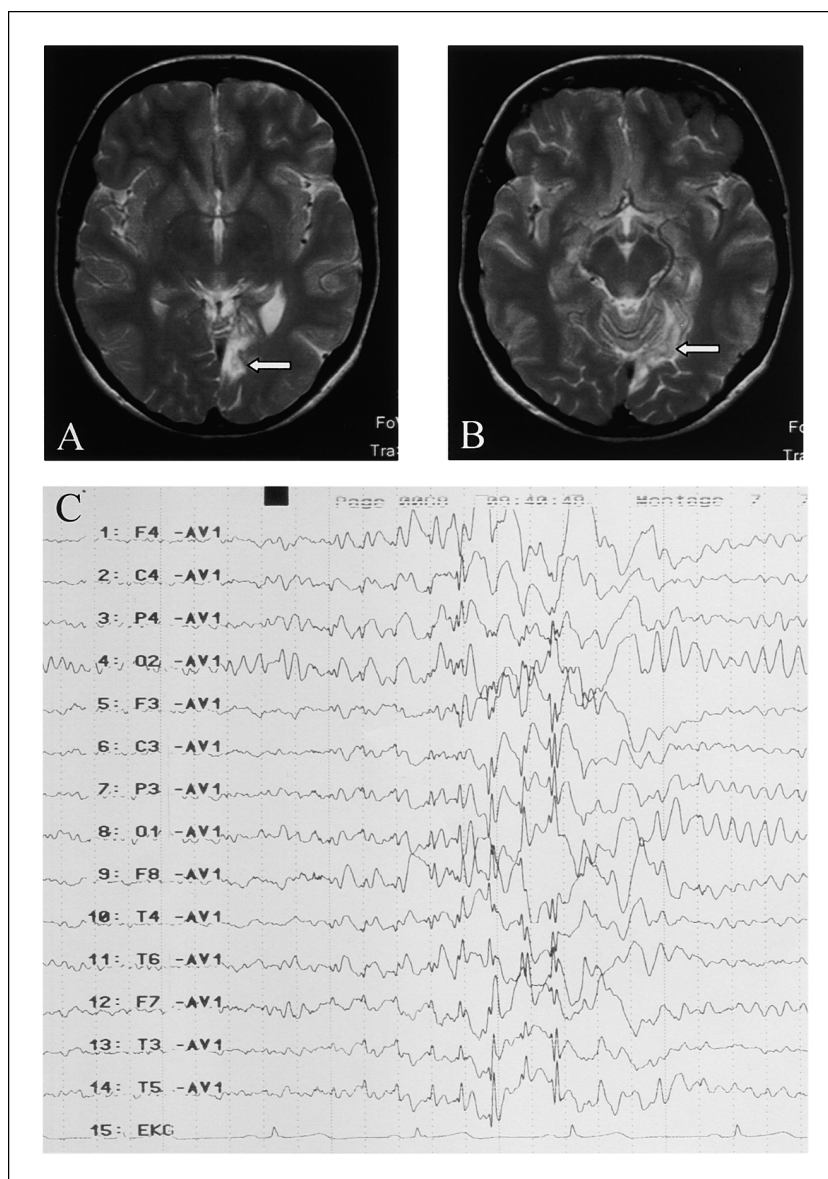


Fig. 1A-1C.—Top row, axial T2-weighted magnetic resonance (MR) images (A, B). The left-sided infarcted area involves the anterior radiatio optica as well as the anterior part of the primary visual cortex (arrows), corresponding to the patient's right upper quadrant anopsia. Bottom row (C), the electroencephalogram demonstrates a group of 4- to 5-Hz spike and wave discharges.

lactic treatment with 900 mg valproic acid was initiated. Within 1 week, the absences subsided and the EEG became normal (valproate serum level, 89.5 $\mu\text{g/mL}$).

At follow-up examinations 3 and 9 months later, the patient reported that her migraine with aura had also become scarce, from an average of 5 attacks per month before treatment to 1 attack per month.

Our findings correlate with several characteristics of MRE.^{1,2} Like most MRE cases, our patient had migraine with aura. Furthermore, her seizures often

occurred in close temporal proximity to her auras. This aspect may corroborate the theory of a common pathophysiological basis of both disorders. In fact, both absence epilepsy and familial hemiplegic migraine (FHM) have been linked to mutations in the *CACNA1A* gene encoding the P/Q-type calcium channel,³ although our patient lacked the other clinical stigmata of FHM, eg, ataxia or prolonged aura.³

True migraine-induced stroke, ie, cerebral ischemia evolving from a migrainous aura, is an extremely rare

condition and may be difficult to differentiate from symptomatic migraine following cerebral ischemia of other cause. To our knowledge, an association with MRE has not been reported. The pathophysiology of migraine-induced infarction is currently unknown. It has been hypothesized that cortical spreading depression, the neurophysiological phenomenon underlying migraine aura, may lead to migraine-induced stroke if the coupling between neuronal metabolism and cerebral blood flow is disturbed.^{4,5} Absence epilepsy, in turn, is associated with cortical hyperexcitability. Human and animal in vitro epilepsy models suggest that epileptiform cortical hyperexcitability is often paralleled by the occurrence of spreading depression.⁶ This may possibly explain the link between absence epilepsy and migraine aura in our patient. It remains speculative whether the metabolic burden imposed on the cortex by the combination of both disorders was involved in the pathogenesis of migraine-induced stroke in our patient.

Since several epidemiological studies have suggested an increased risk of infarction for young female migraineurs who smoke and take oral contraceptives,⁷ the posterior infarct in our patient may also be related to her risk profile. It has not been clarified, however, whether these risk factors may only apply to infarcts in patients with coexisting migraine or also to true migraine-induced stroke, as in our case. Further studies are necessary to address this question.

Acknowledgments: This work was supported by Deutsche Forschungsgemeinschaft (DFG), SFB 507-A1.

Gabor C. Petzold, MD
 Randolph Klingebiel, MD
 Karl M. Einhäupl, MD
 Guy Arnold, MD
 José M. Valdueza, MD
 Jens P. Dreier, MD
 Charité Hospital
 Humboldt University
 Schumannstr. 20/21
 10098 Berlin, Germany

REFERENCES

1. Marks DA, Ehrenberg BL. Migraine-related seizures in adults with epilepsy, with EEG correlation. *Neurology*. 1993;43:2476-2483.
2. Ottman R, Lipton RB. Comorbidity of migraine and epilepsy. *Neurology*. 1994;44:2105-2110.
3. Kors EE, van den Maagdenberg AM, Plomp JJ, Frants RR, Ferrari MD. Calcium channel mutations and migraine. *Curr Opin Neurol*. 2002;15:311-316.
4. Dreier JP, Petzold G, Tille K, et al. Ischaemia triggered by spreading neuronal activation is inhibited by vasodilators in rats. *J Physiol*. 2001;531:515-526.
5. Bogousslavsky J, Regli F, Van Melle G, Payot M, Uske A. Migraine stroke. *Neurology*. 1988;38:223-227.
6. Avoli M, Drapeau C, Louvel J, Pumain R, Olivier A, Villemure JG. Epileptiform activity induced by low extracellular magnesium in the human cortex maintained in vitro. *Ann Neurol*. 1991;30:589-596.
7. Tzourio C, Kittner SJ, Boussier MG, Alperovitch A. Migraine and stroke in young women. *Cephalalgia*. 2000;20:190-199.

Response to "More on Migraine and Coronary Artery Disease"

We would like to thank Dr. Loder for her thoughtful letter concerning our recent publication regarding the relationship between migraine and subsequent coronary heart disease in the Physicians' Health Study (PHS) and the Women's Health Study (WHS).¹ We, too, were concerned about the use of self-report of migraine in our study and used several means to examine its possible impact. First, we were concerned about the possibility of false-positives (ie, false reports of migraine by our participants). Since all were health professionals, we felt that this should be less of a problem than in other studies. We nonetheless examined the effect of using stricter migraine definitions which more closely followed the IHS criteria. The results, available only for the WHS, were very similar to those for the entire group.

Second, we were concerned about the possibility of false negative reports, the issue that Dr. Loder raised. To examine this issue, we created a third group consisting of those who reported headache but not migraine. We reasoned that those who experienced migraine were likely to at least report the occurrence of headache, even if they did not classify it as migraine headache. We then directly compared those reporting migraine to those reporting neither migraine nor