

Case report

MR evaluation of crossed and uncrossed cerebral–cerebellar diaschisis

Chakravarty A. MR evaluation of crossed and uncrossed cerebral–cerebellar diaschisis.

Acta Neurol Scand 2003; 108: 60–65. © Blackwell Munksgaard 2003.

In three patients with infantile hemiplegia syndrome, MR imaging done later in life showed significant volume loss in the cerebellar hemisphere contralateral to the side of the affected cerebrum in two and ipsilateral in one. By comparison, the cerebellar volume loss seemed to correlate with the degree of volume loss in the contralateral cerebral hemispheres in two patients. These observations provide morphological evidence of the phenomenon of crossed and uncrossed/ipsilateral cerebral–cerebellar diaschisis (CCD and ICD). Functional neuroimaging studies in support of the concept of CCD and ICD have been critically reviewed in the light of the morphological changes demonstrated in the cases cited herein.

A. Chakravarty

Division of Neurology, Vivekananda Institute of Medical Sciences, Calcutta

Key words: crossed cerebral–cerebellar diaschisis; ipsilateral cerebral–cerebellar diaschisis

Ambar Chakravarty, 59, Beadon Street, Calcutta – 700 006

Tel.: +91 33 25546271

Fax: +91 33 23528653

e-mail: saschakra@yahoo.com

Accepted for publication August 20, 2002

Diaschisis in neurology signifies reduction of function of a part of the brain following the interruption at a remote site of an afferent pathway which normally supply background excitation to the neurons in that part, keeping them in a state of low activity (1). The concept was introduced first by von Monakow who described diaschisis corticospinalis (progression of functional depression of the spinal cord following an injury to the motor cortex); diaschisis commisuralis (functional depression of the contralateral cerebral cortex after injury to cortex of one hemisphere); and diaschisis associativa (depression of function in intact cortical areas adjacent to the site of a cortical injury) (1).

Each cerebellar hemisphere is intimately connected to the contralateral cerebral cortex through feed-back circuits, needed for smooth execution of motor function. Cerebellar afferents reaching the cortex of one cerebellar hemisphere are relayed through the cerebello-dentate, dentato-rubral (crossed), rubro-thalamic and thalamo-cortical projections to the opposite motor cerebral cortex. The latter, in turn, tends to modulate cerebellar control of motor function through cortico-pontine (uncrossed mostly) and ponto-cerebellar (crossed mostly) pathways to the opposite cerebellar cortex. The concept of crossed cerebral cerebellar diaschisis following injury (usually vascular) to the motor

cortex of one cerebral hemisphere was popularized by Baron and his colleagues (2). The effect on the cerebellum was one of reduction of blood flow and energy metabolism secondary to neuronal depression resulting from infarction of the opposite cerebral hemisphere. Recent works with advanced technology have thrown further light on the subject and will be discussed.

In the present communication, the author will discuss MR evidence of structural changes induced in the cerebellum as a result of such changes in vascularity and metabolism, secondary to injury to the contralateral cerebral hemisphere in two patients and ipsilateral cerebral hemisphere in one patient, all with infantile hemiplegia syndrome.

Observations

Case 1

A 30-year-old male was first seen in May 1999 for control of refractory complex partial seizures. The seizures were characterized by speech arrest, right upper limb jerking and brief periods of loss of consciousness. In early childhood (below 1 year of age) he had an episode of recurrent seizures (probably right focal motor with secondary generalization) following which he developed a right hemiparesis which persists to date. Only infrequent

seizures occurred until the age of 10 years, but thereafter the seizure frequency increased considerably in spite of anticonvulsant therapy. He remained mentally subnormal (verbal IQ < 60) and never attended school. He had a spastic right hemiparesis with the right hand considerably smaller in size than the left, but he remained independently mobile. His seizure control improved following treatment with carbamazepine, clobazam and topiramate.

On MR imaging (Figs 1 and 2) the left cerebral hemisphere showed moderate volume loss with widening of the sulci especially in the sylvian area and compensatory dilatation of the lateral ventricle on the same side. The left side of the brain stem was flattened. The right cerebellar hemisphere showed moderate volume loss with widening of the sulci and thinning of the folia. Total hemispheric volumetry was not possible with the

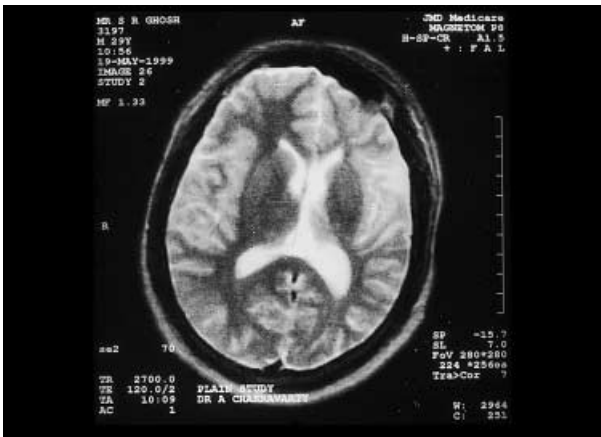


Figure 1. Case 1. MR brain (T2W1) showing moderate left cerebral hemiatrophy. Area of hyperintensity in the left sylvian area indicates dilated CSF space resulting from atrophy.

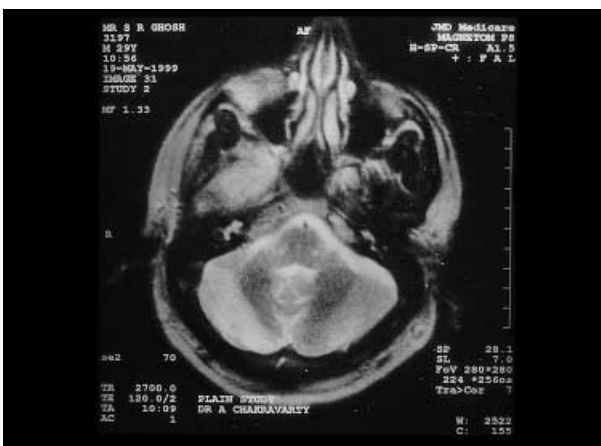

Figure 2. Case 1. MR brain (T2W1) showing right cerebellar hemispheric volume loss evidenced by increased area of hyperintensity.

scanner used but the significant volume loss mentioned was quite apparent. SPECT study was not done as the neurologic insult had been of very long duration.

Case 2

A 14-year-old female was first seen in June 2000 for treatment of spasticity. Details of her birth history were not available and reduced movement of left limbs was noted quite early (< 1 year of age). Her milestones were delayed and dragging of left leg was noted when walking started around two and a half years of age. She was found to be grossly mentally retarded and developed marked behavioral problems over the years. She had a few seizures early in life with fever but thereafter these did not recur. Examination revealed a retarded girl with slurred speech, left hemiparesis and marked spastic dystonia of the left limbs. The left hand and foot were considerably smaller than the right.

MR imaging of the brain (Figs 3–5) revealed gross hemiatrophy of the right hemisphere with considerable dilatation (compensatory) of the right lateral ventricle and widening of the overlying subarachnoid space. The right cerebral peduncle was considerably atrophied. The left cerebellar hemisphere showed considerable volume loss. As in Case 1 hemispheric volumetry was not possible.

Case 3

A 14-year-old male was seen in January 2002 for uncontrolled right focal motor seizures with occasional secondarily generalized seizures which started around 18 months of age. The boy was delivered by LUCS at full term and there was no history of birth asphyxia. Milestones were delayed

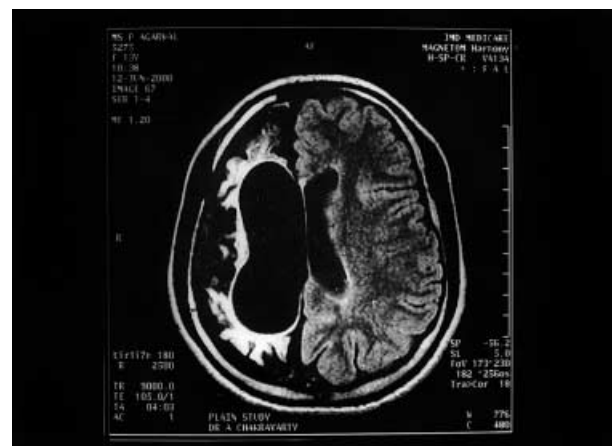


Figure 3. Case 2. MR brain (FIAIR) showing gross right cerebral hemiatrophy.

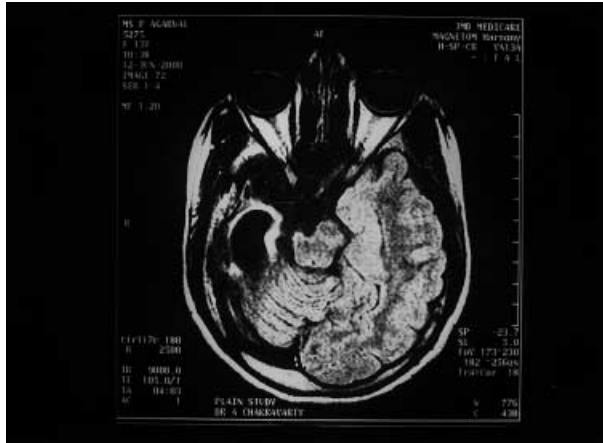

Figure 4. Case 2. MR brain (FLAIR) showing significant atrophy of right cerebral peduncle.

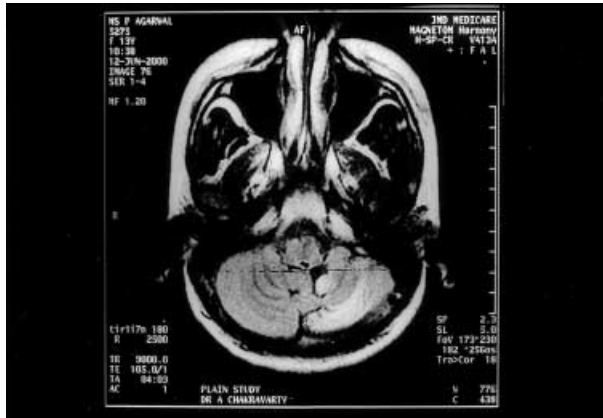

Figure 5. Case 2. MR brain (FLAIR) showing volume loss in left cerebellar hemisphere evidenced by increased area of hyperintensity.

and reduced movements of right limbs were noted as early as 3 months of age. He was mentally subnormal (verbal IQ 70). In his childhood he underwent some form of a neurosurgical procedure on the left brain, but details were not available. At presentation, he had a spastic right hemiparesis with slurred speech, and the right hand and foot were smaller than the left.

On MR imaging, a large area of marked T1 and T2 lengthening with gliotic bands and peripheral rim was seen involving the left fronto-parieto-temporal region (encephalomalatic change) corresponding to the distribution of the left middle cerebral artery. Significant regional volume loss (hemiatrophy) with widening of the left lateral ventricle was noted. Post-operative changes with ferromagnetic artifact were seen at the left parietal region. The left side of the brain stem showed volume loss. The left cerebellar hemisphere also showed significant volume loss (Figs 6–8). Volu-

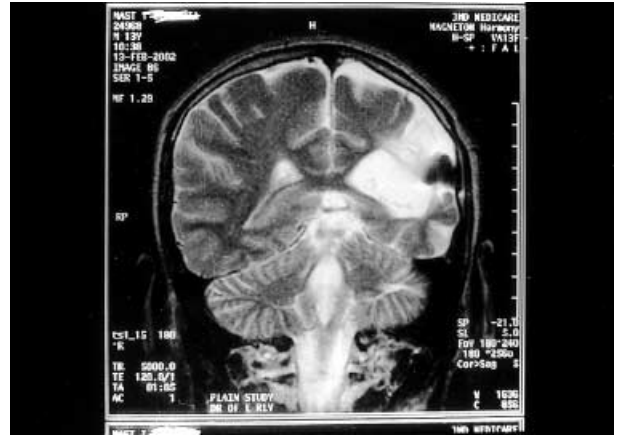

Figure 6. Case 3. MR brain (T2WI) showing encephalomalacia and volume loss in left cerebral hemisphere and volume loss of left cerebellar hemisphere.

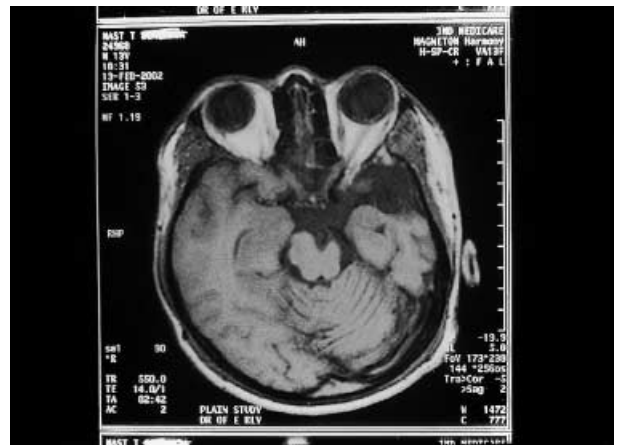

Figure 7. Case 3. MR brain (T1WI) showing atrophy of left cerebral peduncle.

metric studies could not be performed. It seems likely that the past neurosurgical procedure was a burr hole exploration of the encephalomalatic area. The boy's seizures could be kept under reasonable control with a combination of phenytoin and carbamazepine.

Discussion

All the aforementioned cases can be taken as examples of Infantile Hemiplegia Syndrome. The onset of the problem in all cases had been very early in life as judged by the hand and foot size differences, mental subnormality and the degree of hemi-cerebral atrophy demonstrated on MR imaging. It appears from the histories that the cerebral insult in Case 3 probably occurred earlier (pre or perinatal) than the other two cases. Case 1 and 3 had features of the Hemiplegia–Hemiatrophy–

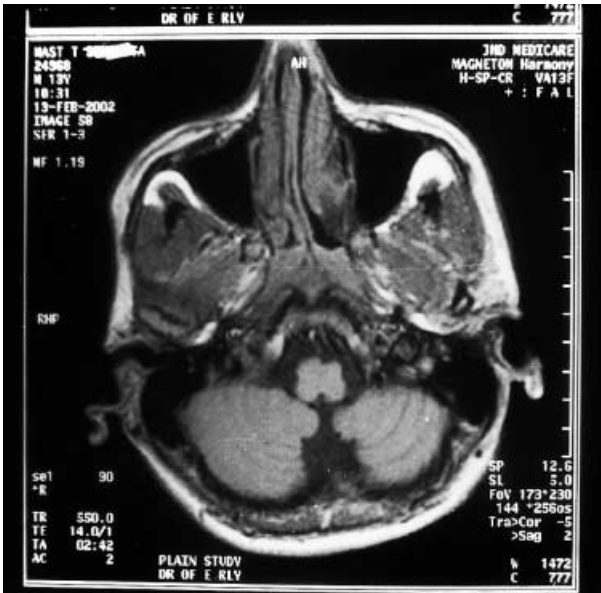

Figure 8. Case 3. MR brain showing volume loss of left cerebellar hemisphere.

Hemiconvulsion syndrome, but seizures had not been a major problem in Case 2 who was considerably more handicapped physically. The etiology of the cerebral injury remains unclear, but the possibility of a vascular injury early in life remains. This appears more likely in Case 3 in view of the site of encephalomalatic changes seen on MR imaging.

MR imaging in all revealed unilateral cerebral hemiatrophy; atrophy of the ipsilateral cerebral peduncle (suggesting degeneration of ipsilateral cortico-bulbar and cortico-spinal tracts) and volume loss in the contralateral cerebellar hemispheres in Cases 1 & 2 and ipsilateral in Case 3. The latter finding would suggest structural cerebellar affection as a result of injury to the contralateral cerebral hemisphere (crossed cerebral cerebellar diaschisis – CCD) in Cases 1 & 2 and ipsilateral cerebral hemisphere (uncrossed/ipsilateral cerebral–cerebellar diaschisis – ICD) in Case 3. It may be of interest to compare the MR images of the three cases. Case 2 undoubtedly had a more marked cerebral hemiatrophy, and this has been reflected in the more obvious atrophy of the ipsilateral cerebral peduncle and greater volume loss in the contralateral cerebellar hemisphere than the other two cases. This observation would be in concordance with the concept of crossed cerebral–cerebellar diaschisis (CCD). However, in spite of marked cerebellar volume loss in one hemisphere, none of the cases showed any clinical evidence of cerebellar disease. The significant motor deficit and spasticity undoubtedly marked any cerebellar component in the clinical evaluation.

CCD has been studied in hemiplegic children mostly by functional neuroimaging like SPECT. In the study by Homano et al. (3), seven of 25 patients studied had cerebral palsy and the others were impaired by acquired brain injury between 10 months and 14 years of age. CCD (hypoperfusion on SPECT) was demonstrated in five patients (20%) who were impaired by acquired brain injury after 7 years of age. CCD could never be detected in patients with cerebral palsy. Ipsilateral cerebellar diaschisis was also demonstrable in two patients with cerebral palsy and in three with early acquired brain injury before 3 years of age. The authors suggested that diaschisis (manifested by hypoperfusion) presents itself as a different form (ipsilateral or contralateral) depending upon the age of cerebral insult. Early insults would be likely to produce ipsilateral and later ones to produce a crossed cerebellar diaschisis. The same observation had been made by the authors at a later date by SPECT studies on a larger number of children with hemiplegic syndromes (4).

Other workers (5) also commented on this difference in side of cerebellar diaschisis depending upon the age of onset of the cerebral injury. It has been suggested that the production of remote effects, such as crossed and uncrossed cerebellar diaschisis, could be closely related to maturation of the cortico-ponto-cerebellar tract in the developing brain during childhood. CCD has been demonstrated by SPECT study in a young boy with basal ganglion germinoma which improved after therapy of the offending lesion (6). CCD has also been studied in adults with hemispheric brain injury by functional neuroimaging (SPECT) in various conditions including Alzheimer's disease (7), ischemic cerebro-vascular disease (8–11), cerebral hematomas (12), brain tumors (13), head injury (14) and epilepsy (15).

None of the studies quoted above has, however, mentioned the morphological changes observed in the cerebellum as a result of CCD or ICD. The present report appears to be significant in that, in all subjects, evidence of cerebellar volume loss could be detected on MR imaging contralateral (Cases 1 & 2) or ipsilateral (Case 3) to the side of cerebral lesion. Furthermore, there appears to be some correlation between the degree of morphologic damage to the cerebrum and the volume loss in the opposite cerebellum in the first two cases. Only one report commented on such morphological alteration in the cerebellum on MR imaging and found similar correlation (16). No detailed volumetric study has been reported.

One further point needs to be critically evaluated in this connection. All the reported cases herein, appear to have had the cerebral insult quite early in life (before 1 year of age) and all showed evidence of CCD/ICD morphologically. In view of this observation, the author would like to modify the opinion expressed by Homano et al. (3, 4) that early cerebral injury below one year would be more likely to produce ipsilateral rather than contralateral cerebellar diaschisis. It appears more likely that very early (pre or perinatal as in Case 3) cerebral injury can be expected to produce ipsilateral cerebellar damage (ICD) while cerebral insult at a later date (probably after 1 month of age as in Cases 1 & 2) would be more likely to produce crossed cerebellar lesions (CCD).

In this connection, the studies by Chugani and his colleagues (17, 18) seem noteworthy. These workers, using PET, demonstrated increased glucose utilization and increased binding of benzodiazepine receptors in the contralateral cerebellar hemisphere when brain injury occurred early in life before 1 year of age but after the first 4 weeks. This had been the case with Cases 1 & 2 cited in this communication. It appears that the increased metabolic rate perhaps signifies nature's defence mechanism to prevent neuronal damage in the contralateral cerebellum following cerebral injury. This certainly reflects deranged function in the cortico-ponto-cerebellar pathway (CCD). With increasing age, this increased metabolic rate is likely to decrease and morphological evidence of neuronal loss becomes evident. Imaging done later on, therefore, showed contralateral cerebellar volume loss. It is to be noted that this increased metabolic rate could not be demonstrated in older children and in adults in the contralateral cerebellum in these studies though hypoperfusion could be demonstrable on SPECT (vide supra). Naturally, there is difference in cerebellar functional reorganization pattern following contralateral cerebral injury between developing and developed brains. It is unclear from the studies quoted above about the pattern of such metabolic alteration when cerebral insult occurs very early in pre or perinatal period as in Case 3 of the present series.

A point of great interest may be the possible effect of unilateral cerebellar lesion on the contralateral cerebral hemisphere (crossed cerebello-cerebral diaschisis). Recently, Gasparini (19) et al. described a patient with linguistic impairment (without any other cognitive dysfunction) after a right cerebellar stroke. Though SPECT study showed gross hypoperfusion in the affected cerebellum, no perfusion alteration (diaschisis) could

be demonstrated in the opposite cerebral hemisphere. In contrast, Broich et al. (20) demonstrated SPECT evidence of contralateral cerebral hemispheric hypoperfusion following a right cerebellar infarction. Such studies are expected to throw considerable light on the non-motor functions of the human cerebellum.

References

1. FEENEY DM, BARON JC. Diaschisis. *Stroke* 1986;**17**:817–30.
2. BARON JC, BOUSSER MG, COMAR D, COSTAIGNE P. 'Crossed cerebellar diaschisis' in human supratentorial brain infarction. *Trans Am Neurol Assoc* 1980;**105**:459–61.
3. HAMANO S, NARA T, NOZAKI H et al. Crossed cerebellar diaschisis demonstrated by SPECT in hemiplegic children. *No To Hattatsu* 1991;**23**:58–64.
4. HAMANO S, NARA T, NAKANISHI Y et al. Secondary changes in cerebellar perfusion (diaschisis) in hemiplegia during childhood: SPECT study of 55 Children. *Pediatr Neurol* 1993;**9**:435–43.
5. SZTRIAH L, AL SUHAILI AR, PARIS V, NORK M. Regional cerebral blood perfusion in children with hemiplegia: a SPECT study. *Neuro-pediatrics* 1996;**27**:178–83.
6. AKIYAMA H, HARROP R, McGEER PL et al. Crossed cerebellar and uncrossed basal ganglia and thalamic diaschisis in Alzheimer's disease. *Neurology* 1989;**39**:541–8.
7. MARTIN MR, RAICHEL ME. Cerebellar blood flow and metabolism in cerebral hemisphere infarction. *Ann Neurol* 1983;**14**:168–76.
8. PANTANO P, BARON JC, SAMSON Y et al. Crossed cerebellar diaschisis (further studies). *Brain* 1986;**109**:677–94.
9. YAMAUCHI H, FUKUYAMA H, NAGAHAMA Y et al. A decrease in regional cerebral blood Volume and hematocrit in crossed cerebellar diaschisis. *Stroke* 1999;**30**:1429–31.
10. GONZALEZ-AGUADO E, MARTI-FABREGAS J, MARTI-VILALTA JL. The phenomenon of diaschisis in cerebral vascular disease. *Rev Neurol* 2000;**30**:941–5.
11. KIN SE, LEE MC. Cerebellar vasoreactivity in stroke patients with crossed cerebellar diaschisis assessed by acetazolamide and 99m Tc-HMPAO SPECT. *J Nucl Med* 2000;**41**:416–20.
12. LIM JS, RYU YH; KIM BM, LEE LD. Crossed cerebellar diaschisis due to intracranial hematoma in basal ganglia or thalamus. *J Nucl Med* 1998;**39**:2044–7.
13. PATRONAS NJ, DiCHIRO G, SMITH BH et al. Depressed cerebral glucose metabolism in supratentorial tumours. *Brain Res* 1984;**291**:93–101.
14. ALAVI A, MIROT A, NEWBERG A et al. Fluorine-18-FDG evaluation of crossed cerebellar diaschisis in head injury. *J Nucl Med* 1997;**38**:1717–20.
15. STUBGGEN JP. Crossed cerebellar diaschisis related to recurrent focal seizures. *Epilepsia* 1995;**36**:316–8.
16. TIEN RD, ASHDOWN BC. Crossed cerebellar diaschisis and crossed atrophy: correlation of MR findings, clinical symptoms and supratentorial diseases in 26 patients. *Am J Roentgenol* 1992;**158**:1155–9.
17. SHAMOFO H, CHUGANI HT. Glucose metabolism in the human cerebellum: an analysis of crossed cerebellar diaschisis in children with unilateral cerebral injury. *J Child Neurol* 1997;**12**:407–14.
18. NIIMURA K, CHUGANI DC, MUZIK O, CHUGANI HT. Cerebellar reorganisation following cortical injury in humans. Effects of lesion size and age. *Neurology* 1999;**52**:792–7.

19. GASPARINI M, DIPIERO V, CICCARELLI O et al. Linguistic impairment after right cerebellar stroke: a case report. *Eur J Neurol* 1999;**6**:353–6.
20. BROICH K, HARTMAN A, BIRSACK HJ, HORN R. Crossed cerebello-cerebral diaschisis in a patient with cerebellar infarction. *Neurosci Lett* 1987;**83**:7–12.