

# Neurorehabilitation and Neural Repair

<http://nnr.sagepub.com/>

---

## **Intramuscular Hand Neuroprosthesis for Chronic Stroke Survivors**

John Chae and Ronald Hart  
*Neurorehabil Neural Repair* 2003 17: 109  
DOI: 10.1177/0888439003017002005

The online version of this article can be found at:  
<http://nnr.sagepub.com/content/17/2/109>

---

Published by:



<http://www.sagepublications.com>

On behalf of:



[American Society of Neurorehabilitation](#)

Additional services and information for *Neurorehabilitation and Neural Repair* can be found at:

**Email Alerts:** <http://nnr.sagepub.com/cgi/alerts>

**Subscriptions:** <http://nnr.sagepub.com/subscriptions>

**Reprints:** <http://www.sagepub.com/journalsReprints.nav>

**Permissions:** <http://www.sagepub.com/journalsPermissions.nav>

**Citations:** <http://nnr.sagepub.com/content/17/2/109.refs.html>

>> [Version of Record](#) - Jun 1, 2003

[What is This?](#)

# Intramuscular Hand Neuroprosthesis for Chronic Stroke Survivors

John Chae and Ronald Hart

*The purpose of this study was to assess the feasibility of a percutaneous hand neuroprosthesis system for stroke survivors. Case reports of 4 chronic stroke survivors who were implanted with percutaneous intramuscular electrodes in various muscles of the forearm for hand grasp and release are presented. A percutaneous hand neuroprosthesis was able to open a spastic hemiparetic hand as long as the upper limb was in a resting position, the wrist and proximal forearm were supported, participants did not try to assist the stimulation, and an individual other than the participant modulated the stimulation. However, when participants tried to assist the stimulation or complete a functional task, hand opening was significantly reduced due to increased finger flexor hypertonia, even with increased stimulation intensity. Similarly, electrically stimulated hand opening was significantly reduced following voluntary hand closure. Techniques that provide real-time modulation of hypertonia with closed loop control, control strategies that are independent of the contralateral limb, and methods to enhance proximal control must be developed to demonstrate the feasibility of a hand neuroprosthesis system for persons with hemiparesis.*

Key Words: Neuroprosthesis—Stroke—Hemiparesis.

Functional neuromuscular electrical stimulation (NMES) is used to activate paralyzed or paretic muscles in precise sequence and intensity to assist in the performance of activities of daily living. Devices or systems that provide functional NMES are also appropriately called neuroprostheses. An implanted hand neuroprosthesis system has been shown to enhance the hand func-

tion of persons with cervical spinal cord injury.<sup>1</sup> In view of the success of this system for persons with tetraplegia, it is reasonable to apply this evolving technology to persons with hemiparesis following stroke.

In 1973, Rebersek and Vodovnik<sup>2</sup> demonstrated that a transcutaneous hand neuroprosthesis system could open and close the hemiparetic hand under volitional control. With training, participants demonstrated progressive improvements in the number of plugs and baskets they could manipulate with the device. In 1975, Merletti and associates<sup>3</sup> used a similar system to demonstrate that stroke survivors can use a transcutaneous hand neuroprosthesis system to manipulate small plastic baskets and bottles.

However, since these early studies, there have been few additional reports on the development of hand neuroprosthesis systems for stroke survivors. Cameron and associates<sup>4</sup> demonstrated the effectiveness of transcutaneous NMES in opening a resting hemiparetic hand. Cyclic transcutaneous NMES with or without an orthosis has also been shown to facilitate motor recovery of stroke survivors.<sup>5,6</sup> However, the ability of these systems to provide direct hand function has not been demonstrated. Furthermore, earlier work in our laboratory demonstrated that transcutaneous NMES is not effective in opening a spastic hemiparetic hand if the participant attempts to assist the stimulation or if the stimulation is applied immediately after voluntary hand closure. Similarly, Lin demonstrated the varying nature of hypertonia as a function of movement of the ipsilateral and contralateral upper limb and the need for varying the stimulation intensity to adequately open the spastic hemiparetic hand.<sup>7</sup>

In view of the recent success of an implanted neuroprosthesis system for persons with tetraplegia and the inconsistent experience reported in the literature with transcutaneous neuroprosthesis systems among stroke survivors, we elected to further explore the feasibility of a hand neuroprosthesis

From the Center for Physical Medicine and Rehabilitation and Department of Biomedical Engineering (JC), Case Western Reserve University; Departments of Physical Medicine and Rehabilitation (JC), MetroHealth Medical Center, Cleveland Functional Electrical Stimulation Center (JC, RH), Louis Stokes Cleveland Veterans Affairs Medical Center (RH), Cleveland OH.

Address correspondence to John Chae, MD, ME, Assistant Professor of Physical Medicine and Rehabilitation, Assistant Professor of Biomedical Engineering, Case Western Reserve University, MetroHealth Medical Center, 2500 MetroHealth Drive, Cleveland, OH 44109. E-mail: jchae@metrohealth.org.

Chae J, Hart R. Intramuscular Hand Neuroprosthesis for Chronic Stroke Survivors. *Neurorehabil Neural Repair* 2003;17:109–117.

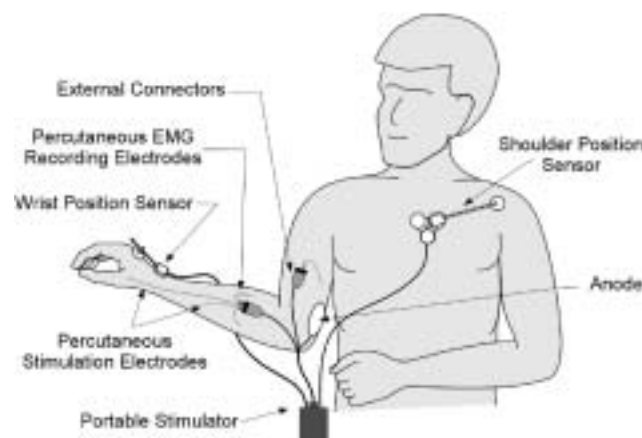
DOI: 10.1177/0888439003254402

system for persons with hemiparesis. NMES may be able to address the “negative signs” of central nervous system motor dysfunction such as weakness, fatigue, and delay in initiation of muscle contraction. However, it cannot address the “positive” signs such as delay in termination of muscle contraction, co-contractions of agonist and antagonist muscles, co-activation of synergistic muscles, and spasticity. These positive signs may be exacerbated by the cutaneous noxious stimuli of transcutaneous NMES. We elected to evaluate a percutaneously placed intramuscular system to decrease the level of discomfort associated with transcutaneous NMES.<sup>8,9</sup> In addition, intramuscular NMES addresses several inherent limitations of transcutaneous systems. These include the labor-intensive nature of placing and removing electrodes (especially when multiple electrodes are required), poor reproducibility and muscle selectivity of stimulation, and poor access to deeper muscles. Thus, Merletti and associates<sup>3</sup> suggested that an implanted system would best meet the clinical needs of persons with hemiplegia. However, prior to developing and implementing a fully implantable system in hemiparesis, feasibility should be demonstrated with a reversible system. A percutaneous system that allows intramuscular stimulation meets this condition of reversibility. Thus, the specific aims of this exploratory study were to 1) demonstrate the adequacy of percutaneous stimulation for opening and closing a hemiparetic hand, 2) identify control strategies that reliably open and close the hand under participant control, and 3) demonstrate functional efficacy.

## METHOD

Four stroke survivors were recruited to participate. Inclusion criteria included age 18 years or older, medical stability, intact cognition, 5 months or greater from last stroke, and ability to follow 3 stage commands. In addition, participants must have sufficient control of the paretic shoulder and elbow to functionally position the hand. However, active finger extension was absent. The study protocol was reviewed and approved by the study institution's human subjects committee, and all participants signed informed consent.

Each participant received multiple percutaneous intramuscular electrodes in the paretic muscles of the upper extremity to provide functional hand grasp and release. The specific muscles for implantation varied depending on the neurological status



**Figure 1.** A percutaneous hand neuroprosthesis system for hemiplegia. All 3 control options of shoulder transducer, wrist joint angle transducer, and EMG controller are illustrated. However, only 1 control method is used at any one time.

of each participant. The electrode, stimulator, stimulation parameters, and implant procedure have been described previously.<sup>8</sup> One week after implantation, each electrode was tested by stimulating the implanted muscle. The stimulation of the various hand and forearm muscles was then synthesized to create a functional grasp and release.<sup>10,11</sup> Functional grasp or hand closure was defined as generation of sufficient grasp strength to hold simple objects such as a utensil or a soda can. Functional release or hand opening was defined as sufficient activation of the finger extensors to produce adequate clearance of the finger tips to place a simple object in the hand or to release an object after hand closure. In all cases, the stimulation provided hand opening. Hand closing was provided by volitional activation of the finger flexors in 2 participants and via electrical stimulation in 2 participants. The investigator controlled the stimulation intensity with a potentiometer or the participant controlled the stimulation via 3 methods, which included shoulder position transducer, wrist angle transducer, and EMG controller. The percutaneous system with these 3 options for control by the user is shown in Figure 1. Only one of the 3 control methods would be used at any one time. Detailed descriptions of these strategies have been previously described.<sup>12</sup>

Demographic characteristics of each participant are shown in Table 1. The specific muscles implanted, the number of electrodes, duration of implantation, and control strategies used for each participant are shown in Table 2. All participants received electrically stimulated conditioning exer-

**Table 1.** Demographic Characteristics of Participants

Participant	Age (years)	Gender	Stroke Type	Stroke Level	Side <sup>a</sup>	Etiology	Onset (mo) <sup>b</sup>	Fugl-Meyer	Volitional Finger Flexion
1	54	Male	NH	Cortical	Left	Carotid dissection	9.0	23	No
2	39	Male	NH	Cortical	Left	Thrombotic	6.5	35	Yes
3	41	Male	NH	Cortical and bilateral cerebellar	Right	Thrombotic	24.0	23	Yes
4	70	Male	NH	Cortical	Left	Thrombotic	5.0	—	Yes

NH = nonhemorrhagic. Dash indicates not obtained.

a. Side of hemiparesis.

b. Stroke onset to study entry.

**Table 2.** Specific Muscles Implanted, Number of Electrodes Implanted, Duration of Implantation, Control Paradigms Used, and Number of Electrodes that Fractured during Removal for Each Participant

Participant	Muscles Implanted <sup>a</sup>	Number of Electrodes	Duration of Implantation of Electrodes (months)	Control Methods	Number of Electrode Fracture <sup>b</sup>
1	EDC, EIP, EPL, APB, 2nd and 3rd DI, FDS <sup>c</sup>	20	17.5	Potentiometer; shoulder transducer; EMG controller	4
2	EDC, 2nd and 3rd DI, FDS <sup>c</sup>	7	17.0	Potentiometer; controller; shoulder transducer; wrist EMG controller	7
3	EPL, EIP, EDC, ECR, <sup>c</sup> FDS <sup>c</sup>	10	13.7	Potentiometer; shoulder transducer; EMG controller	8
4	EDC, ECR, EPL, FDS	7	7.0	Potentiometer	d

a. EDC = extensor digitorum communis; EIP = extensor indicis proprius; EPL = extensor pollicis longus; APB = abductor pollicis brevis; DI = dorsal interosseous; FDS = flexor digitorum superficialis; ECR = extensor carpi radialis.

b. Number of electrodes fractured during removal.

c. These muscles were implanted to monitor EMG signal for the EMG controller and not for muscle stimulation.

d. Participant removed the electrodes himself during a seizure episode and they were discarded prior to examination by the investigators.

cises of the implanted muscles for at least 1 h/day during the study period. The upper extremity component of the Fugl-Meyer Motor Assessment, a valid and reliable measure of poststroke motor impairment,<sup>13,14</sup> was administered to 3 of 4 participants at baseline prior to implantation. Resistance to passive range of motion (ROM) with extension of the metacarpophalangeal (MCP) joint was also assessed at baseline using the modified Ashworth Scale (MAS).<sup>15</sup> When participants reported improvement in arm function without the electrical stimulation, follow-up Fugl-Meyers were administered.

### Case 1

Participant 1 moved his hemiparetic upper extremity in flexor and extensor synergy patterns, predominantly in the proximal limb with minimal distal movement. He scored a 23 out of possible 66 on the Fugl-Meyer Motor Assessment at baseline. He

exhibited full passive ROM at the MCP, proximal interphalangeal (PIP) and distal interphalangeal (DIP) joints. However, significant finger flexors hypertonia graded as a 3 on the MAS was noted at the MCP joint. Clonus was also noted at the MCP joint.

The stimulator was programmed to provide lateral and palmar grasps. In the open phase of lateral grasp, the finger and thumb were extended. The fingers were fully flexed at all joints while the thumb remained extended. The thumb was then flexed against the lateral aspect of the index finger to produce a grasp. In the open phase of palmar grasp, the fingers were extended and the thumb was posted in full abduction. The fingers then flexed against the thumb, ideally resulting in contact between the tip of the thumb and the tips of the index and long fingers. Lateral and palmar grasps were achieved through electrical stimulation but only when the upper limb was in a resting position, both wrist and proximal forearm were supported, the participant did not try to assist the

stimulation, and the investigator controlled the stimulation. The stimulation opened the hand to receive a simple utensil and closed the hand using the lateral grasp pattern to hold the utensil. Similarly, the stimulation opened the hand to receive a soda can and closed the hand using the palmar grasp pattern to hold the can. However, when the participant tried to perform these tasks without the proximal support, when he tried to assist the stimulation, or when the stimulation was controlled by the participant using a shoulder transducer on the contralateral limb, marked clonus of the finger flexors and tremor of the fingers, wrist, and forearm prevented functional use of the system. Specifically, the clonus prevented sufficient opening of the hand to receive the utensil, or the can and the tremor prevented controlled positioning of the hand. Trials of dantrolene sodium and baclofen were discontinued due to significant cognitive side effects. A temporary motor point block of the flexor digitorum superficialis (FDS) and profundus (FDP) with lidocaine hydrochloride decreased resting hypertonia but failed to yield any significant reduction in clonus or tremor during attempts at using the system. Attempts at controlling hand function by using the EMG signal from the FDS were unsuccessful as the participant was unable to sustain his EMG signal. There was no detectable EMG signal from the extensor digitorum communis (EDC).

The subject participated in the study for a period of 17.5 months. During the study period, he reported significant improvement in the awareness of his hemiparetic arm and its use for gross assist. Increased mobility of the shoulder and elbow were also reported. Ten months after initial implantation, the Fugl-Meyer score was 35, an increase of 12 points relative to baseline. However, all of the improvements occurred in the proximal portion of the measure.

During the study period, there were no episodes of electrode-related skin infections. All electrodes were removed by gently pulling on the electrodes until they loosened from the soft tissue. The distal portion of 4 of 20 electrodes fractured during removal. There has been no evidence of infection or granuloma formation associated with the retained fragments during the 5 years of follow-up.

## Case 2

Participant 2 exhibited isolated movements of his shoulder and elbow with wrist extension and fin-

ger flexion in synergy. There was no volitional finger extension. Although he was able to volitionally flex and extend his elbow with full ROM, he exhibited marked flexor and extensor hypertonia graded as a 4 on the MAS. He exhibited full passive ROM at MCP, PIP, and DIP joints. However, marked finger flexor hypertonia graded as a 3 on the MAS was noted with MCP extension. The patient was being treated with baclofen at study entry with marginal success. His upper extremity Fugl-Meyer score was 35 out of possible 66 prior to implantation.

Six weeks after implantation, the participant experienced a grand mal seizure, which was initially treated with phenytoin and subsequently changed to carbamazepine. The participant was not using the stimulator when the seizure occurred. Baclofen was discontinued and tizanidine was started. However, no significant change in hypertonia was noted. The participant subsequently discontinued the tizanidine due to cognitive side effects. The participant continued to have brief episodes of focal seizures once or twice a year, even after completion of the study.

If investigators controlled the stimulation, the participant did not try to assist the electrical stimulation, and the wrist was flexed, adequate hand opening could be achieved. However, when the participant extended his elbow to reach for an object, increased finger flexion hypertonia significantly reduced hand opening, even with increased stimulation intensity. Similarly, stimulation-induced functional hand opening was significantly reduced after volitional hand closure due to increased finger flexion hypertonia, which prevented placement of simple objects in the hand. When the hand was sufficiently opened, the participant was able to pick up small objects with volitional finger flexion. However, attempts at opening the hand with the electrical stimulation to release the object with a shoulder transducer on the contralateral shoulder was ineffective due to marked finger flexion tone associated with effort. Use of a wrist controller, which stimulated EDC and 2nd and 3rd dorsal interossei with volitional wrist flexion and terminated stimulation with volitional wrist extension was also ineffective. The participant was able to initiate hand opening by flexing his wrist. However, as the EDC was activated, the participant was unable to maintain wrist flexion and finger extension due to the extensor moment of the EDC on the wrist. After volitional finger closure with wrist extension in synergy, the participant was unable to flex the wrist adequately to activate finger extension due to wrist extensor hypertonia.

Even when the wrist extensor tone was overcome, the residual finger flexor tone severely limited electrically stimulated hand opening. A similar phenomenon was noted with an EMG controller using EMG signals from the FDS. Treatment of the hypertonia with botulinum toxin A reduced finger flexion tone to decrease the clonus. However, the participant no longer had sufficient control of hand closure to use the system functionally.

The subject participated in the study for a period of 17 months. He reported improvements in the overall mobility of shoulder and elbow with increased use of the hemiparetic upper limb. He reported initiation of bimanual tasks by placing objects in his paretic hand and volitionally keeping the hand closed. Five months into the protocol, the Fugl-Meyer score improved to 44, an increase of 9 points relative to baseline. Improvements were all seen in the proximal limb.

During the study period, there was 1 superficial infection at 3 months' post-implantation. Examination revealed macerated skin surrounding the electrode exit sites with purulent discharge. Furthermore, the plastic connector was found on top of the electrode exit sites instead of away from them. The participant failed to follow instruction and did not check or clean his electrode site for an entire 1-week period. The participant was treated with topical and oral antibiotics with good resolution. The distal tips of all 7 electrodes fractured during removal at the end of the study. There has been no evidence of infection or granuloma formation associated with the retained fragments during the 3.4 years of follow-up.

### Case 3

Participant 3 exhibited elbow flexion and extension in synergy patterns only. There was no volitional finger extension. The fingers could be passively opened to full range but with significant finger flexion tone graded as a 3 on the MAS at the MCP joint. Initial upper-extremity Fugl-Meyer score was 23. Electrically stimulated hand opening was achieved when the investigator controlled the stimulation, the upper limb was in a resting position, the participant did not try to assist the electrical stimulation, and the wrist and proximal limb were supported. However, the participant was unable to open the hand using a shoulder transducer on either shoulder due to inadequate shoulder control and triggering of finger flexion hypertonia. EMG-controlled hand opening was also ineffective

because the participant could not terminate his EMG signals from the extensor carpi radialis or FDS. Even with the investigator controlling the stimulation, hand opening following voluntary closure or during attempts at specific tasks was not achieved due to increased finger flexor tone.

The subject participated in the study for 13.7 months. He reported no improvements in the use of his paretic upper limb, including the proximal segments. No additional Fugl-Meyer scores were obtained. There were no episodes of skin infections during the study period. The distal tips of 8 of 10 electrodes fractured during removal at the end of the study period. After 1 year of follow-up, 1 granuloma was palpable on examination of the mid dorsal forearm. After 2.8 years of follow-up, the same granuloma was noted to have migrated toward the skin with resultant erythema and tenderness to palpation. The electrode fragment was removed in a minor outpatient procedure under local anesthesia without complications. At the time of the procedure, additional granulomas were palpable, but there was no evidence of erythema or tenderness warranting additional interventions.

### Case 4

Participant 4 exhibited left upper extremity movement in a synergy pattern with proximal movement being greater than distal. Weak finger flexion was in a synergy pattern. There was no finger extension. The participant exhibited full passive ROM of the fingers but with significant finger flexion tone at the MCP graded as a 3 on the MAS. The electrical stimulation opened the hand fully as long as the investigator controlled the stimulus intensity, the limb was in a resting position, the participant made no effort to assist the electrical stimulation, and the wrist and proximal forearm were supported. As with other participants, electrical stimulation was significantly less effective in opening the hand during attempts at functional tasks and after volitional hand closure due to increased finger flexion tone. Control methods were not assessed.

There were no episodes of skin infection during the study period. The participant reported no improvements in the use of the hemiparetic limb. No additional Fugl-Meyer scores were obtained. Seven months after implantation, the participant experienced a grand mal seizure associated with a new right hemisphere infarct. The participant did not use the stimulator on the day of or on the day prior to the new stroke and seizure. The participant

removed all the electrodes during the seizure episode. The electrodes were discarded prior to examination by the investigators. Thus, it was not possible to determine whether the distal tips were intact. The participant experienced marked deterioration in cognition and was disenrolled from the study. He was subsequently lost to follow-up.

## DISCUSSION

These case reports describe the first 4 chronic stroke survivors implanted with a percutaneous hand neuroprosthesis system. Intramuscular stimulation was effective in opening and closing the hemiparetic hand as long as the involved limb was in a resting position, the wrist and proximal forearm were supported, the participant did not assist the stimulation, and an individual other than the participant modulated the stimulation intensity. However, when participants attempted to use the system in a functional manner or they tried to assist the stimulation, marked hypertonia with or without clonus predominated, which prevented completion of the targeted task. The control strategies evaluated in this report were inadequate. Shoulder transducer control was ineffective due to inadequate proximal control in both shoulders. Wrist position transducer control was ineffective due to weak wrist flexion, which could not counter the wrist extension moment from the electrically stimulated EDC. EMG controller was ineffective due to the participants' inability to control their EMG signals in the paretic muscles. In view of these limitations, functional ability was not formally evaluated.

An earlier report from our laboratory demonstrated that whereas transcutaneous NMES can open a spastic hemiparetic hand while it was in a resting state, this was not the case if the participant tried to assist the stimulation or if the participant voluntarily closed the hand just prior to the stimulation. These observations were attributed to increased finger flexor tone associated with effort and the participant's inability to terminate muscle activity in a timely manner. We pursued the present study based on the possibility that the discomfort associated with transcutaneous NMES exacerbated the hypertonia and that standard clinical interventions would be effective in reducing the hypertonia. Specifically, because intramuscular NMES is significantly less painful than transcutaneous NMES, we hypothesized that intramuscular NMES would be associated with less finger flexor hypertonia. In addition, we hypothesized that standard

oral antispasticity and focal neurolytic techniques would be effective in further reducing the finger flexor hypertonia. However, the persistence of significant finger flexor hypertonia during intramuscular NMES suggests that noxious stimuli of transcutaneous NMES is not an important exacerbating factor in the genesis of marked hypertonia during transcutaneous NMES. We also found that available oral antispasticity medication and focal neurolytic techniques are inadequate in reducing finger flexor hypertonia in the present experimental context.

The major barrier to the present investigation was the dominant role of "positive" signs of central nervous system injury, which decreased electrically stimulated hand opening. Previous studies have demonstrated that in addition to the usual "negative" signs of central nervous system, many stroke survivors exhibit spasticity, delay in termination of EMG activity,<sup>16</sup> abnormal co-contraction of agonist and antagonist muscles,<sup>17</sup> and abnormal co-activation of synergistic muscles.<sup>18</sup> We previously demonstrated that these abnormalities in the hemiparetic upper limb correlate highly with clinical measures of upper limb motor impairment and physical disability.<sup>19,20</sup> Although the presence of these "positive" signs and their clinical implications have been well documented, pathophysiologic mechanisms and explanations for their increased prominence with voluntary activity remain uncertain. Neurophysiologic studies have shown higher F wave amplitudes, more persistent F waves, and higher H wave–M wave amplitude ratios in spastic muscles suggesting increased alpha motoneuron excitability.<sup>21</sup> Some have described positive signs as "release phenomenon" attributed to loss of supraspinal inhibitory influences on normal interneuronal pool.<sup>22</sup> Increased and decreased Renshaw's inhibition have also been implicated.<sup>21</sup> However, a reduction in corticospinal input may also result in increased dependence in undamaged vestibulospinal, reticulospinal, and tectospinal pathways.<sup>18,23,24</sup> These brainstem pathways exhibit extensive branching, innervating neurons over many spinal segments, which may induce abnormal activation patterns. Cortical reorganization may also induce redistribution of cortical pathways to spinal segmental circuits leading to more unfocused descending inputs.<sup>25</sup> Whether any or all of these mechanisms are responsible for the positive signs observed in this study remains to be elucidated.

Two of our participants experienced some motor-relearning effect during the study period. Motor relearning is defined as the reacquisition of

motor skills lost after central nervous system injury. Whether this apparent improvement was a direct result of the electrical stimulation or some other factor such as natural recovery cannot be determined from the present study. Nevertheless, previous studies have suggested that NMES-mediated active repetitive movement therapy has a significant motor-relearning effect among stroke survivors.<sup>5</sup> We have not observed this phenomenon among spinal cord patients who use a hand neuroprosthesis system on a regular basis. Thus, in the implementation of NMES for stroke survivors, it remains unclear as to when motor relearning ends and when neuroprosthetic needs begin. The application of NMES for motor relearning will require temporary systems such as transcutaneous or percutaneous intramuscular systems. The activity will be in an exercise mode in which muscles are stimulated in a cyclic manner. Therefore, because the activity itself is not functional, the control paradigm does not need to be sophisticated. However, neuroprosthesis systems will be used chronically and will need to be fully implanted with sophisticated control systems that allow users to perform functional tasks.

Although 2 participants may have experienced some motor-relearning effect during the study, all participants were too severely impaired to benefit from any neuroprosthetic effect. The present system is likely more appropriate for a small but select group of stroke survivors who have minimal hand function but have excellent control of the shoulder, elbow, and wrist with minimal hypertonia. A second-generation hand neuroprosthesis,<sup>26</sup> which uses an implantable wrist joint angle transducer or an EMG controller, may be able to provide grasp-and-release function and basic bimanual functional capacity to this population. Experience with such a system in a limited number of participants may provide insight into the design of future systems that will be applicable to the broader stroke population.

The extent to which the scientific, engineering, and medical communities further pursue the development of a hand neuroprosthesis for hemiparesis will depend on its functional and technical goals. Although more complex systems are presently being investigated for tetraplegia, the provision of simple hand opening and closing is still justifiable in the spinal cord population. However, the system for hemiparesis must demonstrate that participants are able to perform bilateral tasks and are able to perform specific tasks faster and more efficiently compared to the usual single-handed approach. The system must have sufficient miniaturization

and robustness to allow mobility for ambulating stroke survivors. The system must provide proximal as well as distal function. In view of the complex nature of motor control in hemiplegia, the system must be able to address the problem of positive signs described earlier. In our experience with spinal cord patients, spasticity is well controlled in most patients with only oral pharmacological agents. Because all our spinal cord participants sustained complete injuries, the phenomena of delay in termination, co-contraction, and co-activation, which are likely mediated by cerebral mechanisms, were not relevant issues. Finally, the control paradigm must allow smooth, relatively effortless, volitionally controlled functional movement of the impaired upper extremity without compromising the function of the intact or nonparalyzed limbs or muscles.

To achieve these functional and technical specifications, future studies must focus on the following. Fundamental studies should be carried out to further elucidate the motor control issues of hemiparesis. Dynamic electromyography studies should be carried out to characterize the hypertonia and motor activation patterns during functional activities. An effective hand neuroprosthesis will be able to turn off unwanted co-contraction and hypertonia as well as turn on weak or plegic muscles during functional activities. Clinically available methods for treating the positive signs of central nervous system injury include oral antispasticity medications; focal neurolytic agents such as phenol, ethanol, and botulinum toxins; and intrathecal baclofen. However, none of these techniques are able to provide real-time modulation as a function of specific activity. An alternative strategy is a blocking nerve electrode,<sup>27,28</sup> which can undergo real-time modulation. Blocking electrodes are presently undergoing development at our center and could be incorporated into future hand neuroprosthesis systems. Surgical options such as tendon lengthening should also be considered to decrease the affects of hypertonia. Closed loop systems that correct the output based on knowledge of the output may also improve performance.<sup>29</sup> Finally, control paradigms, which use cortical signals, should be developed to provide smooth functional activation of paralyzed muscles without encumbering the function of the intact limb.<sup>30</sup>

This investigation used percutaneous intramuscular electrodes as a proxy for a fully implantable system. The primary reason for this approach was the reversible nature of the system. A percutaneous system was chosen over a transcutaneous system

due to the lower level of discomfort during stimulation,<sup>8</sup> greater selectivity of muscle activation, and greater access to deeper muscles. However, percutaneous electrodes also have limitations. In this series, distal tips of 19 of the 37 electrodes available for examination fractured during removal. Potential complications from retained fragments include formation of granulomas, foreign body response to the retained fragment, and infection. In this series, 1 granuloma developed without infection during the follow-up period and was removed. There were no other complications associated with the retained fragments over the average follow-up period of 25 months. One episode of skin infection, which was due to poor participant compliance with skin care of the electrode exit sites, required oral antibiotics. Based on 20 years of experience in our laboratory with persons with spinal cord injury, stroke, and traumatic brain injury, incidents of granuloma formation and electrode infection occurred at a rate of 1 per 5½ years of research subject participations. Incidents that required outpatient surgical treatment occurred at a rate of 1 per 18½ years of research subject participation.

Two of our participants experienced seizures. Participant 2 experienced his seizure 6 weeks after implantation and 8 months after his stroke. Participant 4 experienced his seizure 7 months after initial implantation and in conjunction with a recurrent stroke. In both cases, participants were not using the stimulator when the seizure occurred. Seizures occur in 10% of stroke patients,<sup>31</sup> and the incidence is significantly higher among those with cortical strokes.<sup>32</sup> Thus, seizures in our participants were likely due to their strokes rather than the intervention.

In conclusion, the actual clinical implementation of NMES therapy for stroke survivors is unlikely to occur in isolation from other treatment modalities. If and when an operational hand neuroprosthesis system becomes available for stroke survivors, it will likely be implemented in conjunction with numerous other techniques. One scenario is that once all known noninvasive motor-relearning techniques have been exhausted, a hand neuroprosthesis may be implemented. An alternative scenario is an early implementation of a NMES system as both a motor-relearning tool and a neuroprosthesis. Evolving data on motor system neuroplasticity clearly indicate that motor relearning is activity dependent and that the most appropriate activity is both meaningful and important to the stroke survivor.<sup>33</sup> Although cyclic NMES and other exercise programs provide repetitive movement therapy,

the activity itself is not functional, which may explain why improvements at the level of motor impairment do not necessarily translate to improvements in functional ability.<sup>5</sup> A hand neuroprosthesis system, which allows stroke survivors to perform functional activities in a repetitive manner, may be a very effective motor-relearning tool. Such a system may be implemented in conjunction with novel motor-relearning strategies such as constraint-induced therapy<sup>34</sup> and robotic therapy<sup>35</sup> and also may increase the number of stroke survivors eligible for these techniques.

## ACKNOWLEDGMENT

This work was supported in part by NIH-NICHD grant K12 HD01097-01A1.

## REFERENCES

1. Peckham PH, Keith MW, Kilgore KL, et al. Efficacy of an implanted neuroprosthesis for restoring hand grasp in tetraplegia: a multicenter study. *Arch Phys Med Rehabil* 2001;82:1380-8.
2. Rebersek S, Vodovnik L. Proportionally controlled functional electrical stimulation of hand. *Arch Phys Med Rehabil* 1973;54:378-82.
3. Merletti R, Acimovic R, Grobelnik S, et al. Electrophysiologic orthosis for the upper extremity in hemiplegia: feasibility study. *Arch Phys Med Rehabil* 1975;56:507-13.
4. Cameron T, McDonald K, Anderson L, et al. The effect of wrist angle on electrically evoked hand opening in patients with spastic hemiplegia. *IEEE Trans Rehab Eng* 1999;7:109-11.
5. de Kroon JR, van der Lee JH, IJzerman MJ, et al. Therapeutic electrical stimulation to improve motor control and functional abilities of the upper extremity after stroke: a systematic review. *Clin Rehabil* 2002;16:350-60.
6. Hendricks HT, IJzerman MJ, de Kroon JR, et al. Functional electrical stimulation by means of the "Ness Handmaster Orthosis" in chronic stroke patients: an exploratory study. *Clin Rehabil* 2001;15:217-20.
7. Lin C. The effects of ipsilateral forearm movement and contralateral hand grasp on the spastic hand opened by electrical stimulation. *Neurorehabil Neural Repair* 2000;14:199-205.
8. Chae J, Hart R. Comparison of discomfort associated with surface and percutaneous intramuscular electrical stimulation for persons with chronic hemiplegia. *Am J Phys Med Rehabil* 1998;77:516-22.
9. Yu DT, Chae J, Walker ME, et al. Comparing stimulation-induced pain during percutaneous (intramuscular) and transcutaneous neuromuscular electric stimulation for treating shoulder subluxation in hemiplegia. *Arch Phys Med Rehabil* 2001;82:756-60.
10. Kilgore KL, Peckham PH. Grasp synthesis for upper-extremity FNS. Part 2. Evaluation of the influence of electrode recruitment properties. *Med Biol Eng Comput* 1993;31:615-22.
11. Kilgore KL, Peckham PH. Grasp synthesis for upper-extremity FNS. Part 1. Automated method for synthesizing the stimulus map. *Med Biol Eng Comput* 1993;31:607-14.

12. Hart RL, Kilgore KL, Peckham PH. A comparison between control methods for implanted FES hand-grasp systems. *IEEE Trans Rehabil Eng* 1998;6:208-18.
13. Duncan PW, Propst M, Nelson SG. Reliability of the Fugl-Meyer assessment of sensorimotor recovery following cerebrovascular accident. *Phys Ther* 1983;63:1606-10.
14. Berglund K, Fugl-Meyer AR. Upper extremity function in hemiplegia: a cross-validation study of two assessment methods. *Scand J Rehabil Med* 1986;18:155-7.
15. Gregson JM, Leathley MJ, Moore AP, et al. Reliability of measurements of muscle tone and muscle power in stroke patients. *Age Ageing* 2000;29:223-8.
16. Sahrman SA, Norton BJ. Relationship of voluntary movement to spasticity in upper motor neuron syndrome. *Ann Neurol* 1977;2:460-5.
17. Hammond M, Fitts S, Kraft G, et al. Co-contraction in the hemiparetic forearm: quantitative EMG evaluation. *Arch Phys Med Rehabil* 1988;69:348-51.
18. Dewald JP, Pope PS, Given JD, et al. Abnormal muscle coactivation patterns during isometric torque generation at the elbow and shoulder in hemiparetic participants. *Brain* 1995;118:495-510.
19. Chae J, Yang G, Park BK, et al. Delay in initiation and termination of muscle contraction, motor impairment and physical disability in upper limb hemiparesis. *Muscle Nerve* 2002;25:568-75.
20. Chae J, Yang G, Park BK, et al. Muscle weakness and co-contraction in upper limb hemiparesis: relationship to motor impairment and physical disability. *Neurorehabil Neural Repair* 2002;16:241-8.
21. Delwaide PJ. Human reflex studies for understanding the motor system. *Phys Med Rehabil Clin N Am* 1993;4:669-86.
22. Ghez C. The control of movement. In: Kandal ER, Schwartz JH, Jessell TM, eds. *Principles of neural sciences*. Norwalk, CT: Appleton & Lange; 1991:533-63.
23. Dewald JP, Beer RF, Given JD, et al. Reorganization of flexion reflexes in the upper extremity of hemiparetic participants. *Muscle Nerve* 1999;22:1209-21.
24. Dewald JP, Beer RF. Abnormal joint torque patterns in the paretic upper limb of participants with hemiparesis. *Muscle Nerve* 2001;24:273-83.
25. Kamper DG, Rymer WZ. Impairment of voluntary control of finger motion following stroke: role of inappropriate muscle coactivation. *Muscle Nerve* 2001;24:673-81.
26. Peckham PH, Kilgore KL, Keith MW, et al. An advanced neuroprosthesis for restoration of hand and upper arm control using an implantable controller. *J Hand Surg [Am]* 2002;27:265-76.
27. van den Honert C, Mortimer JT. A technique for collision block of peripheral nerve: frequency dependence. *IEEE Trans Biomed Eng* 1981;28:379-82.
28. van den Honert C, Mortimer JT. A technique for collision block of peripheral nerve: single stimulus analysis. *IEEE Trans Biomed Eng* 1981;28:373-8.
29. Crago PE, Mortimer JT, Peckham PH. Closed-loop control of force during electrical stimulation of muscle. *IEEE Trans Biomed Eng* 1980;27:306-12.
30. Lauer RT, Peckham PH, Kilgore KL. EEG-based control of a hand grasp neuroprosthesis. *Neuroreport* 1999;10:1767-71.
31. Wiebe-Velazquez S, Blume WT. Seizures. *Physical Medicine and Rehabilitation: State of the Art Review* 1993;7:73-88.
32. Richardson EP, Dodge PR. Epilepsy in cerebral vascular disease. *Epilepsia* 1954;3:49-74.
33. Nudo RJ, Plautz EJ, Frost SB. Role of adaptive plasticity in recovery of function after damage to motor cortex. *Muscle Nerve* 2001;24:1000-19.
34. Liepert J, Bauder H, Wolfgang HR, et al. Treatment-induced cortical reorganization after stroke in humans. *Stroke* 2000;31:1210-6.
35. Volpe BT, Krebs HI, Hogan N, et al. A novel approach to stroke rehabilitation: robot-aided sensorimotor stimulation. *Neurology* 2000;54:1938-44.