

# Survival from accidental strangulation from a scarf resulting in laryngeal rupture and carotid artery stenosis: the “Isadora Duncan syndrome”. A case report and review of literature

P A Gowens, R J Davenport, J Kerr, R J Sanderson, A K Marsden

*Emerg Med J* 2003;20:391–393

In 1929 the dancer Isadora Duncan died from strangulation and carotid artery insult when her scarf caught in the wheels of a motor vehicle in which she was travelling. As part of the Edinburgh Festival scene, cycle propelled rickshaws are in popular use as short range taxis. The case is presented of a student who sustained a laryngeal rupture from strangulation with a scarf in the same way as Isadora. Despite an out of hospital cardiorespiratory arrest, severe laryngeal trauma, and carotid artery damage resulting in hemiparesis, the patient was successfully resuscitated and recovered with no neurological deficit. It is believed that this is the first recorded survival from this condition.

In the early hours of a June morning in 2001, an ambulance was dispatched to a suspected case of “choking” in a main Edinburgh street. On arrival six minutes later a 21 year old woman was found lying in the recovery position, apparently strangled from her scarf, which had become caught in the wheels of a cycle powered rickshaw. Bystanders had loosened the ligature (scarf) with difficulty but no other first aid measures had been undertaken.

Initial assessment was extremely difficult. Assessment of the airway was virtually impossible on account of gross oedema of the neck and face and massive surgical emphysema. However, the patient was apnoeic and unresponsive to painful stimuli. The neck oedema made it impossible to palpate the carotid pulses but cardiac arrest was presumed from the absence of the other major pulses. Airway control was achieved by jaw thrust; chin lift with a bystander maintaining c-spine support. The patient was ventilated by bag-valve-mask with supplemental oxygen delivered through a reservoir. Tracheal intubation was not possible, as, during laryngoscopy, the normal laryngeal landmarks could not be visualised.

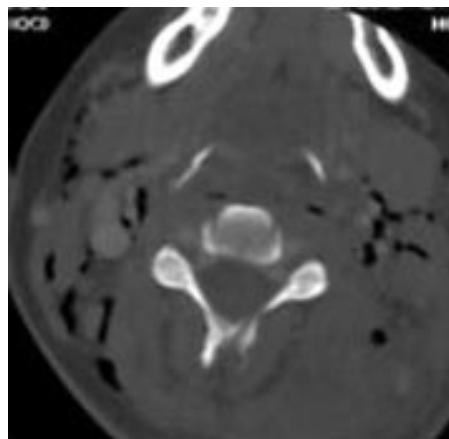
Initial CPR was stopped after a few minutes because, although the pulses remained impalpable, the patient made occasional physical movement and some respiratory effort.

A collar was applied, intravenous access obtained, and the patient was made ready for rapid transport to hospital. Assisted ventilation was continued though there were some irregular spontaneous respirations with marked laryngeal noises heard.

En route to hospital the patient had a seizure followed by a right sided facial weakness.

On arrival at hospital the vital signs were RR18 with stridor, radial pulse rate 104, GCS – E1, M5, V1 and, despite the obvious partial airway obstruction, the initial SPO<sub>2</sub> was recorded as 99%.

There was great difficulty in securing a definitive airway because an attempt at conventional intubation by senior accident and emergency staff and anaesthetic staff failed



**Figure 1** Fractured hyoid bone in accidental strangulation.

because of the gross dissection of the normal laryngeal architecture. These attempts had been supported by the administration of short acting agents, propofol and halothane. Eventually, nearly two hours from onset, a definitive “airway” was obtained by diathermic cricothyroidotomy carried out by a specialist ENT surgeon. The airway was secured with a cuffed tracheostomy tube.

Radiology revealed a hyoid bone fracture consistent with a strangulation injury (fig 1). The cervical spine appeared intact.

With a clinical diagnosis of traumatic carotid artery stenosis, the patient was transferred to the regional neuroscience unit for neurosurgical intensive care. Computed tomography showed no intracranial abnormality. Neither vascular investigation nor therapeutic interventions were required with the hemiparesis resolving spontaneously over the next 12 weeks. The patient was able to be discharged after four months. A full neurological recovery has taken place though the patient has required further re-constructive laryngeal surgery.

## LITERATURE REVIEW

The possibility of death from strangulation by a scarf caught in the wheel spokes of a vehicle was brought to the public’s attention when the world famous dancer Isadora Duncan died on 14 September 1929. The long scarf, which she was wearing, became caught in the wire wheels of her Buggati car, stopping the vehicle. Isadora died at the scene and was later found to have sustained a fractured larynx and carotid artery injury.<sup>1</sup>

Cycle powered rickshaws (fig 2) remain a common form of transport in some parts of India. However, the unprotected spokes of the cycle wheel can trap the long scarf (chunni) worn by Indian women and a number of cases of accidental strangulation have been described—with no recorded



**Figure 2** Cycle powered rickshaw.

survivors.<sup>2,3</sup> Aggarwal from the Department of Forensic Medicine at Delhi has described a number of common features including the persistence of unconsciousness from the outset with death confirmed soon after arrival at hospital.

Closed injury to the larynx most frequently follows blunt injury to the neck with some “classic” presentations including the two wheeled motorist running into an ambush wire or the unguarded tailgate of a lorry. The clinical features of dysphagia, hoarseness, and dyspnoea are related to the gross oedema and/or the distortion of the laryngeal skeleton including fracture of the hyoid and/or dislocation of the arytenoid cartilages.<sup>4</sup> Carotid artery injury, also, usually follows blunt trauma and has been described following karate blows to the neck,<sup>5,6</sup> diving,<sup>7</sup> therapeutic manipulations,<sup>8</sup> and assaults. It occasionally requires endarterectomy with the use of stents.

When the traumatic insult is severe such as in strangulation, which is described here, or in hanging, it is not uncommon for the two injuries to coexist and in some cases, the carotid artery damage is bilateral.<sup>9</sup>

## DISCUSSION

Cycle powered rickshaws have been part of the Edinburgh scene for the past five or six years. Propelled—and patronised—by students they provide a popular “taxi” service along the pedestrianised zones in the capital centre. The occupant sits close to the ground and fairly close to the wire spokes of the rickshaw wheels. Though at first the Edinburgh accident was thought to be a rare unfortunate mishap, similar cases in India have been discovered in the literature and this raises the need for preventative measures to be introduced to avoid further occurrence. Rickshaws now in use in Edinburgh have plastic guards fitted to their wheels (fig 3).

This case raises several important points. The first is the obvious difficulty in diagnosing cardiorespiratory arrest in the presence of cervical oedema<sup>10</sup> obscuring the carotid pulses. Initial indications at the scene (and later at hospital) were of a dismal prognosis. However, the attending ambulance crew, encouraged by occasional movements of the patient and an ECG rhythm that was potentially compatible with cardiac output, made vigorous attempts at resuscitation concentrating on basic airway care, ventilation, and oxygenation. The short response, scene and transit times (a total prehospital time of 16 minutes) ensured that hypoxia did not become established—and the initial SPO<sub>2</sub> of 99% on arrival at hospital was indeed very gratifying.

Secondly, of note was the impossibility of tracheal intubation in this patient even with the assistance of



**Figure 3** Protected spokes on the wheel of a modern recreational rickshaw.

anaesthetic agents. This was attributable to both the anatomical distortion of laryngeal structures and the secondary complication of facial and laryngeal oedema. Although it can be speculated that there was a role for cricothyroidotomy at scene it is noteworthy that even when it came to be performed this procedure was not straightforward and required a specialist approach.

The development of traumatic carotid artery stenosis is a recognised complication of strangulation however it is of interest there are occasions where this can be managed conservatively with spontaneous recovery of the hemiparesis recovered over time.

Finally, it is remarkable that this patient survived at all. We can find no previous recorded evidence of survival from this “syndrome”. The “take home” message from this case must be that rapid intervention using good basic techniques in apparently hopeless cases can still occasionally produce remarkable results.

## ACKNOWLEDGEMENTS

Mr Paul Grant, ambulance technician who assisted in the management of the case. Ms Marianne Smith, librarian at the Royal College of Surgeons for assistance with the literature search. Dr D Patel, consultant radiologist for assistance with the laryngeal imaging.

## Authors' affiliations

**P A Gowens, A K Marsden**, The Scottish Ambulance Service, Edinburgh, UK

**R J Davenport**, Western General Hospital, Edinburgh, UK

**J Kerr, R J Sanderson**, Royal Infirmary of Edinburgh, UK

Conflict of interests: none.

Funding: none.

Correspondence to: Mr P A Gowens, The Scottish Ambulance Service, Tipperlinn Road, Edinburgh EH10 5UU, UK; pgowens@scotamb.co.uk

Accepted for publication 7 August 2002

## REFERENCES

- 1 **Benecke M**. Ungewollte Strangulation durch ein Fahrzeug: Der Tod von Isadora Duncan. *Rechtstmedizin* 1996;**7**:28–9.
- 2 **Kohli A**, Verma S, Agarwal B. Accidental strangulation in a rickshaw. *Forensic Sci Int* 1996;**82**:191–92.
- 3 **Aggarwal NK**, Agarwal BB. Accidental strangulation in a cycle rickshaw. *Med Sci Law* 1998;**38**:263–5.
- 4 **Seed R**. Traumatic injury to the larynx and trachea. *Anaesthesia* 1971;**26**:55.

- 5 **Blumenthal D**, Riggs J, Ortiz O. Carotid artery occlusion following a karate punch to the neck. *Mil Med* 1996;**161**:562-3.
- 6 **Meairs S**, Timpe L, Beyer J, *et al.* Acute aphasia and hemiplegia following karate training. *Lancet* 2000;**356**:40.
- 7 **Hughes P**. Internal carotid artery occlusion following sports diving. *J R Nav Med Serv* 2000;**86**:120-2.
- 8 **Parenti G**, Orlandi G, Bianchini M, *et al.* Vertebral and carotid artery dissection following chiropractic cervical manipulation. *Neurosurg Rev* 1990;**22**:127-9.
- 9 **Maier W**. Diagnostic and therapeutic management of bilateral carotid artery occlusion caused by near-suicidal hanging. *Ann Otol Rhinol Laryngol* 1999;**108**:189-92.
- 10 **Eberle B**, Dick WF, Schneider T, *et al.* Checking the carotid pulse: diagnostic accuracy of first responders in patients with and without a pulse. *Resuscitation* 1996;**33**:107-16.

## Sodium bicarbonate to treat massive $\beta$ blocker overdose

U R Shanker, J Webb, A Kotze

*Emerg Med J* 2003;**20**:393

Sodium bicarbonate is well recognised in the treatment of tricyclic overdose. But its use in the treatment of massive  $\beta$  blocker (propranolol) overdose has not been previously reported.

### CASE REPORT

A 24 year old woman presented to the accident and emergency department with a history of overdose, taking 92 propranolol LA 80 mg, 45 paroxetine 30 mg, and 28 diazepam 5 mg tablets, two hours before admission. NPIS advised us to give activated charcoal every four hours and monitor vital signs closely and if needed intravenous glucagon. Within 30 minutes of arrival however her Glasgow Coma Score deteriorated rapidly and she developed hypotension. Arterial blood gas measurements showed metabolic and lactic acidosis. She rapidly deteriorated and went into cardiorespiratory arrest. She was intubated and standard ALS guidelines were followed. In addition NPIS was contacted and advised the following—(1) 100  $\mu$ l of 8.4% sodium bicarbonate to correct the acidosis, (2) an isoprenaline infusion to increase the heart rate, (3) an adrenaline (epinephrine) infusion to increase the blood pressure, (4) glucagon infusion to bypass the  $\beta$  block and act directly on cyclic GMP<sup>1</sup> (5) intravenous fluids to ensure adequate filling.

Despite this, the patient continued to have intermittent arrests, principally PEA (5 PEA, 1VT, 1VF). The ECG trace showed marked widening of QRS complex. Periods of arrest were getting longer and the interval between them shorter. NPIS were contacted again and advised rapid correction of arterial pH to 7.5. Thus a bolus of 300 ml of 8.4% sodium bicarbonate was given. Cardiac output was restored and the

ECG returned to a narrow complex morphology with sodium of 150 mmol. She was transferred to the intensive care unit and made a full recovery.

Propranolol is the most potent sodium channel blocker among  $\beta$  blockers. Sodium channels play an important part in the development of action potential in the cardiac muscle. Bradycardia caused by  $\beta$  blocker overdose in normal hearts is sodium channel block rather than  $\beta$  block.<sup>2,3</sup> Treating  $\beta$  blocker overdose with low extracellular K<sup>+</sup> and high extracellular Na<sup>+</sup> increased the heart rate and restored the ability to pace thereby reversing the toxicity in isolated rat hearts.<sup>4</sup> Similar experiments have been made with dogs but there are no reports of such treatment reported in humans. This is the first reported case demonstrating the importance of overloading sodium to counteract the block of the channels by  $\beta$  blocker overdose.

### Authors' affiliations

### REFERENCES

- 1 **Smith RC**, Wilkinson J, Hull RL. Glucagon for propranolol overdose. *JAMA* 1985;**254**:2412.
- 2 **Lisenberg FS**, Buimsolm A, Eisenberg ES, *et al.* Seizures and intraventricular conduction defects in propranolol poisoning. *Ann Intern Med* 1979;**91**:860-2.
- 3 **Paul F**, Kolecki PF, Curry SC. Poisoning by Na channel blocking agents. *Crit Care Clin* 1997;**13**:829-48.
- 4 **Kerns W**, Ransom A, Tomaszewski C, *et al.* The effects of extracellular ions on beta blocker cardiotoxicity. *Toxicol Appl Pharmacol* 1996;**37**:P1-7.
- 5 **Critchley JA**, Lengar A. The management of acute poisoning due to beta adrenoreceptor antagonist. *Med Toxicol* 1989;**4**:32-45.