

Case Report

Multiple deep-seated cavernomas in the third ventricle, hypothalamus and thalamus

C.-H. Wang, S.-M. Lin, Y. Chen, and S.-H. Tseng

Department of Surgery, National Taiwan University Hospital and National Taiwan University College of Medicine, Taipei, Taiwan

Published online June 11, 2003
© Springer-Verlag 2003

Summary

Background. Cavernomas are rarely located in the third ventricle, hypothalamus, or thalamus. In this report, we present our experience managing a patient with three cavernomas, one each in the floor of the third ventricle, hypothalamus, and left thalamus.

Case presentation. This 62-year-old woman had had an unsteady gait and weakness of both legs for six months. Magnetic resonance imaging (MRI) revealed multiple intracranial tumours in the third ventricle, hypothalamus, and left thalamus. The third ventricle tumour was found to be a cavernoma by intra-operative endoscopic examination and then was excised via a transcortical, transventricular approach. Pathology revealed a cavernoma. The other two tumours were assumed to be cavernomas because of their MRI features. Three days after surgery, the patient developed right hemiparesis and disturbance of consciousness. Computed tomography revealed a left thalamic haemorrhage. After conservative treatment, her conscious level gradually recovered and she could walk with support seven months after surgery.

Interpretation. Our experience with this rare case of multiple, deep-seated cavernomas suggests that management of such patients requires specific consideration of the clinical manifestations, location, size, and previous bleeding history.

Keywords: Deep-seated cavernoma; endoscopy; surgery.

Introduction

Cavernomas, or cavernous hemangiomas, are most commonly found in the subcortical hemispheric area, deep cerebral white matter, basal ganglia, brain stem, and cerebellar hemisphere [6]. Rarely they are located in the third ventricle, hypothalamus, or thalamus [4, 5, 11, 14, 15, 17, 18]. We present our experience managing a patient with three cavernomas in the floor of the third ventricle, hypothalamus, and left thalamus.

Case report

A 62-year-old woman had had an unsteady gait and weakness of both legs for six months. The symptoms progressed gradually, without associated headache, vomiting, or blurred vision. On admission, she was well, without any physical abnormality. She was menopausal, with normal pubic and axillary hair. Neurologically, she had clear consciousness with unimpaired mentality. Her memory was intact and her ability to calculate was good. No cranial nerve deficit or sensory impairment was found. Her muscle power was bilaterally normal. The deep tendon reflexes were symmetrical and not increased. Her plantar response was flexor bilaterally. She had a wide-based gait and tended to tilt in any direction when she walked alone. Urinary incontinence was noted occasionally.

The patient's complete blood count, serum biochemistry, and endocrinology profile were normal. Electroencephalography revealed moderate cortical dysfunction with increased cortical irritability of both frontotemporal regions. Computed tomography (CT) demonstrated a mass located in the third ventricle and the ventricular size was enlarged. T1-weighted magnetic resonance imaging (MRI) revealed an iso-intense tumour located in the floor of the third ventricle, and the tumour was well enhanced by gadolinium (Fig. 1A, 1B, 1C). MRI also revealed a linear lesion at the hypothalamus which was considered as a venous malformation (Fig. 1B), and another two tumours located in the right side of the hypothalamus and the left thalamus (Fig. 1A, 1B, 1C). These two tumours showed a mixed-signal, reticulated core surrounded by hypo-intense-signal rims on T2-weighted MRI (Fig. 1C). Dilated third and lateral ventricles were also noted.

Because the clinical manifestations were considered related to the third ventricle tumour and hydrocephalus, the patient underwent endoscopic surgery (Aesculap AG, Tuttlingen, Germany) via a burr hole in the right frontal area. Endoscopic examination revealed a tumour with a mulberry appearance in the third ventricle (Fig. 2A). Therefore, craniotomy was performed to completely resect the third ventricle tumour via a right frontal transcortical-transventricular approach. The tumor was hypervascular and adhered to the floor of the third ventricle. After complete tumour excision, a drainage tube for cerebrospinal fluid (CSF) drainage was inserted. The pathology of the tumour revealed a cavernoma (Fig. 2B).

Postoperatively, the patient recovered well, without any neurological deficits. However, three days after surgery, she became lethargic and a

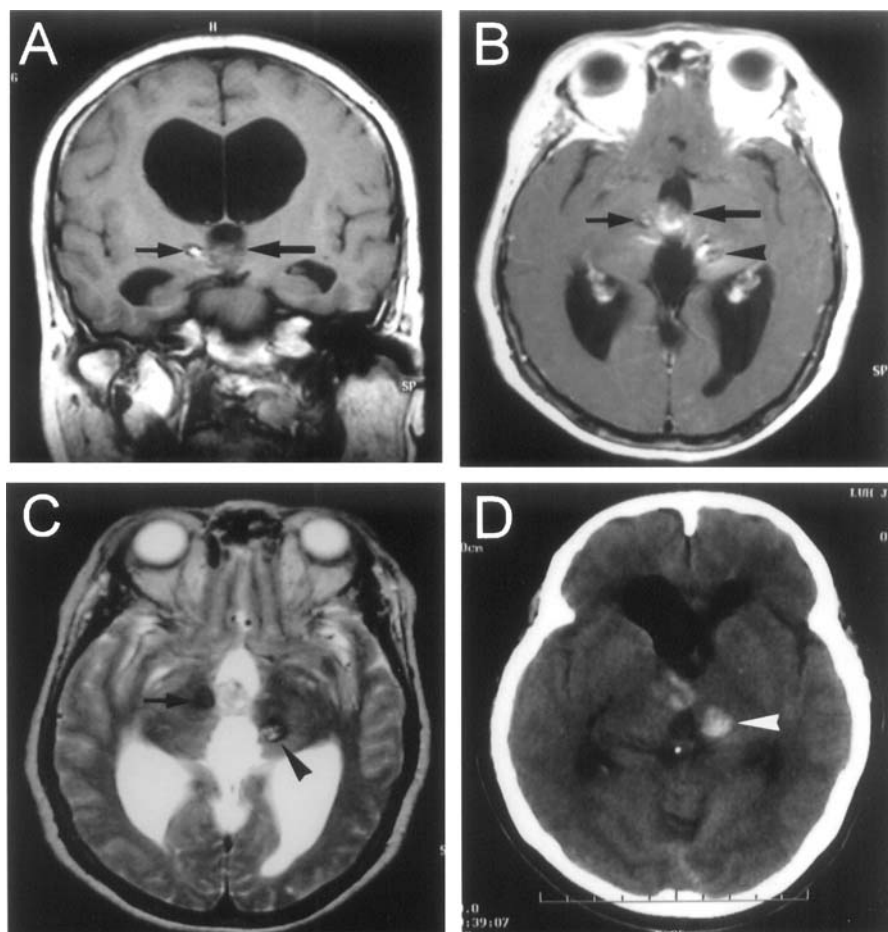


Fig. 1. Magnetic resonance imaging (MRI) of the intracerebral, deep-seated cavernomas. (A) Coronal section of T1 weighted MRI shows an iso-intense tumour located in the third ventricle (large arrow), and a lesion in the right side of the hypothalamus with a hyperintense center surrounded by hypo-intense signal rim (small arrow). The third and lateral ventricles are dilated. (B) Axial section of gadolinium-enhanced T1 weighted MRI reveals enhancement of the third ventricle tumour (large arrow) and another two tumours located in the right side of the hypothalamus (small arrow) and the left thalamus (arrowhead). There is also a linear lesion at the hypothalamus. (C) Axial section of T1 weighted MRI shows two tumours located in the right side of the hypothalamus (small arrow) and the left thalamus (arrowhead). These tumours show mixed-signals, reticulated cores surrounded by hypo-intense-signal rims. (D) Unenhanced computed tomographic imaging 3 days after excision of the third ventricle tumour reveals an intracerebral haematoma in the left thalamus (arrowhead) and a small haematoma within the third ventricle

right hemiparesis (grade 4/5) developed. High blood pressure was noted during that period. CT revealed an intracerebral haemorrhage in the left thalamus, with focal mass effect and a small amount of blood in the third ventricle (Fig. 1D). Osmotic agents and corticosteroids were given. Nonetheless, her neurological status showed no improvement. Four days after the first operation, bloody CSF gushed from the drainage tube accompanied by high blood pressure. Then, her consciousness deteriorated rapidly to semicomatose and the right hemiparesis became worse (grade 2/5). After conservative treatment, the CSF became clear one day later and her condition improved gradually thereafter. Unfortunately, her clinical course was complicated by a central nervous system (CNS) infection. The CSF culture grew gram-positive cocci and enterococci. The CNS infection was well controlled by antibiotics and the CSF drainage tube was then converted to a ventriculoperitoneal shunt. After seven months of follow-up, the patient had clear consciousness with emotional instability. Although she could speak a several-worded sentence, she rarely spoke. She still had mild right hemiparesis; however, she could walk with support. Her daily life was dependent, and her family were reluctant to receive further examination including imaging

studies. Retrospectively, the patient had no family history of intracerebral cavernoma.

Discussion

This patient had three intracranial tumours, and the one in the third ventricle proved to be a cavernoma on pathological examination. The other two tumours were assumed to be cavernomas because of their MRI features, which revealed mixed-signals, reticulated cores surrounded by hypo-intense-signal rim, although there was no surgical or pathological proof that these tumours were cavernomas [8, 19]. Cavernomas rarely occur in any of these three locations, and in the literature, only 24 cases of third ventricle cavernoma and 10 cases of

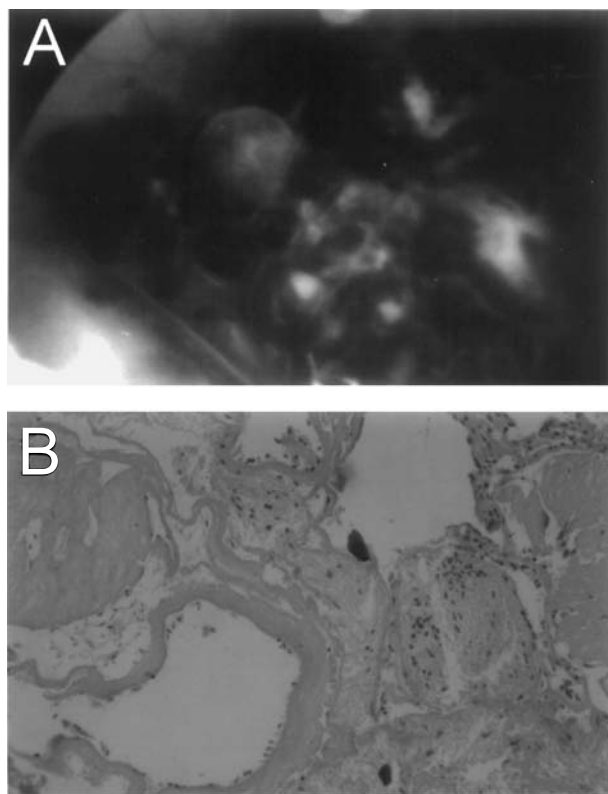


Fig. 2. (A) Operative view through the endoscope shows a tumour with a mulberry appearance in the third ventricle. (B) Pathological section of the tumour reveals a cavernoma with closely packed irregular vascular spaces (H&E, $\times 100$)

hypothalamic cavernoma are reported [4, 5, 7, 11, 14, 15, 17, 18]. Thalamic cavernomas are also rare, although the number of cases reported in the literature is not as small as with third ventricle or hypothalamic cavernomas [1, 2, 10, 12, 16]. Multiple cavernomas may occur in sporadic or familial forms [8]. In our patient, the cavernomas were considered sporadic because she had no family history of these lesions.

The clinical manifestations of intracerebral cavernomas include seizures, mass effect, and extralésional hemorrhage [5, 13, 15]. Our patient showed symptoms of hydrocephalus, which was considered related to the third ventricle tumor. She had no clinical features related to the thalamic and hypothalamic lesions. Therefore, initial management focused on the third ventricle cavernoma and hydrocephalus. Surgical excision is the treatment of choice for third ventricle cavernomas, and several treatment strategies might be considered [5, 14]. For an intraventricular lesion with hydrocephalus, endoscopy could be used for tumor biopsy or resection of a small, poorly vascularized lesion with hydrocephalus, because dilated ventricles allow for manipulation of

the endoscope [3, 17]. Therefore, in our patient, we used endoscopy to check the gross pathology and excise the tumour. However, for a highly vascularized tumor such as a cavernoma [5, 13, 15], endoscopy may not be suitable for tumour resection or biopsy because of difficulty in controlling bleeding during the operation. Thus, we converted the endoscopic procedure to a craniotomy for tumour excision in our patient. A search of the literature revealed two patients with trigonal cavernomas who successfully underwent endoscopic tumour excision, without any difficulty in hemostasis during tumour removal [3]. Thus, an intraventricular cavernoma is not a contraindication for endoscopic surgery, but we emphasize that performing such surgery well requires much experience and practice. When removing third ventricle cavernomas, it is very important to completely resect the tumour, as was done in our patient, because these tumours may have rapid and extensive regrowth after long, stable periods when incompletely removed [9, 18].

Another important issue for our patient was the management strategy for the two cavernomas in the left thalamus and hypothalamus. Surgery for lesions in functionally important areas such as thalamus and hypothalamus is controversial because surgery may cause irreversible neurological insults [8]. Asymptomatic lesions in these areas are usually monitored [4, 5, 8]. The hypothalamic cavernoma in our patient was asymptomatic; thus, we decided to monitor this tumour; however, excision of this lesion together with the third ventricle cavernoma might have been considered at the first operation because they were very close to each other. The left thalamic cavernoma was asymptomatic initially, however, it became symptomatic because the patient had a haemorrhage in the left thalamus, which was probably a spontaneous haemorrhage from the cavernoma or could have been due to relief of pressure by CSF drainage. Because of the clinical significance of this postoperative haemorrhage, we thought surgical excision of this lesion might have been advisable. From another point of view, a treatment option of treating only the hydrocephalus with a ventriculo-peritoneal shunt without excision of the tumours might be used for this patient to avoid the surgical trauma, the postoperative bleeding and infection, and the outcome of this patient might have been better than her current status.

Although long-term follow-up is mandatory before making conclusive comments on treatment strategies for cavernomas in these deep-seated locations; however, from the experience of this patient, we think the management of patients with multiple, deep-seated cavernomas

requires specific consideration of the clinical manifestations, location, size, and previous bleeding history of the patient.

References

- Bertalanffy H, Gilsbach JM, Eggert HR, Seeger W (1991) Microsurgery of deep-seated cavernous angiomas: report of 26 cases. *Acta Neurochir (wien)* 108: 91–99
- Cappabianca P, Spaziante R, de Divitiis E, Villanacci R (1991) Thalamic cavernous malformations. *J Neurosurg* 75: 169–171
- Gaab MR, Schroeder HWA (1998) Neuroendoscopic approach to intraventricular lesions. *J Neurosurg* 88: 496–505
- Hasegawa H, Bitoh S, Koshino K, Obashi J, Kobayashi Y, Kobayashi M, Wakasugi C (1995) Mixed cavernous angioma and glioma (angioglioma) in the hypothalamus: case report. *Neurologia Medico-Chirurgica* 35: 238–242
- Katayama T, Tsubokawa T, Maeda T, Yamamoto T (1994) Surgical management of cavernous malformations of the third ventricle. *J Neurosurg* 80: 64–72
- Kaim A, Kirsch E, Tolnay M, Steinbrich W, Radies EW (1997) Foramen of Monro mass: MRI appearances permit diagnosis of cavernous haemangioma. *Neuroradiology* 39: 265–269
- Mizutani T, Goldberg HI, Kerson LA, Murtagh F (1981) Cavernous hemangioma in the diencephalon. *Arch Neurol* 38: 379–382
- Moriarty JL, Clatterbuck RE, Rigamonti D (1999) The natural history of cavernous malformations. *Neurosurg Clin North Am* 10: 411–417
- Ogawa A, Katakura R, Yoshimoto T (1990) Third ventricle cavernous angioma: report of two cases. *Surg Neurol* 34: 414–420
- Pozzati E, Gaist G, Poppi M, Morrone B, Padovani R (1981) Microsurgical removal of paraventricular cavernous angiomas. *J Neurosurg* 55: 308–311
- Reyns N, Assaker R, Louis E, Lejeune JP (1999) Intraventricular cavernomas: three cases and review of the literature. *Neurosurgery* 44: 648–655
- Roda JM, Alvarez F, Isla A, Blazquez MG (1990) Thalamic cavernous malformation: case report. *J Neurosurg* 72: 647–649
- Simard JM, Garcia-Bengochea F, Ballinger WE, Mickle JP, Quisling RG (1986) Cavernous angioma: a review of 126 collected and 12 new clinical cases. *Neurosurgery* 18: 162–172
- Sinson G, Zager EL, Grossman RI, Gennarelli TA, Flamm ES (1995) Cavernous malformations of the third ventricle. *Neurosurgery* 37: 37–42
- Tatagiba M, Schonmayr R, Samii M (1991) Intraventricular cavernous angioma: a survey. *Acta Neurochir (Wien)* 110: 140–145
- Tew JM, Lewis AI, Reichert KW (1995) Management strategies and surgical techniques for deep-seated supratentorial arteriovenous malformation. *Neurosurgery* 36: 1065–1072
- Veto F, Horvath Z, Doczi T (1997) Biportal endoscopic management of third tumors in patients with occlusive hydrocephalus: technical note. *Neurosurgery* 40: 871–877
- Yamasaki T, Handa H, Yamashita J, Paine JT, Tashiro Y, Uno A, Ishikawa M, Asato R (1986) Intracranial and orbital cavernous angiomas: a review of 30 cases. *J Neurosurg* 64: 197–208
- Zabramski JM, Wascher TM, Spetzler RF, Johnson B, Golfinos J, Drayer BP, Brown B, Rigamonti D, Brown G (1994) The natural history of familial cavernous malformations: results of an ongoing study. *J Neurosurg* 80: 422–432

Comment

The authors describe an interesting case with multiple deep-seated cerebral cavernous angiomas offering the reader an insight into the complexity related to the therapeutic management of such lesions. As most neurosurgeons may only occasionally encounter a cavernoma in the third ventricle, thalamus or hypothalamus due to the rare occurrence in these locations, the general experience with treating such malformations is rather limited. Our knowledge about the optimal treatment in a patient with the simultaneous occurrence of multiple lesions as in the present case is even poorer, and no precise data concerning the natural history of cavernomas in these specific locations are available. Therefore, controversy may exist upon the therapeutic management of this case. Retrospectively, it appears that placement of a ventriculo-peritoneal shunt only, as had been discussed by the authors as well, would probably have been more beneficial to the patient. On the other hand, the bleeding from the left thalamic cavernoma was totally unpredictable and may also have occurred even with such a limited surgical intervention. The cause of this haemorrhage, however, remains unclear. The probable mechanism discussed by the authors (relief of CSF pressure) is speculative, but should focus our attention to similar situations in the future. As for the initial endoscopic procedure, aimed at just establishing the diagnosis of cavernoma, it was not contraindicated, but unnecessary in my opinion. The preoperative imaging was sufficient for this purpose, and removal of the lesion through the endoscopic tube alone would have been too hazardous. Instead, direct surgical removal of all three lesions would have been the primary treatment of choice, to avoid the subsequent haemorrhage. I have no doubt that establishing the indication for just observation, shunt placement, endoscopic or microsurgical procedure, or a combination of these modalities in similar cases will continue to be a matter of case-by-case decision.

Helmut Bertalanffy
Philipps University of Marburg, Germany

Correspondence: Dr. Sheng-Hong Tseng, Department of Surgery, National Taiwan University Hospital, 7 Chung-Shan S. Rd., Taipei 100, Taiwan. e-mail: tsh@ha.mc.ntu.edu.tw