

# Recurrent Arachnoid Cyst of Meckel's Cave Mimicking a Brain Stem Ischaemia. Report of a Rare Case

B. A. Wörner<sup>1</sup>  
M. Noll<sup>1</sup>  
T. Rahim<sup>1</sup>  
U. Fink<sup>2</sup>  
R. Oeckler<sup>1</sup>

*Rezidivierende Arachnoidalzyste im Cavum Meckeli, eine Hirnstammischämie imitierend. Bericht eines seltenen Falles*

## Abstract

A 44-years old man developed TIA-like symptoms with dysaesthesia around the mouth, vertigo and diplopia. MRI revealed a cystic space-occupying lesion on the right Meckel's cave, which spread out into cerebellopontine angle in a further examination. Therefore surgical exploration was performed using a suboccipital approach. An arachnoidal cyst was found and removed including its wall. About three months later the patient suffered again from dysaesthesias of the right side of the face and a new MRI revealed a recurrence of the lesion, with extension into the cerebellopontine angle, too. Surgical revision was done using the same approach and the recurrent cyst was removed. Postoperatively, there were a transient hypaesthesia in the distribution area of the right trigeminal nerve and a light pulmonary embolism occurred as a complication. No symptoms have returned during an observation period of 15 months.

**Conclusion:** An arachnoidal cyst must be considered as a rare cause, when a lesion is found at the Meckel's cave with intermittent clinical symptoms of a trigeminal nerve affection. As surgical treatment we favour fenestration and cyst wall resection.

## Key words

Arachnoidal cysts · Meckel's cave · trigeminal nerve

## Zusammenfassung

Ein 44-jähriger Mann entwickelte TIA-ähnliche Symptome mit perioralen Dysästhesien, Schwindel und Doppelbildern. Kernspintomographisch zeigte sich eine zystische Raumforderung im rechten Cavum Meckeli, die in einer weiteren Untersuchung an Größe zunahm, dann auch mit Ausdehnung in den Kleinhirnbrückenwinkel. Die aufgrund der Größenzunahme durchgeführte operative Freilegung über einen suboccipitalen Zugang ergab eine Arachnoidalzyste, die einschließlich des Zystenbalges entfernt wurde. Etwa drei Monate später traten erneut Dysästhesien auf, diesmal rechts im Gesicht, kernspintomographisch erklärt durch ein Rezidiv der Zyste, wiederum mit Ausdehnung in den Kleinhirnbrückenwinkel. Das Rezidiv wurde über den gleichen Zugang entfernt. Postoperativ bestand eine vorübergehende Hypästhesie im rechten Trigemminusversorgungsgebiet, außerdem trat eine kleinere Lungenembolie als Komplikation auf. Bis zum jetzigen Zeitpunkt bestand im weiteren Beschwerdefreiheit über einen Zeitraum von bisher 15 Monaten.

**Schlussfolgerung:** Eine Arachnoidalzyste sollte differenzialdiagnostisch als seltene Ursache einer Raumforderung im Cavum Meckeli bei intermittierenden Symptomen einer Trigeminafektion erwogen werden. Als operative Therapie bevorzugen wir die Fensterung und Resektion des Zystenbalges.

## Schlüsselwörter

Arachnoidalzyste · Cavum Meckeli · Nervus trigeminus

## Affiliation

<sup>1</sup>Department of Neurosurgery, Klinikum Villingen-Schwenningen, Germany

<sup>2</sup>Institute of Radiology, Villingen-Schwenningen, Germany

## Correspondence

Dr. Bertold Andreas Wörner · Neurochirurgische Klinik · Röntgenstr. 20 · 78054 VS-Schwenningen · Germany · Phone: +49/77 20/93 21-01 · Fax: +49/77 20/93 21-99

## Bibliography

Zentralbl Neurochir 2003; 64: 76–79 © J. A. Barth Verlag in Georg Thieme Verlag KG · ISSN 0044-4251

## Introduction

Arachnoid cysts are common lesions in neurosurgery. Diagnosis has become easier and more frequent with the general use of CT scanner and MRI. First description of this condition was given by Bright 1831 [5]. Most of these lesions are usually accepted to be of congenital origin [7, 12], although up to 15% of them are closely related to a head trauma [6]. One of the existing hypothesis says, that these lesions arise from abnormal CSF flow through the primitive leptomeninges, leading to the formation of a diverticulum within the arachnoid membrane [20]. Bright's description contains a similar concept, which had passed unnoticed for more than one century [5]. But another theory is that of an inflammatory origin [21].

The cysts consist of liquid formations surrounded by an arachnoid sheet and are most commonly located in the middle cranial fossa, other locations being suprasellar and quadrigeminal cisterns, posterior fossa, cerebral convexities, and interhemispheric fissure. Sometimes they can appear multiple [19]. Neurological signs and symptoms are variable depending on their locations. The most frequent symptom is intracranial hypertension, although the cysts are often asymptomatic [7]. Several therapeutic options are described, including endoscopic techniques: direct approach of the cyst and cyst wall excision or fenestration, radical removal or varying shunting procedures [7, 9, 10, 12, 18].

The following report is an unusual case of an arachnoid cyst compressing the trigeminal nerve at Meckel's cave.

## Case report

A 44-year-old man developed a transient dysaesthesia around the mouth for about six hours, vertigo and transient diplopia.

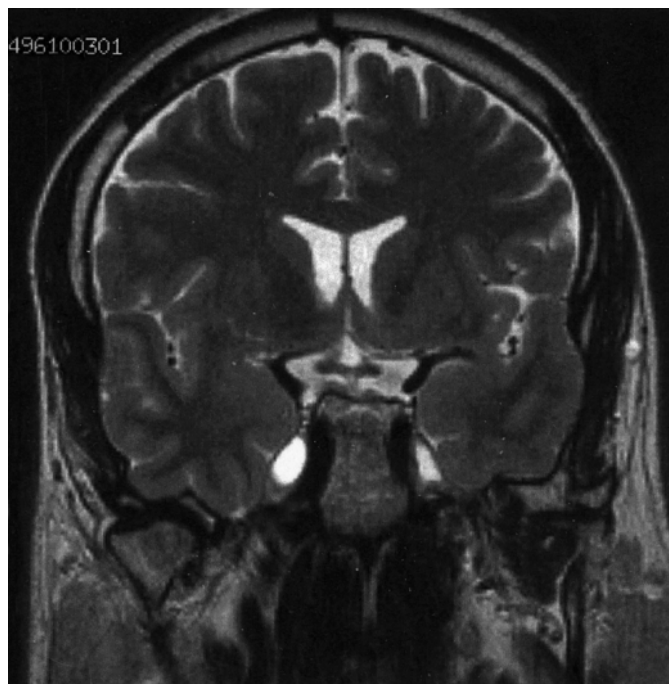

Fig. 1 Arachnoid cyst of Meckel's cave (MRI, T2, Slice-thickness 5 mm).

There was no history of trauma or abnormal birth. There was no neurological deficit either. CCT including CT-angiography were normal. Initially diagnosis of a transient brainstem ischaemia was made, but extensive investigations of the vessels and the heart showed no embolic source. However MRI revealed a small cystic space-occupying lesion in Meckel's cave (Fig. 1), which spread out into the cerebellopontine angle in a further examination five months later (Fig. 2). A cystic trigeminal neuroma or an epidermoid tumour were considered as differential diagnoses. Due to the growth of the lesion, surgical exploration was then performed using a suboccipital retrosigmoid approach. An arachnoid cyst surrounding the trigeminal nerve

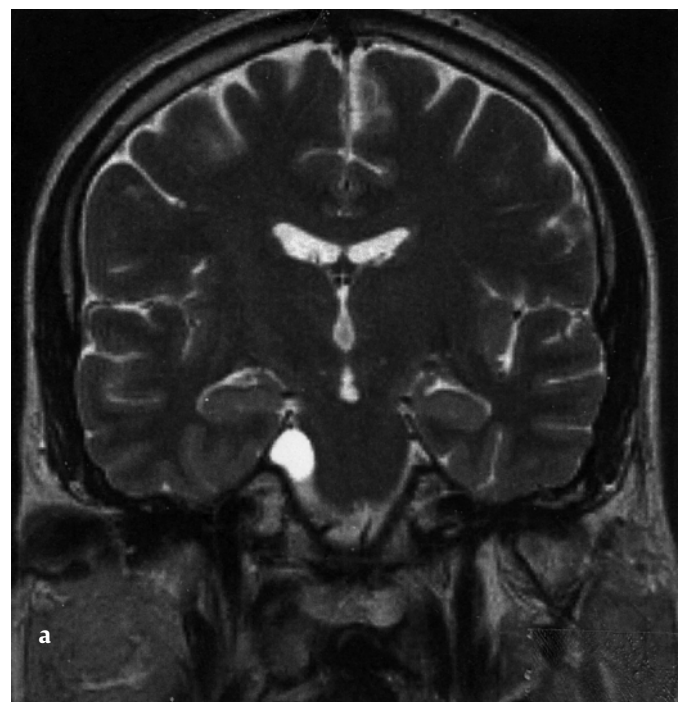
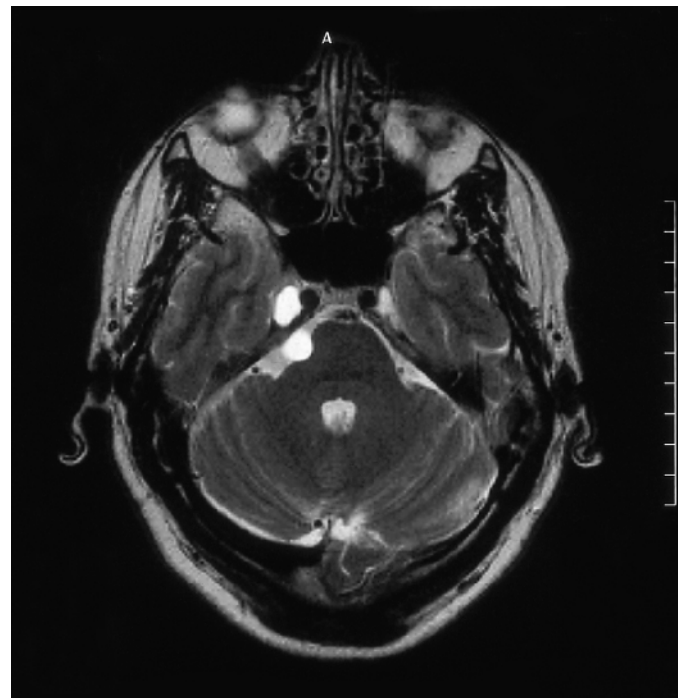


Fig. 2a und b Growing arachnoid cyst after observation (MRI, T2, slice-thickness 5 mm).

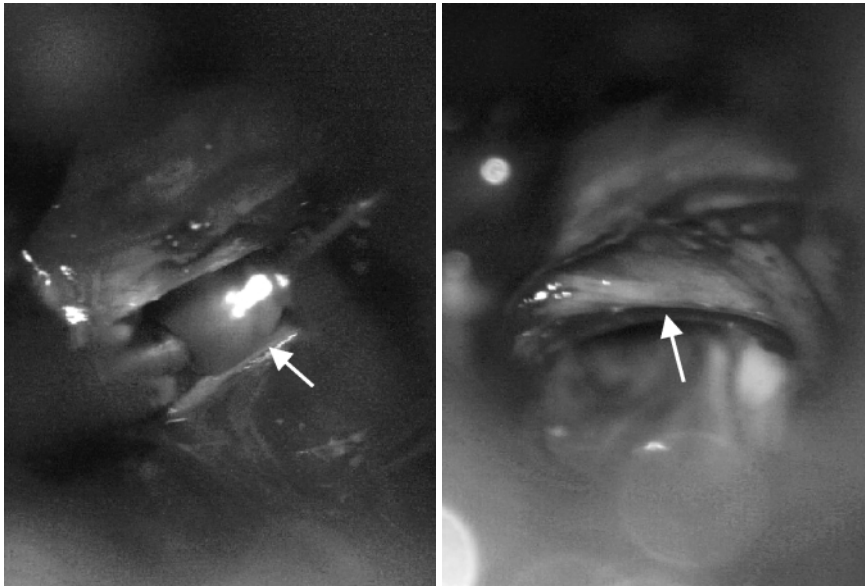


Fig. 3a and b **a** Arachnoid cyst surrounding the trigeminal nerve  
**b** Trigeminal nerve fibres free of compression after cyst wall resection.

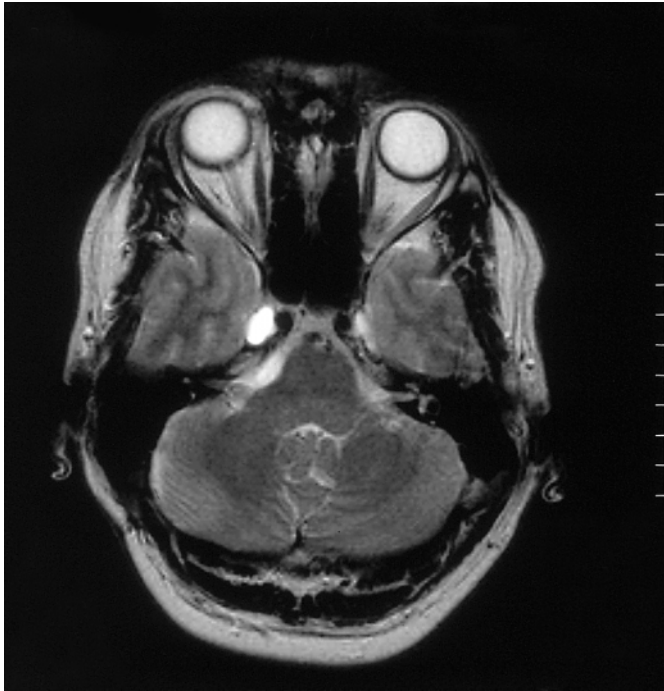


Fig. 4 Recurrence of the arachnoid cyst with extension to cerebellopontine angle (MRI, T2, slice-thickness 5 mm).

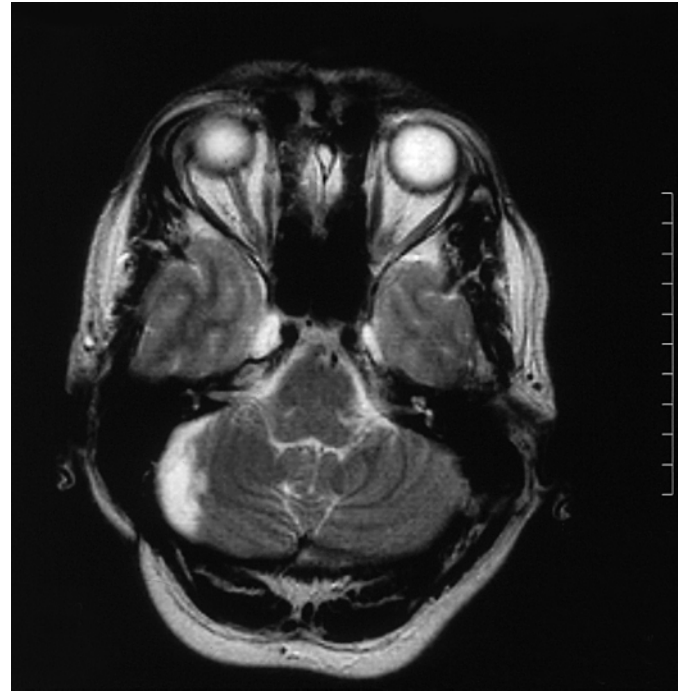

Fig. 5 MRI two months after second surgery (T2, slice-thickness 5 mm).

was found compressing the nerve and pushing it away from the brain stem, the nerve showed evidence of an oedema (Fig. 3a). After fenestration of the cyst and removal of CSF, the cyst collapsed. The cyst wall behind the nerve could then be removed. Following the removal of the cyst the nerve and its surrounding structures showed no more evidence of compression (Fig. 3b). There was no evidence of neoplastic tissue in histological investigation. About three months later the patient suffered from dysaesthesias of the right half of the face and a new MRI revealed a recurrence of the lesion, again spreading into the cerebellopontine angle (Fig. 4). No neurological deficits were found. Surgical revision was performed using the same approach. The trigeminal nerve was swollen and at this time the cyst's posi-

tion was more cranial of the nerve. After the nerve fibres were dissected from the cyst, the cyst wall was more radically removed and furthermore the lateral portion of the arachnoid membrane of the prepontine cistern was removed to achieve a large CSF communication. In histological investigation there was no evidence of neoplastic tissue again. Postoperatively there was a transient hypaesthesia in the distribution area of the right trigeminal nerve and a light pulmonary embolism occurred as a complication. A new MRI made about two months after second surgery revealed the defect in the region of surgery, but no evidence of cyst recurrence was found (Fig. 5). No symptoms have returned so far during an observation period of 15 months.

## Discussion

Most of space occupying lesions in the area of Meckel's cave and the trigeminal nerve are of neoplastic origin [23]. Schwannomas [23], meningiomas [8, 23], lymphomas [1], rarely cancer metastases [15, 16], ganglioneuromas [2], epidermoid tumours [14, 23] and lipomas [23] must be considered as differential diagnoses. MRI is the choice imaging modality, although differential diagnosis is difficult [23]. Differential diagnosis between an epidermoid tumour and an arachnoid cyst can be made by diffusion-weighted MRI, but in our case an arachnoid cyst initially was not considered [17]. Meckel's cave shows an anatomical variability, which can be evaluated in MRI, but any expansion or its disappearance, is of pathological significance [4]. If MRI shows a hyperintense, cystic mass along the distribution of the trigeminal nerve, also a pontine glioma should be included in differential diagnosis [22].

In this case, the intermittent clinical course, which initially led to the diagnosis of ischaemia, was not very typical for an schwannoma or cholesteatoma, which was considered before surgery on the basis of MRI. However, haemorrhage into such a tumour was considered to explain intermittent symptoms. Retrospectively, this clinical course probably could be explained by a quickly widening of the cyst.

Arachnoidal cysts have been well described in the posterior fossa, first by Maunsell in 1899 [13], but Meckel's cave is a very unusual position. However, there is a report of a traumatic arachnoidal cyst involving the Gasserian Ganglion of the trigeminal nerve written in the sixties by Jelsma et al. This cyst spread out anteriorly and medially to the foramen rotundum and back over the ganglion to the petrous ridge. The bone around was eroded and the maxillary part of the nerve was destroyed by the impact of the cyst. The clinical symptoms consisted of progressive dysesthesia and numbness in the distribution of the trigeminal nerve, the skull x-ray showed the bony erosion. The cyst was removed using a basal temporal approach [11]. In their cases of Meckel's cave lesions Beck et al. reported an arachnoid cyst presenting with double vision, exophthalmos and paralysis of 5<sup>th</sup> and 6<sup>th</sup> nerve. This cyst was treated by opening the cyst cavity and by creating a communication with the basal cistern. Observation during 6 months revealed a trouble-free period [3].

In our case, the cyst spread out under observation and recurred into the cerebellopontine angle, which is a somewhat more common position for arachnoidal cysts. However, the cyst's origin was not in the cerebellopontine angle.

We conclude, that arachnoidal cysts must be considered as a rare differential diagnosis of brain stem ischaemias, where no vascular risk factors could be found, especially in younger patients. Therefore MRI with contrast should be performed in such patients. Arachnoidal cysts also may be included as differential di-

agnosis finding space-occupying lesions in Meckel's cave. A sub-occipital approach to remove the cyst is possible. To minimize the risk of recurrence, we favour to resect the cyst's wall as radical as possible.

## References

- 1 Abdel-Aziz KM, van Loveren HR. Primary lymphoma of Meckel's cave mimicking trigeminal schwannoma: case report. *Neurosurgery* 1999; 44: 859–863
- 2 Abe T, Asano T, Manabe T, Matsuura H, Furuta T, Taguchi K. Trigeminal ganglioneuroma. *Brain tumor Pathol* 1999; 16: 49–53
- 3 Beck DW, Menezes AH. Lesions in Meckel' cave: variable presentation and pathology. *J Neurosurg* 1987; 67: 684–689
- 4 Benoudiba F, Hadj-Rabia M, Iffenecker C, Fuerxer F, Bekkali F, Francke JP, Doyon D. Variantes anatomiques du cavum de Meckel en IRM. *J Neuroradiol* 1998; 25: 201–206
- 5 Bright R. Serous cyst in the arachnoid. In: Longman, Rees, Orme, Browne, Green, Pater Noster-Row, Higley S (eds). *Reports of medical cases elected with a view of illustrating the symptoms and cure of diseases by reference to morbid anatomy, vol II, Diseases of the Brain and Nervous System, Part I, London 1831; 437–439*
- 6 Choi JU, Kim DS. Pathogenesis of arachnoid cyst: congenital or traumatic? *Pediatr-Neurosurg* 1998; 29: 260–266
- 7 Clemenceau S, Carpentier A. Kystes arachnoidiens intracranien. *Mise au point. Rev-Neurol-Paris* 1999; 155: 604–608
- 8 Delfini R, Innocenzi G, Ciapetta P, Domeniucucci M, Cantore G. Meningiomas of Meckel's cave. *Neurosurgery* 1992; 3: 1000–1007
- 9 Erdinçler P, Kaynar MY, Bozkus H, Ciplak N. Posterior fossa arachnoid cysts. *Br-J-Neurosurg* 1999; 13: 10–17
- 10 Hopf NJ, Perneckzy A. Endoscopic neurosurgery and endoscope-assisted microneurosurgery for the treatment of intracranial cysts. *Neurosurgery* 1998; 43: 1330–1336
- 11 Jelsma F, Ross PJ. Traumatic intracranial arachnoidal cyst involving the Gasserian ganglion. *Case report. J Neurosurg* 1967; 26: 439–441
- 12 Lange M, Oeckler R. Results of surgical treatment in patients with arachnoid cysts. *Acta Neurochir, Wien* 1987; 87: 99–104
- 13 Maunsell HW. Subtentorial hydatid tumor removed by trephining. *Recovery. N Z Med J* 1899; 2: 151–156
- 14 Mehta DS, Malik GB, Dar J. Trigeminal neuralgia due to cholesteatoma of Meckel's cave. *Case report. J Neurosurg* 1971; 34: 572–574
- 15 Mewes H, Schroth I, Deinsberger W, Böker DK. Trigeminal neuralgie als Erstsymptom einer Oesophaguskarzinommetastase im Cavum Meckeli-Fallbericht. *Zentralbl Neurochir* 2002; 63: 65–68
- 16 Nakano I, Iwasaki K, Kondo A. Solitary metastatic breast carcinoma in a trigeminal nerve mimicking a trigeminal neurinoma. *Case report. J Neurosurg* 1996; 85: 677–680
- 17 Park SH, Chang KJ, Song IC, Kim YJ, Kim SH, Han MH. Diffusion-weighted MRI in cystic or necrotic intracranial lesions. *Neuroradiology* 2000; 42: 716–721
- 18 Samii M, Carvalho GA, Schuhmann MU, Matthies C. Arachnoid cysts of the posterior fossa. *Surg-Neurol* 1999; 51: 376–382
- 19 Sener RN. Multiple, small, intracranial arachnoid cysts. *Comput Med Imaging Graph* 1997; 2: 261–263
- 20 Starkman SP, Brown TC, Linell EA. Cerebral arachnoid cysts. *J Neuro-pathol Exp Neurol* 1958; 17: 484–500
- 21 Thompson RK. Cystic cerebellar arachnoiditis. *J Neurosurg* 1946; 3: 461–467
- 22 Yuh WT, Nguyen HD, Mayr NA, Follett KA. Pontine glioma extending to the ipsilateral cavernous sinus and Meckel's cave: MR appearance. *AM J Neuroradiol* 1992; 13: 346–348
- 23 Yuh WT, Wright DC, Barloon TJ, Schultz DH, Sato Y, Cervantes CA. MR imaging of primary tumors of trigeminal nerve and Meckel's cave. *Am J Roentgenol* 1988; 151: 577–582