

Correspondence

A potential hazard of the Bivona cuffless paediatric tracheostomy tube

SIR—The Bivona cuffless paediatric tracheostomy tube is in common use in our hospital by patients who require a tracheostomy for a variety of indications. It is used in the short and medium term and often managed at home by patients and parents. This tracheostomy tube is licensed for multiple usage in a single patient and is steam-autoclavable. A device is provided in the pack to remove the plastic 'flange' (arrow) to facilitate thorough cleaning prior to reinsertion (Figure 1).

We would like to report a case of incorrect reassembly after autoclaving by our Theatre Sterile Supplies Department (TSSD) which led to a potentially serious critical incident.

The patient was a 5-year-old male with a long-term tracheostomy *in situ* following a caustic soda ingestion injury at the age of 2. He presented electively for stage 2 of his pharyngeal reconstruction. He was otherwise well. The tracheostomy was cannulated with a Bivona cuffless paediatric tracheostomy tube size 5.0 internal diameter (ID).

Inhalational induction proceeded uneventfully via an Ayre's T-Piece (Intersurgical Ltd, Wokingham, Berkshire, UK) connected by a standard 15.0 mm

connector to the Bivona tracheostomy tube. Neuromuscular blockade was achieved and the cuffless tracheostomy tube was exchanged for a size 5.5 ID reinforced cuffed or tracheal tube inserted via the tracheostomy. The tracheal tube was secured and the intraoperative course was unremarkable.

At the end of the operation, paralysis was reversed and spontaneous respiration was re-established. The child remained deeply anaesthetized on 100% O₂ and a volatile agent whilst breathing spontaneously via the Ayre's T-Piece circuit. The cuff of the reinforced tube was deflated and the tube exchanged for a newly autoclaved size 5.0 Bivona cuffless tracheostomy tube.

It was impossible to reconnect the breathing circuit to the tracheostomy tube but the reason for this was not immediately apparent. The tracheostomy tube was quickly removed and replaced with a brand new size 5.0 ID cuffless Bivona tracheostomy tube, the breathing system was reattached and the patient awakened uneventfully. There was no arterial oxygen desaturation or other adverse sequelae in this instance.

On subsequent inspection of the tracheostomy tube, it was clear that it had been reassembled incorrectly after cleaning (please see Figure 1, correct configuration; and Figure 2, incorrect configuration). The device to remove the flange was not provided in

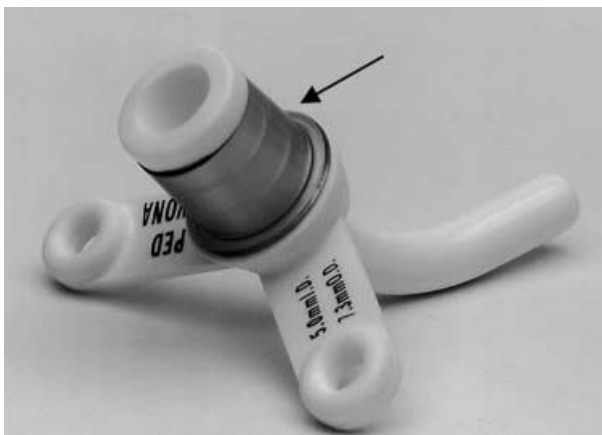


Figure 1
Bivona tracheostomy tube with the plastic flange correctly aligned.



Figure 2
Bivona tracheostomy tube with the plastic flange replaced upside down, making connection to the breathing system impossible.

the sterile packet from our TSSD, and even after recognizing the problem, it was difficult to remove and replace the flange without this tool.

We feel that this potential hazard is well worth pointing out to other anaesthetists who may encounter this tracheostomy tube after it has been autoclaved and reassembled incorrectly.

This case underlines the need to check all equipment carefully before use, and re-emphasizes the advantage of thorough preoxygenation before performing any intervention which could impact upon airway safety. We suggest that any reusable tracheostomy tube is repackaged with all accessories provided in the original set if autoclaved.

SARAH HARPER*

ELSPETH FACER†

*SpR Anaesthesia

Whittington Hospital

Highgate Hill

London, UK

†Consultant in Anaesthesia

Great Ormond Street Hospital for Sick Children

Great Ormond Street

London, UK

Anaesthetic management of a child with Hallermann–Streiff–Francois syndrome

SIR—Hallermann–Streiff–Francois syndrome is a rare genetic disorder that occurs sporadically. Familial occurrence (1) has been suggested, indicating a possibility of autosomal recessive inheritance or a dominant mutation with parental mosaicism. Principal manifestations (2) of this syndrome include dyscephaly with frontal parietal bossing, marked micrognathia and microstomia. Ophthalmic features include micropthalmia and congenital cataracts. Dental abnormalities such as malocclusion, natal teeth and skin atrophy with hypotrichosis are among the cardinal features of this syndrome. We report a child with typical Hallermann–Streiff syndrome who required multiple general anaesthetics for ophthalmic procedures in our hospital.

Our patient was the first child of nonconsanguineous parents. Antenatal history was uneventful except for intrauterine growth retardation. He was delivered at 33 weeks by Caesarean section for

early but poor progress of labour. Birth weight was 1.5 kg. Physical examination at birth revealed a dysmorphic neonate with bird-like facies, resulting from a disproportionately small nose, mouth and mandible. The head was brachycephalic with bilateral corneal opacities. Testes were undescended.

He presented at 1 month of age for an ophthalmic examination under anaesthesia and laser therapy for glaucoma. Body weight was 1.8 kg. Preoperative ultrasound revealed a patent foramen ovale and no other cranial or renal anomalies.

The patient was brought to the theatre after a 4-h preoperative fast. A difficult airway was anticipated due to the small mouth opening and the receding mandible. Several sizes of oral airway, tracheal tubes and a 2.1 mm neonatal fiberoptic bronchoscope were prepared. General anaesthesia was induced using incremental sevoflurane up to 5% in 100% oxygen via a circle system. A patent airway was easily maintained using a soft seal facemask and size 0 oral airway. After a successful trial of bag and mask ventilation, intravenous atropine $2 \mu\text{g}\cdot\text{kg}^{-1}$ was given, followed by succinylcholine $1 \text{ mg}\cdot\text{kg}^{-1}$ and fentanyl $1 \mu\text{g}\cdot\text{kg}^{-1}$. Laryngoscopy was performed using a size 0 Miller blade. Full glottic visualization was possible and intubation easily achieved with a size 3 RAE® tracheal tube. After confirmation of tube placement, muscle relaxation was maintained with atracurium.

After the initial surgery, the patient presented twice again at the age of 2 months for lensectomy. General anaesthesia was performed in the same manner, without any complications. In all three instances, the patient was transported back to neonatal intensive care. He was allowed to recover fully from general anaesthesia and neuromuscular blockade before extubation in the intensive care unit.

Children with Hallermann–Streiff syndrome can have a multitude of problems such as cardiac anomalies and congenital cataracts, which require surgical correction. The main concerns for the anaesthetist relate to the cardiorespiratory system and airway problems. The incidence of cardiac anomalies is 4.8% and includes simple septal defects, patent ductus arteriosus, or more complex defects such as tetralogy of Fallot. Severe pulmonary infections caused by underlying immunodeficiency can pose a problem for adequate oxygenation and ventilation.

By far, the greatest anaesthetic challenge lies in the maintenance of the airway. Narrow upper airway associated with the craniofacial configuration and narrowing of the posterior oropharynx can lead to complete airway obstruction despite use of conventional oropharyngeal airways (3). Severe respiratory embarrassment and obstructive sleep apnoea have been treated using elective tracheostomy (4, 5). Microstomia and undeveloped or absent temporomandibular joint can make laryngoscopy difficult or impossible. Marked mandibular hypoplasia, anterior glottis with posterior tracheal displacement can also impair glottic visualization and tracheal intubation.

Our patient did not exhibit any signs of respiratory embarrassment. Although intravenous access was available at induction, we chose an inhalational technique to assess the adequacy of mask ventilation before the administration of muscle relaxant to facilitate tracheal intubation. If we had failed to intubate the trachea, our next option would have been oral fibreoptic-aided intubation using a size 2.2 mm neonatal bronchoscope, while maintaining anaesthesia with 100% oxygen and sevoflurane. A size 1 laryngeal mask airway (LMATM) could have been used for a bigger child undergoing a short procedure but the size of our patient (1.8 kg) preclude the use of this device.

Difficult airway and intubation is a known feature of Hallermann-Streiff patients since this syndrome was first described by Aubry in 1893. Our patient has all the other typical features of this syndrome but had presented with a normal airway.

KENG FATT CHEONG
CONSTANCE SU LIN THAM
Department of Anaesthesia
National University Hospital
Singapore
(Email for KFC: anackf@nus.edu.sg)

References

- 1 Dennis NR, Fairhurst J, Moore IE. Lethal syndrome of slender bones, intrauterine fractures, characteristic facial appearance, and cataracts, resembling Hallermann-Streiff Syndrome in two sibs. *Am J Med Genet* 1995; **59**: 517–520.
- 2 Cohen MM Jr. Hallermann-Streiff syndrome: a review. *Am J Med Genet* 1991; **41**: 488–499.
- 3 Malde AD, Jagtap SR, Pantvaidya SH. Hallermann-Streiff syndrome: airway problems during anesthesia. *J Postgrad Med* 1994; **40**: 216–218.
- 4 Van Balen ATM. Dyscephaly with microphthalmos, cataract and hypoplasia of mandible. *Ophthalmologica* 1961; **141**: 53–63.
- 5 Falls HF, Schull WJ. Hallermann-Streiff syndrome: a dyscephaly with congenital cataracts and hypotrichosis. *Arch Ophthalmol* 1960; **63**: 409–420.

Anaesthetic considerations for a child with reflex anoxic seizures

SIR—Reflex anoxic seizures (RAS) are produced by a cerebral ischaemic event secondary to a vagally mediated cardiac arrest. Anaesthetic procedures may provoke an attack. The anaesthetic management for a child with RAS has not been described. We describe the case of a 3-year-old boy with RAS undergoing a routine ear, nose and throat procedure.

A healthy 3-year-old boy weighing 18 kg presented for myringotomy and grommets.

He had suffered from RAS since the age of 1. A typical episode lasted seconds for which there was no obvious precipitating cause. Clinically each attack was self-limiting. He would become pale and collapse on the ground accompanied on occasion by tonic-clonic movements.

He was premedicated with 360 mg of paracetamol syrup, and Ametop applied to both hands in the presence of his mother. We applied full monitoring in the anaesthetic room, avoiding blood pressure cuff insufflation prior to induction, and a cannula was sited during a distraction technique where a dedicated staff nurse occupied the child on the opposite side from the cannulation site. Atropine was drawn up ready-to-use at any time. Anaesthesia was induced with 3 mg·kg⁻¹ propofol, and a laryngeal mask airway (LMATM) was inserted. Maintenance of anaesthesia was achieved with 3% sevoflurane, and a mixture of nitrous oxide and 30% oxygen via an Ayres T-piece circuit. Throughout the procedure his heart rate remained above 90 b·min⁻¹.

His mother was present at induction and during his arousal in recovery, and his cannula was left *in situ* until he was fit for discharge.

Reflex anoxic seizures are the consequence of vagally mediated cardiac arrest producing relative cerebral ischaemia (1). The attack can be provoked by fright, venepuncture and extreme changes in

temperature, such as a hot or cold bath (2). The child goes pale and limp, cardiac asystole can occur for up to 15 s (3,4). Cardiac massage is rarely necessary as the episode is self resolving.

A study suggested that eight of 1000 preschool children are affected (5). The condition is commonest in females between the ages of 6 months and 2 years. The presence of tonic-clonic convulsions in some children can lead to the misdiagnosis of epilepsy (4).

Treatment for RAS is mainly supportive and requires reassurance of the parents (3). Occasionally, regular antimuscarinic agents have been used therapeutically in children in whom the seizures are common. Permanent pacing has been used rarely to treat children with a severe form of this condition (7).

We employed simple anaesthetic techniques to minimize anxiety, which could otherwise lead to vagally mediated bradycardia and potential physiological disturbance. A peaceful environment, aided by the presence of his mother, together with local anaesthetic cream applied to potential cannulation sites were deemed essential. Oral analgesic premedication helped ensure a comfortable child in the early postoperative period; the addition of a sedative may help calm a more anxious child prior to anaesthetic induction. Intravenous induction was felt to be preferable because it allowed the immediate administration of antimuscarinic agents such as atropine, and was thought feasible after inspection of potential cannulation sites at the preoperative assessment.

As atropine is shown to reduce the frequency of seizures (6), we considered oral atropine as a premedication in the event of an inhalational technique appearing probable.

In summary, RAS is a rare childhood condition. A clear anaesthetic management plan must include strategies to minimize stress and enable rapid treatment of vagally mediated bradycardia.

J. M. ONSLOW
J. BURDEN
Portsmouth hospitals
Portsmouth
Hants, UK

References

- 1 Stephenson JPB. Reflex anoxic seizures (white breath holding). Non epileptic vagal attacks. *Arch Dis Childhood* 1978; **53**: 193–200.

- 2 Roddy SA, Ashwal S, Schneider S. Venepuncture fits: a form of reflex anoxic seizure. *Pediatrics* 1983; **72**: 715–718.
- 3 Appleton RE. Reflex anoxic seizures. *BMJ* 1993; **307**: 214–215.
- 4 Pollard RC. Reflex anoxic seizures and anaesthesia. *Paediatr Anaesth* 1999; **9**: 467–468.
- 5 Lombroso CT, Lerman P. Breath holding spells (cyanotic and pallid infant syncope). *Pediatrics* 1967; **39**: 563–581.
- 6 McWilliam RC, Stephenson JPB. Atropine treatment of reflex anoxic seizures. *Arch Dis Childhood* 1984; **59**: 473–485.
- 7 McLeod KA, Wilson N, Hewitt J *et al.* Cardiac pacing for severe childhood neurally mediated syncope with reflex anoxic seizures. *Heart* 1999; **82**: 721–725.

Caudal opioids

SIR—I read with interest the editorial 'Use of caudal-epidural opioids in children: still state-of-the-art or the beginning of the end?' (1).

I would like to draw the attention of the editorial writers to our studies on the use of low dose morphine for caudals in children (2–4). This particular dose has not caused any respiratory complications in well over the 500 cases in our report, and has since that time, been used in a large number of children. As discussed in the editorial, single shot caudals do have a finite duration; however, the advantage of having a profound effect on pain during the first hours following surgery is a benefit to all concerned, particularly the patient. The minor side-effects that can be treated effectively should not condemn the caudal opioid use to the relic pile. We should try to continue to give our paediatric patients the best postoperative pain management care we can.

JAMES F. MAYHEW
Arkansas Children's Hospital
Little Rock, AR
USA

References

- 1 Lonnquist PA, Ivani G, Moriarty T. Use of caudal-epidural opioids in children: still state of the art or the beginning of the end? *Paed Anaesth* 2002; **12**: 747–749.
- 2 Mayhew JF, Brodsky R, Blakey D *et al.* Low dose caudal morphine for postoperative analgesia in infants and children: a report of 500 cases. *J Clin Anesth* 1995; **7**: 640–642.
- 3 Nguyen NH, Berman J, Mayhew JF. Efficacy of Using Caudal Morphine to Control Pain in Postoperative Palatoplasty Patients. Society of Pediatric Anesthesiology, Ft Meyers, Florida, February 2000, 25–27.
- 4 Nguyen S, Nguyen NC, Mayhew JF. Caudal Morphine for Postoperative Pain Relief Following Cleft-lip Repair. Gulf Coast Residents Conference. Chapel Hill, North Carolina, April 2000, 7–9.

Authors reply to JF Mayhew

SIR—As the intention with our editorial was to initiate a discussion on this topic we thank Dr Mayhew for his comments relating to our previous communication. We do agree that the risk for respiratory depression is low after limited doses of caudal morphine in children but the risk certainly exists and requires consideration and monitoring/supervision. However, this risk is not the primary reason for not using opioids in the caudal/epidural space of children. As reported initially by Krane *et al.* (1), later by Lloyd-Thomas *et al.* (2) and also by Dr Mayhew's own research group (3) there is a substantial risk for other distressing side-effects, e.g. PONV, pruritus and voiding problems necessitating bladder catheterization. Although all these side-effects are possible to treat it seems far more logical to use other equally effective options that are associated with much more benign side-effect spectra. Thus, we agree that it perhaps is not yet the time to finally put caudal/epidural opioids on the relic pile but we certainly believe that opioids should be removed to a place far back in the medicine cupboard, way behind plain local anaesthetics, clonidine and S-ketamine.

P.A. LÖNNQVIST*

GIORGIO IVANI†

TONY MORIARTY‡

*Paediatric Anaesthesia and ICU
AL Children's Hospital/KS
S-171 76 Stockholm
Sweden

†Department of Pediatric Anesthesia and ICU
'Regina Margherita' Children's Hospital
Piazza Polonia 94, 10126 Turin, Italy and

‡Consultant Anaesthetist, Birmingham
Children's Hospital NHS Trust
Steelhouse Lane, Birmingham B4 6NH

References

- 1 Krane EJ, Tyler DC, Jacobson LE. The dose response of caudal morphine in children. *Anesthesiology* 1989; **71**: 48–52.
- 2 Lloyd-Thomas AR, Howard RF. A pain service for children. *Paed Anaesth* 1994; **4**: 3–15.
- 3 Mayhew JF, Brodsky R, Blakey D *et al.* Low dose caudal morphine for postoperative analgesia in infants and children: a report of 500 cases. *J Clin Anesth* 1995; **7**: 640–642.

Liver transplantation for propionic acidaemia in a 14-month-old male

SIR—We would like to report the anaesthetic management of a 14-month-old child for liver transplantation. Propionyl CoA carboxylase deficiency is a rare autosomal recessive disorder. Death can occur from the effects of an acute episode of severe metabolic ketoacidosis associated with hyperammonaemia. Propionic acidaemia poses a unique problem. Unlike ornithine transcarbamylase deficiency, the enzyme disorder is found not just in the liver but throughout every living cell in the human body. Therefore, transplantation does not cure the patient from the inborn error of metabolism. However, it does attenuate the clinical expression of the disorder (1,2). The transplantation of a normal functioning liver can help eliminate two main precursors of propionate acid, isoleucine and valine, thereby reducing the acid load. There are five reported cases of liver transplantation for propionic acidaemia, of which three had successful outcomes (1–3). We are fortunate to be the first to report the anaesthetic management of a liver transplant for propionic acidaemia in North America.

A 14-month-old male of Middle Eastern descent with propionic acidaemia was scheduled for urgent split-liver transplant. The diagnosis of propionic acidaemia was made during the first week of life during investigation for hypotonia, poor oral feeding, subsequent hyperammonaemia and metabolic acidosis. Since birth, he had been admitted 15 times for exacerbation of hyperammonaemia resulting in significant developmental delays in speech, motor skills and cognitive function. There was no other significant medical history indicated.

The child was already in the hospital having been admitted the previous week for vomiting, which was related to hyperammonaemia and metabolic acidosis.

The frequency of hospital admissions and the refractory nature of his hyperammonaemia led to his elevation to status 1 on the UNOS liver transplant list. At the time of the transplant, the child had progressed from intravenous hydration to enteral feedings of Ross products (Columbus, OH, USA), which included Similac® with iron, Pro-Phree® and Propimex® via gastrostomy. Chronic medications included l-carnitine, l-isoleucine, l-valine and

l-methionine supplementation, ranitidine, sodium citrate, and sodium phenylbutyrate. Physical examination revealed a 10.5-kg male child, who appeared lethargic and was unable to sit in his crib without aid. Cardiopulmonary examination was normal. The abdomen was soft, nontender and nondistended with normoactive bowel sounds. A gastrostomy button was present on the left of midline, in the upper abdominal wall. Laboratory examination was significant for an ammonia level of 50 mmol l^{-1} haemoglobin 119 g l^{-1} and an activated-partial thromboplastin time of 34.5 s. A chest radiograph showed clear lung fields with a normal cardiomedastinal silhouette. Our patient, preoperatively, was lethargic and had obvious signs of hypotonia and a history of difficulty with feeding. He was being supplemented with gastrostomy feedings and intravenous infusion of D10_NS with electrolytes. Many patients with propionic acidaemia have difficulty with feeding, because the acid metabolites are felt to affect the central gag reflex centre and appetite (4). Therefore, we decided to proceed with a modified rapid sequence induction with cricoid pressure. An intubating dose of pancuronium was chosen instead of succinylcholine, because of the presence of hypotonia.

The selection of anaesthetic drugs was partially based on the understanding of the biochemical interactions elucidated by Harker *et al.* (5). We chose a drug, propofol, that could potentially have a negative effect, although to a negligible degree, on the clinical condition of the child. The polyunsaturated fats in soybean oil may be metabolized to propionic acid. However, patients with propionic acidaemia are routinely maintained on diets, which contain 50–75% of the essential amino acids (4,6). In addition, the main propiogenic precursors are valine, isoleucine, threonine and methionine, with a greater contribution from isoleucine and valine (1,5). Cholesterol and odd-chain fatty acids have a relatively minor role in producing propionic acid (7). Dietary sources of odd-chain fatty acids are allowed to provide essential fatty acids (8). The remaining drugs chosen had no potential to exacerbate the organic acidaemia. It was also felt that the amount of drugs injected would not pose a tremendous risk to the patient.

In the operating room, standard monitoring included noninvasive blood pressure measure-

ments, electrocardiography, pulse oximetry, capnography, gas analysis and oesophageal temperature measurements. The child's initial vital signs were stable. The child had been NPO/NPG for greater than 6 h, prior to induction. The gastrostomy tube was attached to suction and did not result in any gastric contents. Prior to induction, the child received midazolam 1 mg, glycopyrrolate $60 \text{ } \mu\text{g}$ and lidocaine 10 mg, intravenously. The patient was preoxygenated and a modified rapid sequence induction with cricoid pressure was performed. Propofol 2.5 mg kg^{-1} with pancuronium 0.1 mg kg^{-1} were given in rapid succession. Intubation of the trachea was achieved atraumatically with a 4.5 mm uncuffed tracheal tube at the first attempt.

Additional monitors and intravenous access were then placed, which included a 22 gauge right radial arterial line, a 5 Fr double lumen central venous line in the left subclavian vein and a 22 gauge intravenous catheter in the right external jugular vein. Peripheral intravenous access was attempted many times, but proved difficult, possibly from the effects of propionic acid on the lining of small blood vessels (9). A 12 fg orogastric tube was placed to help in decompressing the stomach. A combination oesophageal stethoscope and temperature probe was placed in the oesophagus. Care was taken to ensure ample padding of all pressure points and unhindered access to the airway, intravenous lines and monitors. The operation lasted approximately 5 h from incision to the placement of the surgical dressings. A 250 mg of Cefazolin was given prior to incision.

Anaesthesia was maintained with a sufentanil infusion at $1\text{--}3 \text{ } \mu\text{g kg}^{-1} \text{ h}^{-1}$ and $\text{NO}_2\text{--O}_2\text{--isoflurane}$. Supplemental doses of sufentanil in $10 \text{ } \mu\text{g}$ doses were also given. The patient received a total of $150 \text{ } \mu\text{g}$ of sufentanil, the bulk of which was given at the beginning of the case just prior to incision. The gases were delivered through a heated and humidified circuit. Several doses of midazolam 0.1 mg kg^{-1} were administered over the course of the anaesthesia to provide amnesia. The intraoperative haemodynamic perturbations were minimal. The surgical technique of piggybacking the anastomosis of the hepatic veins to the inferior vena cava led to a mild hypotensive episode on cross clamping the diseased liver. A 50 : 50 combination of 0.9 normal saline and

5% albumin was administered in intermittent bolus fashion to stabilize the haemodynamics.

Estimated blood loss was approximately 300 ml; with most of the loss taking place during the vascular anastomosis. The child was transfused with 255 ml of random donor crossmatched, irradiated, CMV-antigen negative, leukocyte-reduced packed red cells. Urine output was $0.5 \text{ ml}\cdot\text{kg}^{-1}\cdot\text{h}^{-1}$. Dopamine at $3 \mu\text{g}\cdot\text{kg}^{-1}\cdot\text{h}^{-1}$ was started to help in improving vascular tone, while additional fluid was given. For the rest of the operating period urine output remained at a mean of $2.2 \text{ ml}\cdot\text{kg}^{-1}\cdot\text{h}^{-1}$. A total of $1.5 \text{ mmol}\cdot\text{kg}^{-1}$ of NaHCO_3 was given over the course of the case to aid in the correction of the child's metabolic acidosis; base deficit reached its nadir of $10 \text{ mmol}\cdot\text{l}^{-1}$ during the anhepatic phase and serum lactate peaked at $3.0 \text{ mmol}\cdot\text{l}^{-1}$ early in reperfusion and slowly corrected itself. Also, an infusion of D10 was continued throughout the operation to prevent a catabolic state and blood glucose levels were ordered with the intraoperative blood specimens.

The blood glucose remained above $11.10 \text{ mmol}\cdot\text{l}^{-1}$.

At the end of the operation, the skin incisions were infiltrated with 20 ml of 0.125% bupivacaine by the surgeon to supplement the PCA morphine for postoperative pain control. The child remained intubated, sedated and paralyzed when transported to the intensive care unit. The patient's generalized hypotonia, the surgery and anaesthetic drugs made it obvious that the patient would not be able to effectively ventilate immediately, postoperatively. In addition, the generous use of analgesics and sedatives would allow the body time to heal and avoid undue stress. The initial blood work done in the paediatric intensive care unit showed an improvement of overall acid-base balance, reflecting the presence of a functioning transplanted liver. Also, the first postoperative serum ammonia level was $19 \text{ mmol}\cdot\text{l}^{-1}$.

In summary, liver transplantation in patients with propionyl CoA carboxylase deficiency is aimed at improving the quality of life. It is too premature to make any assumptions on the long-

term prognosis of these patients, as only a few have undergone the operation. Therefore, transplantation is generally acceptable for those patients who have failed medical management. In the case reported, the child was transplanted electively in hopes of preventing or minimizing the widespread metabolic effects. The rare condition of this child did not result in any significant modification of an anaesthetic plan for a liver transplant; however, the case was presented as an example for others to review, as no previous case has been reported for liver transplantation.

TAE W. KIM*

STUART R. HALL†

*Assistant Professor

Department of Anesthesiology

Texas Children's Hospital

†Anesthesia resident

Department of Anesthesiology

Baylor College of Medicine, Texas

currently Pediatric Cardiac

Anesthesia Fellow

Texas Children's Hospital

Houston, TX, USA

References

- 1 Saudubray JM, Touati G, Delonlay P *et al*. Liver transplantation in propionic acidemia. *Eur J Pediatr* 1999; **158**: S65-S69.
- 2 Schlenzig JS, Poggi-Travert F, Laurent J *et al*. Liver transplantation in two cases of propionic acidemia. *J Inher Metab Dis* 1995; **18**: 448-461.
- 3 Yorifuji T, Muroi J, Uematsu A *et al*. Living-related liver transplantation for neonatal-onset propionic acidemia. *J Pediatr* 2000; **137**: 572-574.
- 4 North KN, Korson MS, Gopal YR *et al*. Neonatal-onset propionic acidemia: neurologic and developmental profiles, and implications for management. *J Pediatr* 1995; **126**: 916-922.
- 5 Harker HE, Emhardt JD *et al*. Propionic acidemia in a four-month-old male: a case study and anesthetic implications. *Anesth Analg* 2000; **91**: 309-311.
- 6 Nelson WE. *Textbook of Pediatrics*, 15th edn. Philadelphia: W.B. Saunders Company, 1996: 343-344.
- 7 Mandava P. Metabolic disease & stroke: propionic acidemia. *eMedicine Journal* 2001; **2**: 1-8.
- 8 Bernstein LE. Organic Acidemia: Dietary Management. <http://www.MeadJohnson.com> 2002: 4-8.
- 9 Greene A. Propionic Acidemia Q & A. Organic Acidemia Association. <http://www.oaanswers.org> 2002: 1-5.