

B. J. Kwon
M. H. Han
C. W. Oh
K. H. Kim
K. H. Chang

Procedure-related haemorrhage in embolisation of intracranial aneurysms with Guglielmi detachable coils

Received: 24 March 2003
Accepted: 2 May 2003
Published online: 8 July 2003
© Springer-Verlag 2003

B. J. Kwon · M. H. Han (✉)
K. H. Kim · K. H. Chang
Department of Radiology,
Seoul National University College
of Medicine, 28 Yongon-Dong,
Chongno-Ku, 110-744 Seoul, South Korea
E-mail: hanmh@radcom.snu.ac.kr
Tel.: +822-760-3602
Fax: +822-743-6385

M. H. Han · K. H. Chang
Clinical Research Institute,
Seoul National University Hospital,
28 Yongon-Dong, Chongno-Ku,
110-744 Seoul, South Korea

M. H. Han · K. H. Chang
Institute of Radiation Medicine,
Seoul National University Medical
Research Centre, Seoul National University
College of Medicine, 28 Yongon-Dong,
Chongno-Ku, 110-744 Seoul, South Korea

C. W. Oh
Department of Neurosurgery,
Seoul National University College
of Medicine, 28 Yongon-Dong,
Chongno-Ku, 110-744 Seoul, South Korea

Abstract We reviewed the haemorrhagic complications of the endovascular treatment of intracranial aneurysms, in terms of frequency, pre-embolisation clinical status, clinical and radiological manifestations, management and prognosis. In 275 patients treated for 303 aneurysms over 7 years we had seven (one man and six women—2.3%) with haemorrhage during or immediately after endovascular treatment. All procedures were performed with a standardised protocol of heparinisation and anaesthesia. Four had ruptured aneurysms, two at the tip of the basilar artery, and one each on the internal carotid and posterior cerebral artery, treated after 12, 5, 14, and 2 days, respectively, three were in Hunt and Hess grade 2 and one in grade 1. Bleeding occurred during coiling in three, after placement of at least four coils, and during manipulation of the guidewire to enter the aneurysm in the fourth. Haemorrhage was manifest as extravasation of contrast medium, with a sudden rise in systolic blood

pressure in three patients. The other three patients had unruptured aneurysms; they had stable blood pressure and angiographic findings during the procedure, but one, under sedation, had seizures immediately after insertion of four coils, and the other two had seizures, headache and vomiting on the day following the procedure. Heparin reversal with protamine sulphate was started promptly started when bleeding was detected in four patients, and the embolisation was completed with additional coils in three. Emergency ventricular drainage was performed in the two patients with ruptured aneurysm and one with an unruptured aneurysm who had abnormal neurological responses or hydrocephalus. The bleeding caused a third nerve palsy in one patient, which might have been due to ischaemia and progressively improved.

Keywords Intracranial aneurysm · Coil embolisation · Haemorrhage

Introduction

Rupture of an aneurysm during a procedure is the most feared complication of endovascular treatment, and has been reported in 2–5 % of procedures for previously ruptured aneurysms [1, 2, 3, 4, 5, 6, 7]. Because of its relatively infrequency, this event and its consequences

have been poorly documented. Haemorrhage usually occurs in patients undergoing treatment for acute subarachnoid haemorrhage, and is rare during treatment of for unruptured aneurysms; to our knowledge, only nine cases have been reported in the English-language literature [7, 8, 9, 10, 11, 12]. Most have been case reports or part of series including thromboembolic, haemorrhagic,

and other complications; their clinical and radiological features were not detailed.

Procedure-related haemorrhage can be defined as not only clinically and angiographically evident bleeding but also as minor leakage presenting only with a symptomatic seizure or a sudden rise of arterial blood pressure even when no extravasation of contrast medium is seen. Reports of haemorrhage have concerned various kinds of patients, so that its frequency and prognosis have been variable [1, 2, 3, 4, 5, 6, 7, 8, 9, 10, 11, 12].

We have had seven cases of procedure-related haemorrhage during endovascular treatment of ruptured or unruptured aneurysms over the past seven years. We discuss the frequency, pre-embolisation clinical status, well known or unusual clinical and radiological manifestations, management and prognosis and compare them with those reported previously.

Materials and methods

Between February 1995 and November 2002, we treated 275 patients with 174 ruptured (123 anterior and 51 posterior circulation) and 129 unruptured (98 anterior and 31 posterior circulation) intracranial aneurysms, with successful or partially protective occlusion. Procedure-related haemorrhage occurred from seven aneurysms (four ruptured and three unruptured). The age of the one man and six women ranged from 37 to 67 years (mean 54 years). All patients with ruptured aneurysms were in good condition, and treatment was performed 2–14 days after the ictus. Two patients with large unruptured internal carotid artery aneurysms had impaired visual acuity, and one unruptured aneurysm of the posterior cerebral artery was incidentally found during investigation for an arteriovenous malformation.

Endovascular treatment was initiated with a standardised protocol: general anaesthesia in six cases and sedation in one, and a loading dose of 2000–4000 IU heparin and 1000 IU every hour in all cases. We used Excelsior microcatheters in five cases, an Excel-14 in one, and a FasTracker-10 in another, Agility-14 microguide wires in four cases, a Transend EX-14 in two cases, and a Seeker-10 in one. At the end of the procedure we routinely stopped heparinisation, but if a thromboembolic complication occurred or was expected, for example, when the blood of the parent artery was in contact with protruding loops of the coil or with a large surface area of coil in a broad-necked aneurysm, heparinisation was continued at twice the level of normal activated-prothrombin time (aPTT) for 24 h after the procedure.

Results

The frequency of procedure-related haemorrhage was 2.3% in both ruptured and unruptured aneurysms. One of the ruptured and two of the unruptured aneurysms lay on the anterior circulation, and three and one, respectively, on the posterior circulation. Three of the ruptured aneurysms were small (5–6 mm) aneurysms and one was large (15 mm); one unruptured lesion was small (3 mm) and two were large (20 mm). The large ruptured aneurysm was elongated, with a large daughter sac and a small width-to-depth ratio (0.4). In contrast,

the two large unruptured aneurysms had larger width-to-depth ratios (0.9 and 1.4).

The mechanism and stage at which haemorrhage occurred varied: during introduction of the wire and during coiling in three ruptured aneurysms, during coiling in one unruptured aneurysm and some time after the procedure in the other two. Both these latter were large aneurysms, with no technical or clinical problem during the procedure, continued heparinisation according to our protocol postprocedure, and bleeding within a day of embolisation without angiographic demonstration of extravasation of contrast medium. In the ruptured aneurysms we saw extravasation of contrast medium in four, coil protrusion in two and an abrupt rise in systolic blood pressure during the procedure in three. None of these was evident with the three unruptured aneurysms, even in the patient who had fits during the procedure. No new neurological deficit developed in six patients; the only new deficit was a third nerve palsy in one patient. Conservative treatment and, if needed, emergency ventriculostomy were performed for all seven cases. Clinical, technical, and angiographic data are summarised in Table 1.

Case reports

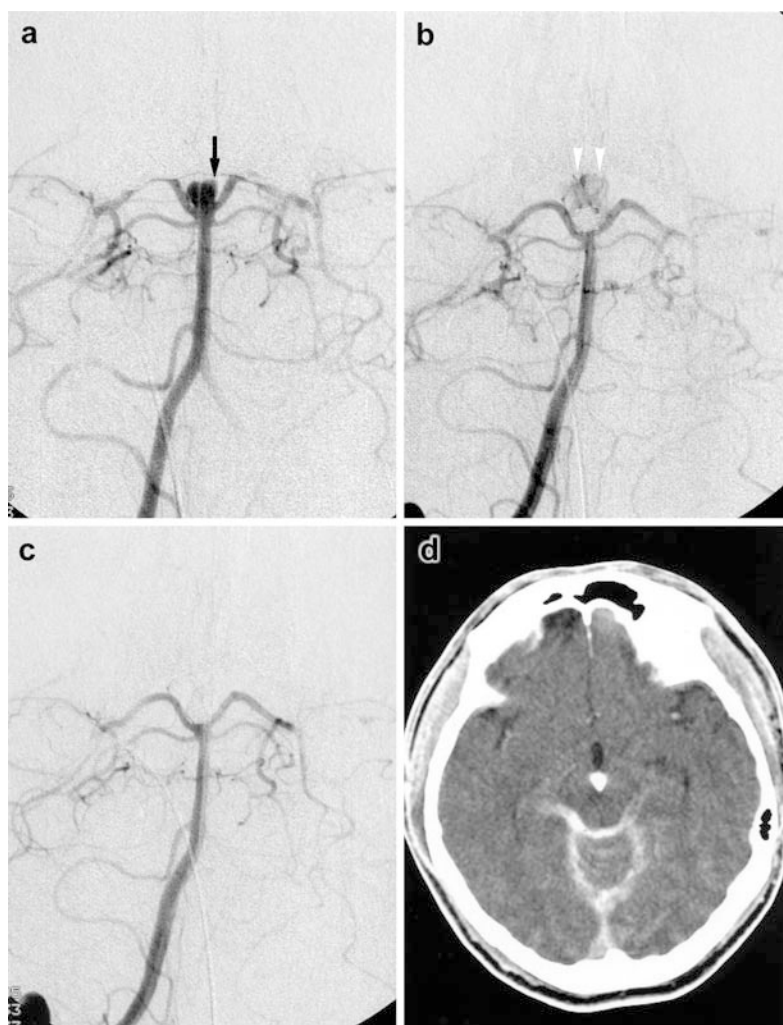
Case 1

A 37-year-old man with acute headache and vomiting underwent endovascular treatment 12 days after symptom onset. Angiography revealed a basilar tip aneurysm, which was selectively catheterised with an Excel 14 microcatheter and Transend EX-14 guidewire. After insertion of four Guglielmi detachable coils (GDC) 10 series (SynerG), 35 mm in total, the aneurysm was completely occluded, but a small amount of extravasation of contrast medium was seen on angiography. Vital signs, including arterial blood pressure, were stable. No additional coils were inserted because no further extravasation was seen on immediate angiography. CT revealed dense material in the subarachnoid space (Fig. 1). The patient recovered promptly with conservative treatment and remains healthy, having been followed for 1 year.

Case 2

CT showed no definite evidence of subarachnoid haemorrhage in a 67-year-old female with acute severe headache, but lumbar puncture was positive. Angiography revealed a large, elongated aneurysm of the right posterior cerebral artery, which we treated 14 days after the ictus. After shaping the catheter tip, we used an Excelsior catheter and an Agility 14 wire to catheterise the aneurysm. During placement of the fifth coil GDC 10 SynerG-2D 3×8, protrusion of a loop was seen on lateral fluoroscopy and extensive extravasation of contrast medium was seen on angiography. The systolic blood pressure abruptly rose from 120 to 200 mm Hg. We immediately gave 30 mg protamine sulphate and detached the fifth coil after inserting the remaining segment without any repositioning. We placed a GDC 10 soft 2×2 in the aneurysm, and angiography showed complete occlusion of the aneurysm, with no extravasation (Fig. 2). After recovering from the anaesthesia the patient was drowsy and CT revealed dense material in the cisterns

Fig. 1a–d Patient 1. Haemorrhage during coiling with extravasation of contrast medium. **a** A small ruptured basilar-tip aneurysm with a suspicious bleb (*arrow*). As soon as the aneurysm was completely occluded with four Guglielmi detachable coils (GDC-10 SynerG), 35 cm total length, angiography **b** showed a little extravasation (*arrowheads*) spreading from the bleb. Arterial blood pressure was unchanged. Extravasation had stopped spontaneously 1 min later **c** without heparin reversal or additional coils. **d** CT immediately after the procedure showed high density in the subarachnoid space



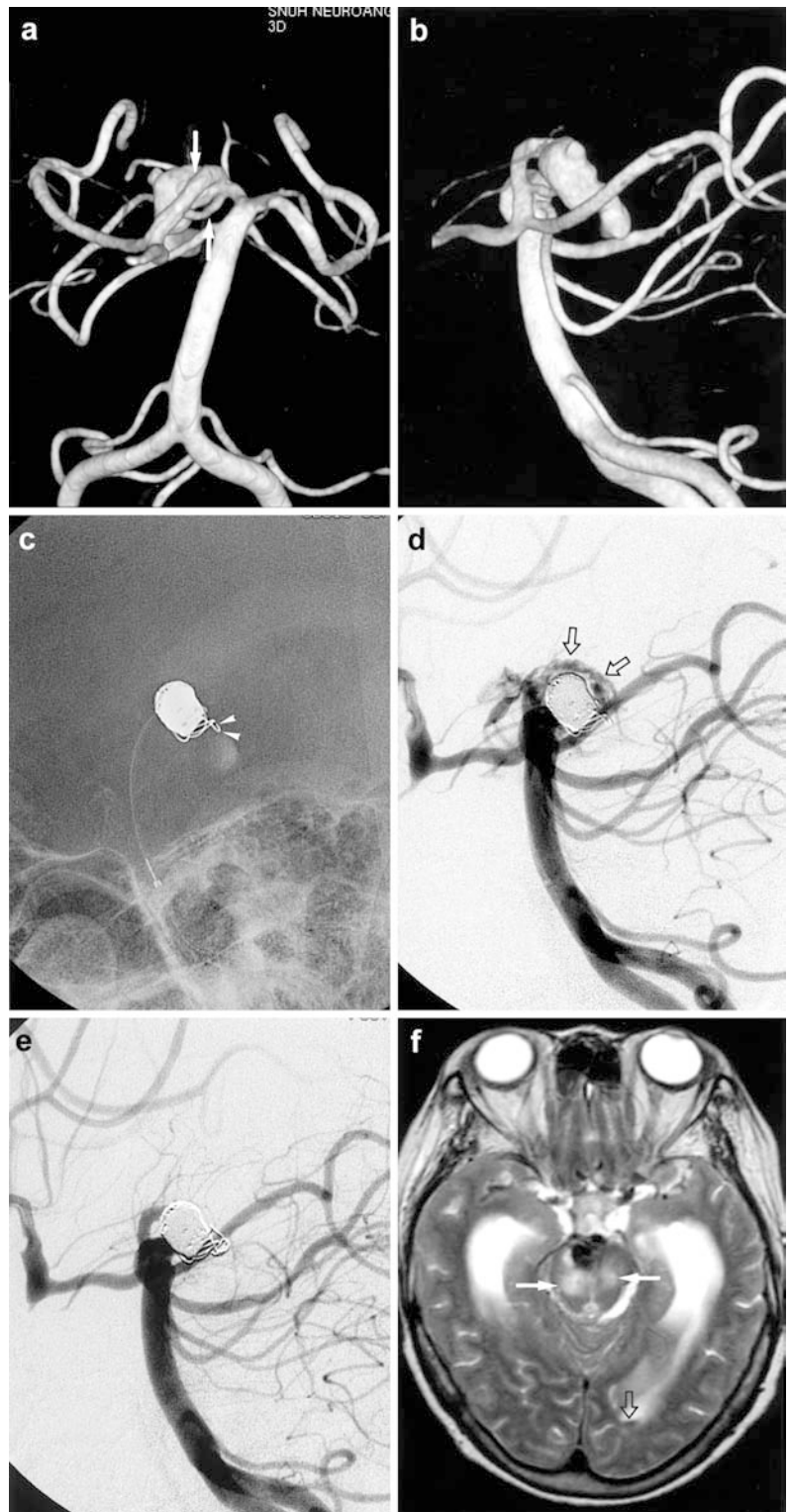
subarachnoid aneurysm trial) indicated that endovascular treatment reduced relative and absolute risk of dependency or death, compared with neurosurgical treatment, suggesting that endovascular coiling be the treatment option for the patient with a ruptured intracranial aneurysm amenable to surgical clipping or endovascular coiling.

Endovascular treatment has its own morbidity and mortality, which are lower than those of surgery [18, 19, 20]. Thromboembolic (4.5–8%) and haemorrhagic (2–5%) complications are the most frequent and serious complications. The former can be treated by immediate thrombolysis, which might decrease the morbidity of endovascular treatment. When a haemorrhagic complication was detected, we routinely performed a well-accepted protocol: heparin reversal with intravenous injection of 10 mg protamine sulphate per 1000 IU heparin; completion of coiling until total occlusion, with disappearance of extravasation of contrast medium; and emergency ventricular drainage if required. In spite of

this, the mortality of procedure-related bleeding has been reported as 20–50% [4, 5, 6].

Posterior circulation aneurysms, poor neurological grade pre-embolisation, and clinical and angiographic findings showing prolonged systemic hypertension, and persistent extravasation or increased transit time of contrast medium are related to poor prognosis. Tummala et al. [5] reported that all three of their patients with posterior circulation aneurysms died; this may be attributable to transient brain-stem ischaemia, sudden increase in infratentorial pressure, inadequacy of pressure relief by supratentorial ventricular drainage, or upward brain-stem herniation. When haemorrhage occurred, there was transient arrest of flow angiographically and abrupt rise of systolic blood pressure in all cases. The only one of four patients reported by Ricolfi et al. [6] who died had posterior inferior cerebellar artery aneurysm and angiographic evidence of flow arrest. After perforation of the aneurysm, all patients in these two small series underwent the routine

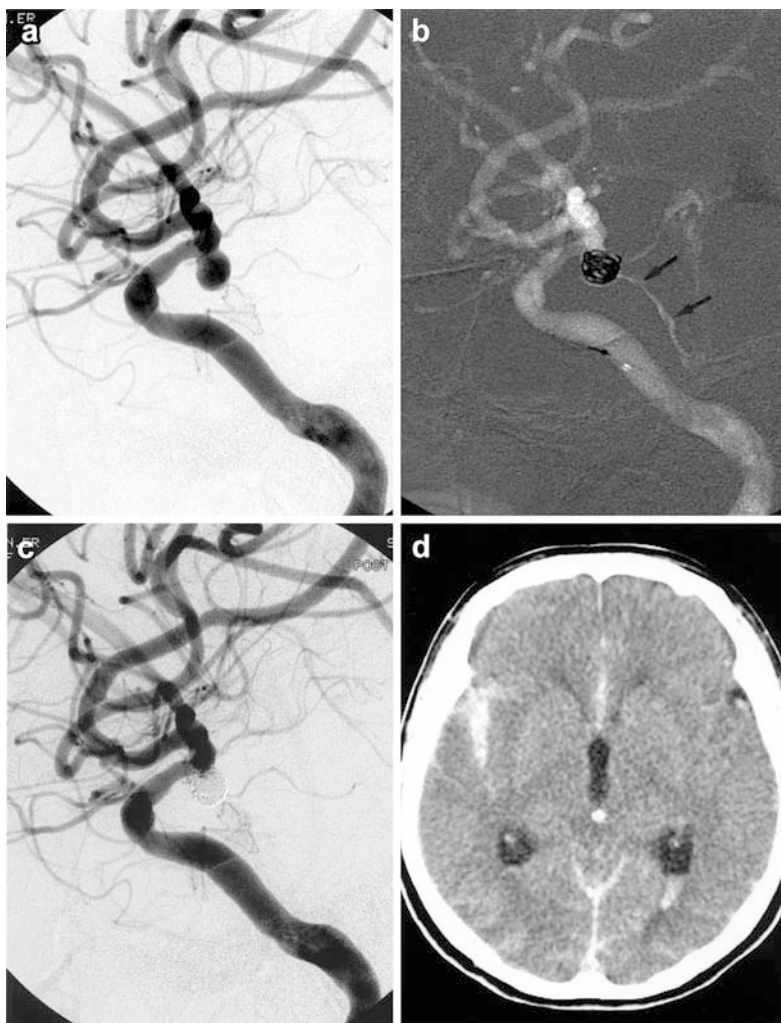
Fig. 2a–f Patient 3. Haemorrhage during coiling with extravasation of contrast medium and a sudden rise in systolic blood pressure. **a, b** Three-dimensional angiography shows two fenestrated P1 segments (*arrows*) with an elongated ruptured aneurysm. **c, d** On lateral images the most proximal straight segment of the fifth GDC 10 SynerG-2D 3×8 protruded through the wall (*arrowheads*), and there was undoubted extravasation of contrast medium (*open arrows*) around the coil mass. Systolic blood pressure rose suddenly by 80 mm Hg, and we promptly gave 30 mg protamine sulphate promptly injected. Insertion of one additional GDC 10-SynerG-soft 2×2 was enough to stop extravasation **e**, and the blood pressure simultaneously became normal. **f** An axial T2-weighted image 10 days later showed high signal in the midbrain (*arrows*), presumed due to ischaemia, and minimal intraventricular blood (*open arrows*). The patient had a third nerve palsy on discharge



management steps. The only death reported by Doerfler et al. [4] in a series of four anterior and one posterior circulation aneurysms was with an aneurysm in an anterior location, which bled during the first coiling; the

patient was immediately transferred to the operating theatre for clipping, while in the other four cases coiling, with a good outcome. Incomplete coiling might be a reason why death supervened.

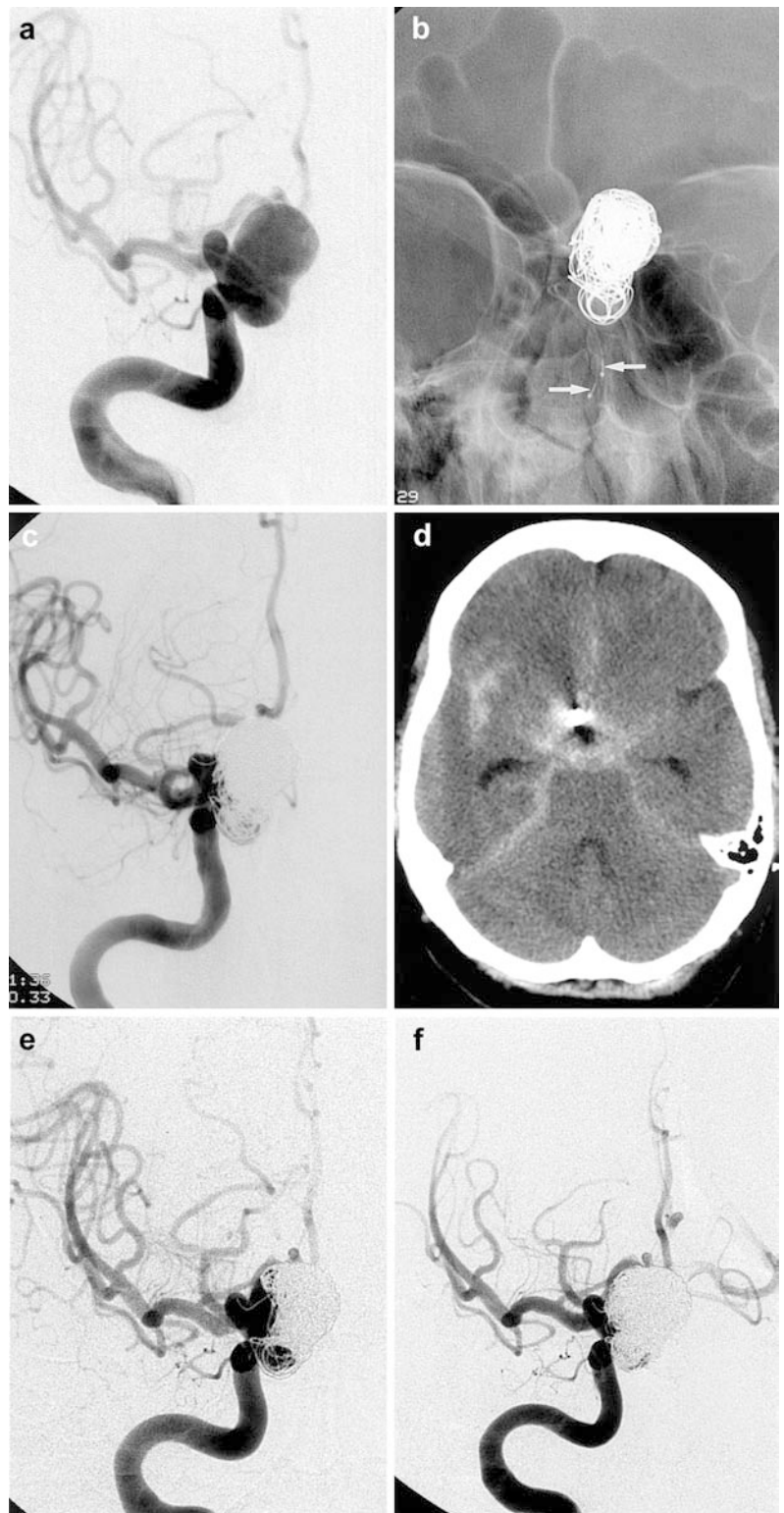
Fig. 3a–d Patient 4. Haemorrhage during catheterising an aneurysm, with extravasation of contrast medium and slight elevation of systolic blood pressure. **a** A ruptured aneurysm at the origin of the posterior communicating artery. To catheterise the aneurysm were advanced an Excelsior catheter and an Agility 14 wire to it, whereupon the tip of the wire suddenly passed through its wall. **b** One GDC was promptly inserted into the aneurysm, using on a roadmap image which showed active extravasation of contrast medium (*arrows*). Systolic blood pressure rose by 30 mm Hg. We placed two further were placed to exclude the aneurysm from the circulation and stop the extravasation. **c** Angiography showed subtotal occlusion of the aneurysm and no extravasation. At the end of the procedure systolic blood pressure was normal. **d** CT immediately after the procedure revealed high density in the subarachnoid space



In our series there were no prognostic factors related to death except location on the posterior circulation. All four patients with ruptured aneurysms were in Hunt and Hess grades 1 or 2. In six cases, we had inserted at least four coils when bleeding occurred, so that leakage of blood leakage may have been much less than it would at earlier stages of the procedure. In two of four patients with angiographic leakage, we performed further coiling to halt extravasation; in the other two cases extravasation stopped spontaneously. Raised systolic blood pressure resolved during the procedure in all cases and there was no arrest of flow in the internal carotid artery. We assume that the bleeding being of short duration and occurring in the later stages of the procedure may explain why the outcome was much better than in other reports. The lack of procedure-related deaths may be explained by our closely observing the patients' neurological status and performing external ventricular drainage immediately after occlusion of ruptured aneurysms, to lower raised intracranial pressure.

In a meta-analysis [21], the risk of aneurysm perforation during GDC therapy was much higher (4.1%) in patients with ruptured than in those with unruptured aneurysms (0.7%), confirming for the first time the impression that ruptured aneurysms are more vulnerable to haemorrhagic complications ($P < 0.001$). But in our study the frequency of procedure-related haemorrhage was not different between ruptured and unruptured aneurysms (2.3% vs. 2.3%). Excluding unusual delayed postprocedure haemorrhage, our frequency of procedure-related haemorrhage was similar to that in the meta-analysis (0.8%) [21]. Considering the definition of a procedure-related haemorrhagic complication (inconsistent or lacking in previous studies) as extravasation of contrast medium on angiography, this occurred only with ruptured aneurysms and was much lower, 1.3%, in our study. Our two patients with large unruptured aneurysms had unusual clinical and radiological findings: no accident during the procedure; effective embolisation; delayed seizures or headache and vomiting within 24 h.

Fig. 4a–f Patient 7. Delayed haemorrhage with signs of meningeal irritation during the night following the procedure. **a** A large paraclinoid aneurysm causing decrease of visual acuity was treated **b** with the double microcatheter technique (*arrows*), and incompletely occluded with a partial protective effect **c**. Later that day the patient complained of headache and vomited; angiography the following day revealed no evidence of haemorrhage. **d** CT showed thick high-density material in the subarachnoid space. Emergency ventricular drainage was instituted and recovery was good. **e** After 6 months the sac had enlarged with compaction of the coil mass, and **f** a second embolisation was performed, with almost total occlusion



Because a large area of coil surface was in contact with the blood in the parent artery, we maintained systemic heparinisation to twice-normal aPTT until bleeding occurred. We cannot why there was bleeding at this late

stage. But, in certain sites aneurysms could become fragile or injured by devices, which might be related to swaying or unidentified movement of the tip of a microcatheter tip in a wide-necked or large aneurysm, and

arterial pulsation might induce minimal haemorrhage during extended heparinisation. There is no previous report of this phenomenon.

In addition to previous rupture, small size is a factor associated with perforation of an aneurysm during endovascular treatment [3, 6, 22]. Raymond and Roy [3] suggested that the risk of rupture could be minimised if acutely ruptured aneurysms smaller than 3 mm were not treated using GDC, because rupture was most frequent with smaller (2 mm in one axis) and acutely ruptured (< 48 h) lesions. With the exception of those showing no extravasation of contrast medium, all our aneurysms were less than 6 mm in one axis and treated within 14 days.

To avoid procedure-related complications, neurointerventionists should also understand that the more complicated the devices and techniques to be used, the higher the risks. In a report of technical problems with new designs [23], the fourth generation of GDC, the

SynerG or SynerG-SR systems, could be responsible for spontaneous detachment, backwards slipping of the coil into the microcatheter lumen after detachment and unwanted detachment with a segment of the coil remaining in the parent artery. It was proposed, from an in-vitro study, that a stiff, long (1–3 mm) proximal segment of the coil could cause technical problems, and that interventionists take particular care to avoid excessive pressure of the proximal segment on the aneurysm wall when treating small aneurysms using the SynerG-SR GDC. Although we could not say that the SynerG or SynerG-SR GDC was directly associated with procedure-related haemorrhage, forceful advancing of the coil against the wall of the aneurysm wall might induce rupture during coiling. We saw no haemorrhagic complication in the pre-SynerG era, and our seven patients all underwent treatment with the new generation of GDC.

References

- Viñuela F, Duckwiler G, Mawad M (1997) Guglielmi detachable coil embolization of acute intracranial aneurysm: perioperative anatomical and clinical outcome in 403 patients. *J Neurosurg* 86: 475–482
- Valavanis A, Machado E, Chen JJ (1996) Aneurysm rupture during GDC treatment: incidence, management and outcome. *Neuroradiology* 38 [Suppl 2]: 45
- Raymond J, Roy D (1997) Safety and efficacy of endovascular treatment of acutely ruptured aneurysms. *Neurosurgery* 41: 1235–1246
- Doerfler A, Wanke I, Egelhof T, et al (2001) Aneurysmal rupture during embolization with Guglielmi detachable coils: causes, management, and outcome. *AJNR* 22: 1825–1832
- Tummala RP, Chu RM, Madison MT, Myers M, Tubman D, Nussbaum ES (2001) Outcomes after aneurysm rupture during endovascular coil embolization. *Neurosurgery* 49: 1059–1066
- Ricolfi F, Guerinell CL, Blustajn J, et al (1998) Rupture during treatment of recently ruptured aneurysms with Guglielmi electrodetachable coils. *AJNR* 19: 1653–1658
- McDougall C, Halbach VV, Dowd C, Higashida R, Larsen D, Hieshima G (1998) Causes and management of aneurysmal hemorrhage occurring during embolization with Guglielmi detachable coils. *J Neurosurg* 89: 87–92
- Murayama Y, Viñuela F, Duckwiler GR, Gobin YP, Guglielmi G (1999) Embolization of incidental cerebral aneurysms by using the Guglielmi detachable coil system. *J Neurosurg* 90: 207–214
- Phatouros CC, Halbach VV, Malek AM, Dowd CF, Higashida RT (1999) Simultaneous subarachnoid hemorrhage and carotid cavernous fistula after rupture of a paraclinoid aneurysm during balloon-assisted coil embolization. *AJNR* 20: 1100–1102
- Solander S, Ulhoa A, Viñuela F, et al (1999) Endovascular treatment of multiple intracranial aneurysms by using Guglielmi detachable coils. *J Neurosurg* 90: 857–864
- Ng P, Khangure MS, Phatouros CC, Bynevelt M, ApSimon H, McAuliffe W (2002) Endovascular treatment of intracranial aneurysms with Guglielmi detachable coils: analysis of midterm angiographic and clinical outcomes. *Stroke* 33: 210–217
- Roy D, Milot G, Raymond J (2001) Endovascular treatment of unruptured aneurysms. *Stroke* 32: 1998–2004
- Saveland H, Hillman J, Brandt L, et al (1993) Causes of morbidity and mortality, with special reference to surgical complications, after early aneurysm operation: a prospective, one-year study from neurosurgical units in Sweden. *Acta Neurol Scand* 88: 254–258
- Nishimoto A, Ueta K, Onbe H, et al (1985) Nationwide co-operative study of intracranial aneurysm surgery in Japan. *Stroke* 16: 48–52
- Raaymakers TW, Rinkel GJ, Limburg M, et al (1998) Mortality and morbidity of surgery for unruptured intracranial aneurysms: a meta-analysis. *Stroke* 29: 1531–1538
- Hadeishi H, Yasui N, Suzuki A (1991). Risks of surgical treatment for unruptured intracranial aneurysms. *No Shinkei Geka* 19: 945–949
- Johnston JC, Wilson CB, Halbach VV, et al (2000) Endovascular and surgical treatment of unruptured cerebral aneurysms: comparison of risks. *Ann Neurol* 48: 11–19
- Johnston SC, Zhao S, Dudley RA, et al (2001) Treatment of unruptured cerebral aneurysms in California. *Stroke* 32: 597–605
- Johnston SC, Dudley RA, Gress DR, et al (1999) Surgical and endovascular treatment of unruptured cerebral aneurysms at university hospitals. *Neurology* 52: 1799–1805
- International Subarachnoid Aneurysm Trial (ISAT) Collaborative Group (2002) International Subarachnoid Aneurysm Trial (ISAT) of neurosurgical clipping versus endovascular coiling in 2143 patients with ruptured intracranial aneurysms: a randomised trial. *Lancet* 360: 1267–1274
- Cloft HJ, Kallmes DF (2002) Cerebral aneurysm perforations complicating therapy with Guglielmi detachable coils: a meta-analysis. *AJNR* 23: 1706–1709
- Sluzewski M, Bosch JA, van Rooij WJ, Nijssen PCG, Wijnalda D (2001) Rupture of intracranial aneurysms during treatment with Guglielmi detachable coils: incidence, outcome, and risk factors. *J Neurosurg* 94: 238–240
- Kwon OK, Han MH, Lee KJ, Koh YC, Oh CW, Han DH (2002) Technical problems associated with new designs of Guglielmi detachable coils. *AJNR* 23: 1269–1275