

## Case report

# Valproate induces reversible factor XIII deficiency with risk of perioperative bleeding

Pohlmann-Eden B, Peters CNA, Wennberg R, Dempfle CE. Valproate induces reversible factor XIII deficiency with risk of perioperative bleeding.

Acta Neurol Scand 2003; 108: 142–145. © Blackwell Munksgaard 2003.

The antiepileptic drug valproic acid (VPA) induces subclinical changes in both the intrinsic and extrinsic coagulation system. However, fatal bleeding is very rare. This study reports a 39-year-old patient who underwent selective amygdalohippocampectomy because of drug-resistant temporal lobe epilepsy. Preoperatively, the patient was on a combined therapy with VPA and topiramate, and routine coagulation laboratory parameters were entirely normal. Epilepsy surgery was immediately followed by severe intracranial bleeding events which prompted repeated craniectomy. Extensive laboratory analyses revealed a factor XIII activity level of 17%, indicating factor XIII deficiency confirmed by a reduced XIIIa-antigen. After termination of treatment with VPA, factor XIII levels returned to normal. Control examinations after 9 and 24 months showed normal range values for all coagulation parameters, including factor XIII, platelet function, and von Willebrand factor. To our knowledge, this case is the first description of a well-documented, clinically relevant transient factor XIII-deficiency syndrome related to VPA treatment.

Valproic acid (VPA) is a frequently used antiepileptic drug with strong efficacy against a wide spectrum of generalized and focal seizures. VPA induces subclinical changes in both the intrinsic and extrinsic coagulation system. It is controversial if these effects are dose-related or idiosyncratic. These changes may include impaired platelet function, thrombocytopenia, reduced serum fibrinogen, significant decrease in von Willebrand factor antigen (1) or very seldomly a decrease in the vitamin K-dependent factors II, VII, IX, X, protein C and S (2). However, fatal bleeding seems to be very rare. The described haematological toxicities may vary in onset and severity, are recurrent, transient or persistent, and have been found most often with VPA levels > 100 µg/ml.

Factor XIII is a protein transglutaminase found both in platelets and in plasma. Being activated at the end of the clotting cascade, it converts the non-covalent fibrin polymer into a covalently cross-linked structure with increased tensile strength and resistance to fibrinolysis (3). Factor XIII is activated by thrombin in the presence of calcium ions.

Polymeric fibrin acts as cofactor in factor XIII activation (4).

While inherited factor XIII deficiency is a well-known disorder and often leads to severe bleeding (in particular intracranial haemorrhage, in up to 30%) by early childhood, the presence of an acquired factor XIII deficiency remains a doubtful entity (3). Factor XIII-deficiency states have not been described with VPA and are not screened for by routine techniques. The following case is presented to illustrate the severe sequelae of acquired factor XIII deficiency in the setting of intracranial surgery.

## Materials and methods

Report of a case

We report on a 39-year-old male with a long-standing history of temporal lobe epilepsy refractory to all available antiepileptic drugs of first and second choice, both in high dosage monotherapy and combined. The patient had a

**B. Pohlmann-Eden<sup>1,3</sup>,  
C. N. A. Peters<sup>1</sup>, R. Wennberg<sup>3,4</sup>,  
C. E. Dempfle<sup>2</sup>**

<sup>1</sup>Departments of Neurology, and <sup>2</sup>Internal Medicine (I) of Mannheim Clinic, University of Heidelberg, Heidelberg, Germany, <sup>3</sup>Toronto Western Hospital, and <sup>4</sup>Bloorview Epilepsy Program, University of Toronto, Canada

Key words: valproate; factor XIII deficiency; perioperative bleeding; epilepsy surgery

Bernd Pohlmann-Eden, Toronto Western Hospital, University of Toronto, 5W-443, 399 Bathurst St., Toronto, ON M5T 2S8, Canada  
Tel.: (416) 603 5800 ext. 6225  
Fax: (416) 603 5768  
e-mail: pohleden@gmx.net

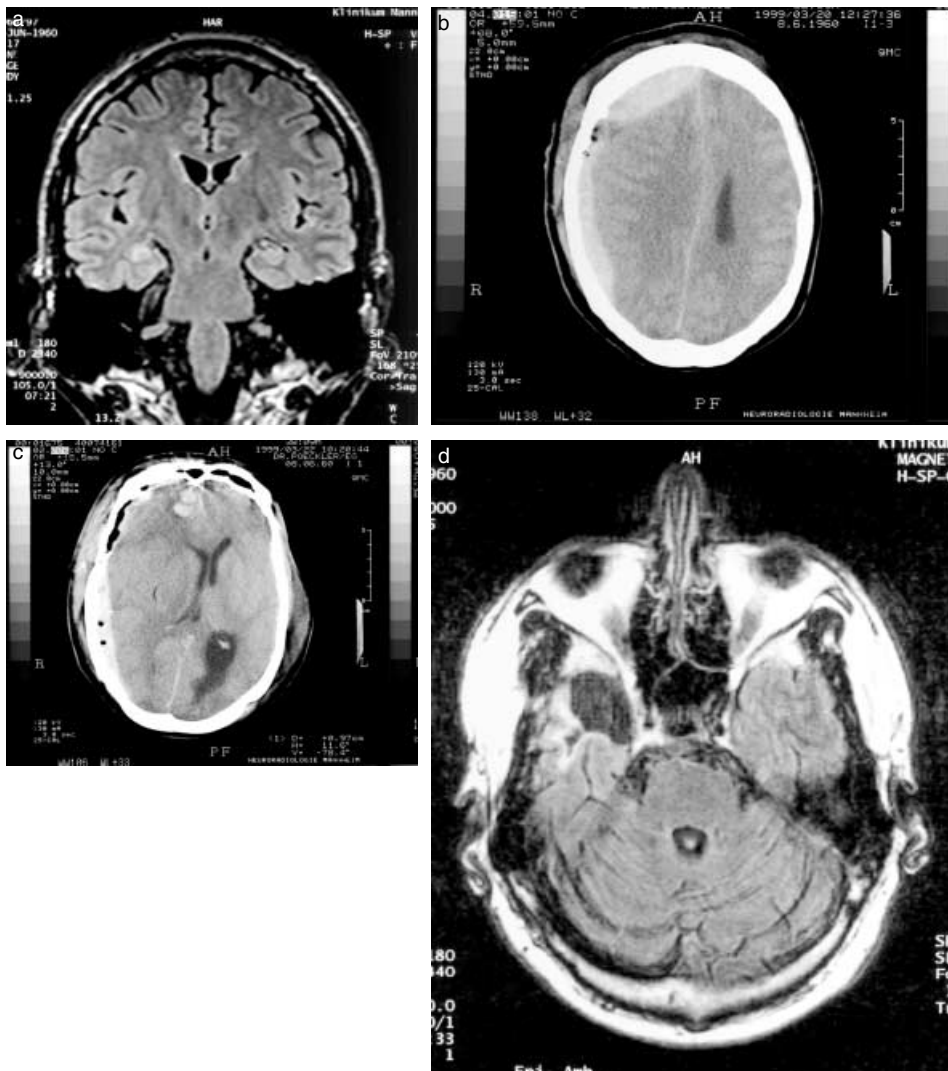
Accepted for publication December 23, 2002

documented seizure frequency of up to 20 per month. The seizure semiology analysed by long-term video-electroencephalography (EEG) monitoring revealed typical stereotyped complex partial seizures with sudden impairment of consciousness, initial tonic posturing of the left arm, staring, brief bilateral hypermotoric movements of the legs and a disorientation for 3–5 min. The clinical examination was normal.

In concordance with the hypothesis of a right mesiobasal epileptogenic area, the interictal and ictal EEG showed localized epileptiform activity with phase reversal at Sp2 (right sphenoidal electrode). The T2 signal increase in the right hippocampal formation on high resolution magnetic resonance imaging (MRI) (Fig. 1a) and

the decrease of N-acetyl-aspartate (NAA) in the magnetic resonance spectroscopy in the same region were strongly suggestive of right hippocampal sclerosis. The patient, therefore, underwent right temporal amygdalohippocampectomy using a modified selective transsylvian-transcisternal approach for mesial *en bloc* resection (5).

At the time of surgery the patient was on a combined daily therapy with 300 mg topiramate and 1500 mg VPA. The preoperative serum level of VPA was in the therapeutic range of 54 mg/dl. VPA had been started 14 months before, initially in combination with lamotrigine, which was tapered off after 8 months because of lack of efficacy. VPA was well tolerated during the entire course without obvious side-effects, in particular



**Figure 1.** Series of cranial MRIs and CTs pre- and post-operatively and during bleeding complication under valproate-induced factor XIII deficiency. (a) Preoperative MRI with right hippocampal T2-signal increase. (b) Initial CT on day 1 after epilepsy surgery with large right epidural haematoma prompting craniectomy. (c) CT on day 4 with right frontal bleeding, recurrence of the right epidural haematoma, signs of severe increased intracranial pressure including midline shifting leading to osteoclastic craniectomy. (d) Post-operative MRI 1 year later with typical defect after right amygdalohippocampectomy.

without any evidence for a coagulopathy or indication of selective factor XIII measurements. There was no past history of bleeding events caused by trauma or elective surgery.

Preoperative extensive laboratory analysis of the coagulation system [prothrombin time (PT), partial thromboplastin time (PTT), thrombin time, fibrinogen, platelet count, platelet function, anti-thrombin (AT) III, von Willebrand factor antigen and ristocetin cofactor assay] was entirely normal. The preoperative assessment of factor XIII deficiency was not performed.

Because of impaired consciousness post-operatively, cranial CT was performed, which showed a large right epidural haematoma (Fig. 1b). This prompted immediate craniectomy. Four days later a repeat decompressive craniectomy had to be performed because of increasing intracranial pressure (ICP) caused by intracerebral bleeding and persistent epidural haematoma with severe midline shifting (Fig. 1c). The patient was sedated and unresponsive at this stage and a third osteoclastic craniectomy was necessary. This finally led to normalization of intraparenchymal ICP, reversal of midline shifting and slow resorption of intracerebral bleedings on day 21. Figure 1d shows the long-term control MRI with the circumscribed post-operative defect caused by amygdalohippocampotomy.

**Results**

Repetition of the preoperatively normal coagulation parameters revealed no pathology after the primary bleeding event. An additional assay (6) for a photometric determination of factor XIII (Hitachi 904 photometric autoanalyzer, San Jose, CA, USA) indicated a significant factor XIII-deficiency syndrome with a markedly reduced activity level of 17% (Table 1). The findings were confirmed by determination of factor XIIIa-antigen by ELISA, yielding a result in a similar range. After immediate termination of treatment with VPA on day 2 after the operation with subsequent switch to iv phenyt-

oin treatment and repeated substitution with factor XIII concentrate (day 2, 2500 international equivalents (IE); day 6, 1250 IE; and day 15, 1500 IE) factor XIII levels gradually returned to normal (Table 1). After discharge, phenytoin was administered orally with further recovery of the patient and later combined with gabapentin. For unknown reason, the patient was restarted on additional oral valproate for 4 months during his rehabilitation process. At this time point, a slightly decreased factor XIII value of 65% was found, 6 months after the operation (Table 1). VPA was tapered off again and control examinations after 9 and 24 months showed normal range values for all coagulation parameters, including factor XIII (Table 1), platelet function and von Willebrand factor.

**Discussion**

To our knowledge, this case record illustrates for the first time a well-documented, clinically relevant transient factor XIII-deficiency syndrome most likely due to VPA treatment and with no evidence for an inherited disorder. The causal relationship is also supported by the fact that discontinuation of VPA led to a slow recovery of factor XIII values and that brief episodes of repeat oral VPA treatment again induced a slightly decreased factor XIII value detected at month 6. This observation is, in particular, important, as this syndrome is not detected by conventional assays for assessment of coagulation, such as PT or PTT. Preoperative screening only includes determination of factor XIII activity if there is a significant history of bleeding.

A recent prospective trial in children treated with VPA has revealed a remarkable percentage of subclinical factor XIII-deficiency syndromes (7) giving additional support for the hypothesis of a VPA-induced factor XIII-deficiency syndrome. The pathobiochemical background of factor XIII reduction is not known. A decreased synthesis by liver and megakaryocytes, the site of synthesis of plasma and platelet factor XIII, or an increased

**Table 1** Post-operative prolonged and isolated decrease of factor XIII with repetitive substitution with factor XIII concentrate (\*1250 to 2500 I.E.)

Coagulation test	Normal range unit/%	Day 1	Day 3	Day 4	Day 5	Day 6	Day 13	Day 18	Day 20	6 months	9 months	24 months
Factor XIII	70–120%	17*	35*	92	76	59	38*	52*	103	65	84	96
AT III	70–120%	69		73	86			111				
Prothrombin time	>70%	84	85		92	96	71					
aPTT	20–35s	27.0	32.3	25	27	26	28	27				
Fibrinogen	140–400 mg/dl		282	260	278	290	266	452				
Platelet count	150–440 × 10 <sup>9</sup> /l		72,000	118,000		170,000						
Factor VIII AAG/vWF	>70%		123									
D-dimer	<0.5 mg/l		0.65	0.64								

consumption/breakdown of factor XIII in circulation, or direct inhibitory effect of VPA or its metabolites on the activity of protein glutaminases (such as factor XIII) are possible, but still speculative mechanisms.

Acquired factor XIII-deficiency syndromes are a matter of on-going debate and have been reported as case reports in various diseases including sepsis, disseminated intravascular coagulation, hepatic failure, inflammatory bowel disorders, Schoenlein-Hennoch purpura and haematological disorders such as leukaemia and myelodysplastic syndrome (8). Severe bleeding events, however, were only observed in operations with increased blood losses, e.g. after cardiac surgery (9). In a recent retrospective analysis of 1264 patients (10) undergoing neurosurgical procedures, a total of 20 patients (1.6%) suffered from a significant post-operative haemorrhage; in eight of these 20 patients factor XIII deficiency states were diagnosed post-operatively. However, all of them were very mild in a range of  $43 \pm 8.4\%$  (compared with 17% in this study) with highly variable time points of measurements and no profile. All operations were major interventions with massive blood loss, compared with the present case with a selective amygdalohippocampectomy. The authors also could not exclude that the underlying pathology, which was a brain tumour in most of these patients, had a significant impact on this coagulopathy.

Whether VPA should be discontinued prior to elective surgery is still controversial. While many established epilepsy centres recommend stopping VPA treatment before operation, recent studies did not find any evidence for an increase of blood loss during temporal lobectomy (11) or a higher incidence of bleeding complications in patients undergoing cortical surgery after preoperative VPA administration (12).

### Conclusion

The illustrated case emphasizes the need for more systematic and controlled studies of coagulation

parameters in patients undergoing VPA treatment, including measurements of factor XIII activity. If abnormalities are detected and elective surgery is planned, VPA treatment should be avoided.

### References

1. ZELLER JA, SCHLESINGER S, RUNGE U, KESSLER C. Influence of valproate monotherapy on platelet activation and hematologic values. *Epilepsia* 1999;**40**:186–9.
2. TEICH M, SUCH E, DEMPFLER CE, KÖNIG S. Mangel an vitmain-K-abhängigen gerinnungsfaktoren: eine valproat-assoziierte koagulopathie. *Epilepsieblätter* 2001;**14**:13–14.
3. ANWAR R, MIŁOSZEWSKI A. Factor XIII deficiency. *Br J Haematol* 1999;**107**:468–84.
4. LORAND L. Sol sherry lecture in thrombosis: research on clot stabilization provides clues for improving thrombolytic therapies. *Arterioscler Thromb Vasc Biol* 2000;**20**:2–9.
5. VAJKOCZY P, KRAKOW K, STODIECK S, POHLMANN-EDEN B, SCHMIEDEK P. A modified approach for the selective treatment of temporal lobe epilepsy: transsylvian-transcisternal mesial en bloc resection. *J Neurol Neurosurg Psych* 1998;**88**:855–62.
6. FICKENSCHER K, AAB A, STUBER W. A photometric assay for blood coagulation factor XIII. *Thromb Haemost* 1991;**65**:535–40.
7. KÖNIG S., DEMPFLER EC. Factor XIII-deficiency syndrome in children with epilepsy treated with valproate. *J Neurol* 2003;(in print).
8. EGBRING R, KRONIGER A, SEITZ R. Factor XIII deficiency: pathogenic mechanisms and clinical significance. *Semin Thromb Hemost* 1996;**22**:419–25.
9. SHAINO JR, ESTAFANOUS FG, YARED JP, DiBELLO PM, KOTTKE-MARCHANT K, LOOP FD. Low factor XIII levels are associated with increased blood loss after coronary artery bypass grafting. *J Thorac Cardiovasc Surg* 1994;**108**:437–45.
10. GERLACH R, RAABE A, ZIMMERMANN M, SIEGEMUND A, SEIFERT V. Factor XIII deficiency and postoperative hemorrhage after neurosurgical procedures. *Surg Neurol* 2000;**54**:260–4; discussion 264–5.
11. WARD MW, BARBARO NNM, LAXER KD, RAMPIL IJ. Preoperative valproate administration does not increase blood loss during temporal lobectomy. *Epilepsia* 1996;**37**:98–101.
12. ANDERSON GD, LIN YX, BERGE C, OJEMANN GA. Absence of bleeding complications in patients undergoing cortical surgery while receiving valproate treatment. *J Neurosurg* 1997;**87**:252–6.