

Brief Communication

Prolonged Cortical Electrical Depression and Diffuse Vasospasm Without Ischemia in a Case of Severe Hemiplegic Migraine During Pregnancy

Pedro Gonzalez-Alegre, MD; Jon Tippin, MD

The pathophysiology of the neurological deficits in hemiplegic migraine remains unclear. Both neurogenic and vascular etiologies have been proposed to explain this phenomenon. We present the case of a patient with hemiplegic migraine in whom there was no diffusion weighted magnetic resonance imaging evidence of cerebral ischemia, despite persistent left hemiplegia and diffuse vasospasm on cerebral angiography, there was no diffusion weighted magnetic resonance imaging evidence of cerebral ischemia. In addition, hypoperfusional changes were seen diffusely, more so on the less symptomatic hemisphere, whereas depression of cortical electrical activity was seen for several days on the right side. These findings support the notion that although both neurogenic and vascular changes occur in hemiplegic migraine, the former seems to be a more likely explanation for the neurological deficits.

Key words: hemiplegic migraine, cortical spreading depression, vasospasm, SPECT, EEG

Abbreviations: CSD cortical spreading depression, DWI-MRI diffusion weighted magnetic resonance imaging, CSF cerebrospinal fluid, CT computerized tomography, MRI magnetic resonance imaging, MRA magnetic resonance angiography, SPECT single photon emission computerized tomography, EEG electroencephalogram

(*Headache* 2003;43:72-75)

Hemiplegic migraine is classified under migraine with typical aura or prolonged aura by the International Headache Society classification.¹ In severe cases, it can be characterized by aphasia, fever, or even coma, in addition to hemiplegia and sensory loss, and may persist for days to weeks.² The mechanism by which these focal deficits occur is unknown, but 2 hypotheses have been posited to explain these phenomena: regional ischemia due to vasospasm and neuronal hypoexcitability caused by “cortical spreading depression” (CSD).^{3,4} We present the case of a patient with severe hemiplegic migraine who had evidence of diffuse large artery vasospasm, cerebral hy-

popperfusion, and depressed cortical electrical activity that was unaccompanied by signs of ischemia on diffusion weighted magnetic resonance imaging (DWI-MRI). These findings support the notion that although both vascular and neurogenic processes occur in this form of migraine, CSD is the likely mechanism for the neurological deficits.

CASE HISTORY

Our patient is a 23-year-old right-handed woman who had her first episode of hemiplegic migraine at the age of 10. A typical migraine would begin with right visual field flickering, then be followed by right hemi-hypesthesia and progressive hemiparesis that would ultimately lead to hemiplegia. She also reported a concomitant language disturbance that probably reflected an expressive aphasia. These symptoms were immediately followed by a right-sided throbbing headache that was associated with photophobia, phonophobia, nausea, and vomiting. After-

From the Department of Neurology, University of Iowa College of Medicine, Iowa City, IA.

Address all correspondence to Dr. Pedro Gonzalez-Alegre, Department of Neurology, University of Iowa College of Medicine, 200 Hawkins Drive, Iowa City, IA 52242.

Accepted for publication August 23, 2002.

ward, she invariably went to sleep, and upon awakening a few hours later, would note complete resolution of all symptoms. Over the ensuing 13 years, she had 7 additional migraines that were all very similar in character, except for the penultimate episode at the age of 20 from which it took her 2 days to recover. A previous evaluation for ischemic cerebrovascular disease showed heterozygosity for the Factor V Leiden allele with abnormal protein C resistance and a trivial patent foramen ovale by transesophageal echocardiography. The remainder of her evaluation, including antinuclear antibody, coagulation profile, rheumatoid factor, anticardiolipin antibodies, antithrombin III, protein S, complete blood count, electrolytes, and cerebrospinal fluid (CSF) examination, was within normal limits. Both computerized tomography (CT) and magnetic resonance imaging (MRI) of the brain had been done on several occasions and were consistently normal. She was symptom free from 1997 until March 2000, when while in the 38th week of her first pregnancy, she presented to a local hospital with an episode of visual aura and mild left hemiparesis followed by right sided throbbing headache, nausea, and vomiting. Head CT was again normal, and she was treated with sumatriptan and hydroxyzine, then subsequently went into spontaneous labor. All of her neurological symptoms persisted throughout an otherwise uncomplicated delivery. MRI and magnetic resonance angiography (MRA) of the brain and brainstem obtained 2 days later showed meningeal enhancement over the right hemisphere, with no other abnormalities. She was transferred to our hospital 5 days after the onset of her symptoms because of persistent headache and worsening hemiparesis.

Past medical history was noncontributory except for alopecia of unclear etiology since childhood. She had smoked a pack of cigarettes a day until the age of 20, 3 years before her last migraine. She did not consume alcohol or use illicit drugs, and was not exposed to any toxins, but took multiple vitamins regularly. She was adopted and did not have information about her biological family.

Physical examination on admission to our hospital showed a temperature of 36.3°C, a heart rate of 67/minute, a respiratory rate of 18/minute, and a blood pressure of 138/70 mmHg. The general exami-

nation was remarkable only for generalized alopecia. On the neurological examination, she was alert and oriented. Her speech was slow but not dysarthric. Language, attention, and fund of knowledge were felt to be normal. Cranial nerve testing disclosed a homonymous hemianopia, facial hemihyesthesia, and supranuclear facial paresis on the left. Motor exam showed a flaccid left hemiplegia with hyperreflexia, and an ipsilateral Babinski sign. Her coordination was intact on the right. She was unable to walk because of the hemiplegia. She also had diminished pain and touch sensation, and astereognosis on the left. A lumbar puncture showed a normal opening pressure, 17 white blood cells (10 neutrophils, 7 monocytes, and 1 lymphocyte), 17 red blood cells, a protein of 37 mg/dL, and a glucose of 50 mg/dL (simultaneous serum glucose 91 mg/dL). Gram stain, cryptococcal antigen, detection of herpes simplex virus by polymerase chain reaction, and cultures were all negative. Complete blood count, erythrocyte sedimentation rate, electrolytes, calcium, magnesium and phosphorus, tests of renal and hepatic function, C reactive protein, coagulation profile, urinalysis, and arterial blood gases were all within normal limits. Brain MRI with DWI (Fig. 1, A and B), MRA, and MR venography were normal except for the previously noted meningeal enhancement that was markedly improved compared with that seen in the study performed 3 days earlier. A 4-vessel cerebral angiogram showed smoothly tapered narrowing of multiple intracranial arteries (bilateral supra- and paraclinoid internal carotid arteries; anterior, middle, and posterior cerebral, and basilar arteries). The extracranial arteries were normal. Cerebral single-photon emission CT (SPECT) on day 6 showed diffuse hypoperfusion of the left cerebral hemisphere compared with the right and nonhomogeneous perfusion of the right cerebral hemisphere, especially in the posterior region (Fig. 1C). An electroencephalogram (EEG) showed diffuse, irregular theta-delta activity over both hemispheres, worse on the right, slowing of the posterior dominant rhythm to 6 to 8 Hz, and marked attenuation of all activity on the right. She was admitted to the intensive care unit for treatment of vasospasm with pressors, hemodilution, and hypervolemia, as well as nimodipine and dexamethasone. She gradually improved

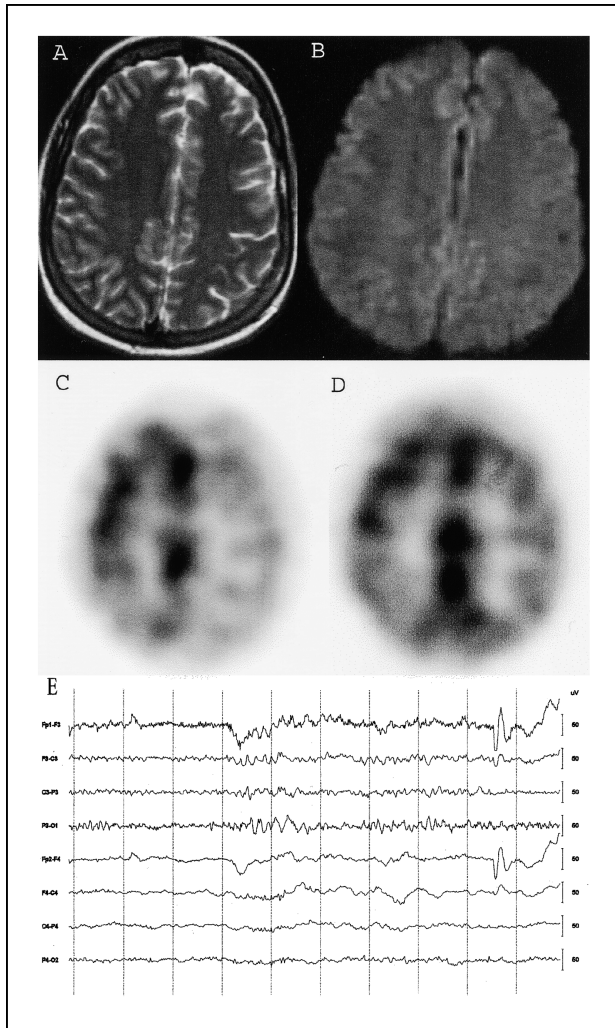


Fig. 1.—T2 (A) and diffusion-weighted (B) MRI performed on day 5 shows no areas of infarction. SPECT from days 6 (C) and 12 (D) show diffuse hypoperfusion, worse on the left. EEG performed on day 12 (E) demonstrates bilateral delta activity and attenuation of faster activities on the right. Bandpass 1.6 to 70 Hz, 1-second time divisions.

over the next few days, but continued to have residual hemiparesis and hemisensory loss, as well as a mild headache. Transcranial Dopplers were normal, showing no evidence of persistent vasospasm. A follow up SPECT performed 12 days after onset of symptoms showed interval improvement, although evidence of residual hypoperfusion remained (Fig. 1D). However, EEG's obtained on days 12 and 19 continued to show bilateral slowing and right hemispheric attenuation (Fig. 1E). She was discharged on day 20 with only a mild headache, and subtle hemiparesis

and hemisensory loss. She was seen in follow-up by her primary care provider the following month at which time she had completely recovered. Follow-up EEG and SPECT were planned, but she tragically died in a motor vehicle accident 5 months after her hospitalization.

COMMENTS

Our patient presented during pregnancy with an episode of prolonged, severe hemiplegic migraine, an atypical variant of migraine with aura that has been described previously.² Hemiplegic migraine may occur during pregnancy in women with or without a previous history of this condition, usually in the third trimester.^{5,6} The biological basis of migraine with associated neurological deficits is unknown, but current thinking suggests that episodes are initiated by neural events in the brainstem.⁷ This is felt to occur in predisposed individuals with interictal central neuronal hyperexcitability, as shown by electrophysiological, hemodynamic, and metabolic studies.⁸ The role of focal ischemia in the genesis of the neurological deficits experienced by some patients is controversial, with some authors emphasizing ischemia as the primary mechanism.³

The presence of our patient's predominantly unilateral symptoms and absence of increased signal on DWI-MRI after several symptomatic days argues against ischemia as the basis for the neurological deficits, despite diffuse macrovascular involvement on angiography. DWI-MRI has been shown to have a sensitivity of 100% in cases of persistent brain ischemia,⁹ making the likelihood of symptomatic ischemia in our patient very remote. EEG attenuation, as noted in our patient, may result from decreased cerebral blood flow, but usually only at levels that, if persistent, would lead to infarction.¹⁰ The absence of signs of infarction on DWI-MRI strongly argues that primary neuronal dysfunction due to CSD was the mechanism responsible for both the EEG attenuation and neurological deficits. CSD has been shown to be associated with marked reduction in cortical neuronal electrical activity and subsequent decline in blood flow.¹¹ The presence of oligemia was corroborated in our patient by hypoperfusional changes on SPECT that, interestingly, were actually worse contralateral to the symptomatic hemisphere. Despite

prolonged cerebral oligemia, no evidence of infarction was seen after several days of continuing focal neurological deficits. It should be pointed out, however, that hypoperfusion, even if a secondary phenomenon, could cause infarctions in some patients with migraine.¹²

In contrast, Barbour et al reported the case of a 31-year-old woman who developed clinical symptoms similar to those of our patient during the 36th week of her pregnancy.⁶ Because of cortical enhancement on MRI and changes consistent with hyperperfusion on SPECT, they concluded that vasodilatory hyperperfusion was the cause of their patient's neurological deficits. Similar findings have been recently reported in a child with hemiplegic migraine by Masuzaki et al.¹³ The apparent disagreement between these cases and the one we present may suggest that there are different pathophysiologic mechanisms producing the same clinical picture in different patients, or simply that hyper- and hypoperfusion occur at different points in time of the same process. Olesen et al has shown that temporal changes in CBF do occur during episodes of migraine with aura, but hypoperfusion accompanies the development of the aura, whereas subsequent hyperperfusion typically is unassociated with symptoms.¹⁴ Note that neither of the 2 SPECT scans performed in our patient showed evidence of hyperperfusion.

In conclusion, the normal DWI-MRI in our patient associated with generalized but asymmetrical hypoperfusal changes on SPECT and unilateral EEG attenuation over the symptomatic hemisphere argues that CSD rather than ischemia was the cause of the neurological deficits in this case of hemiplegic migraine. Oligemia due to CSD likely represented a secondary phenomenon that was not directly related to the development of our patient's deficits.

REFERENCES

1. Headache Classification Committee of the International Headache Society. Classification and diagnostic criteria for headache disorders, cranial neuralgias and facial pain. *Cephalalgia*. 1988;8(suppl 7):1-96.
2. Munte TF, Muller-Vahl H. Familial migraine coma: a case study. *J Neurol*. 1990;237:59-61.
3. Skyhoj Olsen T, Friberg L, Lassen NA. Ischemia may be the primary cause of the neurologic deficits in classic migraine. *Arch Neurol*. 1987;44:156-161.
4. Leao AAP. Spreading depression of activity in the cerebral cortex. *J Neurophysiol*. 1944;7:359-390.
5. Mandel S. Hemiplegic migraine in pregnancy. *Headache*. 1988;28:414-416.
6. Barbour PJ, Castaldo JE, Shoemaker EI. Hemiplegic migraine during pregnancy: unusual magnetic resonance appearance with SPECT scan correlation. *Headache*. 2001;41:310-316.
7. Weiler C, May A, Limmroth V, Juptner M, Kaube H, Schayck RV, Coenen HH, Diener HC. Brain stem activation in spontaneous human migraine attacks. *Nat Med*. 1995;1:658-660.
8. Welch KMA, D'Andrea G, Tepley N, Barkley G, Ramadan NM. The concept of migraine as a state of central neuronal hyperexcitability. *Neurol Clin*. 1990;8:817-828.
9. Barber PA, Darby DG, Desmond PM, Gerraty RP, Yang Q, Li T, Jolley D, Donnan GA, Tress BM, Davis SM. Identification of major ischemic change. Diffusion-weighted imaging versus computed tomography. *Stroke*. 1999;30:2059-2065.
10. Sundt TM, Sharbrough FW, Piepgras DG, Kearns TP, Messick JM, O'Fallon WM. Correlation of cerebral blood flow and electroencephalographic changes during carotid endarterectomy: with results of surgery and hemodynamics of cerebral ischemia. *Mayo Clin Proc*. 1981;56:533-543.
11. Lauritzen M, Jorgensen MB, Diemer NH, Gjedde A, Hansen AJ. Persistent oligemia of rat cerebral cortex in the wake of spreading depression. *Ann Neurol*. 1982;12:469-474.
12. Welch KMA, Levine SR. Migraine-related stroke in the context of the International Headache Society classification of head pain. *Arch Neurol*. 1990;47:458-462.
13. Masuzaki M, Utsunomiya H, Yasumoto S, Mitsu-dome A. A case of hemiplegic migraine in childhood: transient unilateral hyperperfusion revealed by perfusion MR imaging and MR angiography. *Am J Neuroradiol*. 2001;22:1795-1797.
14. Olesen J, Friberg L, Skyhoj Olsen T, Iversen HK, Lassen NA, Andersen AR, Karle A. Timing and topography of cerebral blood flow, aura, and headache during migraine attacks. *Ann Neurol*. 1990;28:791-798.