



CASE STUDY

Cerebral injury in association with profound iatrogenic hyperglycemia in a neonate

Daryl Efron^a, Mike South^a, Joseph J. Volpe^d, Terrie Inder^{a,b,c,d,*}

^aDepartment of Paediatrics, University of Melbourne, Royal Children's Hospital, Melbourne, Australia

^bMurdoch Children's Research Institute, Melbourne, Australia

^cHoward Florey Institute, Melbourne, Australia

^dDepartment of Neurology, Harvard Medical School, Boston Children's Hospital, Boston, USA

Received 13 February 2003; received in revised form 27 March 2003; accepted 28 April 2003

KEYWORDS

Hyperglycemia; Glucose metabolism; Cerebral injury

Summary The adverse effect of hyperglycemia on neurological outcome following cerebral ischemia has been established in both experimental and adult human studies. However, there is a paucity of data to assess this risk in the human infant. This case is the first to describe severe and prolonged iatrogenic hyperglycemia in association with ischemia in an infant who sustained a major cerebral lesion. The topography of the predominant cerebral injury, i.e., bilateral parieto-occipital cortex and subcortical white matter, shown by magnetic resonance imaging was similar to that documented in the hypoglycemic infant, suggesting a similarity in regional cerebral vulnerability to altered glucose metabolism. This case extends recognition of the risk of severe hyperglycemia in association with cerebral ischemia to the newborn and suggests also that the posterior cerebral predilection for injury is similar in both hypoglycemia and hyperglycemia.

© 2003 European Paediatric Neurology Society. Published by Elsevier Science Ltd. All rights reserved.

Introduction

Hyperglycemia has been established to worsen neurological outcome following cerebral ischemia in mature animal models.¹ Considerable data in adult human subjects also indicate that hyperglycemia worsens post-ischemic outcome in both focal and global cerebral insults.² Hyperglycemia

occurring prior to the cerebral insult provides the greatest adverse impact on outcome.³ In contrast, controversy exists concerning the impact of hyperglycemia on cerebral ischemia in the immature brain.⁴ Some experimental data in immature animal models suggest a beneficial role for abundant glucose administered prior to or during cerebral ischemia.^{5,6} This beneficial effect of hyperglycemia in the immature brain has been postulated to reflect a preservation of mitochondrial energy production and enhanced utilization of lactate by the immature brain. However, other animal data have shown an exacerbating influence on ischemic cerebral injury in association with

*Correspondence: Terrie Inder MD, Associate Professor, Murdoch Children's Research Institute and Howard Florey Institute, Royal Children's Hospital, Flemington Road, Parkville, Australia. Tel.: +61-3-9345-4830; fax: +61-3-9345-4840.

E-mail address: terrie.inder@rch.org.au

hyperglycemia.⁶⁻⁹ Despite these inconsistencies there are no human data concerning the risk of hyperglycemia with ischemia on neonatal brain.

This report is the first published case providing evidence of a major adverse effect of severe hyperglycemia in association with circulatory collapse in a newborn.

Case report

A 4-week-old infant boy (corrected post-conceptual age 41 weeks) was admitted to hospital with a 24 hour history of vomiting. He had been born by normal vaginal delivery at 37 weeks gestation following an uncomplicated pregnancy to a G2P1 mother. There were no concerns at birth or in the first 3 weeks of his life. On admission initial studies revealed a mild metabolic alkalosis (pH 7.44, pCO₂ 44 mmHg, bicarbonate 29 mmol/l, base excess 4 mmol/l) but no electrolyte disturbance (sodium 139 mmol/l, potassium 5.3 mmol/l, chloride 106 mmol/l). The vomiting progressed to become projectile and frequent, and a diagnosis of pyloric stenosis was made clinically and supported by ultrasound examination. He was assessed clinically as less than 5% dehydrated, and an intravenous fluid infusion ordered as 50% dextrose in 0.45% saline was commenced at 24 ml/hour (150 ml/kg/day).

After 6 hours of intravenous fluids, his mother was concerned that he appeared pale and lethargic, with dry lips. His cranium exhibited prominently overriding sutures. Five hours later (i.e., after 11 hours of infusion) he developed clonic seizures and became apneic. He had severely compromised peripheral perfusion, and his blood pressure could not be recorded although a heart rate > 100 bpm was always present. He was resuscitated with endotracheal intubation and ventilation with high flow oxygen, and a bolus of normal saline (20 ml/kg). He responded with improved pulse volume and peripheral perfusion. He did not receive external cardiac compression. He was transferred to the intensive care unit, where his initial studies showed pH 7.05, pCO₂ 74 mmHg, bicarbonate 20 mmol/l, base excess -11 mmol/l, sodium 156 mmol/l, potassium 1.9 mmol/l, chloride 132 mmol/l, urea 2.5 mmol/l, creatinine 0.05 mmol/l, serum osmolality 465 mosm/kg, glucose 105 mmol/l (1.891 mg/dl) and lactate 7.3 mmol/l.

It was then discovered that an error had been made in the ordering and administration of his intravenous fluids. The infant had received 50% dextrose, rather than 5% dextrose in 0.45% saline.

In retrospect it was ascertained from his parents that following the intravenous infusion his diapers had been much heavier than normal, consistent with increased urine output.

An insulin infusion of 0.05 units/kg/hour was commenced, and after 2 hours his glucose was 83 mmol/l, serum osmolality 463 mosm/kg. The insulin infusion was then ceased and rehydration was continued with normal saline. By 8 hours his plasma glucose had returned to the normal range. The hypokalaemia and hypernatraemia were corrected over 8 hours and 4 days respectively. The serum osmolality gradually returned to normal over a week.

Seizure activity was noted clinically by 11 hours following his collapse, and over the next 2 days he had frequent clinical seizure activity requiring phenobarbitone and midazolam. Serial electroencephalograms on days 1 to 5 post-collapse demonstrated a severely suppressed background rhythm with prominent multifocal spike and sharp wave activity alternating between the left and right hemispheres. Achieving phenobarbitone levels in excess of 300 µmol/l (>7 mg/dl) terminated his clinical and electroencephalographic seizure activity. His anticonvulsant drug levels were then allowed to decrease slowly, without recurrence of significant seizure activity.

A CT brain scan 8 hours following his collapse demonstrated prominent extra-axial spaces, consistent with decreased brain volume, and decreased attenuation within the right thalamus, the right caudate head and the left parietal region. Hyperdensity within the transverse sinus on the left was suggestive of sinus venous thrombosis. Five days after his collapse an MRI scan revealed extensive signal changes involving the basal ganglia (Fig. 1A), and the parietal and occipital lobes bilaterally (Fig. 1B), consistent with infarction. There also was bilateral intraventricular haemorrhage. No abnormality in venous blood flow was present. Proton MR spectroscopy over the left basal ganglia utilizing point resolved spectroscopy (PRESS) method showed a reduction in *N*-acetylaspartate (NAA/CR 0.88; control levels in term infants $n = 8$ NAA/CR 1.92 ± 0.5) and markedly elevated lactate on short TE (35 ms) (inverting fully on longer TE (144 ms)). Quantification of the lactate undertaken at TE 144 msec showed a lactate/creatine ratio of 0.77, control lactate/creatine ratio ($n = 8$) being 0.28 ± 0.22 (Fig. 2).¹⁰ Repeat MRI scan three weeks following the insult revealed evolution of the widespread ischemic injury involving the cerebral cortex, white matter and deep nuclei. Cystic encephalomalacia had developed within the areas of previously identified infarction (Fig. 1C).

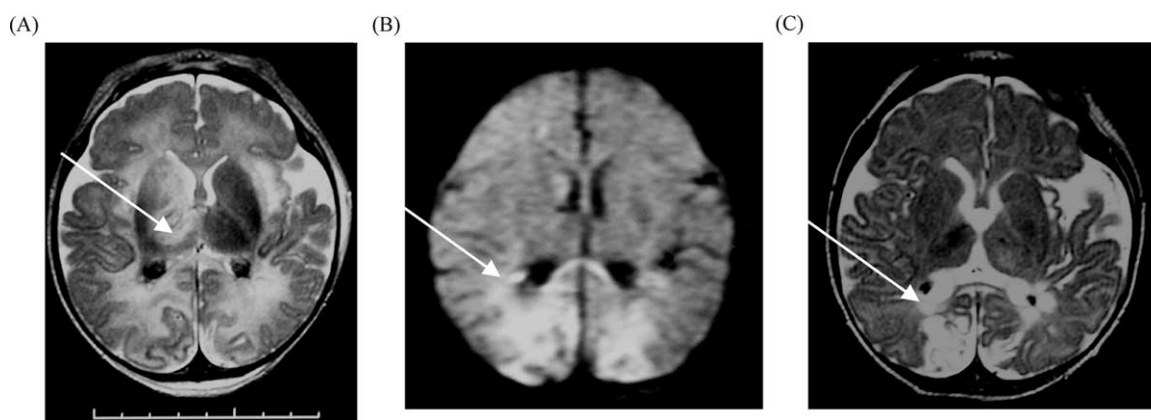


Figure 1 Axial T2-weighted magnetic resonance scan (A) of the infant on the fifth day after collapse shows bilateral intraventricular haemorrhage, with multiple signal abnormalities in the right caudate, putamen and thalamus (arrow); less severe changes are apparent in the left deep nuclear structures; bilateral signal abnormalities are apparent in the parieto-occipital cortex and subcortical white matter. Diffusion weighted imaging (B) at the same time as in 'A' shows regions of marked restriction in diffusion in the posterior cerebrum (arrow). Later axial T2-weighted imaging (C) at 2 months of age shows cystic necrosis and atrophy in the occipital regions (arrow), signal abnormality in the basal ganglia (right greater than left), and resolving intraventricular hemorrhages.

The infant was extubated 6 days post-collapse, and had normal spontaneous respirations. He sucked actively and swallowed normally, permitting normal bottle-feeding. His auditory-evoked brainstem responses 3 weeks post-collapse were within normal limits. At 6 months of age he had clinical features of microcephaly, severe cortical visual impairment, marked global developmental delay, with global hypotonia consistent with a predominant hypotonic cerebral palsy. There have been no features of choreoathetosis or dystonia. He developed infantile spasms (EEG at 4½ months

demonstrated frequent multifocal epileptiform activity), which responded to high dose vigabatrin.

Discussion

This report is the first to describe the combined cerebral effects of severe hyperglycemia and ischemia in an infant. This case extends the recognition of the risk of hyperglycemia in association with cerebral ischemia to the paediatric population and supports animal and adult human

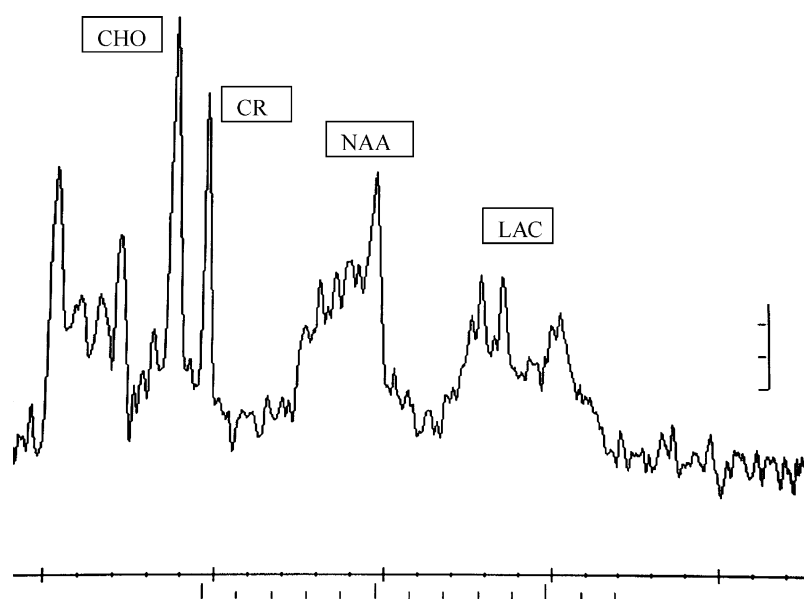


Figure 2 Proton (^1H) MR spectroscopy obtained from voxel localized to the left basal ganglia using PRESS localization, TE 35 mseconds, demonstrating reduction in *N*-acetylaspartate (NAA) and increased lactate (LAC) doublet (see arrows). Choline (CHO) and creatine (CR) are also displayed.

data highlighting the potential risk of hyperglycemia with cerebral ischemic insults.

The pattern of cerebral injury documented in our case by MRI suggests two important contributing pathogenetic mechanisms. The first contributing mechanism relates specifically to altered glucose homeostasis and is demonstrated by the unique topographic vulnerability of the posterior cerebrum, as has been previously documented in neonatal hypoglycaemia.¹¹⁻¹³ The second contributing mechanism relates to that of probable cerebral ischemia resulting in a pattern of deep nuclear injury as is most commonly associated with severe abrupt hypoxic-ischemic insult in the term infant.^{14,15} Transient T1-weighted MRI abnormalities have been documented in the basal ganglia in adults with non-ketotic hyperglycemia in association with chorea.¹⁶ However, these MRI changes have been entirely isolated to the putamen differing significantly from the global deep nuclear gray matter injury displayed in our case. Thus, in our case, it is most likely that mechanisms related to both hyperglycemia and ischemia were intimately inter-related in contributing to the pattern of basal ganglia injury.

With relation to the pattern of cerebral ischemic injury in our patient, poor cerebral perfusion secondary to severe hyperglycemia and hyperosmolality with intravascular volume depletion and systemic hypotension may have been the pivotal pathophysiological mechanism. It is also noteworthy that high glucose concentrations have been shown to impair cerebral endothelial reactivity and perhaps thereby the autoregulatory cerebral response to systemic hypotension which may have further exacerbated the lesion.¹⁷ However, the extent of the infant's cerebral injury was more severe than would have been predicted from the promptly corrected clinical cardiovascular compromise, suggesting that the hyperglycemia directly contributed to the severity of the cerebral injury.

Hyperglycemia has been well documented to produce enhanced cerebral injury in both adult human reports and animal models of ischemic brain injury.² In adult subjects experiencing ischemic brain injury, an increase in blood glucose has been associated with adverse histopathological and functional outcomes, regardless of the mechanisms of increased blood glucose.^{3,18} The mechanism of the hyperglycemia-exacerbated injury is not clear but the most common explanation for the increased brain injury has been the enhanced tissue lactic acidosis.¹⁹⁻²¹ However, the influence of hyperglycemia on brain injury in the newborn has been more variable with several studies demonstrating a beneficial effect of glucose administration prior to

or immediately after cerebral ischemia in newborn animal models.^{4,5} The beneficial effect of hyperglycemia in the immature brain may be mediated by such effects as preservation of levels of adenosine triphosphate and phosphocreatine, demonstrated directly in a newborn rat model of unilateral carotid ligation and hypoxemia.²² In contrast to the adult there may be in the immature brain a reduction in the potential deleterious effect of hyperglycemia from excessive lactate production because lactate can be utilized as an alternative energy source.²³ However if the lactate level were extremely high, this benefit may be negated. It is important to note in this context that in our case the level of lactate in the occipital white matter and in the basal ganglia was very high. The marked elevation in lactate is suggestive that potentially the hyperglycemia may have enhanced lactate accumulation, and helped mediate the adverse cerebral consequences in our case. In keeping with concerns over hyperglycemia in cerebral injury in the newborn, studies in immature animal models have raised concerns that the infant brain is vulnerable to more moderate hyperglycemia following ischemia.^{6,8,9,24} However, there have been no previously published cases in human infants demonstrating a definitive risk of hyperglycemia in potentiating ischemic cerebral injury.

MRI in this case revealed a predominantly posterior cerebral insult, similar to that recognized in the hypoglycemic infant.¹¹⁻¹³ There is no clear explanation for this distinctive regional cerebral vulnerability, but it appears from our case that hyperglycemia exacerbated ischemic cerebral injury may have a similar topography and may be mediated by similar mechanisms. However, the nature of the latter remains unclear. The topography of posterior cerebral injury does not match the pattern of normal glucose uptake in neonates, as measured by positron emission tomography,^{25,26} and suggests that the mechanism of vulnerability does not relate to glucose metabolism per se. Perhaps secondary effects develop in both hypoglycemia or hyperglycemia, such as disorders of excitatory amino acid homeostasis or secondary vascular effects.

In conclusion, this is the first published case in a newborn to demonstrate the adverse neurological effects of combined cerebral ischemia and hyperglycemia in the neonate. The striking elevations in lactate on MR spectroscopy support a potentiating role for hyperglycemia as does the topographic distribution of the injury, which is similar to that of hypoglycemic cerebral injury in the newborn. This case adds support to the guidelines for avoiding highly abnormal blood glucose levels in the newborn

infant, particularly in the setting of hypoxic-ischemic insults.

References

- Warner DS, Todd MM, Dexter F, Ludwig P, McAllister AM. Temporal thresholds for hyperglycemia-augmented ischemic brain damage in rats. *Stroke* 1995;26:655–60.
- Wass CT, Lanier WL. Glucose modulation of ischemic brain injury: Review and clinical recommendations. *Mayo Clin Proc* 1996;71:801–12.
- Pulsinelli WA, Waldman S, Rawlinson D, Plum F. Moderate hyperglycemia augments ischemic brain damage: a neuropathologic study in the rat. *Neurology* 1982;32(11):1239–46.
- Vannucci RC. Cerebral carbohydrate and energy metabolism in perinatal hypoxic-ischemic brain damage. *Brain Pathol* 1992;2(3):229–34.
- Hattori H, Wasterlain CG. Posthypoxic glucose supplement reduces hypoxic-ischemic brain damage in the neonatal rat. *Ann Neurol* 1990;28(2):122–8.
- Volpe JJ. *Neurology of the Newborn*, 4th ed. Philadelphia, PA: Saunders; 2001.
- LeBlanc MH, Huang M, Vig V, Patel D, Smith EE. Glucose affects the severity of hypoxic-ischemic brain injury in newborn pigs. *Stroke* 1993;24:1055–62.
- Sheldon RA, Partridge JC, Ferriero DM. Postischemic hyperglycemia is not protective to the neonatal rat brain. *Pediatr Res* 1992;32:489–93.
- Vannucci RC, Rossini A, Towfighi J. Effect of hyperglycemia on ischemic brain damage during hypothermic circulatory arrest in newborn dogs. *Pediatr Res* 1996;40:177–84.
- Robertson NJ, Cowan FM, Cox IJ, Edwards AD. Brain alkaline intracellular pH after neonatal encephalopathy. *Ann Neurol* 2002;52:732–42.
- Barkovich AJ, Al Ali F, Rowley HA, Bass N. Imaging patterns of neonatal hypoglycemia. *AJNR* 1998;19:523–8.
- Traill Z, Squier M, Anslow P. Brain imaging in neonatal hypoglycaemia. *Arch Dis Child Fetal Neonatal Ed* 1998;79:F145–7.
- Kinnala A, Rikalainen H, Lapinleimu H, et al. Cerebral magnetic resonance imaging and ultrasonography findings after neonatal hypoglycemia. *Pediatrics* 1999;103:724–9.
- Pasternak JF, Gorey MT. The syndrome of acute near-total intrauterine asphyxia in the term infant. *Pediatr Neurol* 1998;18:391–8.
- Roland EH, Hill A. MR and CT evaluation of profound neonatal and infantile asphyxia. *AJNR* 1992;13:973–5.
- Oh SH, Lee KY, Im JH, Lee MS. Chorea associated with non-ketotic hyperglycemia and hyperintensity basal ganglia lesion on T1-weighted brain MRI study: a meta-analysis of 53 cases including four present cases. *J Neurol Sci* 2002;200(1/2):57–62.
- Cipolla MJ, Porter JM, Osol G. High glucose concentrations dilate cerebral arteries and diminish myogenic tone through an endothelial mechanism. *Stroke* 1997;28(2):405–10.
- Longstreth WT, Inui TS. High blood glucose level on hospital admission and poor neurological recovery after cardiac arrest. *Ann Neurol* 1984;15:59–63.
- Nedergaard M, Goldman SA, Desai S, Pulsinelli WA. Acid-induced death in neurons and glia. *J Neurosci* 1991;11:2489–97.
- Smith ML, von Hanwehr R, Siesjo BK. Changes in extra- and intracellular pH in the brain during and following ischemia in hyperglycemic and in moderately hypoglycemic rats. *J Cereb Blood Flow Metab* 1986;6:574–83.
- Marsh WR, Anderson RE, Sundt TM. Effect of hyperglycemia on brain pH levels in areas of focal incomplete cerebral ischemia in monkeys. *J Neurosurg* 1986;65:693–6.
- Vannucci RC, Brucklacher RM, Vannucci SJ. The effect of hyperglycemia on cerebral metabolism during hypoxia-ischemia in the immature rat. *J Cereb Bl Fl Metab* 1996;16(5):1026–33.
- Young RS, Petroff OA, Chen B, Aquila Jr WJ, Gore JC. Preferential utilization of lactate in neonatal dog brain: in vivo and in vitro proton NMR study. *Biol Neonate* 1991;59(1):46–53.
- LeBlanc MH, Qian XB, Cai ZW. The effect of glucose during ischemia on brain ATP, lactate and glutamate in piglets. *Biol Neonate* 1997;72:243–54.
- Chugani HT, Phelps ME, Mazziotta JC. Positron emission tomography study of human brain functional development. *Ann Neurol* 1987;22:487–97.
- Chugani HT, Hovda DA, Villablanca JR, Phelps ME, Xu W-F. Metabolic maturation of the brain: a study of local cerebral glucose utilization in the developing cat. *J Cereb Bl Flow Metabol* 1991;11:35–47.