

A case of intimal hyperplasia induced by stenting for vertebral artery origin stenosis: Assessed on intravascular ultrasound

Kentaro Hayashi, Naoki Kitagawa, Minoru Morikawa* and Makio Kaminogo

Department of Neurosurgery, *Department of Radiology, Nagasaki University School of Medicine, Nagasaki, Japan

We report a case of proximal vertebral artery restenosis following stent placement. Intravascular ultrasound study helped delineate its characteristics. A 69-year-old man was admitted because of dysarthria and dysphagia. Angiography revealed hypoplasia of left vertebral artery (VA) and remarkable stenosis of the proximal right VA with inadequate collateral flow from the anterior circulation. Balloon angioplasty and stent placement at the VA was performed to an excellent angiographic result with recovery of neurological symptoms. His condition deteriorated six months later due to intimal hyperplasia, which we evaluated by intravascular ultrasound (IVUS). Balloon angioplasty was then performed. Stent placement may induce intimal hyperplasia and IVUS is useful to assess the lesion. [Neurol Res 2003; 25: 357–360]

Keywords: Vertebral artery stenosis; stent placement; intimal hyperplasia; intravascular ultrasound

INTRODUCTION

Percutaneous transluminal angioplasty (PTA) is thought to be a safe and effective procedure for the treatment of stenotic arterial lesions. Some atherosclerotic lesions have a poor response to angioplasty due to elastic recoil or early restenosis. Intraluminal stents are now widely used in the peripheral vascular system, cardiovascular system, and in the renal arteries to provide a supporting frame to keep the lumen patent and smooth walled. Stent flexibility allows for easy maneuver through curves and tortuous vessels, such as a vertebral artery (VA)¹. However, restenosis occasionally occurs in stent placement cases². Direct intravascular (IVUS) assessment may be a useful technique for detection of plaques, to determine the size of lesion and appropriate stent size during the procedure³. Additionally, an auxiliary technique for flow visualization using IVUS has been recently introduced⁴. We present a case whereby ultrasound imaging and flow imaging were utilized to identify proximal VA restenosis following stent placement. This situation illustrates the utility of IVUS and emphasizes the important role that IVUS plays in this delicate intervention.

CASE REPORT

A 69-year-old man was initially admitted to another hospital following repeated episodes of floating sensation, dysarthria and dysphasia. He gave a history of angina pectoris, hypertension, diabetes mellitus and hyperlipidemia. These symptoms were improved after

plasma expanders and antiplatelet medication. Angiography revealed proximal right VA severe stenosis and hypoplastic left VA (*Figure 1A*). Collateral flow from anterior circulation was poor. The diagnosis of the vertebrobasilar insufficiency was reached and elective endovascular recanalization was planned. After the administration of local anesthesia, 8-French sheath was introduced into the femoral artery. 8F guiding catheter was then navigated into the right subclavian artery and Avamar F/X imaging catheter (Jomed Inc., Rancho Cordova, CA, USA) was inserted to the right VA. Stenotic lumen was visualized with color flow imaging on In-Vision monitor (Jomed Inc.) (*Figure 1B*). Dilatation by 3-mm by 20-mm balloon catheter was performed. There was brief disturbance to consciousness during balloon inflation. A 4-mm by 10-mm Palmaz stent (Johnson & Johnson, Arlington, TX, USA) mounted on a 5-mm by 20-mm angioplasty balloon was then placed at the ostial origin. An angiogram following the stent placement revealed widely patent proximal VA with stent in place (*Figure 1C*). Immediately after stent placement, IVUS was performed to assess the treated vessel (*Figure 1D*). Mild arterial dissection occurred after balloon angioplasty, that was corrected by stent placement. No major peri-operative complication occurred apart from a mild transient consciousness disturbance. His symptoms improved significantly and he was maintained on warfarin and aspirin therapy. Approximately six months after stent placement, his symptom frequency and severity began to increase. Angiography revealed subocclusive restenosis on proximal portion of the stent placement (*Figure 2A*). Imaging catheter focusing at the restenosis revealed homogenous lesion inside the stent, indicating an intimal hyperplasia (*Figure 2B*). Dilatation was performed by 3-mm by 20-mm angioplasty balloon catheter under local anesthesia. This

Correspondence and reprint requests to: Kentaro Hayashi, MD, Department of Neurosurgery, Nagasaki University School of Medicine, 1-7-1 Sakamoto, Nagasaki-city, Nagasaki 852-8501, Japan. [Kentaro.Hayashi@ma8.seikyuu.ne.jp] Accepted for publication February 2003.

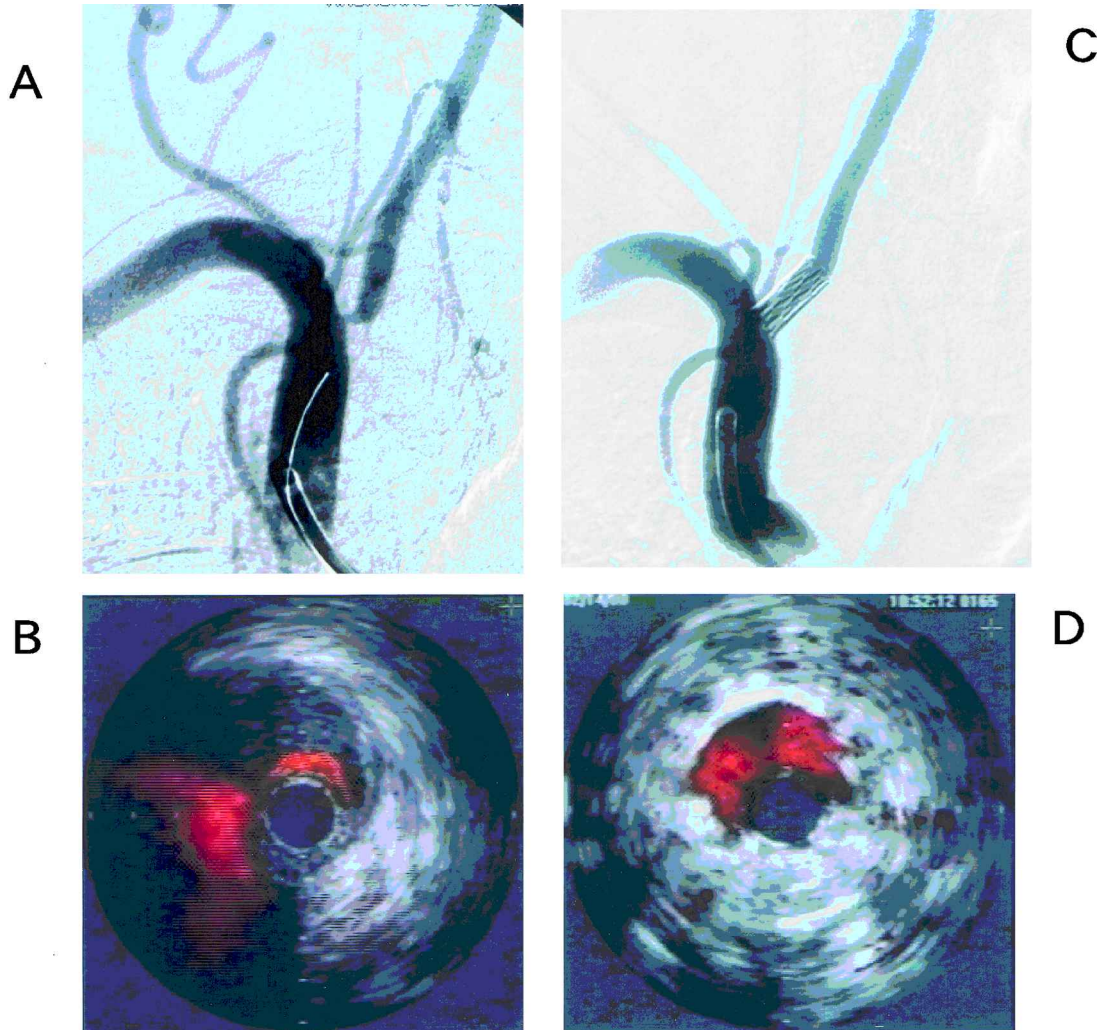


Figure 1 **A:** Right subclavian artery angiogram showing severe stenosis of VA origin. **B:** Cross-sectional IVUS image of the VA orifice. Color flow help identify stenotic lumen. The flow of subclavian artery is widely identified from 6 to 9 o'clock. **C:** Right subclavian artery angiogram immediately post-angioplasty demonstrating complete reversal of stenosis. **D:** IVUS with color flow after original deployment. Color flow areas help identify widely opened vascular lumen

resulted in a residual 10% to 20% stenosis of the origin of the right VA with acceptable blood flow (*Figure 2C,D*). There was no serious complication caused by the PTA procedure. Post-operative course was uneventful and he is doing well more than one year after the second recanalization procedure.

DISCUSSION

Restenosis is a major long-term success limiting factor after PTA procedure. The recent development of stenting has led to an evident improvement of PTA results, reducing restenosis and effecting a low morbidity and mortality⁵. Lesions of VA origin tend to restenose. Restenosis presents in a number of ways, such as from atherosclerosis, elastic recoil, stent deformity and intimal hyperplasia⁶. Atherosclerotic restenosis usually takes an indolent course⁷. Generally it takes more than one year

following the procedure. In this patient restenosis took six months to occur. Although, in this VA portion, elastic recoil is seen frequently after PTA, it is usually rare after stenting. In peripheral arteries such as carotid artery, the mechanical stress induces stent deformity. Mechanical stress from the outside seems to be unlikely since VA origin is anatomically located deep under the clavicle. Sometimes, subclavian artery or nerve get compressed by anterior scalenus muscle and middle scalenus muscle inducing thoracic outlet syndrome. The best possible cause for stent restenosis in this case is considered to be intimal hyperplasia^{6,7}. Pathophysiology of this thickening is thought to be a remodeling failure of the arterial wall along with excessive and disorderly proliferation of smooth muscle cells⁸. Local inflammation is thought to be important in the pathogenesis. Excessive arterial wall injury or stimulation during intervention may induce local inflammation. In this case, small arterial dissection

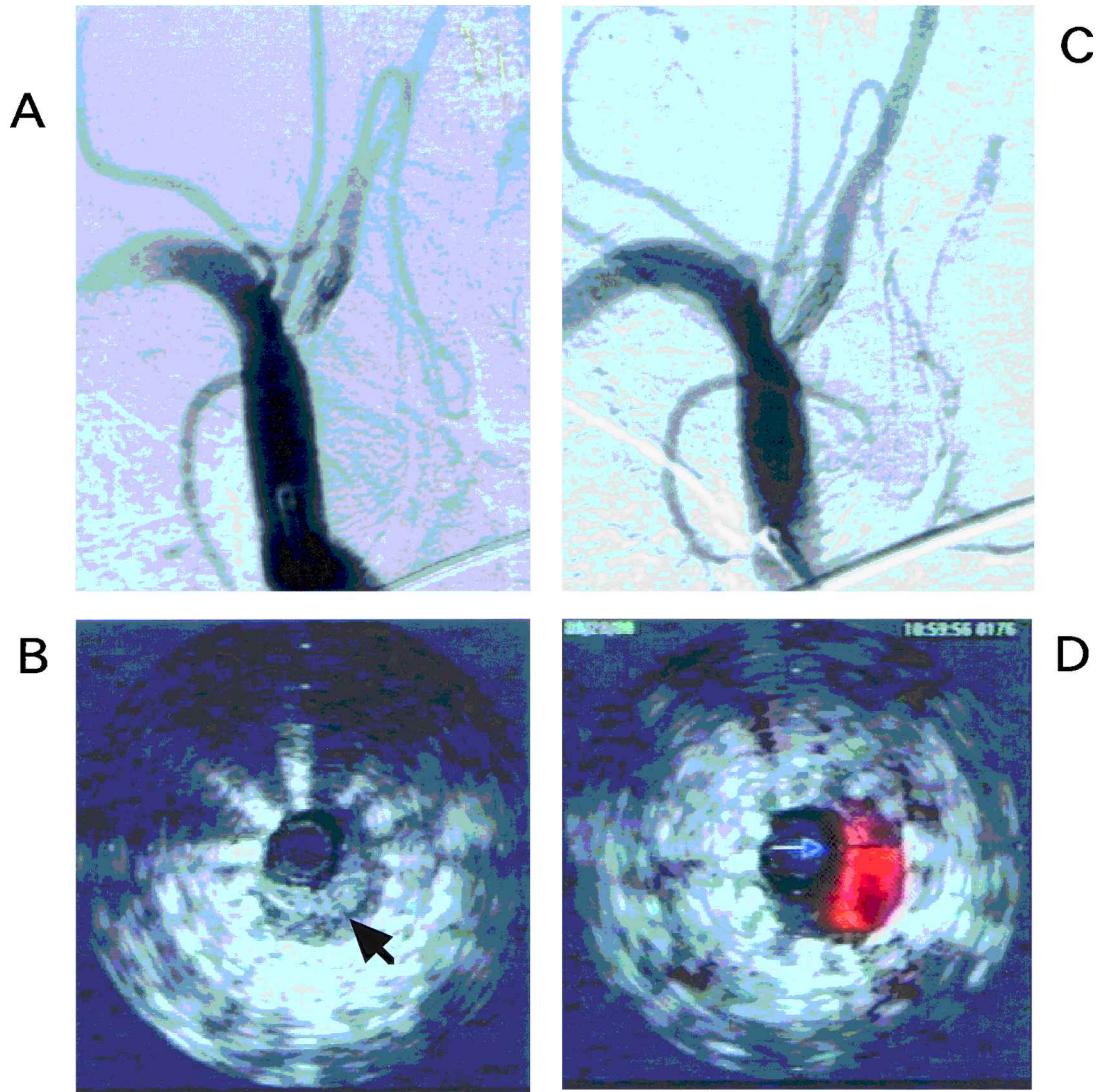


Figure 2 **A:** Right subclavian artery angiogram obtained six months post-stenting showing severe restenosis of right VA origin. **B:** Cross-sectional IVUS image of the restenotic lesion. Blood flow was not seen despite color image, because the probe was wedged to the stenotic lumen. Homogeneous lesion was detected inside the stent struts, indicating intimal hyperplasia (arrow). **C:** Right subclavian artery angiogram after second PTA. Balloon dilatation with angioplasty catheter resulted in a residual 10% to 20% stenosis of the origin of the right VA. **D:** IVUS with color flow after second PTA. Acceptable blood flow was detected

during angioplasty, which was corrected by stenting, may be associated with neointimal formation. Some animal experiments have highlighted the possibility of inhibiting the migration of smooth muscle cell by either conventional medication, gene delivery or irradiation⁹. Clinical trials are currently in progress¹⁰.

IVUS imaging provides real-time information in the interventional setting, affording a unique perspective on which to base decisions such as adequacy of balloon deployment, cross sectional percent stenosis and residual stenosis, and the creation of flaps and dissections. The operator is thus given more comprehensive data that can direct further treatment, such as redilatation or stent placement. For these reasons, IVUS is being used more frequently in the treatment and assessment of endovas-

cular lesions⁴. In this patient, restenosis appeared after six months from the stent placement, suggesting that the cause of restenosis is intimal hyperplasia. Furthermore, IVUS demonstrated the lesion inside the stent struts without stent deformity. The IVUS show us real-time, 360 degrees view of vascular lumen during the endovascular procedure. Additionally, a newly introduced color flow imaging technique can allow easy identification of the region of blood flow. More flexible monorail type probe catheters are available that make it more easy to evaluate lesions in the tortuous vessels. At present, most stents are poorly defined angiographically since they are invariably radiolucent. Thus IVUS proves its usefulness in this respect. However, the cost effectiveness is still under investigation. Therefore, the

use of IVUS is currently established at special research centers.

There are some strategies for restenosis such as surgical reconstruction or repeated PTA. Sometimes these lesions are surgically inaccessible and pose a greater potential risk. One such technique includes transection of the vessel above the stenosis, then re-implanting it either at the ipsilateral carotid artery or subclavian artery¹¹. As such, additional risks of injury to the sympathetic fibers, the phrenic, recurrent laryngeal, vagus or thoracic nerves, as well as the potential for pulmonary complications from the thoracotomy are possible¹². To minimize this, Ogawa *et al.*¹³ introduced relatively less invasive surgical reconstruction without thoracotomy or artificial heart-lung machine. By and large, PTA is now a well established therapeutic alternative to operative reconstruction of proximal VA stenosis and seems to be relatively safe. No mortality has been reported after PTA. Higashida *et al.*¹⁴ report of 34 patients who underwent angioplasty for proximal VA, where the restenosis rate was 8.8%. Restenosis cases were successfully treated by repeated balloon angioplasty. PTA is minimally invasive and it was chosen for this case. Although the patient is doing well more than one year from second procedure, the possibility of restenosis can not be definitely ruled out. Prolonged follow-up is therefore needed.

CONCLUSION

Stent placement may induce intimal hyperplasia and IVUS is useful to assess the lesion.

REFERENCES

1 Malek AM, Gigashida RT, Phatouros CC, Lempert TE, Meyers PM, Gress DR, Dowd CF, Halbach VV. Treatment of posterior circulation ischemia with extracranial percutaneous balloon angioplasty and stent placement. *Stroke* 1999; **30**: 2073–2085

2 Chastain HD, Campbell MS, Iyer S, Rousin GS, Witek J, Mathur A, Al-Mubarak NA, Terry JB, Yates V, Kretzer K, Alred D, Gomez CR. Extracranial vertebral artery stent placement: In-hospital and follow-up results. *J Neurosurg* 1999; **91**: 547–552

3 Nissen SE, Yock P. Intravascular ultrasound novel pathophysiological insight and current clinical applications. *Circulation* 2001; **103**: 604–616

4 Cespedes EI, Carlier S, Sabate M, Ligthar J, Serruys PW, Bom N. Angiographically undetected stent malapposition resolved by intravascular ultrasound and flow imaging. *J Vasc Invest* 1998; **4**: 81–84

5 Piotin M, Spelle L, Martin JB, Weill A, Rancurel G, Ross IB, Rufenacht DA, Chiras J. Percutaneous transluminal angioplasty and stenting of the proximal vertebral artery for symptomatic stenosis. *Am J Neuroradiol* 2000; **21**: 727–731

6 Storey GS, Marks MP, Dake M, Norbash AM, Steinberg GK. Vertebral artery stenosis following percutaneous transluminal angioplasty. *J Neurosurg* 1996; **84**: 883–887

7 Komatsu R, Ueda M, Naruko T, Kojima A, Becker AE. Neointimal tissue response at sites of coronary stenting in humans – microscopic, histological, and immunohistochemical analyses. *Circulation* 1998; **98**: 224–233

8 Gibbons GH, Dzau VJ. The emerging concept of vascular remodeling. *N Engl J Med* 1994; **330**: 1431–1438

9 Todaka T, Yokoyama C, Yanamoto H, Hashimoto N, Nagata I, Tsukahara T, Hara S, Hatae T, Morishita R, Aoki M, Ogihara T, Kaneda Y, Tanabe T. Gene transfer of human prostacyclin synthase prevents neointimal formation after carotid balloon injury in rats. *Stroke* 1999; **30**: 419–426

10 Ahmed JM, Mintz GS, Waksman R, Mehran R, Leiboff B, Pichard AD, Satler LF, Kent KM, Weissman NJ. Serial intravascular ultrasound assessment of the efficacy of intracoronary gamma-radiation therapy for preventing recurrence in very long, diffuse, in-stent restenosis lesions. *Circulation* 2001; **104**: 856–859

11 Spetzler RF, Hadley MN, Martin NA, Hopkins LN, Carter P, Budny J. Vertebrobasilar insufficiency. Part 1: Microsurgical treatment of extracranial vertebrobasilar disease. *J Neurosurg* 1987; **66**: 648–661

12 Imparato AM. Vertebral arterial reconstruction: A nineteen-year experience. *J Vasc Surg* 1985; **2**: 626–634

13 Ogawa A, Yoshimoto T, Sakurai Y. Treatment of proximal vertebral artery stenosis – Vertebral to subclavian transposition. *Acta Neurochir (Wien)* 1991; **112**: 13–18

14 Higashida RT, Tsai FY, Halbach VV, Dowd CF, Smith T, Fraser K, Hieshima GB. Transluminal angioplasty for atherosclerotic disease of vertebrobasilar arteries. *J Neurosurg* 1993; **78**: 192–198