

Cerebral Embolism From Atrial Myxoma in Pediatric Patients

Majeed Al-Mateen, MD*†; Margaret Hood, MD*; Don Trippel, MD*; Samuel J. Insalaco, MD*§; Randolph K. Otto, MD*; and Kari J. Vitikainen, MD*

ABSTRACT. We describe 2 children with cerebrovascular events caused by emboli from left atrial myxomas and review 7 other pediatric cases from the literature. Transient cutaneous eruptions involving the extremities preceded the cerebrovascular events and were most likely attributable to fragmentation of the atrial tumor with peripheral embolization. Our first case demonstrates the more common presentation with acute hemiplegia caused by cerebral infarction and the second case a transient ischemic attack manifested by more subtle features as a result of involvement of the vertebrobasilar circulation. Neither child had a history or other signs of cardiac disease. Atrial myxoma should be considered in the differential diagnosis when children present with neurologic symptoms or with signs of embolization, because surgical removal of the tumor is critical and may be curative. *Pediatrics* 2003;112:e162–e167. URL: <http://www.pediatrics.org/cgi/content/full/112/2/e162>; *cardiac myxoma, acute hemiplegia (in children), stroke, evanescent rash, retinal artery occlusion*.

ABBREVIATION. MRI, magnetic resonance imaging.

Cardiac myxoma is a rare cause of cerebrovascular disease, especially in children. The tumor is usually benign, and the cardiac signs and symptoms produced are related to the size and location of the tumor. Primary cardiac tumors in children are rare. Myxomas are the third most common tissue type behind rhabdomyomas and fibromas. When situated in the left side of the heart, they can lead to cerebral embolization. A high index of suspicion and familiarity with its various modes of presentation are essential for diagnosis. The neurologic manifestations consist mainly of acute focal deficits from emboli, and these may be the initial presentation of the tumor.¹ We describe 2 cases of children with histories of cutaneous eruptions that were not recognized as embolic lesions. Both were found to have left atrial myxomas only after presenting with acute hemiplegia in one case and with transient, nonlateralized neurologic deficits in the other. Description of these children and comparison with

other pediatric cases from the literature may alert others to suspect this potentially curable tumor in children who present with symptoms suggestive of cerebrovascular disease.

CASE REPORTS

Case 1

An 11-year-old, right-handed girl was admitted for acute right hemiplegia. Two months before admission, red spots of the nail beds of the right hand were noted. The spots faded, only to recur within 3 weeks in conjunction with slight swelling of the joints of the fifth digit. The swelling subsided, but the slightly erythematous spots on the nail beds persisted. She was referred to a dermatologist, who noted a few telangiectasias of her nailbeds, but her skin examination at the time of evaluation was otherwise normal. Two weeks before admission, similar lesions were noted on the soles of her feet. She had a normal complete blood count, urinalysis, and chest radiograph. Her erythrocyte sedimentation rate was 34 mm/h. She was scheduled to be evaluated by a pediatric rheumatologist. On the morning of admission, while brushing her hair, she collapsed without alteration of consciousness. She was able to walk but dragged her right leg and could not move her right arm. Her speech was garbled, and she had a right facial droop. She complained of a frontal headache, nausea, and abdominal pain en route to her local hospital, where she was unable to speak, could not move her right arm and fingers, and was unable to lift her right leg off the bed.

There was no history of recurrent headache, fever, head injury, seizures, heart disease, syncope, dizziness, or drug abuse. She was on no medications. Her birth history, growth, and development were normal. The family history was notable for systemic lupus erythematosus and migraine headaches.

On admission, her blood pressure was 138/76. Her heart rate was 94 beats/min, and she was afebrile. There were no cranial or carotid bruits. There were faint erythematous, nonhemorrhagic, nontender, punctate lesions on the lateral aspect of her left foot. Her chest was clear to auscultation. Cardiovascular examination showed a regular rhythm and no murmurs, gallops, or rubs. There was no organomegaly. She was an alert and cooperative girl. Her speech was dysarthric and limited to 1- or 2-word responses. She pointed correctly to pictures and objects. Visual fields were full to distraction. She did not have papilledema. Pupils were 4 mm, isocoric, and reactive to light. Extraocular movements were full and conjugate. There was no gaze preference or nystagmus. Corneal reflexes were intact. The right nasolabial fold was flattened, and right eye closure was decreased. There was no movement of the right upper extremity. Right iliopsoas power was 2/5, and the right tibialis anterior was 3/5. Strength on the left side was normal. Muscle stretch reflexes were 1 at the biceps and 2 at the quadriceps and equal. Plantar responses were extensor on the right and flexor on the left. Response to pinprick in the limbs and torso was symmetrical. There was no dysmetria or tremor of the left upper extremity. The initial impression was that she had an acute cerebrovascular infarction involving the left hemisphere. However, a head computerized tomography scan between 1 and 2 hours after presentation and a brain magnetic resonance imaging (MRI) scan 7 hours after presentation both were normal (not shown). Laboratory studies on admission revealed a white blood cell count of 7000 cells/ μ L, a hemoglobin of 12.9 g/dL, a hematocrit of 39.6%, and a platelet count of 333 000 cells/ μ L. The erythrocyte sedimentation rate was 40 mm/h. Serum electrolytes and

From the *Mary Bridge Children's Hospital and Health Center and Tacoma General Hospital, Tacoma, Washington; †Department of Neurology, University of Washington School of Medicine, Seattle, Washington; and §Department of Pathology, University of Washington School of Medicine, Seattle, Washington.

Received for publication Jan 6, 2003; accepted Apr 23, 2003.

Reprint requests to (M.A.-M.) Pediatric Neurology Clinic, Mary Bridge Children's Hospital and Health Center, 316 Martin Luther King Jr Way, Ste 406B, Tacoma, WA 98415. E-mail: majeed.al-mateen@muticare.org
PEDIATRICS (ISSN 0031 4005). Copyright © 2003 by the American Academy of Pediatrics.

glucose were normal. Electroencephalogram showed intermittent slow activity over the left posterior head region. A 2-dimensional echocardiogram showed a 30 × 30-mm tumor in the left atrium situated in the mitral valve orifice and partially occluding the mitral valve apparatus (Fig 1). An ophthalmologic evaluation revealed branch retinal artery occlusion of the left retina, which seemed to be recent in origin. The right eye seemed normal. MRI of the brain was repeated and showed multiple periventricular white matter and basal ganglia lesions of both hemispheres, particularly on the left side (Fig 2). White matter lesions of the left parietal and occipital regions were also noted. These were compatible with small infarcts and consistent with multiple emboli. There were no hemorrhages. Brain magnetic resonance angiography was normal. She underwent resection of the left atrial tumor. During the operation, the tumor was described as exceedingly friable with a piece of tumor being easily dislodged when attempting to retract it to obtain visualization. The surgical specimen had an irregular frond-like gelatinous surface, and microscopic section showed short stellate myxoma cells in a hypovascular myxoid matrix. There was a left hemiparesis after the operation. One month after presentation, there was no expressive aphasia, and visual fields were full to confrontation testing. A mild left central facial paresis was noted, and left upper extremity strength was 4/5. Muscle stretch reflexes were brisk and symmetrical, and she walked with slight circumduction of the left lower extremity. Strength on the right side was normal, and she was able to write legibly. Eight months after presentation, the echocardiogram showed no residual left atrial tumor.

Case 2

A 10-year-old, right-handed boy underwent neurologic evaluation because of an episode of dizziness, unsteady gait, and visual disturbance. Approximately 24 hours before he was evaluated, he had experienced slight dizziness followed by a left-sided headache, which lasted 5 minutes. He felt fine until later that evening. While he was getting out of a swimming pool, he again felt dizzy as if he were spinning. He seemed to have difficulty walking, his speech was slurred, and he was closing 1 eye because of double vision. In the emergency department, dysconjugate eye movements were reported and he was somewhat unsteady while walking. Within 2 hours, however, there were no visual, speech, or gait

disturbances. A few weeks before evaluation, he was seen by his pediatrician because of "red spots" involving the toe of the left foot. Within 1 week, the spots were gone. There was no history of headache, fever, head injury, seizures, or heart disease. He was on no medications. His birth history, growth, and development were normal. The general and neurologic examinations were normal 12 hours after presentation to the emergency department. The transient deficits were suggestive of a brainstem and cerebellar dysfunction. The head computerized tomography scan in the emergency department was normal. The brain MRI, which was obtained 11 hours after presentation, showed multiple 4- to 5-mm foci of abnormal increase in T2 signal and decreased T1 signal intensity involving the left cerebellar hemisphere and a single lesion involving the right cerebellar hemisphere. There was also a 5 × 10-mm area of abnormal increased T2 signal and decreased T1 signal in the splenium of the corpus callosum (Fig 3) and an abnormal T2 signal involving the right parietal region. There was no abnormal enhancement or mass effect. Normal vascular flow voids were present. An echocardiogram showed a 20 × 25-mm tumor in the left atrium attached to the atrial septum. He underwent surgical resection of the tumor, which was a myxoma on microscopic examination. He had no postoperative neurologic deficits, and the neurologic examination 1 month after presentation remained normal. His brother's echocardiogram was normal.

RESULTS

Table 1 shows cases from the literature. The age range was 3 to 17 years. All patients had tumors located in the left atrium. Five patients were female (55%). All but 1 of the 9 patients had right hemiparesis as a presenting feature. "Red spots" was the phrase used in the literature and by the parents of our 2 patients to describe transient cutaneous eruptions that most likely represented embolic lesions. These were present in 4 patients (44%). Three patients (33%) had retinal artery occlusion. A cardiac murmur was present in 2 patients (22%). The tumors were surgically removed in all 9 patients. One patient died 20 minutes after the opera-

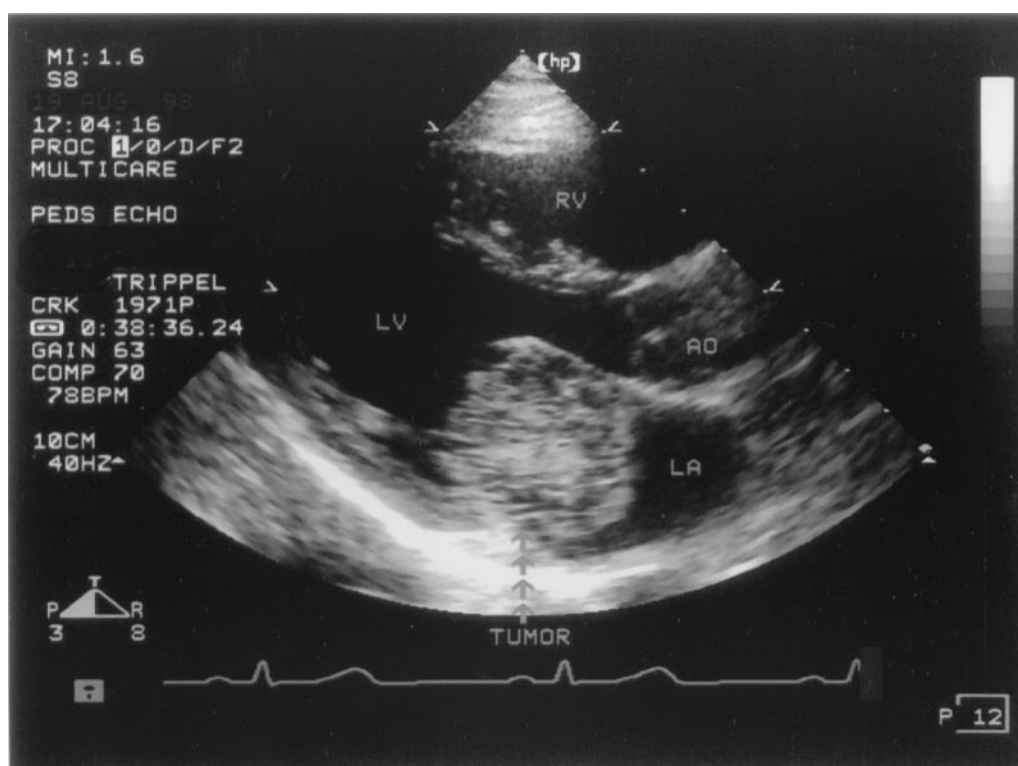


Fig 1. In case 1, 2-dimensional long-axis echocardiogram shows a tumor (myxoma) in the left atrium. It appears adherent to the mitral valve. RV indicates right ventricle; LV, left ventricle; AO, aorta; LA, left atrium.

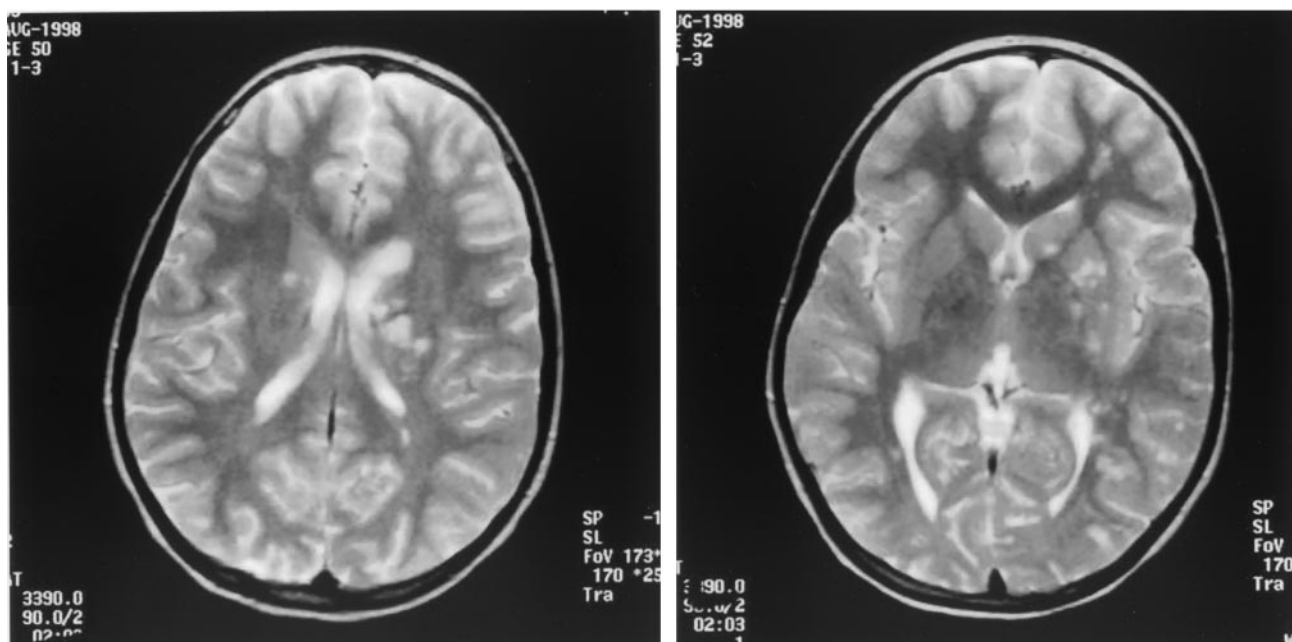


Fig 2. In case 1, T2-weighted (TR 3390, TE 90) MRI images depict numerous lesions involving the cerebral white matter of both hemispheres (left) and particularly the left basal ganglia (right).

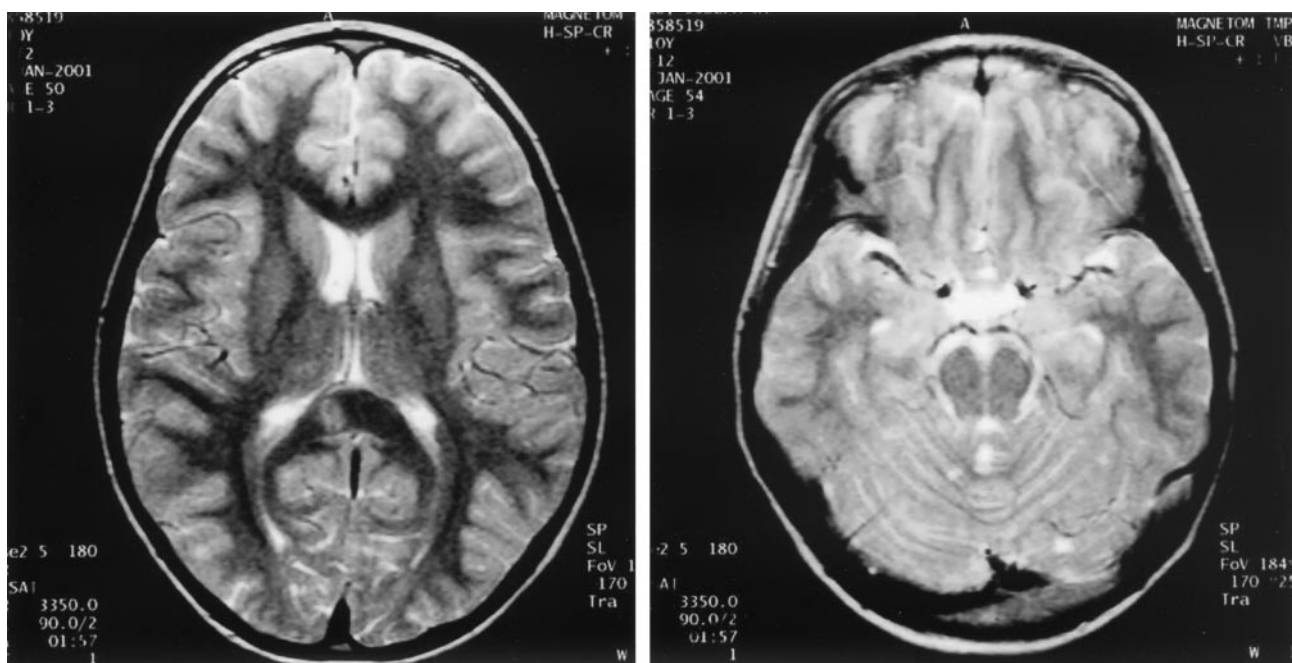


Fig 3. In case 2, T2-weighted (TR 3350, TE90) MRI images depict lesions involving the splenium of the corpus callosum (left) and cerebellum (right).

tion, 6 patients had residual neurologic deficits, and 1 patient was normal.

DISCUSSION

The heart is the most common source of cerebral emboli in children, and acute hemiplegia caused by occlusion of the supraclinoid internal carotid artery and middle cerebral artery (anterior circulation) is the most common clinical presentation. Many children are already known to have heart disease before the recognition of cerebrovascular disease, but in

other instances, a less obvious cardiac lesion is discovered only after a stroke.

Atrial myxoma is listed among the acquired heart diseases as a risk factor for pediatric cerebrovascular disorders, and embolic infarction is the most common neurologic complication of atrial myxoma.² In 1952, the first antemortem diagnosis of atrial myxoma was made in a 3-year-old boy who presented with recurrent right hemiparesis.³ Subsequent reports of atrial myxoma presenting with neurologic manifestations have been described in several series

TABLE 1. Clinical Summary of 9 Children With Cardiac Myxoma and Cerebrovascular Infarction

Reference	Age (Years)/ Gender	Location of Tumor	Presentation	Other Embolic Signs	Cardiac Murmur	Brain Imaging	Outcome After Surgical Removal of Myxoma
3 7	3/M 17/M	Left atrium Left atrium	Right hemiparesis Right hemiparesis, lethargy headache	Red spots left foot None	No No	None Angiogram: left MCA occlusion CT: left intracerebral hemorrhage angiogram: small fusiform aneurysm of right MCA	Died Mild right hemiparesis, dysphasic speech Impaired fine motor of right hand
8	15/F	Left atrium, right atrium	Right hemiparesis, headache	None	No		
9	8/M	Left atrium	Right hemiparesis, seizures, aphasia Right hemiparesis, left eye blindness	Red spots on hands and feet, retinal artery occlusion Retinal artery occlusion	No	MRI: multiple cerebral lesions CT: hypodensities in left internal capsule and corpus callosum angiogram: fusiform aneurysms left ACA, MCA	Right hemiparesis, visual impairment Right hemiparesis improved, left eye blindness, recurrence of tumor
11	14/F	Left atrium	Right hemiparesis, aphasia, slurred speech, lethargy Right hemiparesis, expressive aphasia	Cool right leg	Yes	MRI: left hemisphere lesion MRA: absent flow in left ICA, MCA MRI: left MCA infarct MRA: complete occlusion left MCA	Nonfluent aphasia
12	8/F	Left atrium	Right hemiparesis, expressive aphasia Right hemiparesis, expressive aphasia Dizziness, ataxia, diplopia	Pulmonary embolus?	Yes		Not reported
Case 1	11/F	Left atrium	Right hemiparesis, expressive aphasia Dizziness, ataxia, diplopia	Red spots on hands and feet, retinal artery occlusion Red spots on left foot	No	MRI: infarcts of both hemispheres MRA: normal MRI: lesions of cerebellum, corpus callosum, right parietal	Left hemiparesis Normal

ACA indicates anterior cerebral artery; MCA, middle cerebral artery; ICA, internal carotid artery.

of mostly adult patients.^{1,4-6} A 16-year-old subject is included in 1 of the reports, but the clinical details are not discussed.⁶ In all 7 of the individual pediatric case reports and in our first case, the child presented with acute right hemiparesis caused by embolic occlusion involving the anterior circulation.^{3,7-12}

Our second case is distinguished by presentation with ataxia, slurred speech, and ocular dysmotility. The distribution of some of the lesions on MRI was indeed suggestive of vertebrobasilar (posterior circulation) involvement. The presence of the callosal lesion was believed to be an unusual area of involvement for ischemic injury. Therefore, the differential also included inflammatory and postinfectious conditions such as acute disseminated encephalomyelitis. The onset and resolution of the symptoms, however, were more suggestive of a transient ischemic attack resulting from small emboli. Ischemic stroke involving the vertebrobasilar circulation in children is less common than in the distribution of the carotid arteries.¹³ The initial symptoms may include headache and a mixture of brainstem and cerebellar signs, as in our patient. Visual field defects and focal seizures caused by occipital lobe infarction are other features of posterior circulation stroke. Syncope (with possible features of seizure activity) attributable to obstruction of blood flow through the mitral valve by the tumor is another cause of altered consciousness in patients with cardiac myxoma.⁵

In 2 of the previous case reports and in both of our cases, peripheral cutaneous embolic phenomena were reported as "red spots" involving the extremities and were noted before the onset of a cerebral ischemic event. Cardiac myxomas may mimic systemic vasculitis.¹⁴ The dermatologic manifestations of collagen vascular disease may include transient erythematous eruptions and capillary loop telangiectasias of periungual skin. Collagen vascular disease was considered a possible cause of the cutaneous eruptions in our first case before her presentation with acute hemiplegia. The evanescent rashes were most likely attributable to emboli to the skin and nails (splinter hemorrhages); fragmentation of the atrial tumor with peripheral embolization may affect any vascular bed. This feature is important because it provides a clue, which should prompt a more urgent need to obtain an echocardiogram. Such lesions are commonly associated with infective endocarditis and, rarely, tumors. The common cutaneous embolic manifestations include the following¹⁵: 1) splinter hemorrhages, which are normally seen under the fingernails and toenails and are usually linear and red for the first 2 to 3 days and brownish thereafter; 2) Osler's nodes, which are tender, subcutaneous nodules often in the pulp of the digits or thenar eminence; 3) Janeway's lesions, which are nontender erythematous, hemorrhagic, or pustular lesions often on the palms and soles; and 4) conjunctival petechiae. In our cases and others from the literature, a high index of suspicion might have prevented the subsequent strokes if the cutaneous eruptions described as "red spots" had been recognized as embolic lesions. The lack of other clinical evidence of cardiac disease should not dissuade one from con-

sidering a cardioembolic cause. Indeed, both of our cases and 5 of the 7 cases from the literature did not have a cardiac murmur at the time of presentation with cerebrovascular disease.

Noncardiac signs and symptoms of this histologically benign tumor may result from the release of cytokines. They include fever, weight loss, cachexia, arthralgia, Raynaud's phenomenon, and elevated erythrocyte sedimentation rate. It therefore is not surprising that myxomas are sometimes mistaken for noncardiac neoplasm. Symptomatic emboli occur in 20% to 45% of patients with cardiac myxoma, and approximately half of all myxomatous emboli from the left heart go to the brain. In addition to hemiplegia and aphasia, our first patient had retinal artery occlusion, which has been described in individuals with atrial myxoma.^{9,10,16} Embolus from the heart is the most common cause of retinal artery occlusion in individuals younger than 40 years. Sickle cell anemia and antiphospholipid antibodies are causes in patients younger than 30 years. When present in a child without other predisposing factors, retinal artery occlusion should suggest the diagnosis of cardiac myxoma.

Myxomas are friable, and recurrent cerebral emboli are common before surgical removal. Emboli consist mainly of myxomatous tissue, but embolisms of material originating from the bland thrombus adhering to the surface of the myxoma also occur.¹ In addition to multiple brain infarctions, the tumor emboli, when located on peripheral branch arteries, can cause cerebral aneurysms that can rupture and cause intracranial hemorrhage.^{8,10} In the adult cases, tumor recurrence is uncommon after surgical removal. The recurrence of the tumor in 2 of the pediatric cases, however, warrants careful follow-up of these children.^{8,10} Because of the familial occurrence of atrial myxomas, it has been recommended that echocardiography be performed on family members.¹⁷

Our reports and those of others demonstrate the importance of considering the diagnosis of atrial myxoma in children with acute neurologic deficits, especially in association with embolic lesions ("red spots") suggestive of infective endocarditis, retinal artery occlusion, or both. Two-dimensional echocardiography is highly accurate for the diagnosis. Unless another probable cause for stroke is clearly documented, this noninvasive study should be done in a timely manner on all pediatric patients who are suspected of having cerebrovascular disease even when the cardiac examination is normal and the results of brain imaging are not characteristic of ischemic injury. Anticoagulation before surgery is not effective,⁶ but surgical excision of the myxoma usually alleviates any cardiac symptoms and prevents additional cerebral emboli.

ACKNOWLEDGMENTS

We thank Dr E. Steve Roach for helpful comments during the preparation of the manuscript and Marlene Kennedy and Joe Wood for technical assistance in preparation of the manuscript.

REFERENCES

1. Markel MC, Waller BF, Armstrong WF. Cardiac myxoma—a review. *Medicine*. 1987;66:114–125
2. Roach ES, Riela A. *Pediatric Cerebrovascular Disorders*. 2nd ed. New York, NY: Futura; 1995

3. Goldberg HP, Glenn F, Dotter CT, et al. Myxoma of the left atrium: diagnosis made during life with operative and post-mortem findings. *Circulation*. 1952;6:762–767
4. Bulkley BH, Hutchins GM. Atrial myxomas: a fifty year review. *Am Heart J*. 1979;97:639–643
5. Yufe R, Karpati G, Carpenter S. Cardiac myoma: a diagnostic challenge for the neurologist. *Neurology*. 1976;26:1060–1065
6. Knepper LE, Biller J, Adams HP, et al. Neurologic manifestations of atrial myxoma—a 12 year experience and review. *Stroke*. 1988;19:1435–1440
7. Tipton BK, Robertson JT, Robertson JH. Embolism to the central nervous system from cardiac myxoma: report of two cases. *J Neurol*. 1977;47:937–940
8. Bobo H, Evans OB. Intracranial aneurysms in a child with recurrent atrial myxoma. *Pediatr Neurol*. 1987;3:230–232
9. Tonz M, Laske A, Carrel T, et al. Convulsions, hemiparesis and central retinal artery occlusion due to left atrial myxoma in a child. *Eur J Pediatr*. 1992;151:652–654
10. Hung PC, Wang HS, Chou ML, et al. Multiple cerebral aneurysms in a child with cardiac myxoma. *J Formos Med Assoc*. 1992;91:818–821
11. Bayir H, Morelli PJ, Smith TH, et al. A left atrial myxoma presenting as a cerebrovascular accident. *Pediatr Neurol*. 1999;21:569–572
12. Landes C, Baumann R, Coffrill CM. Embolic strokes in an 8-year-old girl. *Neurology*. 2000;55:146
13. Ganesan V, Chon WK, Cox TC, et al. Posterior circulation stroke in childhood. Risk factors and recurrence. *Neurology*. 2002;59:1552–1556
14. Macedo ME, Reis R, Sottomayor C, et al. Systemic vasculitis as the initial presentation of a left atrial myxoma. *Rev Cardiol*. 1997;16:463–466
15. Mylonakis E, Calderwood SB. Infective endocarditis in adults. *N Engl J Med*. 2001;18:1318–1330
16. Rafuse PE, Nicolle DA, Hutnik CM, et al. Left atrial myxoma causing ophthalmic artery occlusion. *Eye*. 1997;11:25–29
17. Crawford F, Selby J, Watson D, et al. Unusual aspects of atrial myxoma. *Ann Surg*. 1978;188:240–244

Cerebral Embolism From Atrial Myxoma in Pediatric Patients

Majeed Al-Mateen, Margaret Hood, Don Trippel, Samuel J. Insalaco, Randolph K.

Otto and Kari J. Vitikainen

Pediatrics 2003;112;e162

DOI: 10.1542/peds.112.2.e162

Updated Information & Services

including high resolution figures, can be found at:
<http://pediatrics.aappublications.org/content/112/2/e162>

References

This article cites 16 articles, 5 of which you can access for free at:
<http://pediatrics.aappublications.org/content/112/2/e162#BIBL>

Subspecialty Collections

This article, along with others on similar topics, appears in the following collection(s):

Cardiology

http://www.aappublications.org/cgi/collection/cardiology_sub

Permissions & Licensing

Information about reproducing this article in parts (figures, tables) or in its entirety can be found online at:

<http://www.aappublications.org/site/misc/Permissions.xhtml>

Reprints

Information about ordering reprints can be found online:

<http://www.aappublications.org/site/misc/reprints.xhtml>

American Academy of Pediatrics

DEDICATED TO THE HEALTH OF ALL CHILDREN™



PEDIATRICS®

OFFICIAL JOURNAL OF THE AMERICAN ACADEMY OF PEDIATRICS

Cerebral Embolism From Atrial Myxoma in Pediatric Patients

Majeed Al-Mateen, Margaret Hood, Don Trippel, Samuel J. Insalaco, Randolph K. Otto and Kari J. Vitikainen

Pediatrics 2003;112;e162

DOI: 10.1542/peds.112.2.e162

The online version of this article, along with updated information and services, is located on the World Wide Web at:

<http://pediatrics.aappublications.org/content/112/2/e162>

Pediatrics is the official journal of the American Academy of Pediatrics. A monthly publication, it has been published continuously since 1948. Pediatrics is owned, published, and trademarked by the American Academy of Pediatrics, 141 Northwest Point Boulevard, Elk Grove Village, Illinois, 60007. Copyright © 2003 by the American Academy of Pediatrics. All rights reserved. Print ISSN: 1073-0397.

American Academy of Pediatrics

DEDICATED TO THE HEALTH OF ALL CHILDREN™

