

Reversible Ischemic Neurological Deficit (RIND) due to Exercise Testing for the Diagnosis of Angina Pectoris

Toshihiko NANKE,¹ MD, Naoki MATSUMOTO,³ MD, Hirofumi WAKIMOTO,¹ MD,
Kiyoshi NAKAZAWA,¹ MD, Fumihiko MIYAKE,¹ MD,
Hirofumi WATANABE,² MD, Masahiro HORIUCHI,² MD,
and Yoichi TAKAHASHI,² MD

SUMMARY

A 57 year old Japanese male with chest oppression due to exercise is presented. This symptom was likely due to effort angina pectoris. Master's double two-step test revealed ischemic ST segment depression on the electrocardiogram, thus, a Tl²⁰¹ myocardial stress imaging test using a bicycle ergometer was undertaken. Immediately following the exercise test, the patient experienced dizziness and palsy in his left upper and lower limbs. Cerebral angiography demonstrated 70% stenosis at the right internal carotid artery, but no abnormal findings were demonstrated on a cranial x-ray CT scan and magnetic resonance imaging. His palsy in the left limbs completely recovered within 3 weeks. Thus this event was diagnosed as a reversible ischemic neurological deficit (RIND). Major but non-cardiogenic complications during exercise testing are very rare, and RIND has not been reported thus far to the best of our knowledge. (Jpn Heart J 2003; 44: 575-581)

Key words: Exercise testing, Complication, Reversible ischemic neurological deficit, Stroke

EXERCISE testing is considered to be a relatively safe examination with which to diagnose unknown coronary artery lesions in angina pectoris patients or to test exercise capacity after myocardial infarction.¹⁻³⁾ Although some investigators have reported their experiences with major cardiac complications such as acute myocardial infarction, lethal arrhythmia, or death, their occurrence is rare.^{4,5)} Moreover, the occurrence of cerebral vessel-related complications is very rare, since only two cases were reported by Gibbons, *et al*⁴⁾ and Atterhög, *et al*⁵⁾ in 590,000 exercise tests. Here we report a case of reversible ischemic neurological deficit (RIND) as a noncardiac major complication due to exercise testing. This is a rare complication of symptom limited exercise testing.

From the ¹ Division of Cardiology, ² Division of Neurology, Department of Internal Medicine and ³ Department of Pharmacology, St. Marianna University School of Medicine, Kawasaki, Japan.

Address for correspondence: Toshihiko Nanke, MD, FACP, Division of Cardiology, Department of Internal Medicine, St. Marianna University School of Medicine, 2-16-1 Sugao, Miyamae-ku, Kawasaki 216-8511, Japan.

Received for publication September 20, 2002.

Revised and accepted November 11, 2002.

CASE REPORT

A 57 year old Japanese male bus driver who began to experience anterior chest oppression when ascending stairs or slopes from March 2000, was referred to our department for examination. He had smoked 20 cigarettes per day for 37 years, and had a history of mild hypertension. Aspirin (81 mg) and nicorandil (15 mg) had been administered by his family doctor to treat angina pectoris. His blood pressure was 134/90 mmHg and heart rate 70 beats/min in a sitting position. No murmurs or extra heart sounds were audible, and there were no bruits on neck auscultation. No other abnormal physical findings were noted. An abdominal examination was normal. ECG demonstrated a normal sinus rhythm of 60 beats/min without significant morphological abnormalities. Chest x-rays also demonstrated a normal cardiac shadow and normal lung field findings. Echocardiography demonstrated very slight concentric hypertrophy of the left ventricle, however, the wall motion of both ventricles was normal (LVEF = 75%, FS = 44%). No thrombus formation was detected in the left atrium or left ventricle. On Master's double 2 step testing, horizontal ST depression of 0.07 mV in leads V₅ and V₆ was noted just after exercising, thus, the patient was diagnosed as positive for ischemic heart disease on exercise testing criteria.

Myocardial scintigraphy with Tl²⁰¹ on exercise was performed since effort angina pectoris was strongly suspected due to his clinical course and the results, of the Master's double 2 step test. A bicycle ergometer was used under a symptom limited protocol of 20 watts/min ramp increment. Blood pressure before the exercise in a sitting position was 158/90 mmHg and heart rate was 70 beats/min. The patient was symptom free and his physical condition was good and fitted for exercise at the start point of the testing. Upon exercise, his blood pressure and heart rate gradually increased. A feeling of dizziness suddenly appeared 6 minutes after the start of exercise. The exercise test was terminated at 6 minutes and 30 seconds. Blood pressure at the end point of the exercise was 172/94 mmHg and his heart rate was 125 beats/min, which was 78% of the maximum heart rate adjusted by age (Table). There was no sudden decrease in blood pressure, chest pain, or ischemic ST depression on an ECG conducted just after the exercise. However, muscle weakness in the left upper and lower limbs appeared with dizziness so he was hospitalized immediately.

Upon hospitalization, he was alert and there was no disorientation or higher brain function disorder. No disorders of the cranial nerve system or deep tendon reflex disorder were seen. Muscle strength in the left upper and lower limbs was decreased by 40%. Blood cell counts, blood chemistry tests, and urinalysis were normal. A cranial x-ray CT scan did not demonstrate a definite high or low absorption area. Cranial magnetic resonance imaging (MRI) did not demonstrate

an abnormal signal focus or perfusion defect area (Figure 1). Diffusion weighted cranial MRI, which is believed to sensitively detect acute ischemic deficits,⁶⁾ also

Table. Patient's Response to Incremental Maximal Exercise Testing

Phase	Time	Work Rate (Watts)	HR (beats/min)	BP (mmHg)	PRP (×100)	PVC (/min)
Rest	0:00	0	70	158/90	117	0
Exercise	1:00	20	87	154/92	133	0
	2:00	40	92	155/94	142	0
	3:00	60	98	156/94	153	0
	4:00	80	106	151/93	160	0
	5:00	100	114	163/97	185	0
	6:00	120	122	172/94	209	0
End point	6:30	100	125	172/94	215	0
Recovery	1:00	0	123	174/95	214	0
	2:00	0	107	169/95	181	0
	3:00	0	85	157/97	133	0
	3:30	0	76	157/97	119	0

HR = heart rate; BP = blood pressure; PRP = pressure rate product; PVC = premature ventricular contraction.

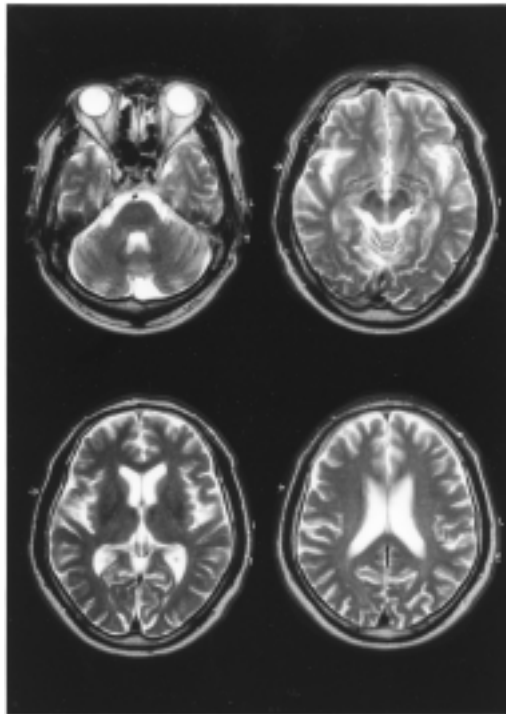


Figure 1. Cranial MRI examination. T₂-weighted image of MRI performed on attack day shows no particular abnormal findings.

revealed no definite abnormal findings. Cerebral arteriography (four vessel study) was performed three hours after onset of the muscle weakness, and demonstrated 70% stenosis at the ostium of the right internal carotid artery. The North American Symptomatic Carotid Endarterectomy Trial (NASCET) method⁷⁾ was used to measure the ratio of carotid artery stenosis (Figure 2). No cerebral artery stenosis or findings of embolism were observed. During his hospitalization, an antithrombin drug was used for 2 weeks. No abnormal findings were detected in follow up cranial x-ray CT (Figure 3) and cranial MRI examinations. Brain SPECT revealed no decrease in brain blood flow in the resting state. On day 21, the muscle weakness in the limbs had fully recovered to normal levels.

Coronary angiography performed later revealed no significant coronary organic stenotic lesions, but spastic stenotic changes were induced by intracoronary infusion of acetylcholine. Vasospastic angina was the most likely diagnosis, so nicorandil administration was continued.

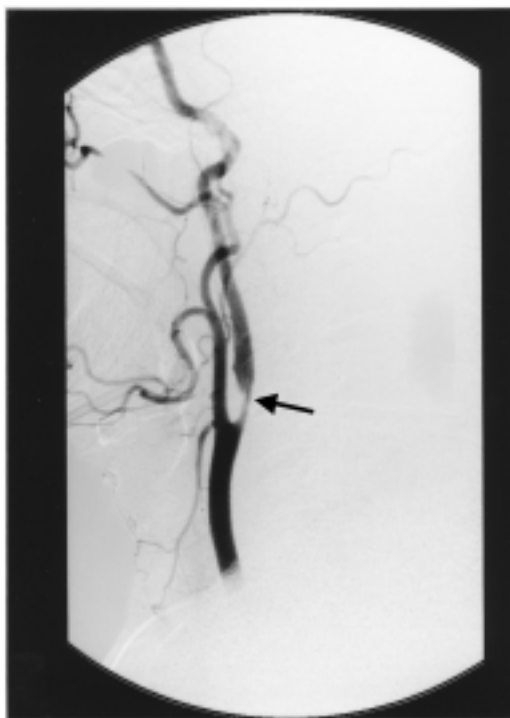


Figure 2. Right common carotid arteriography. Right common carotid arteriography shows circumferential stenotic change at the orifice of the right internal carotid artery (arrows).

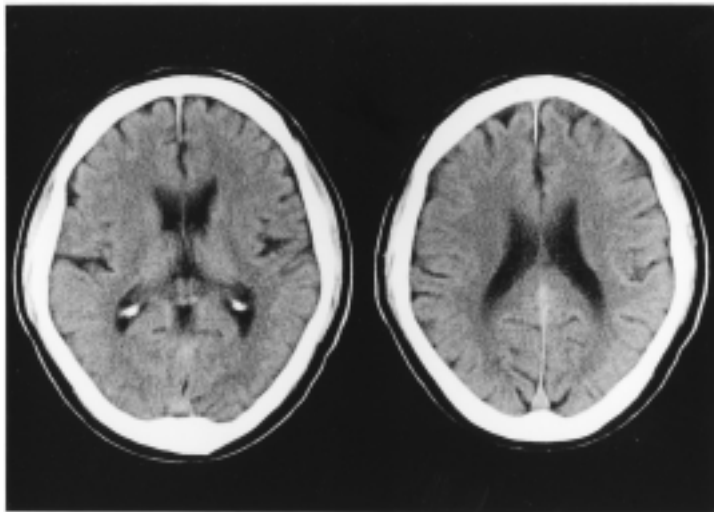


Figure 3. Cranial x-ray CT examination. Plain CT scan performed 6 days after the attack shows no particular abnormal findings.

DISCUSSION

Gibbons, *et al*⁴⁾ have reported 6 cases of major cardiac complications out of 71,914 cases of symptom-limited exercise testing, with none being stroke. Ninety-two cases with complications out of 518,448 exercise testing cases were reported by Atterhög, *et al*,⁵⁾ and only one TIA and one syncope case were cerebral vessel-related complications. Other investigators have reported noncardiogenic major complications during exercise testing such as cerebral bleeding⁸⁾ and transient global amnesia,⁹⁾ however, there have not been any reports on RIND. The present case is considered to be a very rare case.

An ischemic brain attack, the neurological symptoms of which fully recover within 24 hours, is called a 'transient ischemic attack (TIA)'. It is considered to be the prodrome of brain infarction. If the neurological symptoms lasted more than 24 hours though a full recovery was seen within 3 weeks, the attack is called 'reversible ischemic neurological deficit (RIND)',¹⁰⁾ and is distinguished from TIA. Loeb, *et al*¹¹⁾ described the clinical features of RIND as : (1) a relatively rare disease since there were only 42 cases in 1018 consecutive stroke patients (4.1%), (2) frequent in internal carotid artery area, (3) sudden onset, (4) rarely accompanied by a consciousness disorder, (5) usually normal cranial x-ray CT and

encephalogram, (6) frequently seen arterial stenosis and occlusion with arteriography, and a (7) poor prognosis following a massive infarction or bleeding in the brain, which tend to lead to death. The clinical course of the present case largely met these criteria; sudden onset of ischemic symptoms of the brain without consciousness disorder, full recovery of the neural deficit within 3 weeks, a normal encephalogram, normal cranial x-ray CT and MRI, and 70% stenosis in the internal carotid artery with arteriography. Therefore, the attack was diagnosed as RIND.

The cause of RIND is not yet clear, although it is suspected that a thrombus may be formed in the main portion of the internal carotid artery or mid-cerebral artery, which is then followed by the localized ischemic event. If thrombolysis occurs shortly after the thrombus formation, the symptoms may fully diminish.¹¹⁾ Zulch, *et al*¹²⁾ pointed out that brain cells may survive even if the oxygen consumption rate decreases to 50-80% of the normal level, though palsy may occur as a symptom of brain function disorder. The reversed symptom of the present case may be explained by the hypothesis that the remarkable stenosis in the right internal carotid artery might have caused localized brain ischemia during the exercise, or that the thrombus which formed in the vessel might have disappeared in a very short time. The reason for the full recovery from the cerebral ischemic attack without any neurological deficits is believed to be that the intensive treatment was started early (three hours) after the onset of the event.¹³⁾ Carotid artery stenosis can exist even in cases without neck bruit.¹⁴⁾ Exercise testing should be performed with great precaution in those who have risk factors for arteriosclerosis.¹⁵⁾ It may be advisable to perform exercise testing under informed consent that describes major and minor complications, including such rare occurrences as cerebral infarctions or brain ischemic attacks.

REFERENCES

1. Pina IL, Balady GJ, Hanson P, Labovitz AJ, Madonna DW, Myers J. Guidelines for clinical exercise testing laboratories: a statement for healthcare professionals from the committee on exercise and cardiac rehabilitation, American Heart Association. *Circulation* 1995; 91: 912-21.
2. Stuart RJ, Ellestad MH. National survey of exercise stress testing facilities. *Chest* 1980; 77: 94-7.
3. Fletcher GF, Balady G, Froelicher VF, Hartley LH, Haskell WL, Pollock ML. Exercise standards: a statement for healthcare professionals from the American Heart Association. *Circulation* 1995; 91: 580-615.
4. Gibbons L, Blair SN, Kohl HW, Cooper K. The safety of maximal exercise testing. *Circulation* 1989; 80: 846-52.
5. Atterhög JH, Jonsson B, Samuelsson R. Exercise testing: a prospective study of complication rates. *Am Heart J* 1979; 98: 572-9.
6. Marx JJ, Mika-Gruettner A, Thoenke F, *et al*. Diffusion weighted magnetic resonance imaging in the diagnosis of reversible ischaemic deficits of the brainstem. *J Neurol Neurosurg Psychiatry* 2002; 72: 572-5.
7. North American Symptomatic Carotid Endarterectomy Trial Collaborators. Beneficial effect of carotid endarterectomy in symptomatic patients with high-grade carotid stenosis. *N Engl J Med* 1991; 325: 445-53.

8. Onnis E, Montisci R, Corda L, *et al.* Intracranial haemorrhage during exercise testing. *Eur Heart J* 1995; 16: 282-4.
9. Richardson RS, Leek BT, Wagner PD, Kritchevsky M. Transient global amnesia: a complication of incremental exercise testing. *Med Sci Sports Exerc* 1998; 30 : S403-5.
10. Millikan CH, Bauer RB, Goldschmidt J, *et al.* A classification and outline of cerebrovascular diseases II. *Stroke* 1975; 6: 565-616.
11. Loeb C, Priano A, Alabano C. Strokes with full recovery. In: Meyer JS, Lechner H, Reivich M, Eichorn O, editors. *Cerebral Vascular Disease*. Stuttgart: Georg Thieme 1973: 15-21.
12. Zulch KJ. Hemorrhage, Thrombosis, Embolism. In: Pathology of the Nervous System. Minckler J, editor. New York: McGraw-Hill 1971: 1499-536.
13. Furlan A, Higashida R, Wechsler L, *et al.* Intra-arterial prourokinase for acute ischemic stroke- The PROACT II study: A randomized controlled trial. *JAMA* 1999; 282: 2003-11.
14. Zhu CZ, Norris JW. Role of carotid stenosis in ischemic stroke. *Stroke* 1990; 21: 1131-4.
15. Staikov IN, Arnold M, Mattle HP, *et al.* Comparison of the ECST, CC, and NASCET grading methods and ultrasound for assessing carotid stenosis. European Carotid Surgery Trial. North American Symptomatic Carotid Endarterectomy Trial. *J Neurol* 2000; 247: 681-6.