



ELSEVIER

CASE REPORT

Otogenic cerebral venous infarction: a rare complication of acute otitis media

Enver Özer^{a,*}, Ercan Sıvaslı^b, Yıldırım A. Bayazıt^a, Akif Şirikci^c,
Abdulvahap Gök^d, Semih Mumbuç^a, Muzaffer Kanlıkama^a

^a Department of Otolaryngology, Faculty of Medicine, University of Gaziantep, Kolejtepe, Gaziantep, Turkey

^b Department of Pediatrics, Faculty of Medicine, University of Gaziantep, Gaziantep, Turkey

^c Department of Radiology, Faculty of Medicine, University of Gaziantep, Gaziantep, Turkey

^d Department of Neurosurgery, Faculty of Medicine, University of Gaziantep, Gaziantep, Turkey

Received 19 December 2002; received in revised form 9 May 2003; accepted 11 May 2003

KEYWORDS

Cerebral venous infarction;
Otitis media;
Facial paralysis;
Hemiplegia

Summary A case of cerebral venous infarction (CVI) as a complication of acute otitis media (AOM) was presented in a 16-month-old male patient. The patient admitted with AOM in the right ear, ipsilateral facial paralysis and contralateral hemiplegia. Computerized tomography of the brain showed low density areas involving both the cortex and subcortical white matter in the right frontoparietal region, and there were patchy and multifocal enhancing areas with intravenous contrast enhancement. These findings disclosed the diagnosis of venous infarctions involving the superficial cortical veins on the right side. Complete recovery was achieved with 2 weeks of sulbactam–ampicilline, amikacin and prednisolone treatment. Although it is rather rare, CVI should also be remembered among the otogenic intracranial complications. © 2003 Elsevier Ireland Ltd. All rights reserved.

1. Introduction

Although the overall incidence of intracranial complications of suppurative otitis media has fallen greatly with antibiotic treatment, mortality from intracranial complications is still possible [1,2]. Meningitis is the most commonly seen complication, and is followed by brain abscess, perisinus abscess, lateral sinus thrombophlebitis and extradural abscess, respectively [2–5]. However, cerebral venous infarction (CVI) as a complication of acute otitis media (AOM) has not been

reported in the literature to date. To our knowledge, this is the first case of CVI as a complication of AOM.

2. Case report

Right peripheral facial paralysis developed in a 16-month-old male patient in the 3rd day of his treatment for AOM. He was taking sulbactam–ampicilline (150 mg/kg per day) for 3 days. He was referred to our clinic due to deterioration of his general status. History did not reveal previous history of otitis media.

On admission, the patient was found to be febrile and confused. He had AOM in the right ear. Right

*Corresponding author. Tel.: +90-342-360-3354; fax: +90-342-336-5505.

E-mail address: enveroz@hotmai.com (E. Özer).

tympanic membrane was hyperemic and bulging toward the external auditory canal in otoscopic examination. He also had hemiplegia on the left side, and peripheral facial paralysis on the right side. The child was otherwise healthy. Computerized tomography (CT) of the brain showed low density areas involving both the cortex and subcortical white matter in the right frontoparietal region. With intravenous contrast enhancement on CT examination, patchy and multifocal enhancing areas were encountered. The radiological and clinical findings were pointing venous infarctions, which involved some of the superficial cortical veins on the right side (Figs. 1 and 2).

A mucopurulent exudate was aspirated on tympanosynthesis. Tympanostomy tube was not inserted since AOM was considered to resolve with antibiotic treatment. Nothing was cultivated in the middle ear aspirate, possibly due to previous antibiotic treatment. Therefore, an empiric treatment with sulbactam–ampicilline (150 mg/kg per day), amikacin (15 mg/kg per day) and prednisolone (2 mg/kg per day) was administered for 2 weeks as an antimicrobial and antiedema treatment, respectively.

At the end of the 2nd week with this treatment, the facial paralysis and left hemiplegia recovered, medications were discontinued, and the patient was discharged from the hospital. Cranial CT that was obtained 1 month after discharge revealed a decrease in the CVI areas. The patient is doing well without any sequel in his 4 months follow up.

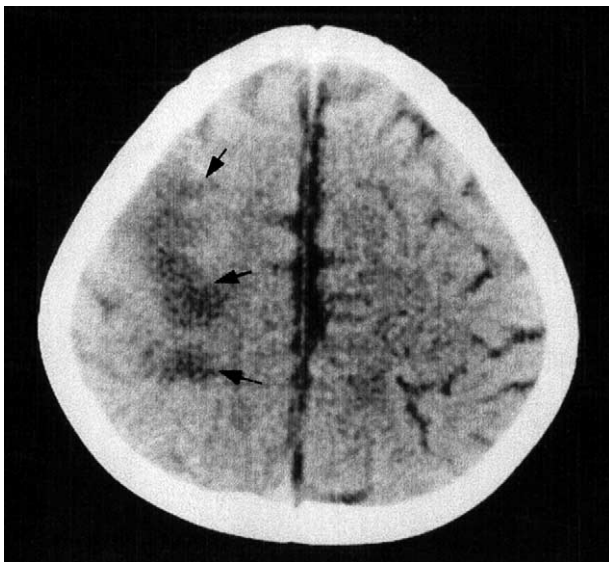


Fig. 1 Axial CT scan obtained 2 days after the neurological symptoms. Low intensity areas in the cortex and subcortical white matter involving the right frontoparietal region (arrows). Note the hypodensity is not confined to an arterial territory.

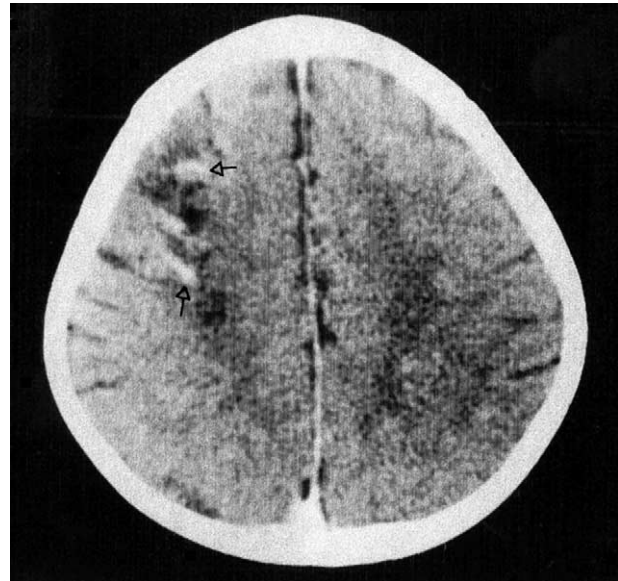


Fig. 2 Post contrast CT study showing patchy multifocal enhancing areas at corticomedullary junctions (open arrows).

3. Discussion

CVI as a complication of AOM should be rare, and has not been reported to date. Similarly, there are a few cases of cerebellar venous infarction due to chronic suppurative otitis media in the literature, which were proposed to occur in pregnancy, antithrombin III deficiency, and diabetic osmolar coma [6]. These disorders were not present in our case.

An otogenic infection may spread by a number of possible routes; (1) by extension through demineralized bone during acute infection; (2) by the spreading of infected clot within small veins through bone and dura to venous sinuses; (3) through anatomical pathways—oval and round windows, cochlear and vestibular aqueducts, dehiscence tegmen and suture lines; (4) through non-anatomical, surgical or traumatic defects; (5) into brain tissue along the periarteriolar spaces of Virchow–Robin. In our case, the CVI possibly occurred by retrograde spreading of an infected clot into the venous sinuses and veins of the frontoparietal region through small veins in the bone and dura [7].

Central nervous system (CNS) infarction associated with meningitis mostly occurs because of inflammatory-induced arterial spasm or because of direct inflammation of the walls of arteries and arterioles, resulting in an infectious arteritis [8]. However, cortical veins or dural venous sinuses may also be involved with resultant venous thrombosis

and venous infarction of involved CNS tissues [9,10].

CVIs with CT and magnetic resonance abnormalities usually have characteristics that distinguish them from arterial infarction. Since major cerebral veins generally drain more than one arterial distributions, CVI usually are not confined, as with the arterial infarction to the territory of a single artery. On CT, CVI are usually poorly delineated hypodense or mixed attenuation areas involving the subcortical white matter and producing a mass effect on ventricular structures. The low attenuation is probably due to localized cerebral edema. After contrast administration linear or round gyral enhancement frequently overlies the hypodensity [11].

Antibiotic treatment of AOM is certainly not an absolute safeguard against the development of complications. Antibiotic therapy may have a masking effect on significant signs and symptoms of complications, causing delay in diagnosis. Myringotomy, especially in young children, should not be forgotten for drainage and to provide material for culture. Despite these facts, antibiotic treatment (as performed in our case) should not be discontinued in similar cases even if no microorganism is cultivated. Antibiotic should be selected according to microorganism cultivated. When no microorganism was isolated, an empirical treatment with wide spectrum antibiotics is necessary. Steroids appear to be beneficial against cerebral edema, and nerve paralyses. With this treatment protocol, rapid recovery of the patient is expected as in our case. If there is insufficient improvement of the patient with the appropriate conservative treatment, radioimaging followed by the necessary surgical procedures should be performed [12].

In conclusion, mortality and morbidity of intracranial complications of otogenic infections are still possible, and clinician should be aware of their

symptoms and signs. CVI should also be remembered among the otogenic intracranial complications.

References

- [1] J.F. Hirsch, F.X. Roux, C. Sainte Rose, D. Renier, A. Pierre Kahn, Brain abscess in childhood: a study of 34 cases treated by puncture and antibiotics, *Childs Brain* 10 (1983) 251–265.
- [2] H. Kaftan, W. Draf, Intracranial otogenic complications: inspite of therapeutic progress still a serious problem, *Laryngorhinootologie* 79 (2000) 609–615.
- [3] J. Kangsanarak, N. Navacharoen, S. Foonant, K. Ruckphaopunt, Intracranial complications of suppurative otitis media: 13 year's experience, *Am. J. Otol.* 16 (1995) 104–109.
- [4] J. Samuel, C.M. Fernandes, Otogenic complications with an intact tympanic membrane, *Laryngoscope* 95 (1985) 1387–1390.
- [5] G.D. Dobben, B. Raofi, M.F. Mafee, A. Kamel, S. Mercurio, Otogenic intracranial inflammations: role of magnetic resonance imaging, *Top. Magn. Reson. Imaging* 11 (2000) 76–86.
- [6] A.K. Nayak, D. Karnad, M.V. Mahajan, A. Shah, Y.V. Meisheri, Cerebellar venous infarction in chronic suppurative otitis media. A case report with review of four other cases, *Stroke* 25 (1994) 1058–1060.
- [7] J.B. Booth, London: Scott-Brown's Otolaryngology, sixth ed., 1998.
- [8] U.S. Kanamalla, R.A. Ibarra, J.R. Jinkins, Imaging of cranial meningitis and ventriculitis, *Neuroimaging Clin. North Am.* 10 (2000) 309–331.
- [9] M.R. Crain, W.T. Yuh, G.M. Greene, D.J. Loes, T.J. Ryals, Y. Sato, et al., Cerebral ischemia; evaluating with contrast-enhanced MR imaging, *Am. J. Neuroradiol.* 12 (1991) 631–639.
- [10] T.M. Harris, M.K. Edwards, Meningitis, *Neuroimaging Clin. North Am.* 1 (1991) 39.
- [11] J. Chiras, M. Dubs, J. Bories, Venous infarctions, *Neuroradiology* 27 (1985) 593–600.
- [12] I.J. Dhooge, F.W. Albers, P.B. Van Cauwenberge, Intratemporal and intracranial complications of acute suppurative otitis media in children: renewed interest, *Int. J. Pediatr. Otorhinolaryngol.* 49 (Suppl) (1999) 109–114.

Available online at www.sciencedirect.com

SCIENCE @ DIRECT®