

# Posterior Encephalopathy Subsequent to Cyclosporin A Presenting as Irreversible Abulia

Makoto NISHIE, Kozo KURAHASHI, Masaya OGAWA,  
Yasuji YOSHIDA\* and Hiroshi MIDORIKAWA\*\*

## Abstract

**A case of cyclosporin A (Cys A)-induced posterior encephalopathy developed into persistent abulia despite rapid and marked improvement of abnormal T2- and FLAIR MRI hyperintense regions. Diffusion-weighted MRI signal intensity was also high at the onset. This change is atypical in Cys A-induced encephalopathy and was thought to predict poor recovery from the encephalopathy. Persistent abulia was probably due to marked hypoperfusion in the whole cortex including bilateral frontal lobes and basal ganglia as detected by SPECT. Apart from the breakdown of the blood-brain barrier, direct toxicity of Cys A to the brain may play a role in the pathogenesis of chronic, irreversible encephalopathy. (Internal Medicine 42: 750–755, 2003)**

**Key words:** toxic encephalopathy, reversible posterior leukoencephalopathy, cortical laminar necrosis, apoptosis, diffusion-weighted MRI, atopic dermatitis

## Introduction

Cyclosporin A (Cys A) is frequently used for patients with autoimmune diseases. This drug may induce acute or subacute encephalopathy classified as reversible posterior leukoencephalopathy (RPLE) (1, 2). Although rapid progress to generalized seizure or cortical blindness are typical symptoms, the initial complaints may be subtle symptoms, such as headache or reduced vitality (3). Transient high intensity signals in bilateral parieto-occipital lobes in T2-weighted or FLAIR sequence MRI with no lesions detected by diffusion-weighted imaging (DWI) is a typical finding of RPLE (2, 4),

reflecting vasogenic edema caused by disturbance of cerebral blood flow autoregulation (3). However, conversion to irreversible cytotoxic damage from RPLE has recently been reported (5).

## Case Report

A 57-year-old man was admitted to a hospital on May 7, 2001, complaining of loss of appetite and reduced activity for around 6 months. He was diagnosed as having acute gastritis and treated with an H<sub>2</sub>-inhibitor and intravenous fluids. On June 3, he had an episode of unconsciousness. Although he was unresponsive for the following three days, he could walk on June 6. On June 21, after he had consulted a doctor in a dermatology clinic, he developed a twilight condition for several hours before developing a generalized tonic-clonic seizure over 30 minutes. He was transported to a hospital, and was administered diazepam and phenytoin by infusion to arrest paroxysmal seizures. After arrest of the seizures, he became unresponsive to stimulation, mimicking akinetic mutism from June 22 to June 25, so he was transferred to our hospital.

At the age of 45, he had developed atopic dermatitis, spreading to his whole body with severe itchiness, which was resistant to various anti-allergic medications and local steroid ointments. The patient was administered Cys A for intractable dermatitis from April 2000 with remarkable effect. Cys A was taken in oral doses of between 150 mg and 250 mg per day based on blood serum concentrations, which had been relatively high for the therapeutic range of Cys A (100 to 150 ng/ml). Serum concentrations of Cys A were 335 ng/ml on April 20, 749 ng/ml on May 25, 289 ng/ml on July 19 and 202 ng/ml on September 14. After September 2000, around when he had reduced activity and fine finger and postural tremor, Cys A (200 mg/day) was administered without monitoring its serum concentration. After the first seizure

From the Departments of Neurology, \*\*Radiology, Aomori Prefectural Central Hospital, Aomori and \*the Department of Pathology, Research Institute for Brain and Blood Vessels, Akita

Received for publication November 11, 2002; Accepted for publication April 9, 2003

Reprint requests should be addressed to Dr. Makoto Nishie, the Department of Neuropathology, Institute of Brain Science, Hirosaki University School of Medicine, 5-Zaifu-cho, Hirosaki 036-8562

episode, at the beginning of June 2001, he had not regularly taken his Cys A medication, with consequent relapse and exacerbation of his atopic eruptions.

On admission, his face was apathetic. He was unresponsive to verbal orders or painful stimuli, consistent with the condition of akinetic mutism. Although he opened his eyes, he had cortical blindness. His posture mimicked paraplegia flexion and muscles of four extremities showed paratonia. There were no meningeal signs, increase of deep reflexes or pathological reflexes. He had numerous reddish and confluent eruptions with an inflammatory exudate over his entire body. Atopic eruptions were also seen on the lower dorsal extremities. His blood pressure was 120/80; heart rate 110 beats per min with a sinus rhythm; body temperature 37.4°C. Laboratory studies on June 26 revealed that his WBC count was 17,200/mm<sup>3</sup> with 13.2% eosinophils on a differential count; serum CRP was 6.1 mg/dl (normal: <0.2 mg/dl) and IgE 3,642 mg/dl (normal: <170 mg/dl). Specific IgE was highly positive for candida and Japanese cedar pollen. Soluble interleukin-2 receptor level was also high at 4,460 U/ml (normal: 145–519 U/ml). Other serum data, including total cholesterol and magnesium, were within normal range. Markers for various collagen diseases were all negative. Cys A concentration was less than 25 ng/ml. CSF contained 3 cells/mm<sup>3</sup> and 25 mg/dl protein. IgG index was 0.38 (<0.75), myelin basic protein and oligoclonal bands were not detected in CSF. Both bacterial culture and generic herpes virus DNA were negative in both serum and CSF. The CSF and blood levels of pyruvate and lactate were within normal range. EEG revealed diffuse slowing of background activities and bursts of delta waves in the area of the bilateral temporo-parieto-occipital regions without definite epileptic discharges. MRI on June 26 revealed extensive abnormal lesions with high signal intensity on the right temporal and bilateral parieto-occipital lobes on DWI (Fig. 1) and T2 WI and FLAIR sequence. <sup>99m</sup>Tc ECD single photon emission CT (SPECT) showed slight hypoperfusion in the entire cortex, particularly in the bilateral parieto-occipital cortices on June 26 (Fig. 2A).

Considering the results of blood and CSF examinations in addition to neuroimaging, we suspected that the pathological process of the lesions was derived from Cys A-induced encephalopathy. As a diagnostic procedure, a brain biopsy from the right temporal lobe was performed on July 10. Microscopic examination revealed mild brain edema and mild reactive astrocytosis consistent with a diagnosis of RPLE (Fig. 3). In this specimen, there were no findings suggestive of laminar necrosis or neuronal death.

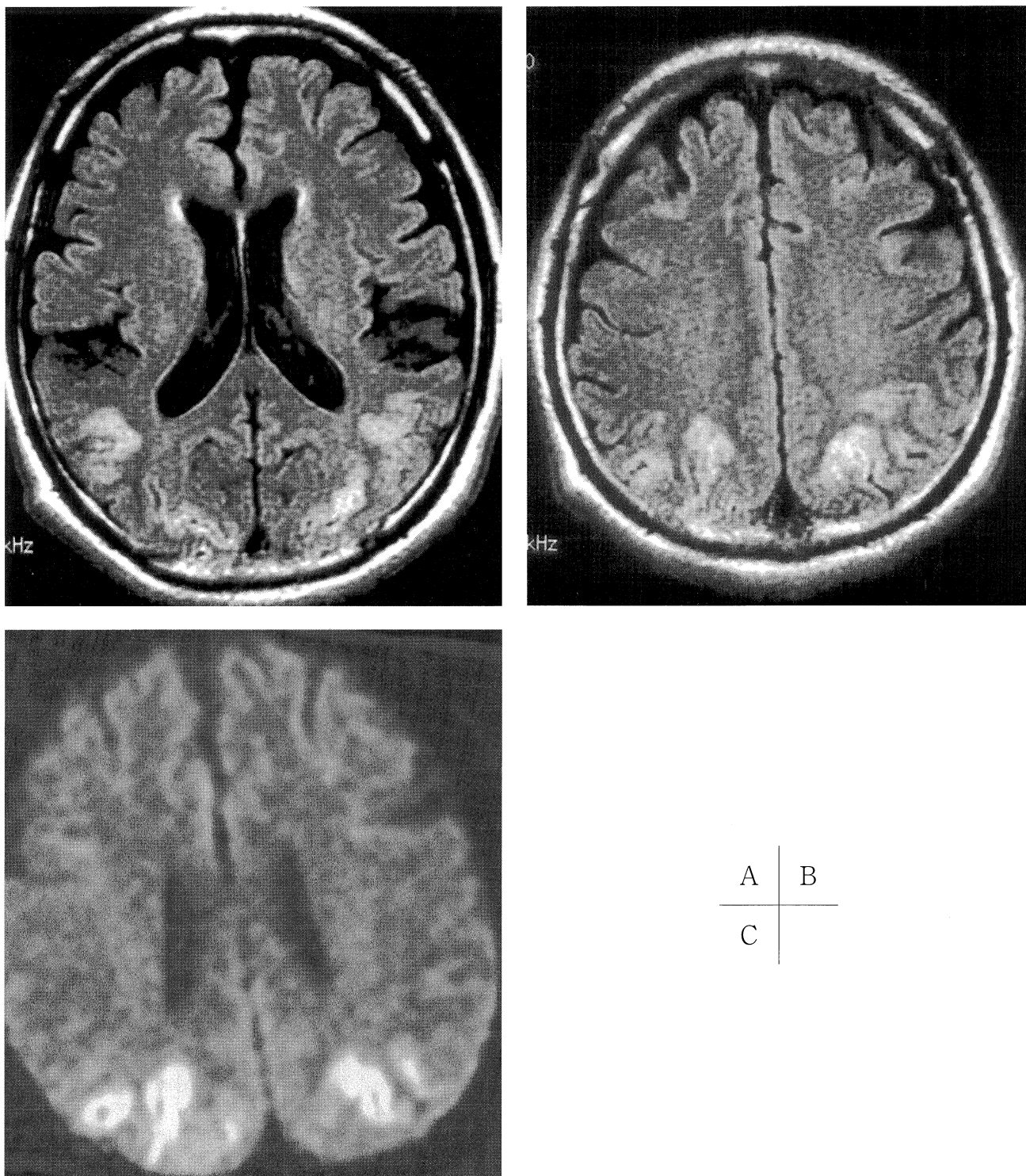
On July 30, T2WI, FLAIR and DW MRI images showed disappearance of the abnormal high intensity lesions. However, T1-weighted MRI showed high-signal linear lesions along with parieto-occipital cortices, suggesting cortical laminar necrosis that was not detected on MRI on June 26 (Fig. 4). In addition, SPECT showed marked progress of hypoperfusion in the entire cortex in contrast to improvement of FLAIR and DWI MRI findings on July 30 and

September 29 (Fig. 2B). From August 21, smaller doses of Cys A (150 mg/day) were necessarily administered to the patient because of severe exacerbation of atopic eruptions that was unresponsive to other medications; this markedly improved his dermatitis without exacerbation of his neurological condition or reappearance of MRI abnormalities. There had not been remarkable changes in the EEG findings through the course. The patient had been abulic and bedridden with only stereotyped verbal responses and echolalia, until his transfer to a rehabilitation hospital on December 13, 2001. His neurological condition had not improved by July 31, 2002.

## Discussion

Cys A is one of the essential immunosuppressive drugs in the treatment of various intractable autoimmune diseases, including refractory atopic dermatitis. This drug has a potent neurotoxicity and may cause various neurological side effects in up to 40% of patients (3). RPLES is the most serious complication and accounts for severe symptoms such as seizure, cortical blindness, or decreased level of consciousness. The principle etiology of the neurotoxic mechanism induced by Cys A is thought to be transient breakdown of the auto-regulation of cerebral blood flow through endothelial damage, leading to brain edema. The experimental finding that endothelial cells of vertebral-basilar arteries lack adrenergic receptors that control vasodilatation is consistent with the posterior predominance of this syndrome (6). Because transient brain edema underlies the condition in most patients, neurological deficits associated with Cys A-induced encephalopathy usually resolve within two weeks after cessation or dose-reduction of Cys A (1).

However, reports concerning poor recovery from this syndrome have been published recently (5, 7, 8). The present patient had symptoms suggestive of chronic encephalopathy for about nine months before the onset of acute encephalopathy with seizure and abnormal MRI findings. Chronic and prolonged universal damage to the cortical neurons besides the parieto-posterior regions was thought to be the cause of the irreversible clinical course and abulic state, which did not correspond to the rapid resolution of vasogenic edema detected by T2- and FLAIR MRI. In addition to the influence of Cys A on arterial endothelial cells, McDonald et al reported that Cys A induced both neuronal apoptosis and death of oligodendroglial cells (9). Direct neurotoxicity of Cys A is thought to play a crucial role in persistent brain damage. In addition, angiographic and SPECT studies during the symptomatic period of RPLES revealed segmental narrowing of the posterior cerebral arteries, possibly resulting in ischemia of the corresponding cortices (10). Chronic vasospasm induced by Cys A may have been another contributor to the permanent brain damage in this patient, because the most common cause of cytotoxic edema, indicated as a high signal on DWI, is hypoxia eventually accompanied by vasogenic edema (11). The pathological findings in our patient were



**Figure 1.** MRI on June 26, 2001 showed abnormal hypersignal lesions on bilateral parieto-occipital lobes with not only FLAIR image (A, B) but also diffusion-weighted imaging (C).

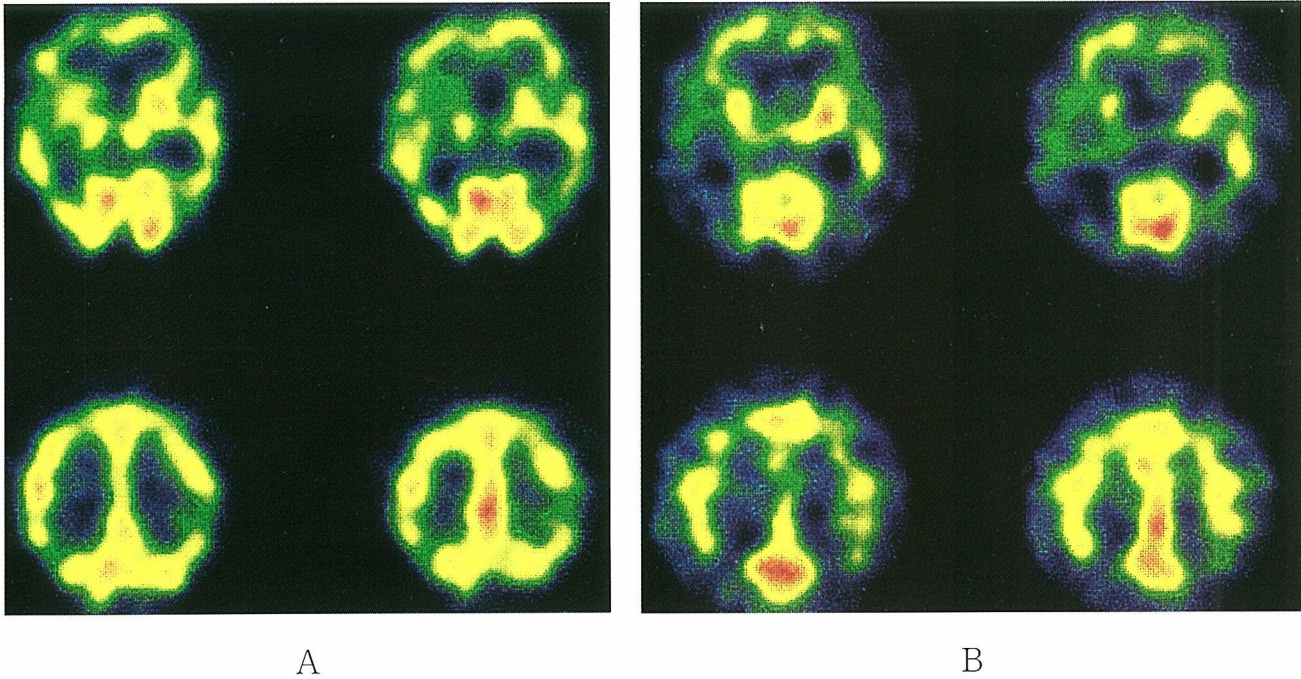
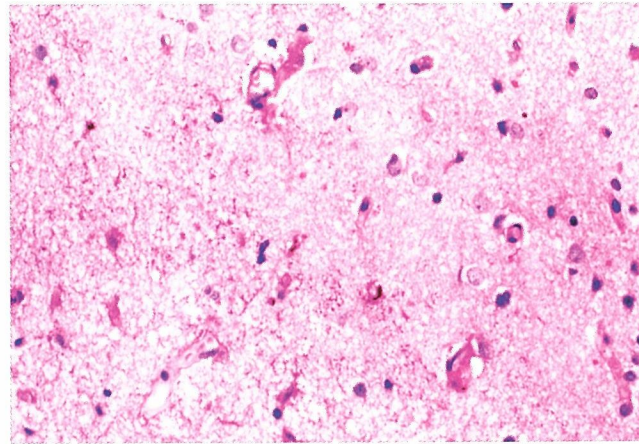
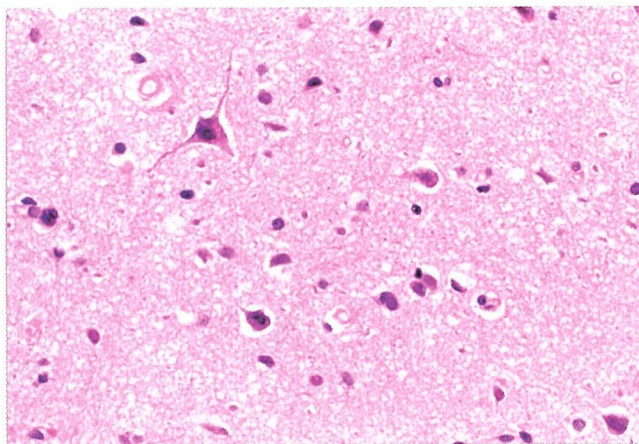
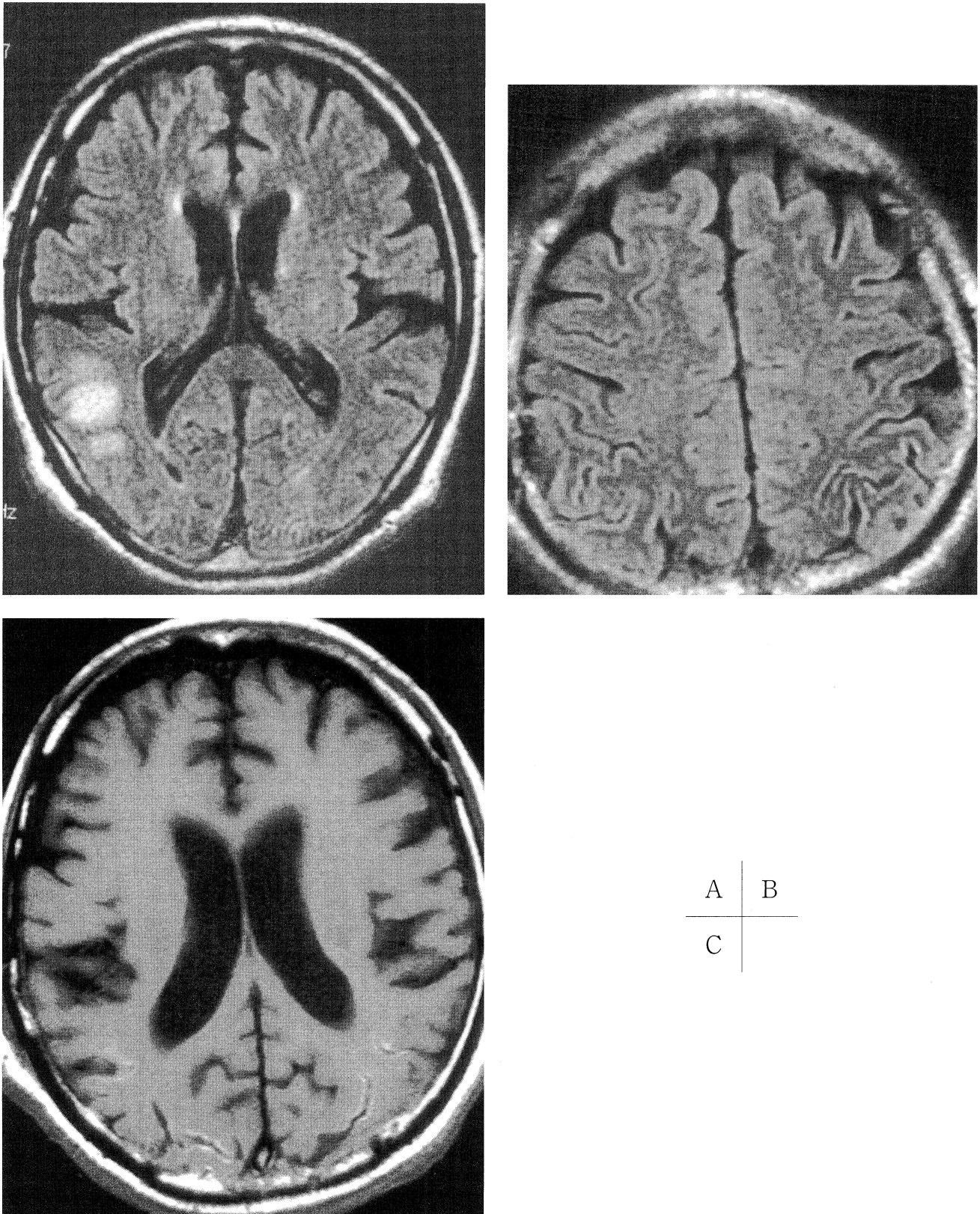


Figure 2. <sup>99m</sup>Tc-ECD SPECT showed hypoperfusion in the bilateral parieto-occipital cortices and right basal ganglia on June 26 (A). The study on September 29 showed marked hypoperfusion in the entire cortex in addition to the lesions detected by the previous study (B).



A	B
C	

Figure 3. Microscopic examinations biopsied from the right temporal cortex (A&B×200, C×100). Hematoxylin and eosin staining revealed enlarged extracellular spaces around neurons and neuronal pyknosis in addition to porosity of neuropile (A). Periodic acid-Schiff (PAS) staining revealed many PAS positive granules, which suggested that there was plasma infiltrate because of a breach of the blood-brain barrier (B). The immunohistochemical stain for glial fibrillary acid protein (GFAP) detected reactive astrocytes with increased processes and GFAP expression (C).



**Figure 4.** MRI on July 30, 2001. The lesions detected by the previous study were almost completely diminished with both diffusion-weighted imaging and FLAIR images (A, B) except the right temporo-parietal cortex from which biopsied specimens were taken. However, T1-weighted image without Gadolinium contrast (C) showed cortical hyperintense lesions consistent with cortical laminar necrosis.

consistent with increased permeability of the blood-brain barrier, which is much the same as the previous report concerning three patients who had a post-mortem examination (12).

An interesting and major manifestation in this patient, abulia, is regarded as a behavioral change reflecting damage of the prefrontal cortex or disturbance of projections to the region via the basal ganglia circuit, especially the head of the caudate (13, 14). However, abulia is not a common manifestation of posterior encephalopathy, and there have been no reports that refer to persisting abulia as a main symptom of Cys A-induced encephalopathy. Although Bird et al reported that three patients acutely developed akinetic mutism on the third day after the introduction of intravenous Cys A, the symptom was temporary and completely resolved from 48 hours to few days after withdrawal of Cys A (15). They did not discuss in depth the mechanism of akinetic mutism induced by Cys A and associated changes of brain-imaging studies during the symptom. We consider that Cys A contributed to chronic subclinical encephalopathy before the acute exacerbation due to posterior encephalopathy because the first SPECT study already showed hypoperfusion in the bilateral frontal lobes and right basal ganglia including the caudate, which were regarded as lesions related to abulia in this patient. Hypoperfusion detected by SPECT was widespread in the cortex, extending well beyond abnormal areas detected by MRI one month after the onset of acute encephalopathy. Although it is unknown why perfusion of the entire cortex detected by SPECT decreased irrespective of improvement of high signal abnormalities in the posterior white matter, it is probable that overlap of chronic toxicity of Cys A and acute breakdown of posterior circulation brought about the most severe form of encephalopathy leading to irreversible abulia. In addition, necessary re-administration of small doses of Cys A to prevent exacerbation of atopic dermatitis might have participated in the persisting pathologic condition. High signal regions on parieto-occipital (occasionally temporal) regions by T2-weighted and FLAIR images with no abnormalities on DWI is a typical MRI finding of RPLES induced by Cys A, indicating vasogenic edema without cytological damage (2, 4, 16). As seen in this patient, abnormal lesions that were detectable with DWI at the onset are thought to be a useful predictor of irreversibility (2) and poor prognosis of posterior encephalopathy. T1-weighted MRI findings which were similar to those associated with laminar necrosis may also be a hallmark of irreversible encephalopathy induced by Cys A (17). Finally, it is clinically important that subtle symptoms, such as decrease of appetite and

activity, may have been the initial symptoms of Cys A-induced encephalopathy that acutely deteriorated, and they may not always be benign, 'reversible' symptoms.

## References

- 1) Hinchev J, Chaves C, Appignani B, et al. A reversible posterior leukoencephalopathy syndrome. *N Engl J Med* **334**: 494–500, 1996.
- 2) Mukherjee P, McKinstry RC. Reversible posterior leukoencephalopathy syndrome: evaluation with diffusion-tensor MR imaging. *Radiology* **219**: 756–765, 2001.
- 3) Gijtenbeek JM, van den Bent MJ, Vecht CJ. Cyclosporine neurotoxicity: a review. *J Neurol* **246**: 339–346, 1999.
- 4) Coley SC, Porter DA, Calamante F, Chong WK, Connelly A. Quantitative MR diffusion mapping and cyclosporin-induced neurotoxicity. *Am J Neuroradiol* **20**: 1507–1510, 1999.
- 5) Covarrubias DJ, Luetmer PH, Campeau NG. Posterior reversible encephalopathy syndrome: prognostic utility of quantitative diffusion-weighted MR images. *Am J Neuroradiol* **23**: 1038–1048, 2002.
- 6) Schwartz RB, Bravo SM, Klufas RA, et al. Cyclosporine neurotoxicity and its relationship to hypertensive encephalopathy: CT and MR findings in 16 cases. *Am J Roentgenol* **165**: 627–631, 1995.
- 7) Antunes NL, Small TN, George D, Boulad F, Lis E. Posterior leukoencephalopathy syndrome may not be reversible. *Pediatr Neurol* **20**: 241–243, 1999.
- 8) Ay H, Buonanno FS, Schaefer PW, et al. Posterior leukoencephalopathy without severe hypertension. Utility of diffusion-weighted MRI. *Neurology* **51**: 1369–1376, 1998.
- 9) McDonald JW, Goldberg MP, Gwag BJ, Chi SI, Choi DW. Cyclosporine induces neuronal apoptosis and selective oligodendrocyte death in cortical cultures. *Ann Neurol* **40**: 750–758, 1996.
- 10) Tajima Y, Isonishi K, Kashiwaba T, Tashiro K. Two similar cases of encephalopathy, possibly a reversible posterior leukoencephalopathy syndrome: serial findings of magnetic resonance imaging, SPECT and angiography. *Intern Med* **38**: 54–58, 1999.
- 11) Klatzo I. Neuropathological aspects of brain edema. *J Neuropathol Exp Neurol* **26**: 1–14, 1967.
- 12) Reece DE, Frei-Lahr DA, Shepherd JD, et al. Neurologic complications in allogeneic bone marrow transplant patients receiving cyclosporin. *Bone Marrow Transplant* **8**: 393–401, 1991.
- 13) Cummings JL. Frontal-subcortical circuits and human behavior. *Arch Neurol* **50**: 873–880, 1993.
- 14) Bhatia KP, Marsden CD. The behavioural and motor consequences of focal lesions of the basal ganglia in man. *Brain* **117**: 859–876, 1994.
- 15) Bird GL, Meadows J, Goka J, Polson R, Williams R. Cyclosporin-associated akinetic mutism and extrapyramidal syndrome after liver transplantation. *J Neurol Neurosurg Psychiatry* **53**: 1068–1071, 1990.
- 16) Furukawa M, Terae S, Chu BC, Kaneko K, Kamada H, Miyasaka K. MRI in seven cases of tacrolimus (FK-506) encephalopathy: utility of FLAIR and diffusion-weighted imaging. *Neuroradiology* **43**: 615–621, 2001.
- 17) Bargallo N, Burrel M, Berenguer J, Cofan F, Bunesch L, Mercader JM. Cortical laminar necrosis caused by immunosuppressive therapy and chemotherapy. *Am J Neuroradiol* **21**: 479–484, 2000.