

Unruptured paraclinoid aneurysms: a management strategy

KOJI IHARA, M.D., KENICHI MURAO, M.D., NOBUYUKI SAKAI, M.D.,
ATSUSHI SHINDO, M.D., HIDEKI SAKAI, M.D., TOSHIO HIGASHI, M.D.,
SHUJI KOGURE, M.D., JUN C. TAKAHASHI, M.D., KATSUHIKO HAYASHI, M.D.,
TOSHIHIRO ISHIBASHI, M.D., AND IZUMI NAGATA, M.D.

Department of Cerebrovascular Surgery, National Cardiovascular Center, Suita, Osaka, Japan

Object. To elucidate an optimal management strategy for unruptured paraclinoid aneurysms, the authors retrospectively reviewed their experience in the treatment of 100 patients who underwent 112 procedures for 111 paraclinoid aneurysms performed using direct surgery and/or endovascular treatment.

Methods. Between 1997 and 2002, 111 unruptured paraclinoid aneurysms categorized according to a modified al-Rodhan classification (Group Ia, 30 anterior wall lesions; Group Ib, 25 ventral paraclinoid lesions; Group II, 18 true ophthalmic artery lesions; Group III, 37 carotid cave lesions; and Group IV, one transitional lesion) were treated by direct surgery (35 lesions) and/or endovascular treatment (77 lesions) (one aneurysm was treated by both procedures). In lesions in Groups Ia, Ib, II, and III that were treated by endovascular treatment, complete aneurysm obliteration was achieved in 50, 65, 50, and 78%, respectively, and the combined transient and permanent morbidity rates due to cerebral embolic events were 20, 25, 20, and 13.9%, respectively. Overall, the transient morbidity rate after endovascular treatment was 14.3% and the permanent morbidity rate was 6.5%. Notably, permanent visual deficits caused by retinal embolism occurred after endovascular treatment in two patients with Group II aneurysms. Direct surgery was mainly performed in Groups Ia (20 lesions), Ib (five lesions), and II (eight lesions), with complete neck clip occlusion achieved in 80, 80, and 71.4%, respectively; the transient and permanent morbidity rates associated with aneurysms treated by surgery were 8.6 and 2.9%, respectively.

Conclusions. Endovascular therapy for superiorly projecting paraclinoid aneurysms (Groups Ia and II) is associated with lower rates of complete obliteration than direct surgery, and with rates of cerebral embolic events comparable to those of endovascular treatment in the other groups. Furthermore, endovascular treatment for Group II aneurysms entails additional risks of retinal embolism. Therefore, direct surgery is recommended for the treatment of paraclinoid aneurysms projecting superiorly. For other groups, especially for Group III, endovascular treatment is the acceptable first line of therapy.

KEY WORDS • paraclinoid aneurysm • clip application • coil embolization • ophthalmic artery • carotid cave

ANEURYSMS arising from the ICA between the site of its exit from the roof of the cavernous sinus and the origin of the posterior communicating artery have been collectively termed paraclinoid aneurysms.^{3,6,10,15,19,21,23,30,40} The proposed nomenclature for aneurysms of this region remains contradictory for anatomical reasons. Unlike most aneurysms, these aneurysms arise at a location unrelated to specific arterial branches. In this area aneurysms can be intradural, extradural, or both; there is no reliable radiographic investigation to make this determination possible. Surgical treatment of paraclinoid aneurysms remains a technical challenge to many neurosurgeons, because of the close relationship these aneurysms hold to bone structures of the skull base, the cavernous sinus, and critical cranial nerves. The surgical difficulties encountered in treating paraclinoid aneurysms depend on their anatomical features, especially their relationship to the dura mater. For example, aneurysms that straddle the dural ring may require broad

opening of the distal ring for adequate control and clip placement. In contrast, aneurysms identified as being completely intradural may require only an anterior clinoidectomy. Since the advent of endovascular techniques, excellent results with Guglielmi Detachable Coil embolization of paraclinoid aneurysms have been reported,^{12,37} especially for those lesions associated with a high surgical risk.¹⁶ The results of these studies have suggested that good overall outcomes can be achieved in the treatment of paraclinoid aneurysms by a combined team approach of direct surgery and endovascular coil embolization by individualizing a management strategy. To date, however, no investigator has proposed a clear management strategy based on the groups of aneurysms found at this location. In this paper we review our experience in treating paraclinoid aneurysms, and propose a management strategy based on individual anatomical and clinical factors in each group of aneurysms.

Clinical Material and Methods

Patient Population

Between July 1997 and October 2002, 472 unruptured

Abbreviations used in this paper: AVM = arteriovenous malformation; CA = carotid artery; CT = computerized tomography; ICA = internal CA; MR = magnetic resonance; OphA = ophthalmic artery; 3D = three-dimensional.

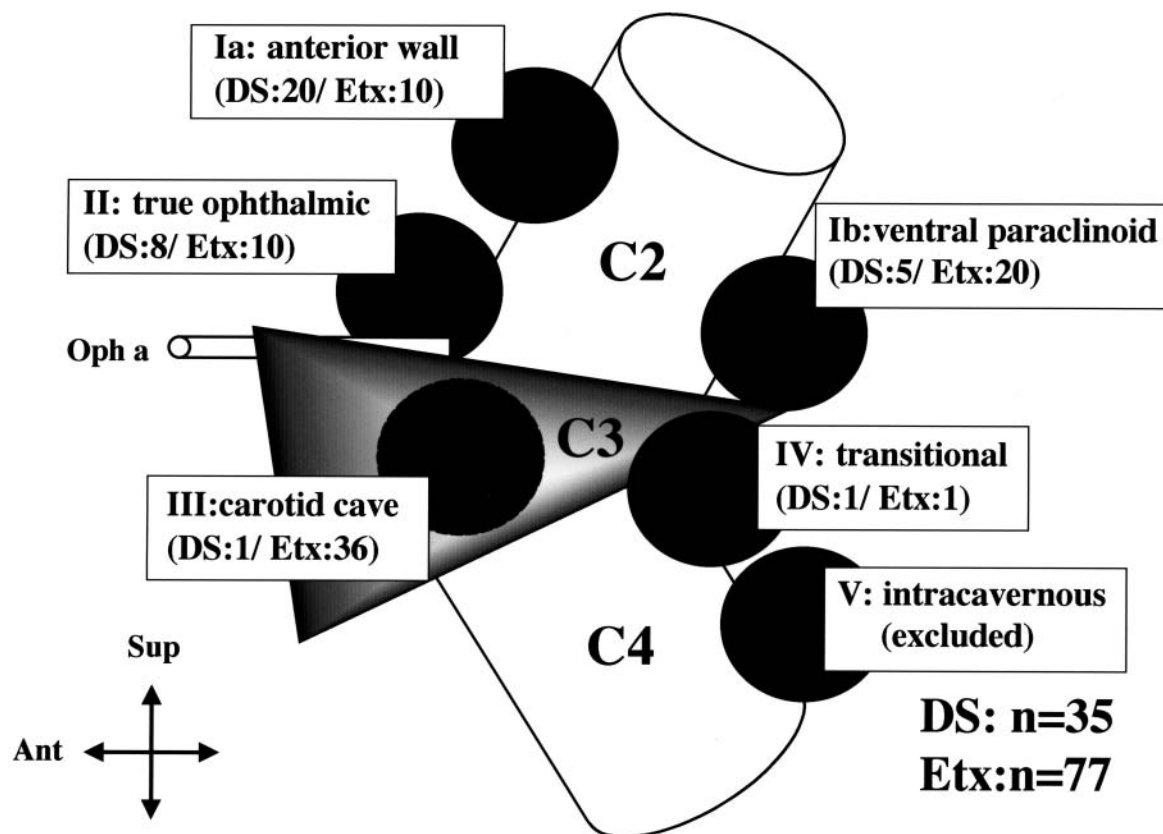


FIG. 1. Schematic drawing showing the modified al-Rodhan classification of paraclinoid aneurysms and the number of the aneurysms in each group assigned to direct surgery (DS) or endovascular treatment (Etx) in this series. n = number; Oph a = OphA.

aneurysms were treated by the neurovascular team at the National Cardiovascular Center. During this period, 111 unruptured paraclinoid aneurysms, none of which were giant, were treated by neck clipping (34 lesions) or coating (one lesion) performed surgically (35 lesions) or by endosaccular obliteration performed endovascularly (77 lesions); in one case an aneurysm was treated using both procedures. Large or giant aneurysms that required therapeutic occlusion of the ICA were excluded from this study.

The aneurysms were classified into five groups according to a method reported previously (Fig. 1).² Briefly, Group I included aneurysms with necks that arose intradurally from the ophthalmic segment of the ICA. This group was divided into two subtypes: Ia refers to aneurysms that project superiorly, are unassociated with branching arteries, and are entirely located intradurally (“anterior wall aneurysm,” originally designated as “superior hypophysial.”^{20,33}); and Ib refers to aneurysms that project postero-inferiorly intradurally or, in some cases, extradurally into the cavernous sinus (“ventral paraclinoid aneurysm”³²). The term anterior wall is used, instead of superior hypophysial, for Group Ia aneurysms, because aneurysms arising from the superior hypophysial artery are usually located at the medial or inferomedial wall of the ICA at the clinoidal or infraclinoidal level.³⁶ Group II includes “true OphA aneurysms” with necks that arise at the junction of the OphA and the ICA.^{6,8} Group III aneurysms are “carotid cave aneurysms,” located in medial infraophthalmic and supracavernous

regions.²² Group IV (“transitional”) includes cavernous aneurysms in which the neck arises from the cavernous segment of the ICA but the dome projects superiorly into the intradural extracavernous subarachnoid space.² Group V aneurysms are purely intracavernous and were excluded from the present study. Aneurysm size was classified as small (< 5 mm), medium (5–9 mm), large (> 10–25 mm), and giant (> 25 mm). The preprocedural workup included CT scanning; digital subtraction angiography, with routine use of 3D rotational digital angiography in the latter part of the series (since August 2000); 3D CT angiography (Toshiba Aquillion Multi; Toshiba Corp., Medical Systems Co., Otawara, Tochigi, Japan) with or without subtraction; and MR imaging. The angiographic result after coil embolization was graded as follows: complete obliteration (no contrast filling of the dome, body, or neck of the aneurysm); neck remnant (some contrast filling of part of the neck of the aneurysm); and body filling (some contrast filling of the dome still observed due to incomplete Guglielmi Detachable Coil packing).

Surgical Technique

A cervical skin incision is usually made before craniotomy to secure the cervical ICA unless the aneurysm is located well above the distal ring. Alternatively, a balloon catheter is placed in the ICA for proximal control. A standard pterional craniotomy is performed with the sylvian fissure

Management strategy for paraclinoid aneurysms

widely open. The falciform ligament is incised, allowing mobilization of the optic nerve. The intradural clinoid process is removed intradurally with or without unroofing of the posterior end of the optic canal by using a high-speed diamond drill. The dural rings are opened and the distal cavernous segment of the ICA is exposed when necessary. Temporary occlusion is performed if the lesion is large and retrograde suction is applied. In the case of aneurysms projecting superiorly (anterior wall or true OphA lesions), an angled clip is introduced over the ICA from the lateral side with the blades of the clip pointing medially and inferiorly, or a right-angled clip is applied along the ICA from the proximal side in a parallel fashion with the blades of the clip pointing distally. In cases in which the aneurysm projects inferiorly (ventral paraclinoid aneurysms), an angled fenestrated clip is applied in a parallel fashion with the CA in the fenestration. The clip blade is advanced until bone contact is made.

Endovascular Technique

After local anesthesia has been administered, a No. 6 French guide catheter (Envoy; Cordis Endovascular Systems, Miami, FL) or a No. 7 French guide catheter (Brite-tip; Cordis Endovascular Systems), used in remodeling technique for broad-based aneurysms, is placed on the ICA while the patient receives systemic heparinization. A microcatheter is delivered coaxially, with the tip placed in the proximal portion or in the middle of the aneurysm sac. Guglielmi Detachable Coils (Target Therapeutics-Boston Scientific, Natick, MA) are distributed within the aneurysm sac. A nondetachable silicon balloon catheter (Commodore; Cordis Neurovascular, Miami, FL) is positioned over the aneurysm neck and inflated for a short period (not more than 2–4 minutes at a time) in cases in which a remodeling technique is used.

Management Strategy

We initially sought the possibility of endovascular treatment as the first line of therapy for paraclinoid aneurysms. Endovascular treatment has several theoretical advantages over surgical treatment; for example, removal of the clinoid and opening of the cavernous sinus are not necessary, there is ease of proximal control without cervical incision, and the procedure is less invasive. One limiting anatomical factor for successful endovascular treatment of the aneurysms is the presence of a wide neck (> 4 mm) or a small dome/neck ratio (< 2);^{7,9} these are relatively common in aneurysms in this location, necessitating the use of a remodeling technique performed with the aid of a nondetachable microballoon catheter.¹ For surgical treatment, the presence of dense calcification at the neck is an important limiting factor. For Group III aneurysms, more extensive resection of the anterior clinoid process and optic strut is required to expose the aneurysm for clip placement. In addition, selection of an appropriate size and shape of clips is more difficult to obtain complete obliteration without compromise of the clinoidal (C-3) portion of the CA. On the other hand, the presence of thrombosis within the aneurysms is attended by specific problems for each treatment modality. Taking into consideration the anatomical factors of the aneurysms and the medical risks and wishes of the patient, a management strategy was tailored to individual patients.

TABLE 1

Characteristics of 100 patients presenting with III aneurysms at hospital admission

| Characteristic | No. of Procedures (%) | |
|--------------------------|---------------------------------|--|
| | Surgery Group (35 aneurysms) | Endovascular Treatment Group (77 aneurysms) |
| female patients | 26 (74) | 61 (79) |
| patient age (yrs) | 52 ± 9 | 56 ± 9 |
| aneurysm size (mm) | | |
| <5 | 15 (43) | 35 (45) |
| 5–9 | 15 (43) | 31 (40) |
| 10–25 | 5 (14) | 11 (14) |
| >25 | 0 (0) | 0 (0) |
| aneurysm dome/neck ratio | 1.6 ± 0.6 | 1.8 ± 0.8 |
| mode of discovery | | |
| incidental | 26 (74) | 59 (77) |
| headache | 7 (20) | 8 (10) |
| compressive symptoms | 2 (6)* | 2 (3)* |
| cerebrovascular disease | 0 (0) | 8 (10)† |

* Visual disturbance.

† Associated with a ruptured aneurysm (five patients), lacuna infarction (one patient), carotid-cavernous fistula (one patient), or AVM (one patient).

Results

Patient Demographics

Between November 1997 and October 2002, 472 unruptured cerebral aneurysms were treated at our institution. Among those, 336 aneurysms (71.2%) were treated surgically and the rest by endovascular methods. During the same period, 111 paraclinoid aneurysms were treated by either modality (one lesion was treated by both), comprising 23.5% of the cerebral aneurysms (Table 1). Presentations for the 112 procedures were as follows: incidental (76%), headache (13%), visual symptoms (4%), SAH from an associated aneurysm (4%), and SAH associated with an AVM or arteriovenous fistula, a carotid cavernous fistula, and a cerebral infarction (1% each). Eighty-seven (78%) of the patients were female and the mean age was 54.5 years. Multiple aneurysms were found in 24% of patients.

Based on the management strategy described earlier, surgical treatment was chosen in 35 cases and endovascular therapy in 77 cases, comprising 10.4 and 56.6%, respectively, of each modality applied (Fig. 1). Combined surgical and endovascular treatment was performed in the one patient with a Group IV lesion and this case was counted twice. Anatomical factors of the aneurysms obtained in the preoperative workups in each group are summarized in Table 1. The mean size of the aneurysms in Group II (8.5 ± 4.5 mm) was significantly larger than that in Group III (5.1 ± 2.1 mm) ($p < 0.05$, Kruskal–Wallis test, Scheffé¹⁷ F test). Except for this, there were no significant differences among the different groups in anatomical factors (size and dome/neck ratio) or frequency of use of a balloon-assisted technique.

Therapeutic Choice Based on Classification

All but one patient with a Group III aneurysm underwent endovascular treatment; this treatment decision was based on the most proximal location of the lesion in relation to distal dural rings and the inherent higher risk of cranial

TABLE 2

Anatomical outcomes after direct surgery and endovascular treatment for paraclinoid aneurysms*

| Aneurysm Group | No. of Procedures (%) | | | | |
|--|-----------------------|-----------|----------|----------|-----------|
| | Total | CO | NR | BF | Other |
| direct surgery (35 aneurysms) | | | | | |
| Ia | 20 | 16 (80.0) | 4 (20.0) | 0 (0) | 0 (0) |
| Ib | 5 | 4 (80.0) | 1 (20.0) | 0 (0) | 0 (0) |
| II | 8 | 5 (62.5) | 1 (12.5) | 1 (12.5) | 1 (12.5)† |
| III | 1 | 0 (0) | 0 (0) | 0 (0) | 1 (100)‡ |
| IV | 1 | 0 (0) | 0 (0) | 0 (0) | 1 (100)§ |
| endovascular treatment (77 aneurysms) | | | | | |
| Ia | 10 | 5 (50.0) | 5 (50.0) | 0 (0) | 0 (0) |
| Ib | 20 | 13 (65.0) | 3 (15.0) | 4 (20.0) | 0 (0) |
| II | 10 | 5 (50.0) | 2 (20.0) | 3 (30.0) | 0 (0) |
| III | 36 | 28 (77.8) | 5 (13.9) | 3 (8.3) | 0 (0) |
| IV | 1 | 0 (0) | 0 (0) | 0 (0) | 1 (100)§ |

* BF = body filling; CO = complete obliteration; NR = neck remnant.

† In one patient with a large Group II aneurysm that straddled the dural ring, only the intradural part of the aneurysm was clipped intentionally.

‡ Coating was performed in the only Group III aneurysm in the direct surgery group.

§ In one patient with a Group IV aneurysm, a combined approach, intentional body clipping followed by complete endovascular obliteration, was performed. This lesion is counted twice.

nerve palsy due to more extensive drilling of basal bone structures (Fig. 1). One patient who harbored with a Group IV aneurysm with a broad neck was treated by a combined approach of direct surgery and endovascular treatment.

For Group Ib (ventral paraclinoid) aneurysms therapeutic plans were made on a case-by-case basis, depending on the relationship between the proximal aspect of the neck and the basal bone structure,³⁰ and the size of the dome and neck. Overall, 20 patients (80%) with Group Ib aneurysms were treated endovascularly (Fig. 1). After an interim analysis of treatment outcomes, we revised our management strategy for Groups Ia and II aneurysms (superiorly projecting aneurysms), as described in the *Discussion* section.

Results of Our Initial Strategy for Groups Ia and II Aneurysms

By the end of October 2000, 30 patients with Group Ia or II aneurysms were treated by either modality (15 cases each). During this period, one attempt at endovascular treatment in a patient with a Group II aneurysm (6.7%) failed because of an instability of the microcatheter. In the endovascular treatment group, permanent visual deficit was seen in two patients with Group II aneurysms; the deficit was caused by a retinal embolism that occurred during and after embolization (13.3% of the initial 15 cases). Furthermore, anatomical outcome was significantly better in the group treated surgically than in the group treated endovascularly ($p < 0.05$, Mann-Whitney U-test). This preliminary result prompted us to change our management strategy, such that paraclinoid aneurysms projecting superiorly (Groups Ia and II) should be treated surgically as the first line of therapy, unless the neck of the aneurysm is heavily calcified or there are unfavorable patient medical conditions.

TABLE 3

Neurological complications in patients who underwent endovascular therapy for 77 paraclinoid aneurysms*

| Aneurysm Group | No. of Procedures (%) | | | | |
|----------------|-----------------------|---------------|---------------|---------------|---------------|
| | Total | Permanent CIE | Transient CIE | Permanent VFD | Transient VFD |
| Ia | 10 | 0 (0) | 2 (20.0) | 0 (0) | 0 (0) |
| Ib | 20 | 1 (5.0) | 4 (20.0) | 0 (0) | 0 (0) |
| II | 10 | 0 (0) | 2 (20.0) | 2 (20.0) | 0 (0) |
| III | 36 | 2 (5.6) | 3 (8.3) | 0 (0) | 0 (0) |
| IV† | 1 | 0 (0) | 0 (0) | 0 (0) | 0 (0) |

* CIE = cerebral ischemic event; VFD = visual field deficit.

† This aneurysm was treated by both direct surgical and endovascular means.

Overall Results

Anatomical outcomes after endovascular treatment in each subgroup are summarized in Table 2. The rate of complete obliteration after endovascular treatment tended to be highest in Group III (78%), followed by Group Ib (65%) and Groups Ia and II (50% each), although these differences did not reach statistical significance ($p = 0.24$, Kruskal-Wallis test).

Overall complication rates in the subgroups of aneurysms treated endovascularly are shown in Table 3. Of note, among the different subgroups in the endovascular treatment group, there was no significant difference in neurological complication rates due to cerebral embolic events ($p = 0.29$). Nevertheless, retinal embolism was a unique complication in the endovascular treatment of Group II aneurysms.

In the direct surgery group, the anterior clinoid process was removed intradurally by using a high-speed diamond drill in 33 cases (94%); the only exceptions were two patients with Group Ia lesions. The overall rate of complete clip occlusion was 73.5% (25 of 34 aneurysms; the case in which both surgery and endovascular treatment was used has been omitted) without any significant difference among subgroups (Groups Ia, Ib, and II, $p = 0.95$; Table 2). Dome filling via a small residual neck at its proximal end occurred in one patient (2.9%); this was caused by contact of the clip blade with the bone structure of the skull base. The overall complication rate of surgical treatment of aneurysms was low, with permanent olfactory nerve dysfunction, transient optic nerve deficit, oculomotor nerve disturbance, and seizure occurring in one patient each (Table 4). Proximal CA control was obtained by exposing the cervical CA in 23 cases (66%) or by placing a nondetachable balloon catheter into the distal ICA during heparinization in the initial five cases (14%). During the initial cases, proximal control of the CA was obtained endovascularly, but we frequently encountered troublesome oozing from the cavernous sinus when it was opened during systemic heparinization. Recently, proximal control has usually been achieved by a direct surgical approach and may not be attained, especially if the aneurysm is projecting superiorly and located well above the anterior clinoid process (20%).

Indication for Treatment

Until December 2000, we treated virtually all patients younger than 70 years of age who were referred to our hos-

Management strategy for paraclinoid aneurysms

pital with carotid cave aneurysms larger than 3 mm (26 patients with a mean age of 56.3 years; mean diameter of aneurysm 4.8 mm). In January 2001, after analyzing the outcomes of such treatment, we revised our treatment plan such that only aneurysms 5 mm or larger would be treated in principle. Since then, only 10 of 19 patients who were referred to us have been treated (10 patients with a mean age of 52 years; mean diameter of aneurysm 6 mm). In fact, the fraction of carotid cave aneurysms smaller than 5 mm in all those treated decreased considerably from 73% before January 2001 to 30% thereafter. Although a relatively high percentage of small and asymptomatic aneurysms have been treated with some combined permanent and transient incidences of morbidity, none of the patients have shown significant morbidity (modified Rankin Scale score 2–5) at 1-year follow up in this series. Using our management strategy, the overall results we achieved in the treatment of paraclinoid aneurysms were considered excellent compared with other recent series.^{3,6,16}

Follow-Up Results

Three aneurysms (two Group II and one Group Ib lesions) that were endovascularly treated demonstrated coil compaction or regrowth on follow-up angiograms obtained 6 months later and required repeated treatment. No aneurysm that was treated surgically required additional treatment. During the follow-up periods, no bleeding event was observed after either modality of treatment.

Illustrative Case

This 34-year-old woman with the diagnosis of a cerebral AVM underwent follow-up cerebral angiography for intractable epilepsy. Angiograms revealed an unruptured small true OphA aneurysm with a broad neck, which was located on the right side. Complete obliteration of the aneurysm was achieved uneventfully by using a balloon-assisted technique. Two days later, while the patient was receiving anticoagulation therapy, she suddenly experienced a right visual disturbance. Ophthalmological evaluation revealed a marked retinal edema due to an embolism of the central retinal artery. The patient was discharged with a persistent partial visual field defect.

Discussion

With the advent of endovascular techniques and inherent surgical risk, paraclinoid aneurysms were suggested as one of the most appropriate targets of endovascular treatment. In the present study, we analyzed our results according to the classification proposed by al-Rodhan, et al.,² and we suggest that superiorly projecting aneurysms (Groups Ia and II) should be treated by direct surgery as the first line of therapy, whereas for other subgroups, especially carotid cave aneurysms, endovascular treatment should be considered an appropriate first line of therapy.

Recent refinements in direct surgery have produced excellent results in surgical clip occlusion of paraclinoid aneurysms.¹¹ Removal of the anterior clinoid process allows at least 6 mm more exposure of the proximal ICA without entering the true cavernous sinus.³¹ Preoperative 3D CT angi-

TABLE 4

*Neurological complications in patients who underwent direct surgery for 35 paraclinoid aneurysms**

| Aneurysm Group | No. of Procedures (%) | | | | |
|----------------|-----------------------|---------------|---------------|---------|-------|
| | Total | Permanent CNP | Transient CNP | Seizure | CIE |
| Ia | 20 | 0 (0) | 2 (10.0) | 1 (5.0) | 0 (0) |
| Ib | 5 | 0 (0) | 0 (0) | 0 (0) | 0 (0) |
| II | 8 | 1 (12.5) | 0 (0) | 0 (0) | 0 (0) |
| III | 1 | 0 (0) | 0 (0) | 0 (0) | 0 (0) |
| IV† | 1 | 0 (0) | 0 (0) | 0 (0) | 0 (0) |

* CNP = cranial nerve palsy.

† This aneurysm was treated by both direct surgical and endovascular means.

ography with subtraction techniques helps plan the extent of drilling and clip placement. Intraoperative angiography²⁹ and suction-decompression techniques during temporary trapping are useful to facilitate safe and complete clip placement, especially in large or giant paraclinoid aneurysms.^{4,35} Regarding endovascular surgery, the technique of using a balloon to remodel coils at the neck of the aneurysm has also made wider-neck lesions treatable with coil embolization.¹ It remains controversial whether remodeling techniques increase thromboembolic complications.^{24,27} Neck size is an independent risk factor for these complications,³⁴ probably because the increased surface area of exposed coils at the interface of the aneurysm and parent artery could serve as a nidus for fibrin strand and platelet aggregates.

Recently, Hoh, et al.,¹⁶ reported excellent outcomes in the management of 238 paraclinoid aneurysms by a combined neurovascular team and emphasized the importance of a combined team approach for such formidable lesions. Their series included patients who presented with SAH and a higher percentage of patients with large or giant aneurysms; the two groups had a comparable rate of morbidity. Higher-grade aneurysms tended to be treated with endovascular techniques, but the authors did not describe in detail how aneurysms of different anatomical groups were assigned to each treatment modality. From a surgical perspective, superiorly projecting C-2 aneurysms (Group Ia or II) are easiest to treat, having little association with superior hypophysial vessels or other strategically important vessels. Frequently, only the optic nerve and the OphA artery must be negotiated. On the other hand, clip occlusion of carotid cave aneurysms (Group III) requires more extensive drilling of the basal bone structure, thereby theoretically increasing the surgical risk. In the original description of carotid cave aneurysms, worsened vision was noted postoperatively in two of seven cases.²² The presence of a neck remnant or body filling was observed at postoperative angiography in six superiorly projecting aneurysms in this series (five Group Ia [19%] and one Group II [3.7%] lesions). In most cases, such a minimal neck remnant (< 3 mm) was observed because sufficient neck had to be preserved to spare the OphA artery or to prevent a kink in the ICA. The results of a recent study³⁸ confirmed the long-term efficacy of clip placement for unruptured aneurysms, but the cumulative risk for SAH was high compared with that in the general population, even after treatment. Recently, a surprising number of cases have been presented in which a seem-

ingly unimportant 1- to 2-mm residual neck dilates over a long period, eventually becoming a dangerous aneurysm.²⁵ Long-term follow up performed using 3D CT angiography is recommended for patients with minimal residual necks after clip placement for superiorly projecting paraclinoid aneurysms (Group Ia or II lesions).

In the present study, the anatomical outcomes for superiorly projecting aneurysms after direct surgery were significantly better than after endovascular treatment, resulting in a revision of our management strategy. Furthermore, a failed attempt was noted in one of the initial 15 cases in this subgroup because of an instability of the microcatheter in the aneurysm. This may be another unfavorable factor for endovascular treatment of aneurysms projecting superiorly. This situation contrasts with the one encountered with aneurysms projecting inferiorly (ventral paraclinoid aneurysms), in which the location of aneurysms within the concavity of the curve formed by the carotid siphon facilitates catheterization. In the last 2 years, 13 (72%) of 18 superiorly projecting aneurysms were treated surgically, whereas only five cases were treated endovascularly for various reasons such as keloid constitution and patient's refusal of surgery. The natural history of the neck remnant of the paraclinoid aneurysm after endovascular treatment is an important problem that remains to be fully elucidated.^{14,26} This is especially important, because paraclinoid aneurysms tend to have two anatomical factors, wide necks and large size, that adversely affect anatomical outcome and long-term durability of results after endovascular treatment.^{14,26} Because increasing stability is demonstrated angiographically in treated aneurysms up to 3 years following coil embolization,²⁸ further follow-up studies are mandatory. Of note, two of three aneurysms that required repeated treatment at the follow-up angiography were Group II aneurysms.

Visual deficits caused by a retinal embolism were unique complications encountered in the endovascular treatment of Group II aneurysms. Retinal artery occlusion is commonly observed in elderly patients with risk factors for arterial occlusive disease and carotid occlusive disease, and is most often caused by embolization.¹³ Based on the irregular, attenuated appearance on fundus examination of the arterioles due to hypoperfusion of the retina, emboli derived from the aneurysm during or after embolization is the most likely explanation for the retinal artery occlusion in these cases. In fact, retinal artery occlusion was reported to occur in two cases following coil embolization of 71 CA-OphA aneurysms.⁵ In the series reported by Hoh, et al.,¹⁶ there were two patients with new visual deficits after endovascular treatment, but the authors did not clarify the causes of these deficits. These results show that, similar to direct surgery especially for Group II aneurysms, endovascular therapy can pose a risk of visual deficit by occluding the retinal artery by emboli from coils packed in the aneurysm through the OphA artery.

Aneurysms arising from the posterior wall of the ICA have been grouped together as ventral paraclinoid aneurysms.^{10,32} In Nutik's cases,³⁰ the aneurysms arose from the ICA opposite the origin of the OphA and the site of origin was partly intradural and partly intracavernous. Especially when the size of the aneurysm increases, there would be a greater chance of incomplete clip occlusion because of contact between the clip blade and the basal bone structure. As a result, 20 cases (80%) of 25 Group Ib aneurysms were

treated endovascularly. Of note, complete obliteration following endovascular treatment of Group Ib lesions was achieved in 65% of cases, which was better than the 50% rate for superiorly projecting aneurysms (combined Groups Ia and II) and worse than that the 78% rate for carotid cave lesions (Group III). Complete clip occlusion of the aneurysm neck was achieved in four patients (80%) with Group Ib aneurysms, indicating that a ventral paraclinoid lesion can be safely clipped surgically, especially if the lesion is small and located well above the basal bone structure. On the other hand, it is difficult to obtain complete obliteration of large and wide-necked ventral paraclinoid aneurysms no matter which modality is chosen.

All but one carotid cave aneurysm were treated endovascularly in the present series, providing the highest rate of complete obliteration (78%) with the lowest combined transient and permanent morbidity rate (13.9%), although these differences were not significant. The size of the carotid cave lesions was significantly smaller than that of true OphA aneurysms (Group II). Although surgery was performed in only one patient with a Group III aneurysm, because of presumably higher surgical risk, the overall results support our notion that Group III aneurysms are the most appropriate target of endovascular treatment among the different groups of paraclinoid aneurysms.

The indications for treatment deserve comment. The critical size at which an aneurysm ruptures remains in dispute.^{17,18,39} In our series, the mean size of carotid cave aneurysms was significantly smaller than that of true OphA aneurysms, probably because the growth of the former may be restricted by the surrounding structure. Assuming that small carotid cave aneurysms within the anatomical boundary of the cave may have a lower chance of rupture, we have become increasingly conservative in their treatment indications. At present, carotid cave aneurysms smaller than 5 mm are treated only in patients younger than 50 years of age based on patient preferences. To address the issue of the natural history of small unruptured paraclinoid aneurysms at various locations, we await the results of a currently ongoing nationwide prospective study (Unruptured Cerebral Aneurysm Study of Japan).

Conclusions

In this paper we have retrospectively reviewed our experience in 111 paraclinoid aneurysms that were treated in 112 procedures. Considering the inherent surgical risks, we initially sought the possibility of endovascular treatment as the first line of therapy for paraclinoid aneurysms. After an interim analysis, we revised our management strategy such that superiorly projecting paraclinoid aneurysms (Groups Ia and II) should be treated by direct surgery. Endovascular treatment is the acceptable first line of therapy for the other groups of paraclinoid aneurysms, especially for carotid cave aneurysms (Group III).

References

1. Aletich VA, Debrun GM, Misra M, et al: The remodeling technique of balloon-assisted Guglielmi detachable coil placement in wide-necked aneurysms: experience at the University of Illinois at Chicago. *J Neurosurg* **93**:388-396, 2000
2. al-Rodhan NR, Piepgras DG, Sundt TM Jr: Transitional cavern-

Management strategy for paraclinoid aneurysms

- ous aneurysms of the internal carotid artery. **Neurosurgery** **33**:993–998, 1993
3. Batjer HH, Kopitnik TA, Giller CA, et al: Surgery for paraclinoid-carotid artery aneurysms. **J Neurosurg** **80**:650–658, 1994
 4. Batjer HH, Samson DS: Retrograde suction decompression of giant paraclinoid aneurysms. Technical note. **J Neurosurg** **73**:305–306, 1990
 5. Castillo B Jr, De Alba F, Thornton J, et al: Retinal artery occlusion following coil embolization of carotid-ophthalmic aneurysms. **Arch Ophthalmol** **118**:851–852, 2000
 6. Day AL: Aneurysms of the ophthalmic segment. A clinical and anatomical analysis. **J Neurosurg** **72**:677–691, 1990
 7. Debrun GM, Aletich VA, Kehrli P, et al: Selection of cerebral aneurysms for treatment using Guglielmi detachable coils: the preliminary University of Illinois at Chicago experience. **Neurosurgery** **43**:1281–1297, 1998
 8. Drake CG, Vanderlinden RG, Amacher AL: Carotid-ophthalmic aneurysms. **J Neurosurg** **29**:24–31, 1968
 9. Fernandez Zubillaga A, Guglielmi G, Viñuela F, et al: Endovascular occlusion of intracranial aneurysms with electrically detachable coils: correlation of aneurysm neck size and treatment results. **AJNR** **15**:815–820, 1994
 10. Fox JL: Microsurgical treatment of ventral (paraclinoid) internal carotid artery aneurysms. **Neurosurgery** **22**:32–39, 1988
 11. Giannotta SL: Ophthalmic segment aneurysm surgery. **Neurosurgery** **50**:558–562, 2002
 12. Gurian JH, Viñuela F, Guglielmi G, et al: Endovascular embolization of superior hypophyseal artery aneurysms. **Neurosurgery** **39**:1150–1156, 1996
 13. Haritoglou C, Muller-Schunk S, Weber C, et al: Central retinal artery occlusion in association with an aneurysm of the internal carotid artery. **Am J Ophthalmol** **132**:270–271, 2001
 14. Hayakawa M, Murayama Y, Duckwiler GR, et al: Natural history of the neck remnant of a cerebral aneurysm treated with the Guglielmi detachable coil system. **J Neurosurg** **93**:561–568, 2000
 15. Heros RC, Nelson PB, Ojemann RG, et al: Large and giant paraclinoid aneurysms: surgical techniques, complications, and results. **Neurosurgery** **12**:153–163, 1983
 16. Hoh BL, Carter BS, Budzik RF, et al: Results after surgical and endovascular treatment of paraclinoid aneurysms by a combined neurovascular team. **Neurosurgery** **48**:78–90, 2001
 17. International Study of Unruptured Intracranial Aneurysms Investigators: Unruptured intracranial aneurysms—risk of rupture and risks of surgical intervention. **N Engl J Med** **339**:1725–1733, 1998
 18. Juvela S, Porras M, Poussa K: Natural history of unruptured intracranial aneurysms: probability of and risk factors for aneurysm rupture. **J Neurosurg** **93**:379–387, 2000
 19. Kim JM, Romano A, Sanan A, et al: Microsurgical anatomic features and nomenclature of the paraclinoid region. **Neurosurgery** **46**:670–682, 2000
 20. Kinouchi H, Mizoi K, Nagamine Y, et al: Anterior paraclinoid aneurysms. **J Neurosurg** **96**:1000–1005, 2002
 21. Knosp E, Muller G, Perneczky A: The paraclinoid carotid artery: anatomical aspects of a microneurosurgical approach. **Neurosurgery** **22**:896–901, 1988
 22. Kobayashi S, Kyoshima K, Gibo H, et al: Carotid cave aneurysms of the internal carotid artery. **J Neurosurg** **70**:216–221, 1989
 23. Kothandaram P, Dawson BH, Kruyt RC: Carotid-ophthalmic aneurysms. A study of 19 patients. **J Neurosurg** **34**:544–548, 1971
 24. Lefkowitz MA, Gobin YP, Akiba Y, et al: Balloon-assisted Guglielmi detachable coiling of wide-necked aneurysms: Part II—clinical results. **Neurosurgery** **45**:531–538, 1999
 25. Lin T, Fox AJ, Drake CG: Regrowth of aneurysm sacs from residual neck following aneurysm clipping. **J Neurosurg** **70**:556–560, 1989
 26. Murayama Y, Viñuela F, Duckwiler GR, et al: Embolization of incidental cerebral aneurysms by using the Guglielmi detachable coil system. **J Neurosurg** **90**:207–214, 1999
 27. Nelson PK, Levy DI: Balloon-assisted coil embolization of wide-necked aneurysms of the internal carotid artery: medium-term angiographic and clinical follow-up in 22 patients. **AJNR** **22**:19–26, 2001
 28. Ng P, Khangure MS, Phatouros CC, et al: Endovascular treatment of intracranial aneurysms with Guglielmi detachable coils: analysis of midterm angiographic and clinical outcomes. **Stroke** **33**:210–217, 2002
 29. Ng PY, Huddle D, Gunel M, et al: Intraoperative endovascular treatment as an adjunct to microsurgical clipping of paraclinoid aneurysms. **J Neurosurg** **93**:554–560, 2000
 30. Nutik S: Carotid paraclinoid aneurysms with intradural origin and intracavernous location. **J Neurosurg** **48**:526–533, 1978
 31. Nutik SL: Removal of the anterior clinoid process for exposure of the proximal intracranial carotid artery. **J Neurosurg** **69**:529–534, 1988
 32. Nutik SL: Ventral paraclinoid carotid aneurysms. **J Neurosurg** **69**:340–344, 1988
 33. Ogawa A, Suzuki M, Ogasawara K: Aneurysms at nonbranching sites in the supraclinoid portion of the internal carotid artery: internal carotid artery trunk aneurysms. **Neurosurgery** **47**:578–586, 2000
 34. Pelz DM, Lownie SP, Fox AJ: Thromboembolic events associated with the treatment of cerebral aneurysms with Guglielmi detachable coils. **AJNR** **19**:1541–1547, 1998
 35. Tamaki N, Kim S, Ehara K, et al: Giant carotid-ophthalmic artery aneurysms: direct clipping utilizing the “trapping-evacuation” technique. **J Neurosurg** **74**:567–572, 1991
 36. Tanaka Y, Hongo K, Tada T, et al: Radiometric analysis of paraclinoid carotid artery aneurysms. **J Neurosurg** **96**:649–653, 2002
 37. Thornton J, Aletich VA, Debrun GM, et al: Endovascular treatment of paraclinoid aneurysms. **Surg Neurol** **54**:288–299, 2000
 38. Tsutsumi K, Ueki K, Usui M, et al: Risk of subarachnoid hemorrhage after surgical treatment of unruptured cerebral aneurysms. **Stroke** **30**:1181–1184, 1999
 39. Weir B: Unruptured intracranial aneurysms: a review. **J Neurosurg** **96**:3–42, 2002
 40. Yaşargil MG, Gasser JC, Hodosh RM, et al: Carotid-ophthalmic aneurysms: direct microsurgical approach. **Surg Neurol** **8**:155–165, 1977

Manuscript received December 6, 2002.

Accepted in final form March 28, 2003.

Address reprint requests to: Koji Iihara, M.D., Department of Cerebrovascular Surgery, National Cardiovascular Center, 5-7-1 Fujishiro-dai, Suita, Osaka 565-8565, Japan. email: kiihara@hsp.nvcv.go.jp.